

**Pure White Cell Aplasia associated with Secondary Hemophagocytosis: experience from
The Indus Hospital**

Abstract:

Pure white cell aplasia (PWCA), also known as agranulocytosis without granulopoiesis, is an uncommon condition that causes neutropenia. If linked with thymomas or medication-induced PWCA, surgical thymectomy or drug cessation may be therapeutically helpful. Here we present the case of an adult 18-year-old male came at The Indus Hospital and Health Network (IHHN), Karachi in-patient department (IPD) with a complaint of colicky abdominal pain and loose stools for 10 days that were watery in consistency and large in amount, 6-7 episodes per day, for which he was taking flagyl. 5 days later, the patient developed high grade fever (102°F) with on and off chills that regressed on antipyretic. The patient also had decreased appetite and 2-3 episodes of vomiting. He had a history of dengue fever and Posterior Inferior Cerebellar Artery (PICA). Laboratory work-up revealed that he had been suffering from severe neutropenia. His bone marrow biopsy indicated absolute neutropenia with normocellular bone marrow demonstrating virtually total lack of myeloid progenitors, with maintenance of erythroid and megakaryocytic lineages, findings strongly indicative of PWCA with secondary hemophagocytosis.

Findings of the case highlights the importance of an unusual clinical condition PWCA with hemophagocytosis. The aggressive clinical course of the idiopathic variant necessitates early immunosuppressive treatment.

Key words: Pure white cell aplasia (PWCA), Hemophagocytosis, Hematology , neutrophil

Introduction:

Pure white cell aplasia (PWCA), also known as agranulocytosis without granulopoiesis, is an uncommon condition that causes neutropenia(1, 2). Because of their extreme neutropenia, these individuals frequently present with recurring infections(3). PWCA is an immune-mediated disease that severely inhibits myelopoiesis(4). PWCA instances, on the other hand, have been reported in conjunction with other autoimmune disorders, thymomas, chronic lymphocytic leukaemia, as an adverse medication response, or as idiopathic(4, 5). If linked with thymomas or medication-induced PWCA, surgical thymectomy or drug cessation may be therapeutically helpful. Immunosuppressive treatments such as corticosteroids, intravenous immunoglobulin, and cyclosporine are also available(2).

Here, we present a case of an adult 18 year old male, who presented with a complaint of colicky abdominal pain, loose stools and high grade fever and having the history of dengue and Posterior Inferior Cerebellar Artery (PICA).

Case Presentation:

An adult 18-year-old male presented at The Indus Hospital and Health Network (IHNN) , Karachi in-patient department (IPD) with a complaint of colicky abdominal pain and loose stools for 10 days that were watery in consistency and large in amount, 6-7 episodes per day, for which he was taking flagyl. 5 days later, the patient developed high grade fever (102°F) with on and off chills that regressed on antipyretic. The patient also had decreased appetite and 2-3 episodes of vomiting. During the previous 6 months, the patient had repeated hospital visits for similar problems. Patient's weight was 55 kg, vitals were: blood pressure (BP) 110/70 mm of Hg, pulse 90 beats per minute, respiratory rate 22 breaths per minute and temperature 98.6 °F. He had a history of dengue fever and Posterior Inferior Cerebellar Artery (PICA).

His laboratory work-up revealed that he had been suffering from severe neutropenia for the last 8 months, with a total leukocytic count of 3.2 (x10E9/L). Hemoglobin and platelet count were 12.5 gm/dl and 239 (x10E9/L) respectively. Routine chemical pathology investigations shows serum creatinine of 0.81 mg/dl with normal electrolytes. The C-reactive protein level was strikingly elevated at 246.5 mg/L (normal <5mg/L) and Vit-B 12 levels are normal. Molecular biology findings of HBV DNA - RT PCR - Detected (2097 IU/ml).Whereas, patient blood culture showed growth of Salmonella typhi. Patient had a weak positive ANA. On examination other standard laboratory workup was unremarkable including detailed infectious and rheumatologic assessments.

Table 1: Complete Blood Count Along with Differential Leukocyte Count of the Patient

CBC Parameters	Values
Hemoglobin (gm/dl)	12.5
Red Blood Cells Count (X10E12/L)	4.91
White Blood Cells (x10E9/L)	3.2
Platelet (x10E9/L)	239
Neutrophils (%)	04
Lymphocytes (%)	91
Monocytes (%)	05
Eosinophil's (%)	01

Ultrasound whole abdomen showed a few sub centimeter-sized mesenteric lymph nodes with the largest one measuring 0.8 cm in the short axis. Moving echoes are noted within the lumen of urinary bladder, likely representing urinary tract infection.

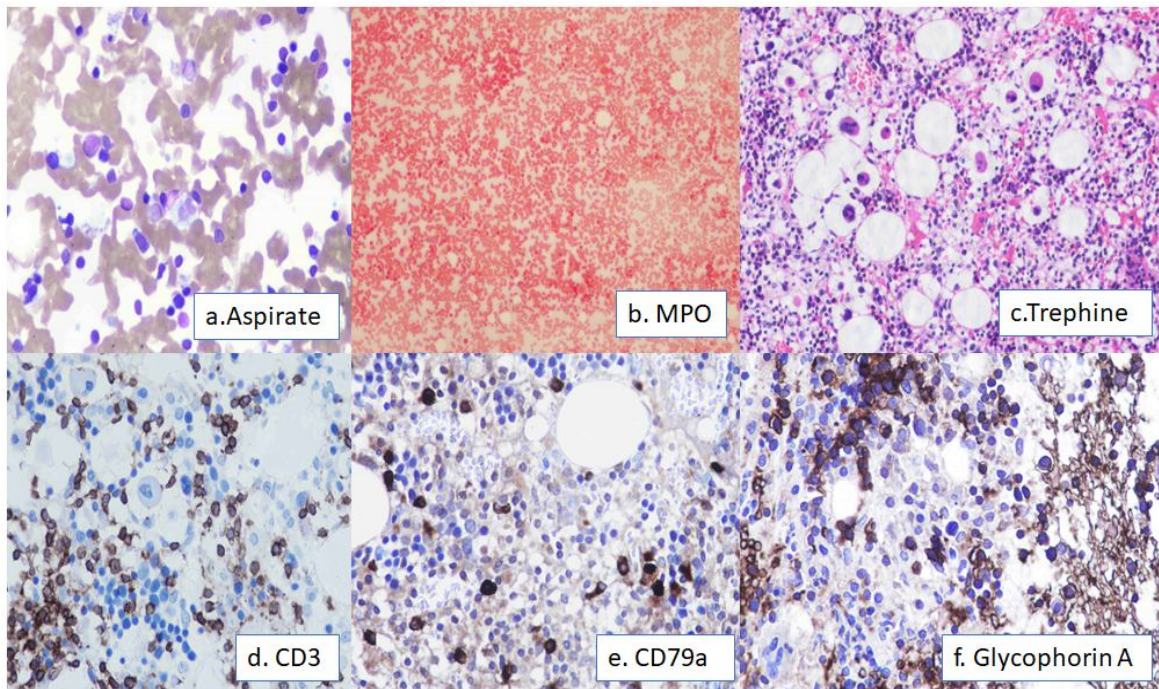


Fig 1 a, b & c shows Aspirate, MPO and trephine.

Fig 1 d, e & f shows immunohistochemistry findings (CD3, CD79a and Glycophorin A)

A bone marrow biopsy is performed as part of the workup for isolated neutropenia. A few days before the biopsy, patient received a single injection of G-CSF. His bone marrow analysis indicated absolute neutropenia with normocellular bone marrow demonstrating virtually total lack of myeloid progenitors, with maintenance of erythroid and megakaryocytic lineages, findings strongly indicative of PWCA with secondary hemophagocytosis. Immunohistochemistry reveals that CD3, CD79a, Glycoprotein, CD61, CD68 (PGM1), and CD68 (KP1) are positive, but CD34 and MPO are negative. Excess blasts, leishmaniasis,

hemoparasite, fibrosis, necrosis, granuloma, lymphoid aggregates, or metastatic disease are not present.

Discussion:

PWCA is a rare haematological condition characterised by agranulocytosis, an absence of all neutrophil series in the bone marrow, and normal erythropoiesis and megakaryopoiesis(3). The condition is frequently linked to autoimmune, drug-induced, or viral origins(4). The majority of instances, however, have been linked to thymoma and thymic cancer. This unusual condition can occur in patients with primary biliary cirrhosis or autoimmune hepatitis(5). PWCA has previously been linked to ibuprofen, chlorpropamide, and mesalazine medication exposure(6, 7).

A bone marrow biopsy was performed on our patient, which clearly suggests PWCA with subsequent hemophagocytosis. The PWCA was initially reported in 1983, and it was discovered that not all "white cells" are damaged, but rather primarily the neutrophils series, which is responsible in 70% of cases(8). A few more examples have been documented in the literature since then(2, 5). Although the exact cause of PWCA has not been determined. Even though PWCA may be recognized as an autoimmune illness, the proof of an immune-mediated mechanism by antibodies and/or T cells remains untested(2).

Secondary PWCA is assumed to have an autoimmune etiology with an antibody-mediated attack on myelocytic progenitor cells, whilst idiopathic or primary PWCA is an exceedingly uncommon disease which is frequently linked with secondary reasons. According to prior research, idiopathic entities appear to have an aggressive clinical course with a poor prognosis, with a higher risk of widespread fungal infections and severe sepsis(9). However, in our case report

PWCA with Haemophagocytic was determined and haemophagocytic lymphohistiocytosis (HLH) is an uncommon clinical illness that includes fever, hepatosplenomegaly, cytopenia, and progressive multi-organ failure. In contrast to hereditary HLH, HLH in adults is frequently related to autoimmune disorders, cancer, or infections. Secondary HLH treatment includes anti-tumor therapy as well as immunosuppressive medication, which is often administered in accordance with the HLH-2004 protocol(10).

The approach to treatment should be adapted to the underlying condition. However, it has been treated with steroids, cyclosporine, high-dose immunoglobulins, and other immunomodulatory treatments. Even though PWCA is extremely uncommon in everyday practice, it may be the root cause of isolated neutropenia. Like in our case, Bofalgan was given to the patient to alleviate pain; Topneuter was given as an injection (300 mcg) to promote the formation of white blood cells (WBCs) and protect the patient from infections; Tanzo (4.5 mcg), Stracef, and Cefixime were also given to treat infections; and mecobalamin (500mcg) was also given to the patient.

Conclusion:

This case highlights an unusual condition PWCA with hemophagocytosis, pathogenesis of which is unknown and it is probably mediated by the immune system. There is a dire need that once the condition diagnosed, examine its possible underlying causes. The aggressive clinical course of the idiopathic variant necessitates early immunosuppressive treatment.

Consent:

As per international standard or university standard patient's written consent has been collected and preserved by the author (s).

Ethical Approval:

As per international standard or university standard patient's written consent has been collected and preserved by the author (s).

References:

1. Ackland SP, Bur ME, Adler SS, Robertson M, Baron JMJAjocp. White blood cell aplasia associated with thymoma. 1988;89(2):260-3.
2. Sultan S, Irfan SMJJoAH. Acquired idiopathic pure white cell aplasia: A rare cause of agranulocytosis. 2014;5(4):161.
3. Fumeaux Z, Beris P, Borisch B, Sarasin FP, Roosnek E, Dayer JM, et al. Complete remission of pure white cell aplasia associated with thymoma, autoimmune thyroiditis and type 1 diabetes. 2003;70(3):186-9.
4. Keast T, Weeraman D, Mayhead P, Grace R, Mathe SJFG. Pure white cell aplasia: Report of first case associated with autoimmune hepatitis. 2014;5(4):287-90.
5. Tamura H, Okamoto M, Yamashita T, Sato C, Watanabe A, Kondo A, et al. Pure white cell aplasia: report of the first case associated with primary biliary cirrhosis. 2007;85(2):97-100.
6. Levitt LJ. Chlorpropamide-induced pure white cell aplasia. 1987.
7. Mamus SW, Burton JD, Groat JD, Schulte DA, Lobell M, Zanjani EDJNEJoM. Ibuprofen-associated pure white-cell aplasia. 1986;314(10):624-5.
8. Levitt LJ, Ries CA, Greenberg PLJNEJoM. Pure white-cell aplasia: antibody-mediated autoimmune inhibition of granulopoiesis. 1983;308(19):1141-6.
9. Postiglione K, Ferris R, Jaffe JP, Stroncek DJA Joh. Immune mediated agranulocytosis and anemia associated with thymoma. 1995;49(4):336-40.
10. Karlsson TJUjoms. Secondary haemophagocytic lymphohistiocytosis: experience from the Uppsala University Hospital. 2015;120(4):257-62.