

Case report

Epidermoid cyst discovered during splenectomy: a case report and review of Literature

ABSTRACT :

Epidermoid cysts of the spleen are very rare benign tumors; characterized by a mesothelial invagination made of a stratified squamous epithelial lining of the splenic capsule during embryogenesis, they are primary non-traumatic and non-parasitic cysts, and they are generally of difficult diagnosis but the advent of CT and histology which remains the arsenal of diagnosis of epidermoid cysts of the spleen. We report a case of a young woman aged 25 years, without any notable pathological history presented with intermittent abdominal pain, with a large palpable splenic mass, ultrasound and abdominal CT scan objectified components that did not present the typical appearance of an epidermoid cyst and biology was in favor of a hydatid cyst igg positive. The patient underwent a total open splenectomy, the histopathological examination revealed the presence of a **yellowish white material**^{this is a gross finding} occupying the entire splenic parenchyma with the presence of numerous intracystic membranes, in addition there are surgical procedures opting for conservative treatment in our case we preferred totalization.

Keywords Epidermoid cyst of spleen, Splenic cyst, splenectomy, , Case report

INTRODUCTION :

Splenic cysts are a relatively rare pathology constituting 30% of splenic lesions, they can be primary or secondary, congenital, parasitic, vascular, neoplastic, or post traumatic. Primary cysts are most often congenital lined by a stratified squamous epithelium while secondary cysts are formed by fibrous tissue lacking this epithelial coating. Epidermoid cysts constitute 10% of splenic cysts, are congenital non-encapsulated primary cysts that arise after invagination of endodermal mesothelial cells in the splenic capsule during embryogenesis which will generate metaplasia and lymphatic secretions originating from these epidermoid cysts

Clinical presentation of an epidermoid cyst of the spleen varies, but most often the cyst is asymptomatic and found incidentally during imaging studies. However, in some cases, the cyst may grow large enough to cause symptoms such as abdominal pain, discomfort, or fullness. Rarely, the cyst may become infected, causing fever and abdominal tenderness

CASE REPORT ;

A 25 year old woman with two caesarean sections and a history of contact with dogs, who presented for 1 year with dull abdominal pain in the left hypochondrium with intermittent nausea and vomiting. On clinical examination, a palpable mass was found in the left upper quadrant; The biological workup was positive for hydatidosis and the rest was unremarkable, the abdominal ultrasound visualized a cystic mass in the medial part of the enlarged spleen measuring 10.4x7.1cm, When helical imaging was performed after injection of intravenous contrast medium revealed a large hypodense cystic mass occupying the entire spleen measuring 13x 8.1cm separated by intracystic septum a diagnosis of hydatid cyst of the spleen was suspected given the biology and imaging.

A laparotomy was proposed to the patient and splenectomy was recommended due to the size and location of the cystic tumor, which revealed a cystic lesion replacing the normal splenic tissue [figure 1], Histopathological examination revealed a cystic formation made of a yellowish-white material occupying the entire parenchyma with the presence of numerous intracystic membranes, the wall is made of a stratified squamous epithelium border without atypia, largely ulcerated, and the cyst content is made of a stack of keratinous lamellae [figure 2] .

DISCUSSION

Splenic cysts are rarely found in surgical practice, they are the subject of different classifications found in the literature (according to Fowler, Martin and Morgenstern) (1); splenic neoplasms can be primary or secondary; parasitic and non-parasitic,

Primary or true cysts such as epidermoid and neoplastic cysts (lymphomas, angiosarcomas), and secondary cysts such as pseudo cysts post trauma and infectious cysts including hydatid cysts (2).

Primary cysts or true cysts are congenital cysts, especially epidermoid cysts, whose origin is not yet clear, but it is thought that they arise during embryonic development of the spleen by mesothelial incorporation into the splenic parenchyma, which is accompanied by metaplasia and fluid secretion that varies from serous to purulent (3)

Epidermoid cysts of the spleen are histologically defined by the presence of a stratified squamous epithelial lining **lining**^{repeat} the interior of the cyst, sometimes variable cuboidal mesothelial cells may be present. This lining distinguishes primary cysts from secondary cysts that lack this epithelial lining. (4)

Primary cysts represent only 10% of all splenic cysts, a pathology that affects young subjects and children preferentially (5), with a varied clinical presentation and unspecific symptoms for small cysts, whereas large cysts present with variable abdominal pain and a mass occupying the entire left flank, thrombocytopenia or complications of the rupture or hemorrhage type can be encountered (6);

Radiologically, the distinctions between true cysts and false cysts are generally difficult to make on abdominal ultrasound; true cysts present as solitary fluid cysts with regular contours and an echo-like content with mobile internal echoes, especially declivity. Sometimes they can appear as trabeculae producing the "festoon sign" (7); whereas secondary cysts develop thicker fibrous walls and eggshell calcifications and neighboring cysts, especially on CT, which is the case of a hydatid cyst; and if peripheral calcifications are found on the abdominal CT scan without enhancement, this is more in favor of a posttraumatic cyst.

In addition, the CT sections analyze the content of the cyst, either liquid or fatty, and the presence of septations and internal debris, as well as the location and size of the cyst and the structures adjacent to it. The CT appearance is less specific than the ultrasound appearance.

On magnetic resonance imaging, epidermoid cysts in T1-weighted time are hypo-signal, but increase according to the content of the cyst, and in T2 are hyper-signal; whatever the imaging method, a discontinuity in the cyst wall and the presence of an intraperitoneal effusion must give rise to fears of rupture of the cyst requiring emergency surgery.

CONCLUSION

The diagnosis of an epidermoid cyst of the spleen is usually confirmed by imaging tests. In some cases, a biopsy or surgical removal of the cyst may be necessary to confirm the diagnosis and rule out other possible conditions, such as a malignant tumor or a parasitic infection.

It is important to note that epidermoid cysts of the spleen do not require treatment unless they are causing symptoms or are at risk of rupturing, which can lead to serious complications such as bleeding and infection. In such cases, surgical removal of the cyst may be recommended.

REFERENCES

1. Slaughter DP, Southwick HW, Smejkal W. Field cancerization in oral stratified squamous epithelium: clinical implications of multicentric origin. *Cancer* 1953;6:963-8.
2. Strong MS, Incze J, Vaughan CW. Field cancerization in the aerodigestive tract: its etiology, manifestation, and significance. *J Otolaryngol* 1984;13:1-6.
3. MAAMRIA donnees épidémiologiques sur les cancers dans le monde et du maroc revue bibliographique, annales de sciences de la santé, N°1,20-29,2015^{modify reference}.
4. Chen, Y.-H. *et al.* Treatment Outcomes of Patients with Locally Advanced Synchronous Esophageal and Head/Neck Squamous Cell Carcinoma Receiving Curative Concurrent Chemoradiotherapy. *Sci. Rep.* 7, 41785; doi: 10.1038/srep41785 (2017).^{modify reference}
5. Morita M, Egashira A, Nakaji Y, Kagawa M, Sugiyama M, Yoshida D, et al. Treatment of squamous cell carcinoma of the esophagus synchronously associated with head and neck cancer. *In Vivo* (2017)^{modify reference} 31:909–16. doi:10.21873/invivo.11146
6. Ishimori T, Patel PV, Wahl RL. Detection of unexpected additional primary malignancies with PET/CT. *J Nucl Med* 2005; 46:752-7.
7. Li Q-W, Zhu Y-J, Zhang W-W, Yang H, Liang Y, Hu Y-H, et al. Chemoradiotherapy for synchronous multiple primary cancers with esophageal squamous cell carcinoma: a case-control study. *J Cancer* (2017)^{modify reference} 8:563–9. doi:10.7150/jca.17408
8. Lee JS, Ahn JY, Choi KD, Song HJ, Kim YH, Lee GH, et al. Synchronous second primary cancers in patients with squamous esophageal cancer: clinical features and survival outcome. *Korean J Intern Med* (2016)^{modify reference} 31:253–9. doi:10.3904/kjim.2014.182
9. Shinoto M, Shioyama Y, sasaki T, Nakamura K, ohura H, Higaki Y, Yamaguchi T. Clinical results of definitive chemoradiotherapy for patients with synchronous head and neck squamous cell carcinoma and esophageal cancer ; *Am J Clin Oncol*.2011;362-366.

10. Chen Y, Chang JY, Jeter M, Guerrero T, et al. Esophageal cancer located at the neck and upper thorax treated with concurrent chemoradiation: single-institution experience. *J Thorac Oncol* (2006) ^{modify reference} 1:252–9. Doi:10.1016/S1556-0864(15)31576-8.
11. NIWA Y, KOIKE M. salvage pharyngolaryngectomy .dis esophagus.2016 29 ;598-602.
12. ORDU AD, NIEDER C. Association between radiation dose and pathological complete response after preoperative radiochemotherapy in esophageal squamous cell cancer. *anticancer Res.*2014;34:7255-7261.

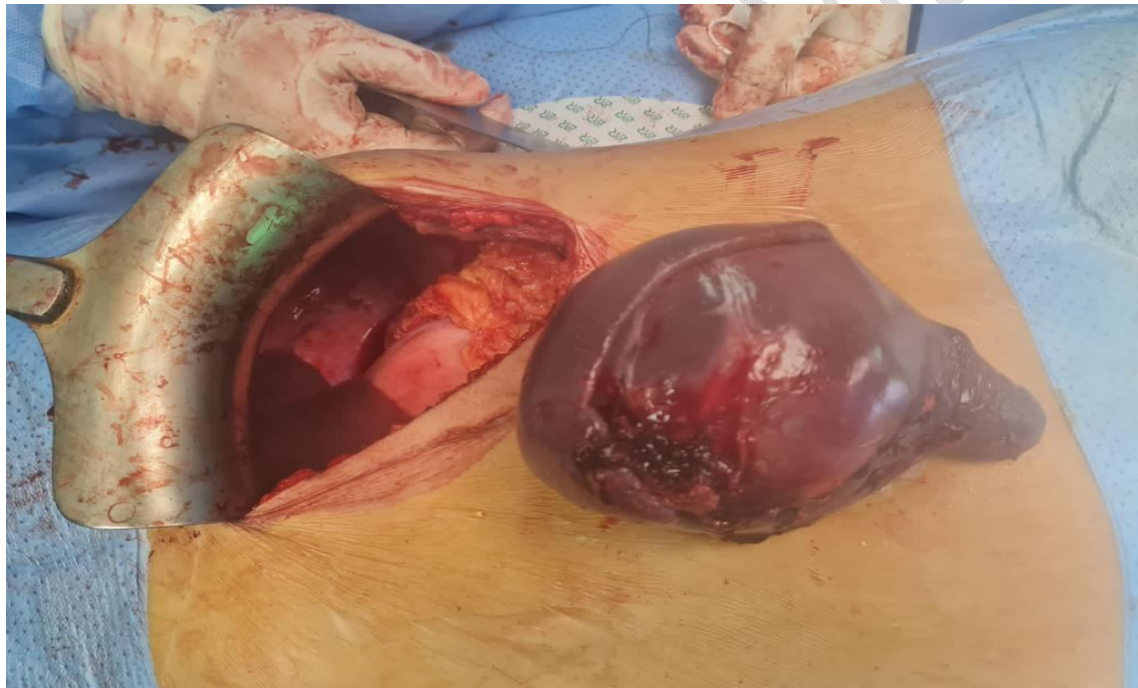

Figure 1 : Total splenectomy. and the cystic lesion has been completely removed.

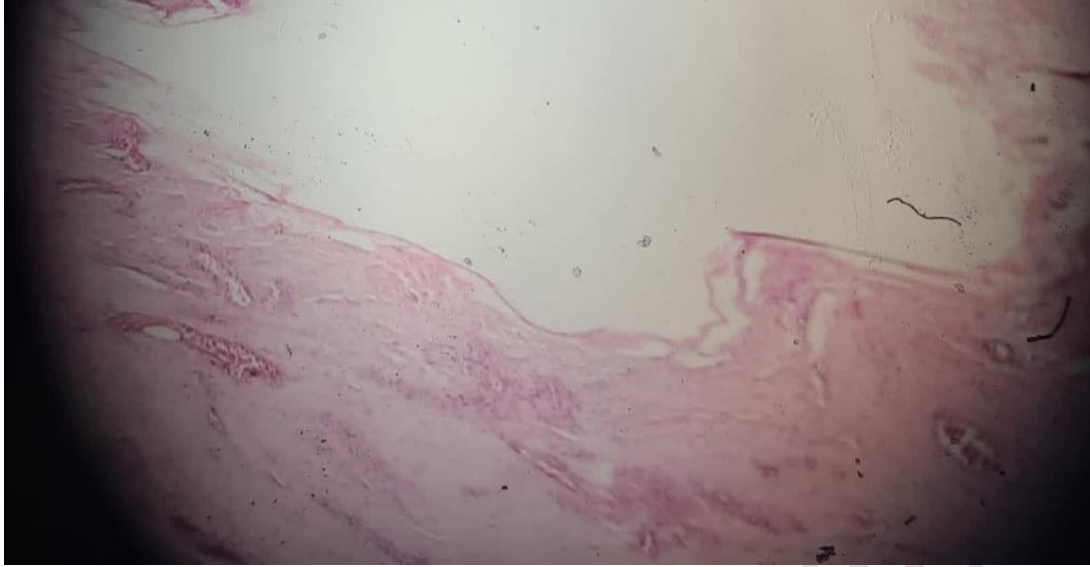


Figure 2: Showing epithelial lining the wall is made of a stratified squamous epithelium border without atypia the cyst content is made of a stack of keratinous lamellae)

UNDER PEER REVIEW