

# Case study

## Acute appendicitis as a complication of severe acute pancreatitis: case report

### Abstract :

Introduction and importance: Pancreatitis is a common condition in the general population. Appendicitis is the most common disease and is the first procedure performed in general and digestive surgery. Complication of acute pancreatitis by acute appendicitis is rare. We present a case of acute appendicitis complicating acute pancreatitis.

Case presentation : A 66-year-old man admitted to the visceral surgical emergency department for epigastralgia and right iliac fossa pain dating back 24 hours. On physical examination, the patient was HD and respiratory stable, afebrile at 36.5°. Epigastric and FID sensitivity, the rest of the examination was unremarkable. CT scan showed a Balthazar stage E acute pancreatitis with acute appendicitis. After hospitalisation and initiation of antibiotic therapy, the patient underwent appendectomy with sampling of the peritoneal effusion.

### Manuscript without author details

Clinical discussion: Complications of the large bowel related to pancreatitis do not exceed 7%, including infarction, infection, and transverse colon and splenic flexure fistula and isolated appendix involvement as no complications of pancreatitis have been reported in the literature.

Conclusion : The dangers of misdiagnosis and persistent symptomatology with conservative treatment in patients with appendicitis and pancreatitis are greater than those inherent in a correctly performed diagnostic laparotomy.

**Keywords** : appendicitis , pancreatitis, pain , surgery.

### Introduction:

Pancreatitis is a common condition in the general population. It is a medical and surgical emergency.

Appendicitis is the most common disease and is the first procedure performed in general and digestive surgery. Complication of acute pancreatitis by acute appendicitis is rare. We present a case of acute appendicitis complicating acute pancreatitis. The aim of this study is to highlight the diagnostic difficulties and to discuss the therapeutic choices in the association of pancreatitis and acute

appendicitis.

### Case presentation

A 66-year-old man, chronic smoker at 40 P/A and chronic alcoholic (2 liters/week) admitted to the visceral surgical emergency department for epigastralgia and right iliac fossa pain dating back 24 hours, associated with food vomiting without transit disorders or externalized digestive hemorrhages, all evolving in a context of apyrexia and alteration of the general state. On physical examination, the patient was HD and respiratory stable, apyretic at 36.5°. Epigastric and **right iliac fossa tenderness**, the rest of the examination was

unremarkable. Laboratory results were as follows: WBC: 19760 per litre (80% neutrophils), haemoglobin: 15.3g /dl platelet count: 375000/ L, Prothrombin rate: 88%, C-reactive protein: 95.6 g/dL, BUN: 0.45 g/l, creatinine: 7.6 mg/l, aspartate aminotransferase: 24U/L, alanine aminotransferase: 14 U / L, total bilirubin: 5,8mg / dL, calcium: 9 mg / dL, , lipase: 472U / L, Gamma-GT:

39UI/L Alkaline phosphatase: 100 UI/L Natremia: 137 meq/L kaleimia: 5 meq/l Abdominal ultrasound was ordered: No visualization of normal or pathological appendix complete with CT scan which revealed: Swollen pancreas measuring 41 mm in its cranial portion, with loss of its physiological lobulations at this level, associated with necrotic flows in the posterior cavity of the epiploons, caudally, in the bilateral renal anterior spaces

- Bilateral peripancreatic and perirenal fat infiltration with thickening of the left renal fascia

- Normal volume **alithiasic gallbladder**

**coiled latero-caecal appendage** measuring 11mm in thickness at most.

peritoneal effusion slide

IN TOTAL: CT appearance of Balthazar stage E acute pancreatitis with acute appendicitis (figure1 (a-b)) (figure2)

After hospitalisation and initiation of antibiotic therapy, the patient underwent appendectomy with sampling of the peritoneal effusion (Figure 3)

Pathological examination showed inflammation of the appendix and analysis of the specimen showed the presence of lipase in the effusion. The postoperative course was simple, with the patient being declared discharged at 10 days postoperatively after cooling of his pancreatitis.

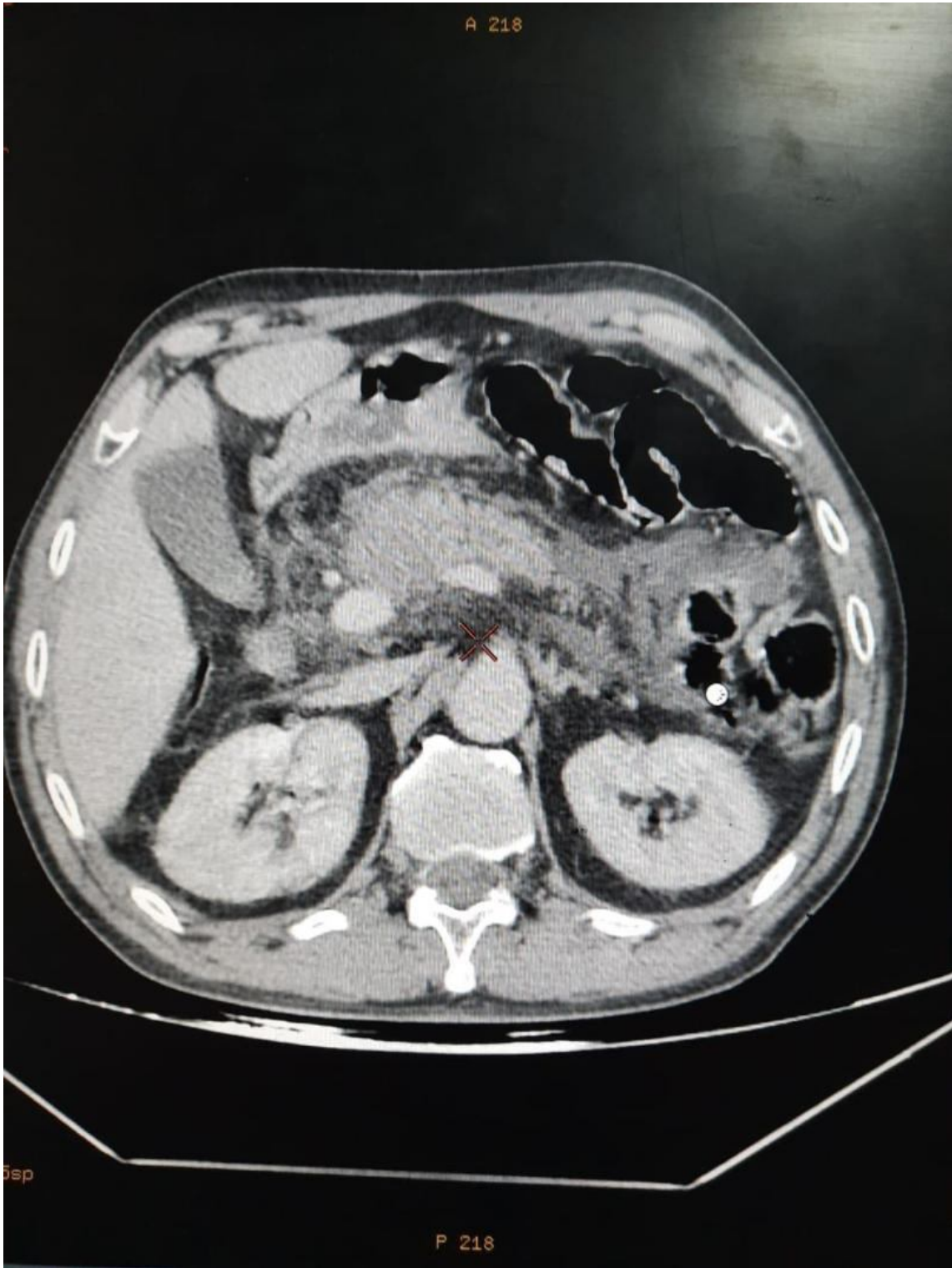


figure 1 (a): appearance of caudal necrosis flows

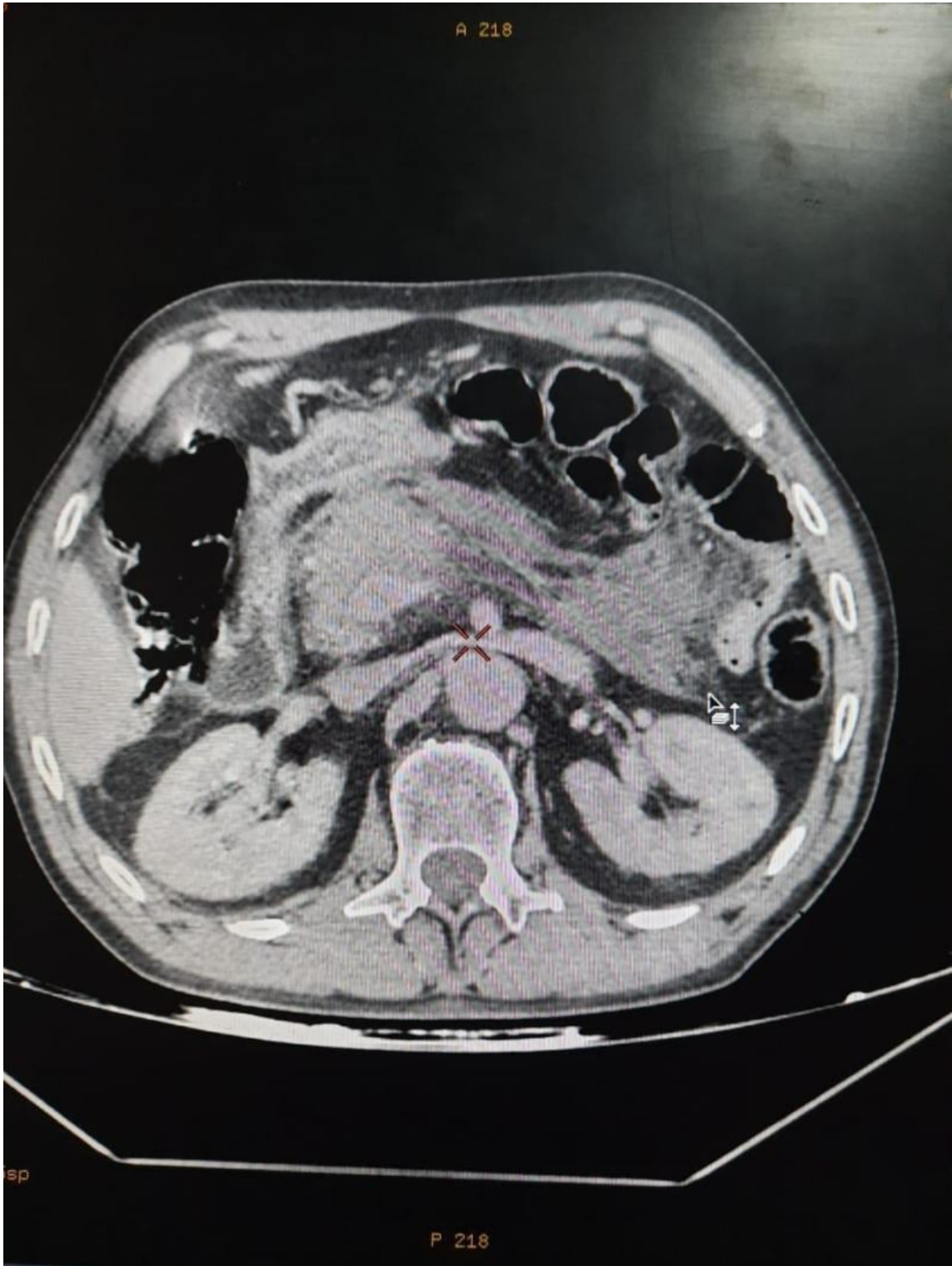


Figure 1(b): appearance of necrotic flows

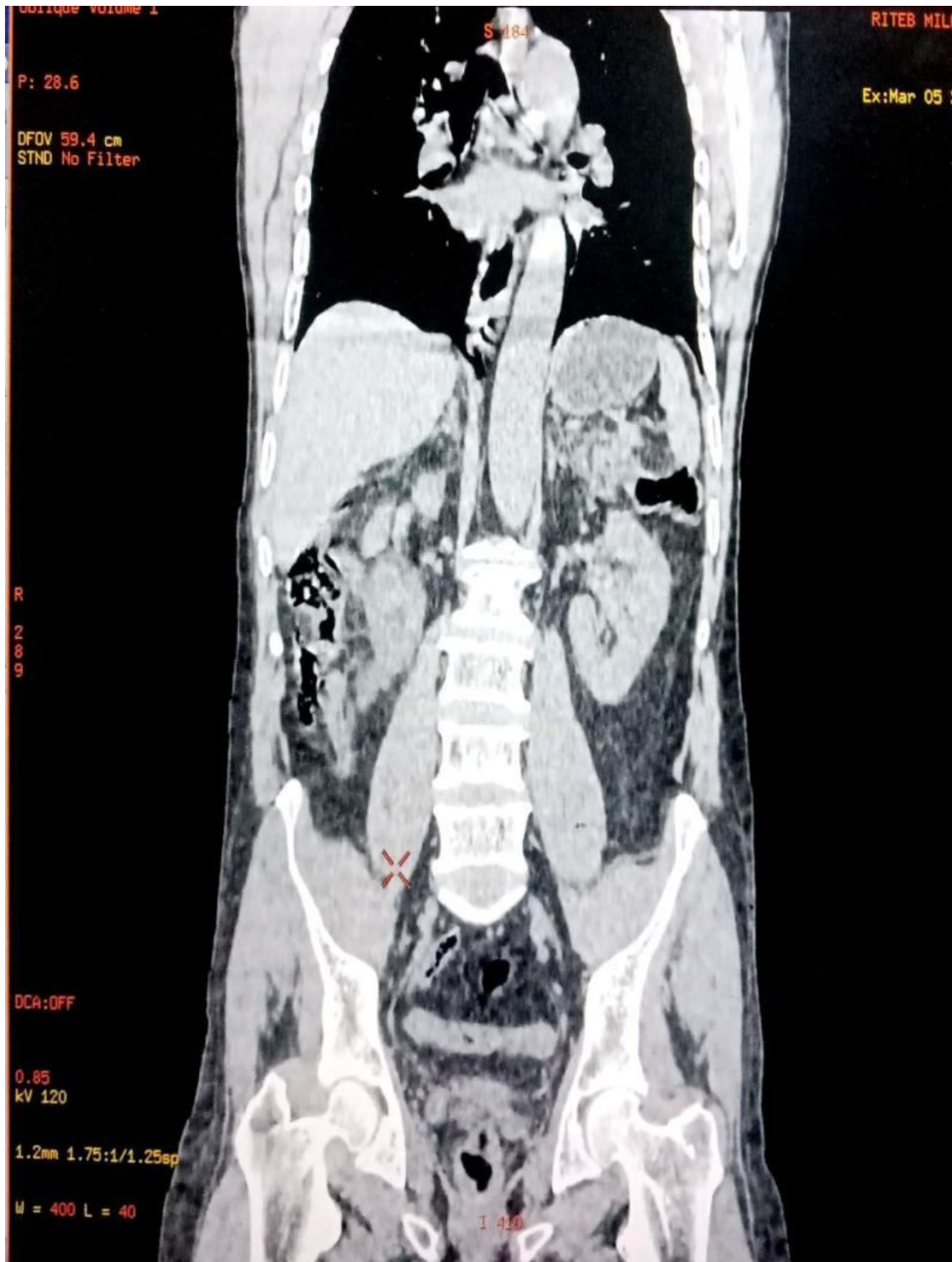
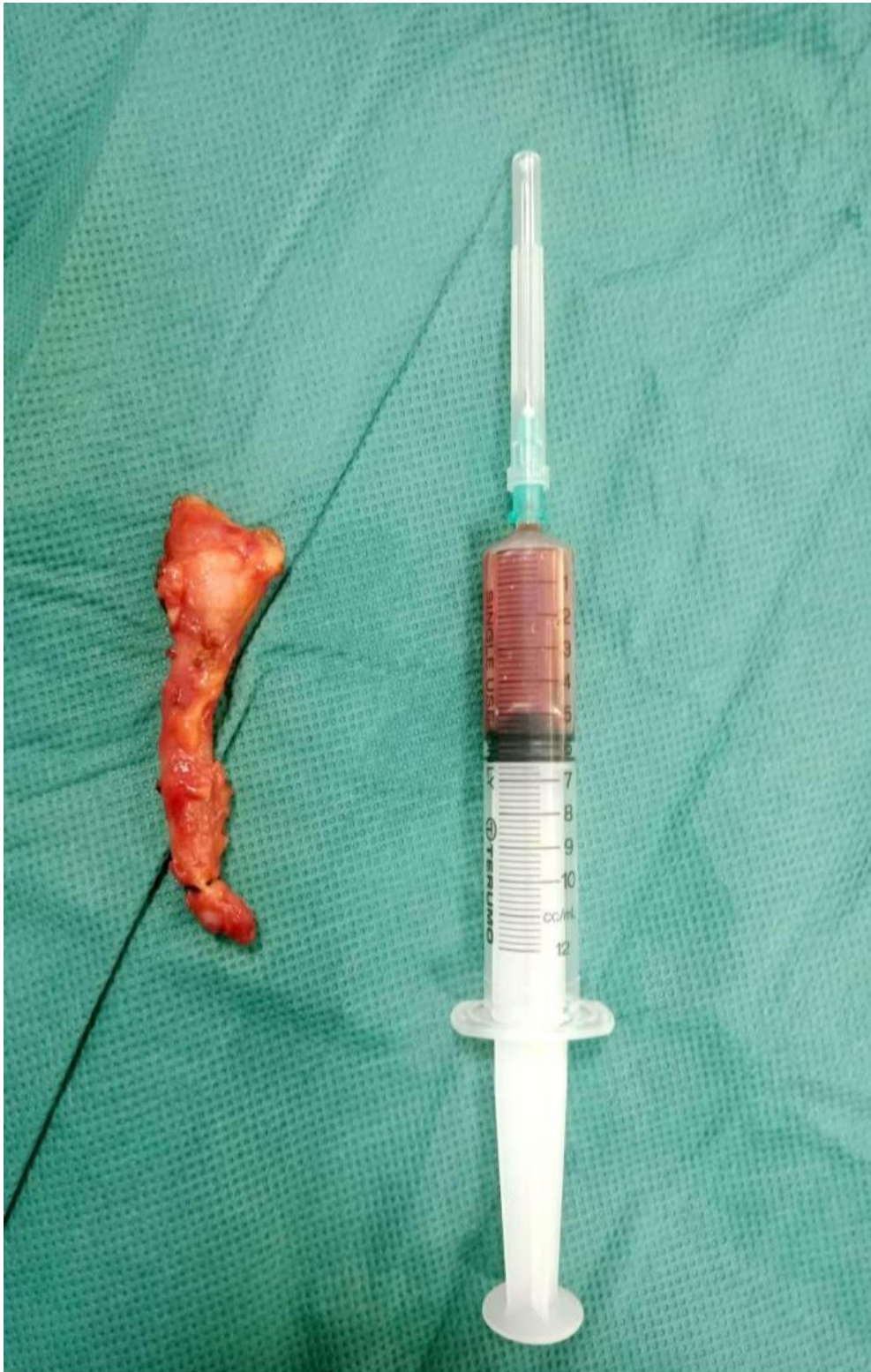
Figure2 : swollen appendix image



Scanné avec CamScanner

Figure 3 : image of the appendix intraoperatively and of the effusion

## **Discussion:**

The diagnosis of pancreatitis is based not only on a typical history and physical examination but also on a lipasemia and amylasemia greater than 3 times normal(1) .

serum amylase is also elevated in other cases of abdominal pain, such as appendicitis (1), perforated duodenal ulcer, or small bowel ischaemia (2) Serum amylase is usually within the first 48 hours after the onset of pancreatitis [(3)].

However, radiological investigations may be requested, including abdominal CT scan to assess the severity of pancreatitis as it is more specific than ultrasound in appendicitis ((4)) (5).

Complications of the large bowel related to pancreatitis do not exceed 7%, including infarction, infection, and transverse colon and splenic flexure fistula and isolated appendix involvement as no complications of pancreatitis have been reported in the literature ((6)).

In rare cases, there is a likelihood that appendicitis is a rare complication of mild pancreatitis ((7)).

Endoscopic treatment of retrograde appendicitis (ERAT) may be a new alternative to surgery for treating patients with severe disease or comorbidities such as acute pancreatitis (AP) associated with appendicitis((8))ERAT is a safe, minimally invasive endoscopic procedure with advantages over surgery for patients with appendicitis and severe pancreatitis.

- When the diagnosis does not provide sufficiently firm criteria on which to base the choice of treatment, surgery is indicated as the best approach in the patient with acute abdomen (9) as in our series Our patient underwent appendectomy and received antibiotic treatment in addition to supportive care for acute pancreatitis

## **Conclusion**

The dangers of misdiagnosis and persistent symptomatology with conservative treatment in patients with appendicitis and pancreatitis are greater than those inherent in a correctly performed diagnostic laparotomy.

In our study an appendectomy by laparotomy was performed with good patient outcome.

## **Consent**

As per international standard or university standard, patient(s) written consent has been collected and preserved by the author(s).

## **Ethical Approval:**

As per international standard or university standard written ethical approval has been collected and preserved by the author(s).

## Références :

1. Heckler M, Hackert T, Hu K, Halloran CM, Büchler MW, Neoptolemos JP. Severe acute pancreatitis: surgical indications and treatment. *Langenbecks Arch Surg.* mai 2021;406(3):521-35.
2. Nozari N. Appendicitis AS a Complication of Acute Pancreatitis; A Case Report. 2016;4.
3. Amylase and gut infarction | *British Journal of Surgery* | Oxford Academic [Internet]. [cité 19 nov 2021]. Disponible sur: <https://academic.oup.com/bjs/articleabstract/73/3/219/6181983?redirectedFrom=fulltext>
4. Láinez Ramos-Bossini AJ, Pérez García MDC, Rivera Izquierdo M. A rare association: acute pancreatitis caused by the influenzavirus A with secondary appendicitis in a six-year-old girl. *Rev Espanola Enfermedades Dig Organo Of Soc Espanola Patol Dig.* févr 2020;112(2):157.
5. Tschuor C, Raptis DA, Limani P, Bächler T, Oberkofler CE, Breitenstein S, et al. The value of pancreatic stone protein in predicting acute appendicitis in patients presenting at the emergency department with abdominal pain. *BMC Gastroenterol.* 25 oct 2012;12:154.
6. Hsia HC, Shoung LK, Chen ML, Wong DW. Acute pancreatitis complicated with periappendicitis. *Zhonghua Yi Xue Za Zhi Chin Med J Free China Ed.* déc 2002;65(12):619-21.
7. Forster MJ. Perforated appendicitis masquerading as acute pancreatitis in a morbidly obese patient. *World J Gastroenterol.* 2008;14(11):1795.
8. Du ZQ, Ding WJ, Wang F, Zhou XR, Chen TM. Endoscopic treatment for acute appendicitis with coexistent acute pancreatitis: Two case reports. *World J Clin Cases.* 6 janv 2021;9(1):245-51.
9. Thapnell JE, Anderson MC. Role of Early Laparotomy in Acute Pancreatitis: *Ann Surg.* janv 1967;165(1):49-55.