

Original Research Article

Ameliorating Potentials of Lemon Zest on Pons Neurons in Cannabis Sativa-Induced Wistar Rat

ABSTRACT

Cannabis sativa, commonly known as marijuana has been indicated for many body organ malfunctions. It is a common plant ingested or taken by many person-people or individuals for body enhancement. The purpose of this study, therefore, is to determine the effects of lemon zest on the pons of cannabis sativa induced wistar-Wistar rats. On a specific basis, the study determined the effects of lemon zest on the cytoarchitecture of pons of *cannabis sativa* non-induced wistar rat, determined the effects of a low dose of lemon zest on the histology of pons of *cannabis sativa* induced wistar rat, and examined the impacts of lemon zest on the histology of pons of *cannabis sativa* induced wistar rat. The plant was collected from National Drug Law Enforcement Agency (NDLEA), Rivers State, Nigeria, and 40 healthy w-Wistar Wistar rats were used for the experiment. The rats were divided into five (5) groups. Group 1 served as control, groups 2,3,4 and 5 served as 250mg/kg lemon zest only, 750mg/kg *cannabis sativa* only, 500mg/kg *cannabis sativa*+ 250mg/kg lemon zest, and 900mg/kg *cannabis sativa* +250mg/kg lemon zest respectively. The plant extract was administered for a period of 21 days, and thereafter, the organs were harvested for routine histological tissue processing. Findings from the study thus revealed that when 500mgkg⁻¹ of *cannabis sativa* was used to induce the pons, observation showed neuronal hypertrophy and degenerated degeneration with mobilization of several supporting cells. The connective tissue indicated an edematous appearance. It was also observed that when a low dosage (500mgkg⁻¹) of the *cannabis sativa* was administered alongside 250mgkg⁻¹ extract of lemon zest, well delineated neuronal cells with well-defined nucleus-nuclei and nucleolus were observed in the tissue. When the dosage of the *cannabis sativa* was increased to 900mgkg⁻¹ alongside 250mgkg⁻¹ extract of lemon zest, pockets of edematous connective tissues and blood vessel congestion wereas still noticeable in the tissue. There was a general recovery (proliferation) of lost cells in groups 4 and 5 respectively, as a consequence of the administration of lemon zest with extract (*cannabis sativa*) on wistar rats. The improved tissue and cellular appearance is an indication of the potency of lemon zest in the amelioration of adverse tissue effects introduced by the extract of *cannabis sativa*.

Keywords: Cannabis sativa, Pons, Lemon Zest

INTRODUCTION

In the health of individuals and communities, medicinal plants and fruits have several vital roles. The medicinal values of these plants and fruits are possible due to the numerous chemical substances contained in them which include phenolic compounds, oleoresins, resins, sesquiterpene, flavonoids, saponins glycosides, alkaloids, fats, and oils, which on the body produce physiological action (Dhanavade *et al.*, 2011). Over a long time period, naturally occurring constituents are used which has the abundant potential for yielding new drugs, and the constituents contain a biologically active substance that demonstrates the biological activity for human health. The naturally occurring antimicrobial substance has the greater significant values and got more importance in plant chemotherapy and these substances are found in plants and fruits such as lemon (Kadhimi *et al.*, 2013).

Cannabis sativa, commonly termed as marijuana, weed, pot, and ganja, is one of the earliest known cultivated plants. Its cultivation started since with the birth of agricultural farming started around 10,000 years ago (Tajammul, *et al.*, 2021). It is a multi-purpose crop plant with diverse agricultural and industrial applications which range from the production of paper, wood, and fibre to pharmaceutical uses in industries. Tajammul, *et al.* (2021), claimed that the first prospect of cannabis sativa as a medical plant was published in 1843 where its use was described for treating patients suffering from tetanus, hydrophobia, and cholera. Consequently, the plant was removed from the medicinal category and recategorized exclusively to the category of drug-type plants.

Lemon zest contains high amounts of nutrients and provides a wider range of health benefits when consumed as juice (Bouzenna, *et al.* 2016). Mainly, the cultivation of lemon is done for the alkaloids which possess the anticancer activities and the antibacterial activities in crude lemon parts (such as flowers, roots, stems, and leaves) extract and alkaloids also exhibit

clinically noteworthy in bacterial strains. The notable part of lemon peel is the lemon zest. Lemon zest is the outermost layer of the lemon peel known as the flavedo and contains loads of natural oils that are used for various purposes including an influence ~~in~~on the nervous system as well as influence on Cannabis Sativa (Melanie, 2021).

~~The aim of this study was~~ study aimed to determine the effects of lemon zest on the pons of cannabis sativa induced wistar rats.

MATERIALS AND METHODS

UNDER PEER REVIEW

Experimental Design: This study will adopt the Completely Randomized Design (CRD). This involves two principles which are the principles of replication and the principle of randomization of experimental design.

Collection and Accumulation of Cannabis Sativa: Dried leaves, twigs, and seeds of [the](#) cannabis sativa plant ~~was~~ ~~were~~ obtained from the ~~national~~ [National](#) Drug Law Enforcement Agency (NDLEA), Rivers State command, Nigeria. The characterization and validation of the plant will be done by evidence specialists at NDLEA, Rivers State Command in Port Harcourt.

Animal Collection and Acclimatization: Forty (40) ~~wistar~~ [Wistar](#) rats of both sexes were used in this study. The rats were obtained from the animal house in the Faculty of Basic Medical Sciences, University of Port Harcourt, and kept in clean cages under standard laboratory conditions of 12 hours light/dark cycle. They had access to vital pellet feed and distilled water as they were allowed to acclimatize for one week. The rats were allowed to roam in an enclosed space having proper ventilation and temperature throughout ~~the period of~~ the experiment. All the rats were allowed to feed *ad libitum* for 14 days after which different behavioral tests will be conducted.

Experimental Procedure: The 40 ~~wistar~~-Wistar rats with an average weight of 110g were randomly divided into 5 groups (8 rats each). A low dose and high dose of 250mg/kg and 900mg/kg respectively and a normal dose of 750mg/kg of aqueous marijuana were used according to research conducted by Danladi, *et al.* (2013) to induce the rat. The dosage of lemon zest used includes 250mgkg⁻¹ in accordance with following the findings of Olarewaju *et al.*, (2020).

Group 1: Control group- This group was given animal feed and distilled water only with no dose of lemon zest or marijuana.

Group 2: Low dose group- This group was served with a low dose (250g) of lemon zest only and no dose of marijuana.

Group 3: Marijuana Induced group: This group was administered a 500mg/kg dose of Marijuana and no dose of lemon zest.

Group 4: This group was induced with 500mgkg⁻¹ of marijuana and treated with a low dose (250mgkg⁻¹) of lemon zest.

Group 5: This group was served with a high dose (900g) of marijuana but with a low dose (250mgkg⁻¹) of lemon zest Lemon.

Tissue Harvesting: The harvesting of tissues was done ~~in order~~ to extract the organ of choice from the rat which is the pons. The rats were first made unconscious by being exposed to chloroform. While unconscious, the rats were then pinned to a wooden board ~~in order~~ to keep them still during dissection. The brains were harvested from their skull and the harvested parts were fixed in Bonin solution

RESULTS

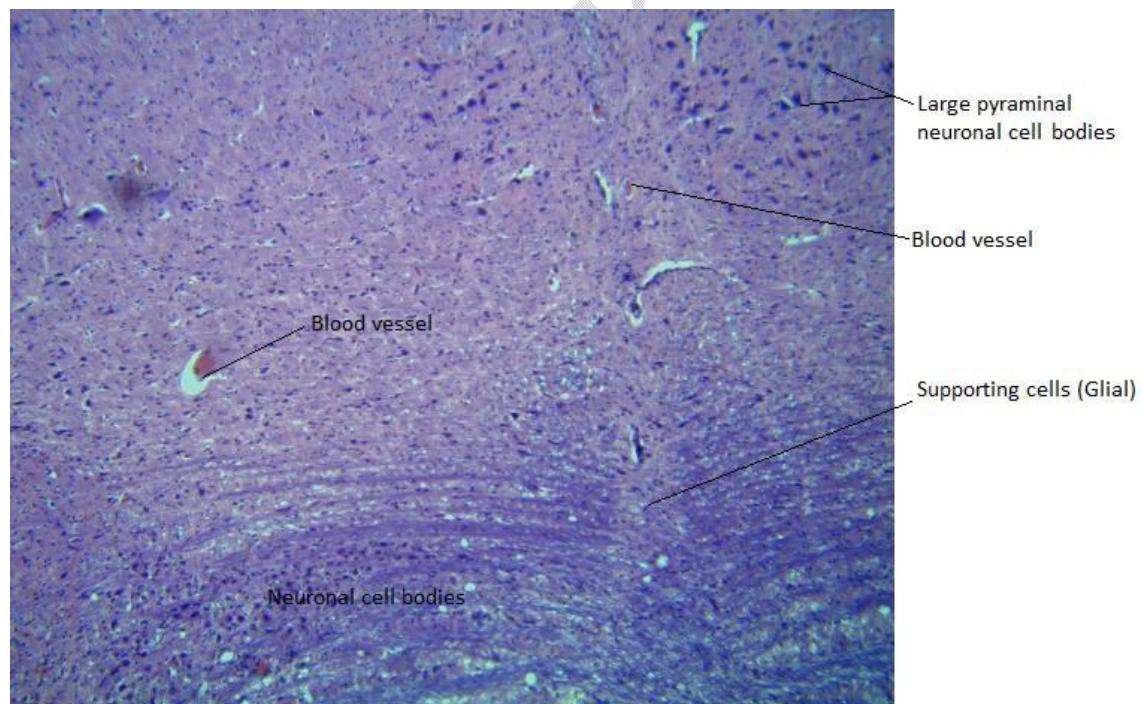


Plate 1: Normal Control showing large pyramidal neuronal cell bodies

The plate 1 above shows the photomicrograph of the pons used for the control experiment at lower magnification showing large pyramidal neuronal cell bodies at the anteromedial area of the pons. Medium size neuronal cell bodies are arranged at the posterior medial area of the pons. Tissue shows normal cytoarchitecture. H & E, X100.

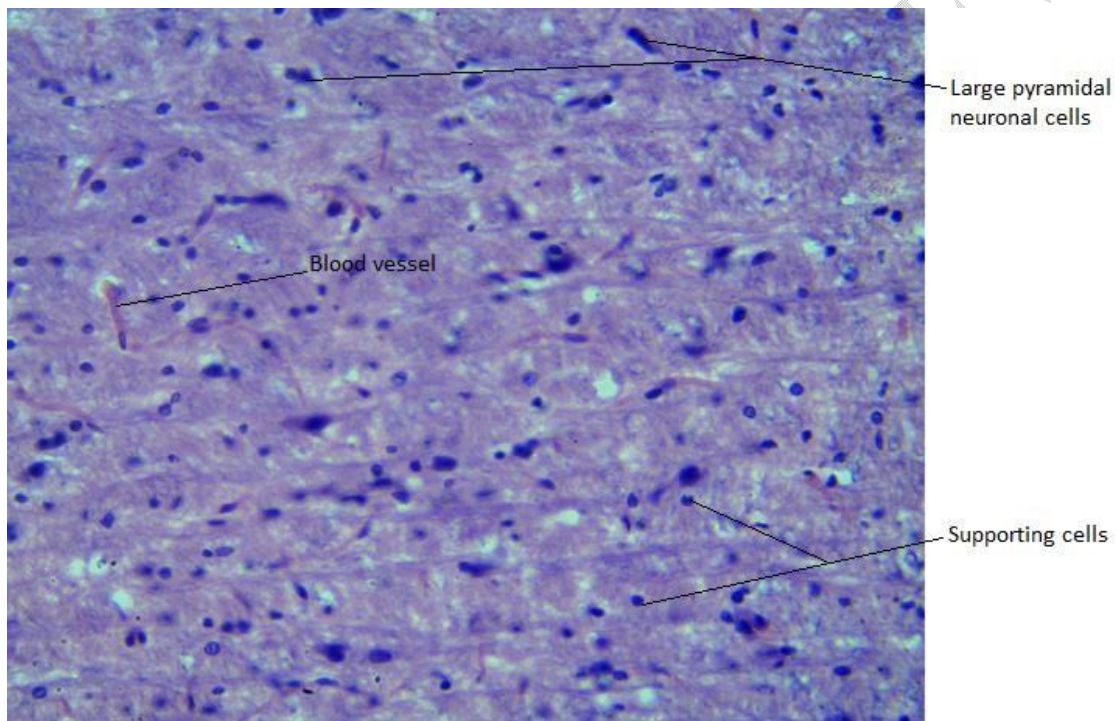


Plate 2: Normal Control showing delineated neuronal and supporting cells

Plate 2 above displays the photomicrograph of the pons showing well delineated neuronal cell bodies and few supporting cells (glial). The connective tissue ~~fibres~~ fibers are well distributed. H & E, X400

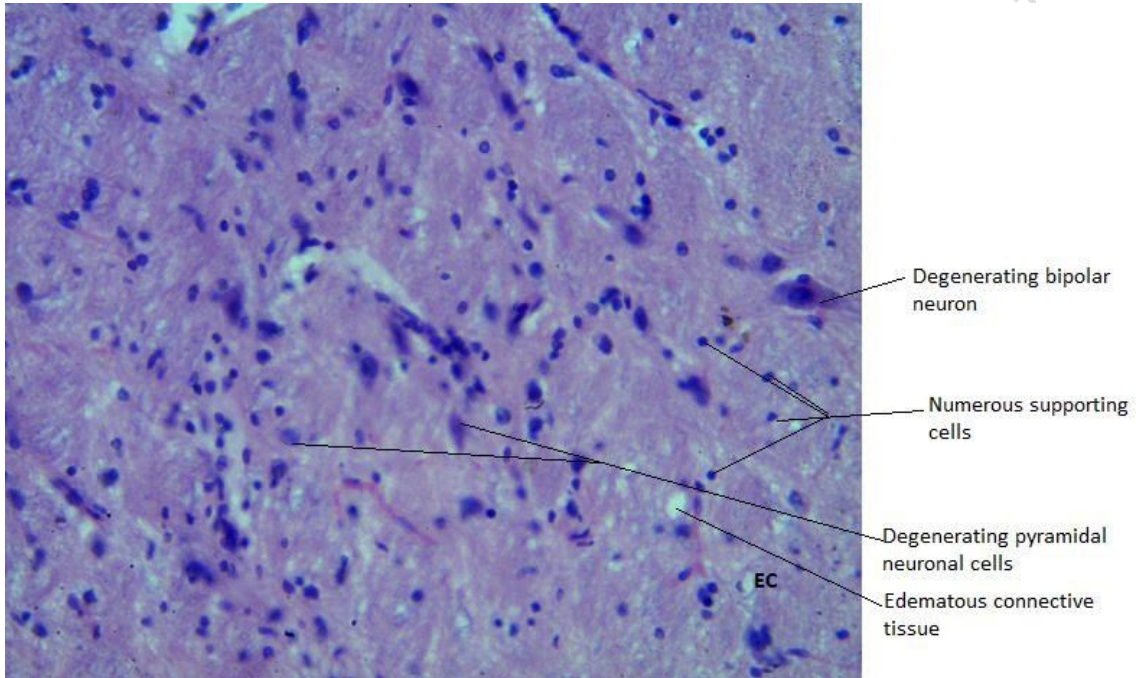


Plate 3: Pons of the ~~Wistar-Wistar~~ rats after 250mgkg⁻¹ of lemon zest induction

The plate 3 above shows the photomicrograph of the pons on a few degenerating neuronal cell bodies and numerous supporting cells (glial) after 250mgkg⁻¹ of lemon zest was administered. Pockets of edematous connective tissue cells are observed. Pons tissue shows mild distortion. H & E, X400.

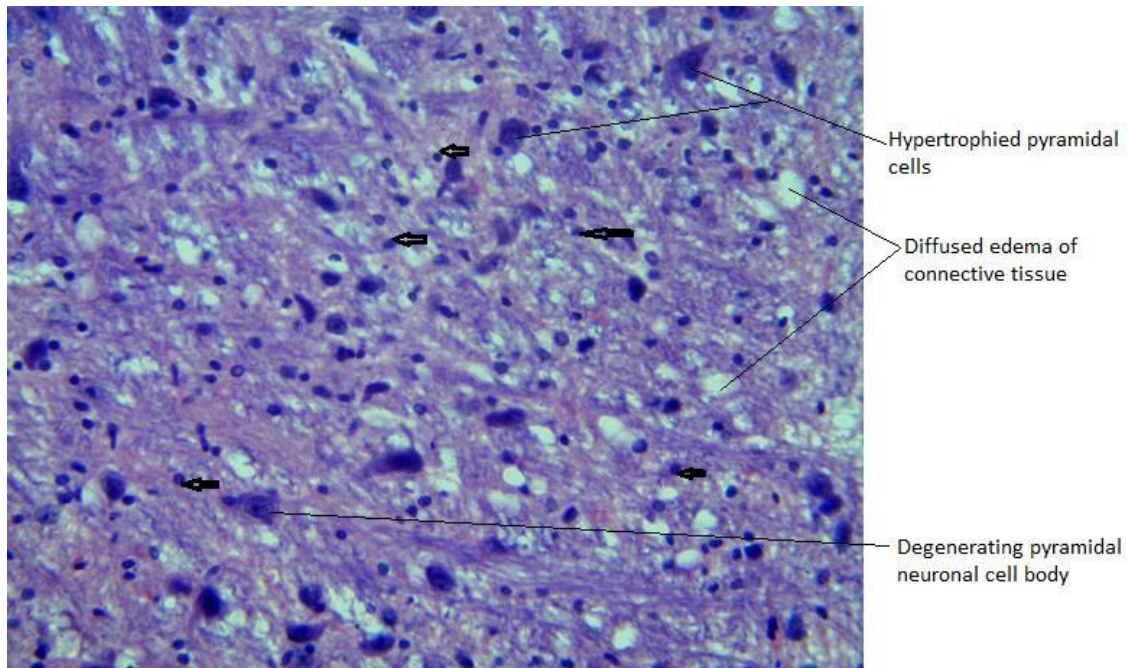


Plate 4: Pon State after the medium dose of *Cannabis Sativa* (500mgkg^{-1}) induction only

Plate 4 above is the photomicrograph of the pons showing several hypertrophied and degenerating neuronal cell bodies alongside numerous supporting cells (glial-arrowed) when a low dose of 250mgkg^{-1} of cannabis sativa was administered to the rat. Diffused edematous connective tissue cells are observed. Pons shows the severe distortion of tissue cytoarchitecture. H & E, X400.

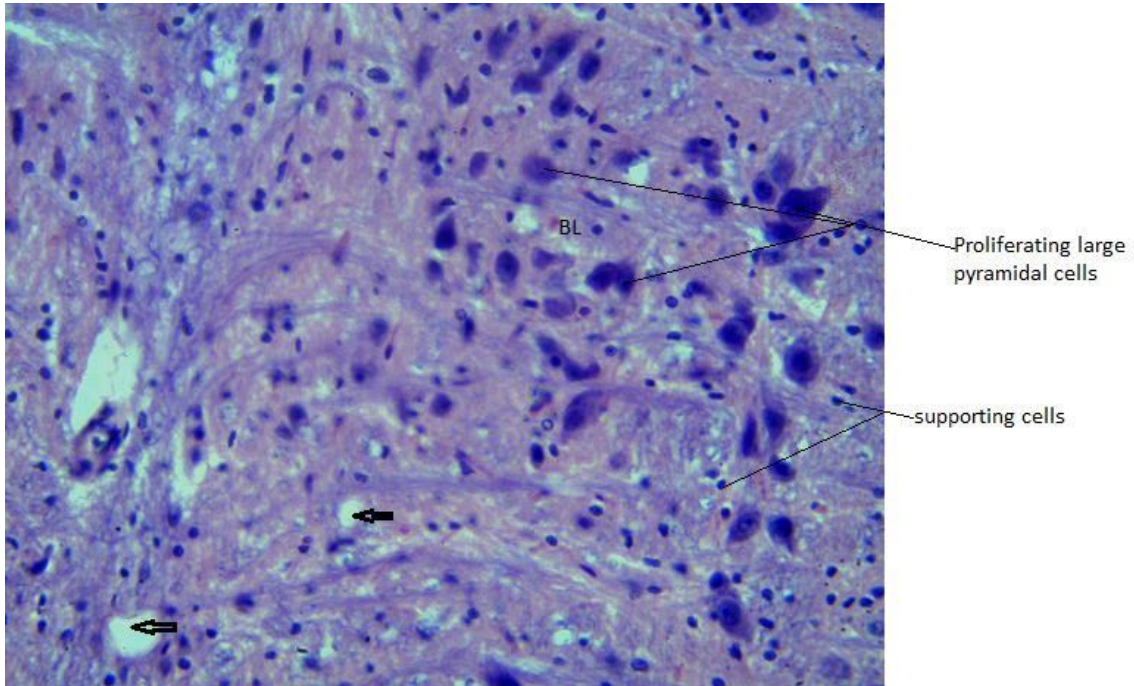


Plate 5:Low dose of *Cannabis Sativa* (250mgkg⁻¹) and a low dose of lemon zest(250mgkg¹) application

The plate 5 above displays the photomicrograph of the pons showing the proliferation of pyramidal neuronal cell bodies with pockets of supporting cells (glial). Pockets of edematous (vacuolation) connective tissue cells (arrowed) and the presence of congested blood vessels are also observed. Pons shows a recovery state of tissue cytoarchitecture. H & E, X400.

Effects of Lemon Zest on the Histology of Pons of High Dose Cannabis Sativa

Induced Wistar Rat

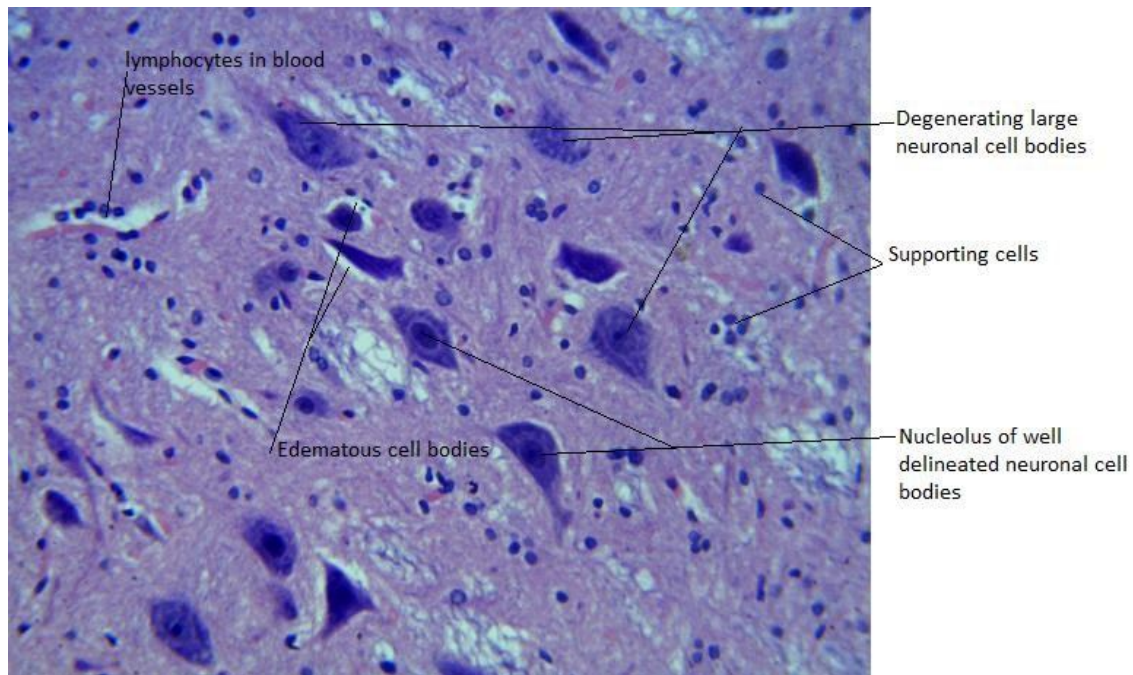


Plate 6: High dose of *Cannabis Sativa* (900mgkg^{-1}) and a low dose of lemon zest (250mgkg^{-1}) application

Plate 6 above displays the photomicrograph of the pons showing proliferation and degenerating pyramidal neuronal cell bodies with pockets of supporting cells (glial). Some well delineated neuronal cell bodies with clear nucleolus are outlined in the tissue. The presence of congested blood vessels containing lymphocytic cells is also observed. Pons shows a recovery state of tissue cytoarchitecture. H & E, X400.

Discussion

This study aims at determining the effects of lemon zest on the pons of cannabis sativa induced wistar rats. The study thus determined the effects of lemon zest on the cytoarchitecture of pons of cannabis sativa non-induced wistar rat, determined the effects of a low dose of lemon zest on the histology of pons of cannabis sativa induced wistar rat, and examined the impacts of high dosage of lemon zest on histology pons of cannabis sativa induced wistar rat.

Results in this study displayed the photomicrograph of the pons before marijuana and/or lemon zest was/were administered. Findings thus revealed that when 250mgkg^{-1} of lemon zest was administered, pons showed few degenerating neuronal cell bodies as well as numerous supporting cells (glial) as against the normal control which displayed well delineated neuronal cell bodies and few supporting cells since the connecting tissues were properly distributed. When 500mgkg^{-1} of *cannabis sativa* was used to induce the pons, it was observed that the neurons of the pons were hypertrophied and degenerated and with several supporting cells with edematous collective tissue cells being observed, in tandem with the findings of Muktar *et al.* (2011), and Tijani *et al.* (2014), who opined that histological differences occur during the administration of *cannabis sativa* on neuronal cells, leading to perinuclear spaces and vacuolations. It was also observed that when a low dosage (250mgkg^{-1}) of the *cannabis sativa* was administered alongside a low dose of lemon zest, congested blood are observed as well as pockets of edematous connective tissues. When the dosage of the *cannabis sativa* was increased to 900mgkg^{-1} , some well delineated neuronal cells with well-defined nucleolus were outlined in the tissue as once observed in the control experiment. There is also the presence of congested blood vessels carrying lymphatic cells and thus recoveries of tissue cytoarchitecture were observed.

Hence this means that the histological areas of the Photomicrograph of pons treated with lemon zest showed improvement in the degenerating neuronal cell bodies previously noted in the study. This also correlated with the findings of Neshatdoust *et al.* (2016), who opined that citrus zest results ~~to~~ in an increase in Brain Derived Neurotropic Factor (BDNF). This means that lemon zest has neuroprotective effects in individuals since the wistar rat brain is similar to that of the humans, although the citrus zest in this study was specifically done with oranges, not a lemon.

The study has demonstrated the negative effect of cannabis sativa on the neuronal cells of the pons upon administration of different doses of the extract, as demonstrated in animals group 3. However, this effect was reversed upon administration of lemon zest as the demonstration in groups 4 and 5. It is therefore important to note that lemons zest has neuroprotective qualities or the potential to ameliorate adverse effects caused by the extract of cannabis sativa.

REFERENCES

- Abad-García, B., Garmón-Lobato, S., Berrueta, L.A. Gallo, B.; Vicente, F (2012) On line characterization of 58 phenolic compounds in Citrus fruit juices from Spanish cultivars by high-performance liquid chromatography with photodiode-array detection coupled to electrospray ionization triple quadrupole mass spectrometry. *Talanta*, 99, 213–224.
- Aboelhadid, S.M., Mahrous, L.N., Hashem, S. A., Abdel-Kafy, E. M., Miller, R. J (2016). In vitro and in vivo effect of Citrus limon essential oil against sarcoptic mange in rabbits. *Parasitol. Res.* 115, 3013–3020.
- Alhoi, H. H., Eddy, F. I., Nyoman, E. L (2018). Antimicrobial Activity of Lemon (Citrus limon) Peel Extract Against *Escherichia coli*. *American Scientific Research Journal for Engineering, Technology, and Sciences (ASRJETS)*, 39 (1): pp 268-273.
- Amorim, J. L., Simas, D. L., Pinheiro, M. M., Moreno, D. S., Alviano, C. S., Da-Silva, A. J., & Fernandes, P. D. (2016). Anti-inflammatory properties and chemical characterization of the essential oils of four Citrus species, 11 (1): 1–18.
- Anwar, R., Naseer, M. I., Bhangar, S., Ashraf, F. N. & Aladedunye F. A (2008). “Physico-chemical characteristics of citrus seeds and seed oils from Pakistan,” *JAOCS, J. Am. Oil Chem. Soc.*, vol. 85, no. 4, pp. 321–330.

- Arathi, R. & Gulia, K.K (2018). Categories of Wistar Rats based on Anxiety Traits: A Study Using Factor and Cluster Method. *Journal of Neuroscience*:234-240.
- Asai, T.; Matsukawa, T.; Kajiyama, S. (2016). Metabolic changes in Citrus leaf volatiles in response to environmental stress. *J. Biosci. Bioeng.* 121, 235–241.
- Balogun, F. O. Ashafa, A.O (2019). A review of plants used in South African Traditional Medicine for the management and treatment of hypertension. *Planta Med.* 2019, 85, 312–334.
- Bhatia, H., Pal-Sharma, Y., Manhas, R.K., Kumar, K (2015). Traditional phyto-remedies for the treatment of menstrual disorders in district Udhampur, J&K, India. *J. Ethnopharmacol.* 160, 202–210.
- Bouzenna, (2016). “The protective effect of Citrus limon essential oil on hepatotoxicity and nephrotoxicity induced by aspirin in rats,” *Biomed. Pharmacother.*, vol. 83, pp. 1327–1334.
- Brodal, P (2014). Pons <https://www.sciencedirect.com/topics/veterinary-science-and-veterinary-medicine/pons> (accessed 31 Jan 2022).
- Carvalho, A., Hansen, E. H., Kayser, O., Carlsen, S., & Stehle, F (2017). Designing microorganisms for heterologous biosynthesis of cannabinoids. *FEMS Yeast Res.* 17. <https://doi.org/10.1093/femsyr/fox037>.
- Cho, H. J. (2012). “Short Vegetative Phase (SVP) protein negatively regulates miR172 transcription via direct binding to the pri-miR172a promoter in Arabidopsis,” *FEBS Lett.*, vol. 586, no. 16, pp. 2332–2337.
- Citrus Page (2019). Available online: <http://citruspages.free.fr> (accessed on 28 August 2019).
- Clement, Y.N., Baksh-Comeau, Y.S., Seaforth, C.E. (2015). An ethnobotanical survey of medicinal plants in Trinidad. *J. Ethnobiol. Ethnomed.* 11, 1–28.
- Cosmetic Ingredient Database (2019). Available online: https://ec.europa.eu/growth/sectors/cosmetics/cosing_en (accessed on 1 September 2019).
- Czech, A., Zarycka, E., Yanovych, D., Zasadna, Z., Grzegorzczak, I., Kłys, S. (2019). Mineral content of the pulp and peel of various Citrus fruit cultivars. *Biol. Trace Elem. Res.*
- Dhanavade, J. & Ghosh S., (2011). Study Antimicrobial Activity of Lemon (Citrus lemon L.) Peel Extract. *British Journal of Pharmacology and Toxicology* 2(3): 119-122.
- European Directorate for the Quality of Medicines (2017). European Pharmacopoeia 9.2, Lemon Oil; European Directorate for the Quality of Medicines: Strasburg, Germany.
- European Food Safety Authority (EFSA). (2019) Available online: <http://www.efsa.europa.eu/> (accessed on 3 September 2019).

- Flores-Sanchez, I. J., & Verpoorte, R. (2008). Secondary metabolism in cannabis. *Phytochem. Rev.* 7, 615–639. <https://doi.org/10.1007/s11101008-9094-4>.
- Fongzossie, E. F., Tize, Z., Fogang-Nde, P. J., Nyangono, C.F., Bouelet, I.S., Dibong, S.D., Nkongmeneck, B.A. (2017). Ethnobotany and pharmacognostic perspective of plant species used as traditional cosmetics and cosmeceuticals among the Gbaya ethnic group in Eastern Cameroon. *S. Afr. J. Bot.*: 112, 29–39.
- German Commission E, Phytotherapy (2019). Available online: <https://buecher.heilpflanzenwelt.de/BGA-Commission-E-Monographs/0043.htm> (accessed on 1 September 2019).
- Goetz, P. (2014). Citrus limon (L.) Burm. f. (Rutacées). Citronnier. *Phytotherapie* 2014, 12, 116–121.
- Gould, J. (2015). The cannabis crop. *Nature* 525, S2–S3. <https://doi.org/10.1038/525S2a>.
- Gualdani, R., Cavalluzzi, M.M., Lentini, G., & Habtemariam, S., (2016). The chemistry and pharmacology of citrus limonoids. *Molecules*, 21, 1530.
- Guerrini, A., Rossi, D., Grandini, A., Scalvenzi, L., Rivera, P.F., Andreotti, E., Tacchini, M., Spagnoletti, A., Poppi, I., & Maietti, S. (2014). Biological and chemo-diverse characterization of Amazonian (Ecuador) *Citrus petitgrains*. *J. Appl. Bot. Food Qual.*, 87, 108–116.
- Hemayatkhah, M., Farajmand, S., Azhdari, S., Ghaedi, M., Farzam, & Kargar, J. H. (2013). “Effect of Hydroalcoholic Extract of Citrus Aurantifolia Peel on Serum Level of Testosterone , Fsh , Lh And Testis Tissue In Adult Male Rats,” *Int. J. Biol. Pharm. Allied Sci.*, vol. 2, no. 6, pp. 1307–1315.
- Hu, J.; Li, X. (2015). Inhibitory effect of lemon essential oil on mushroom tyrosinase activity in vitro. *Mod. Food Sci. Technol.* 31, 97–105.
- Huang, S., Liu, X., Xiong, B., Qiu, X., Sun, G., Wang, X., Zhang, X., Dong, Z., Wang, Z. (2019) Variation in limonin and nomilin content in citrus fruits of eight varieties determined by modified HPLC. *Food Sci. Biotechnol.* 28, 641–647.
- Ige, A. O., Olaoye, M. O., Oluwole, D. T., Ayeni, G. T., Adewoye, E. O (2021). Route of exposure influences the cardiovascular effects of Cannabis sativa in salt-induced hypertensive male Wistar rats. *Journal of African Association of Physiological Sciences*, 9 (2): 74-88.
- Imam, A., Ajao, M. S., Amin, A., Abdulmajeed, W. I., Ibrahim, A., Olajide, O. J., Ajibola, M. I., Alli-Oluwafuyi, A., Balogun, W. G (2016). Cannabis-induced Moto-Cognitive Dysfunction in Wistar Rats: Ameliorative Efficacy of Nigella Sativa. *Malays J Med Sci.* 23 (5): 17-28.
- Jafari, A., E., Mohammadiaghdam, B & Hassanzade, Z. (2013). “Effects of antibacterial activities methanol of extract and lemon grass essence on pathogenic bacteria,” *World Appl. Sci. J.*, 28 (11): pp. 1796–1801.

- Jing, L.; Lei, Z.; Zhang, G.; Pilon, A.C.; Huhman, D.V.; Xie, R.; Xi, W.; Zhou, Z.; Sumner, L.W. (2015). Metabolite profiles of essential oils in citrus peels and their taxonomic implications. *Metabolomics*: 11, 952–963.
- Kanmani, P. (2014). Extraction and analysis of pectin from Citrus peels: Augmenting the yield from Citrus limon using statistical experimental design. *Iran. J. energy Environ*: 5, 303–312.
- Kaskoos, R.A. (2019). Essential oil analysis by GC-MS and analgesic activity of *Lippia citriodora* and Citrus limon. *Journal of Essential Oil-Bear Plants*, 22, 273–281.
- Kato, Y., Domoto, T., Hiramitsu, M., Katagiri, T., Sato, K., Miyake, Y., Aoi, S., Ishihara, K., Ikeda, H., Umei, N (2014). Effect on blood pressure of daily lemon ingestion and walking. *Journal of Nutritional Metabolism*.
- Kaya, M., Sousa, A.G., Crépeau, M. J., Sørensen, S. O., & Ralet, M. C (2014). Characterization of citrus pectin samples extracted under different conditions: Influence of acid type and pH of extraction. *Ann. Bot.*, 114, 1319–1326.
- Khan, R. A.; Riaz, A (2015). Behavioral effects of Citrus limon in rats. *Metab. Brain Dis.*, 30, 589–596.
- Kim, M. J., Hwang, J. H., Ko, H. J., Na, H. B., Kim, J. H. (2015). Lemon detox diet reduced body fat, insulin resistance, and serum hs-CRP level without hematological changes in overweight Korean women. *Nutr. Res*: 35, 409–420.
- Kimira, Y., Taniuchi, Y., Nakatani, S., Sekiguchi, Y., Kim, H. J., Shimizu, J., Ebata, M., Wada, M., Matsumoto, A., & Mano, H. (2015). Citrus limonoid nomilin inhibits osteoclastogenesis in vitro by suppression of NFATc1 and MAPK signaling pathways. *Phytomedicine*: 22, 1120–1124.
- Kumar, A., Premoli, M., Aria, F., Bonini, S.A., Maccarinelli, G., Gianoncelli, A., Memo, M., & Mastinu, A. (2019). Cannabimimetic plants: are they new cannabinoidergic modulators? *Planta*. <https://doi.org/10.1007/s00425-019-03138-x>.
- Lamine, M., Gargouri, M., Rahali, F. Z., Mliki, A (2019). Authentication of Citrus fruits through a comprehensive fatty acid profiling and health lipid indices: A nutraceutical perspectives. *J. Food Meas. Charact*: 13, 2211–2217.
- Ledesma-Escobar, C.A.; Priego-Capote, F.; Luque De Castro, M.. (2015). Characterization of lemon (*Citrus limon*) polar extract by liquid chromatography-tandem mass spectrometry in high resolution mode. *J. Mass Spectrom*: 50, 1196–1205.
- Mahmoud, M.F.; Gamal, S.; El-Fayoumi, H.M. (2014). Limonin attenuates hepatocellular injury following liver ischemia and reperfusion in rats via toll-like receptor dependent pathway. *Eur. J. Pharmacol*. 740, 676–682.
- Manconi, M.; Manca, M.L.; Marongiu, F.; Caddeo, C.; Castangia, I.; Petretto, G.L.; Pintore, G.; Sarais, G.; D'Hallewin, G.; & Zaru, M.; (2016). Chemical characterization of

- Citrus limon var. pompia and incorporation in phospholipid vesicles for skin delivery. *Int. J. Pharm.* 506, 449–457.
- Marta, K., Agnieszka, S., & Halina, E. (2020). Citrus limon (Lemon) Phenomenon—A Review of the Chemistry, Pharmacological Properties, Applications in the Modern Pharmaceutical, Food, and Cosmetics Industries, and Biotechnological Studies. *Plants*: 9: 119.
- Masson, J.; Liberto, E.; Beolor, J.C.; Brevard, H.; Bicchi, C.; & Rubiolo, P. (2016). Oxygenated heterocyclic compounds to differentiate Citrus spp. essential oils through metabolomic strategies. *Food Chem*: 206, 223–233.
- Mehl, F.; Marti, G.; Boccard, J.; Debrus, B.; Merle, P.; Delort, E.; Baroux, L.; Raymo, V.; Velazco, M.I.; Sommer, H. (2014). Differentiation of lemon essential oil based on volatile and non-volatile fractions with various analytical techniques: A metabolomic approach. *Food Chem.*, 143, 325–335.
- Merve, D. K. & Oguz, B (2018). Valorization of Citrus Peel Waste. *Journal of Natural Volatiles and Essential oils*; 5(2): 10-18.
- Millet, F. (2014) Huiles essentielles et essence de citronnier (Citrus limon (L.) Burm. f.). *Phytotherapie*: 12, 89–97.
- Ministry of Health and Family Welfare (2017). Citrus limon (Linn) Burm. f. In *The Ayurvedic Pharmacopoeia of India (IV)*; Ministry of Health and Family Welfare, Government of India: New Delhi, India.
- Olaniyan, A.M. (2010). “Development of a small scale orange juice extractor,” *J. Food Sci. Technol.*, vol. 47, no. 1, pp. 105–108.
- Otang, W. M., Afolayan, A.J (2016). Antimicrobial and antioxidant efficacy of Citrus limon L. peel extracts used for skin diseases by Xhosa tribe of Amathole District, Eastern Cape, South Africa. *S. Afr. J. Bot.*, 102, 46–49.
- Owolabi, M. S.; Avoseh, O. N.; Ogunwande, I.A.; William, N.; Ogungbo, R.; Ogundajo, A.L.; Lawal, O.A.; & Flamini, G. (2018). Chemical composition of Citrus limon (L.) Osbeck growing in Southwestern Nigeria: Essential oil chemotypes of both peel and leaf of lemon. *Am. J. Essent. Oils Nat. Prod.* 6, 36–40.
- Parhiz, H.; Roohbakhsh, A.; Soltani, F.; Rezaee, R.; & Iranshahi, M. (2015). Antioxidant and anti-inflammatory properties of the citrus flavonoids hesperidin and hesperetin: An updated review of their molecular mechanisms and experimental models. *Phyther. Res.* 29, 323–331.
- Radwan, M.M., Wanas, A.S., Chandra, S., & ElSohly, M.A. (2017). Natural Cannabinoids of cannabis and methods of analysis. In *Cannabis Sativa L. - Botany and Biotechnology*, S. Chandra, H. Lata, and M.A. ElSohly, eds. (Springer International Publishing), pp. 163–182. https://doi.org/10.1007/978-3-319-54564-6_7.

- Raimondo, S.; Naselli, F.; Fontana, S.; Monteleone, F.; Lo Dico, A.; Saieva, L.; Zito, G.; Flugy, A.; Manno, M.; & Di Bella, M.A (2015). Citrus limon-derived nanovesicles inhibit cancer cell proliferation and suppress CML xenograft growth by inducing TRAIL-mediated cell death. *Oncotarget* 6, 19514–19527.
- Riaz, A.; Khan, R.A.; Mirza, T.; Mustansir, T.; & Ahmed, M. (2014). In vitro/in vivo effect of Citrus limon (L. Burm. f.) juice on blood parameters, coagulation and anticoagulation factors in rabbits. *Pak. Journal of Pharmaceutical Science*, 27, 907–915.
- Ríos, J.J.; Roca, M.; & Pérez-Gálvez, A. (2015). Systematic HPLC/ESI-high resolution-qTOF-MS methodology for metabolomic studies in nonfluorescent chlorophyll catabolites pathway. *J. Anal. Methods Chem*: 1–10.
- Rosaria, C., Billy, F., Francesco, M., Mario P., & Mark T.H. (2020). Technical and Economic Feasibility of a Stable Yellow Natural Colorant Production from Waste Lemon Peel. *Applied Sciences*, 10 (1): 6812.
- Ruiz, B., & Flotats, X. (2014). Citrus Essential Oils and their influence on the Anaerobic Digestion Process: An Overview. *Waste Management Journal*, 34: 2063-2079.
- Russo, M.; Bonaccorsi, I.; Costa, R.; Trozzi, A.; Dugo, P.; & Mondello, L. (2015). Reduced time HPLC analyses for fast quality control of citrus essential oils. *J. Essent. Oil Res.*, 27, 307–315.
- Shafeeqa I, Muhammad, M. A., Shahid, M., Shafeeqa, I., Muhammad, A. N, Wajiha, S. & Muhammad, Q. A.Muhammad (2019). Lemon Peel: A Natural Medicine. *International Journal of Biotechnology and Allied Field*. 7(10): 185-194.
- U. S. Food & Drug Administration. Available online: <https://www.fda.gov/> (accessed on 3 September 2019).
- Zachariah, R, Adebisi S. S, Uduak E. U., Adamu A. S., & Adamu, P. P. (2020). Effect of n-butanol extract of Cannabis sativa L. extract on the cerebral cortex of adult Wistar rats. *African Journal of Cellular Pathology*:12 (2) pp. 6-15.
- Zaid, A.N.; Jaradat, N.A.; Eid, A.M.; Al Zabadi, H.; Alkaiyat, A.; & Darwish, S.A. (2017). Ethnopharmacological survey of home remedies used for treatment of hair and scalp and their methods of preparation in the West Bank-Palestine. *BMC Complement. Altern. Med.* 17, 1–15.