

ORIGINAL RESEARCH ARTICLE

PHOTOGRAMMETRIC EVALUATION OF PROXIMAL FEMORAL MORPHOMETRIC PARAMETERS OF SOUTHERN NIGERIANS.

ABSTRACT

Background: Understanding the dimensions of the structural configuration of human skeleton is requisite in anthropologic and forensic anatomy, radiologic anatomy and orthopaedics. **Aim:** This study presents a new method of using photogrammetry to obtain and analyse data of the morphometric parameters of the neck, proximal shaft (intertrochanteric or epiphyses area) of the proximal aspect of the cadaveric femur. **Methodology:** A total of 127 dry human femur bones studied and analysed critically using photogrammetry. The following parameters were calculated for each femur: femoral neck shaft angle (FNSA), femoral neck intertrochanteric angle (FNIA), femoral shaft intertrochanteric angle (FSIA), and the area of femoral intertrochanteric triangle (FIT_{AREA}). **Result:** The mean gotten for measured parameters are FNSA=132.91, FNIA=96.50, FSIA=35.93, FIT_{AREA}= 59.38mm². Statistical analysis of the obtained data showed no significant (p<0.01) differences in all measured parameters between right and left sides. **From the outcome of this study, highly significant (p<0.01) positive correlation between FNSA and FSIA, and FSIA and FNIA was observed.** **Conclusion:** We conclude that dynamic and robust understanding of the geometry and strength of the proximal end of the *os femora* requires parameters that conform to anatomical facts between the head, neck and proximal shaft of the *os femora*. This advocate how useful the FNIA and FSIA would be when used together with the FNSA in prognosis and managing proximal femoral fractures as it defines the geometric relation between the neck, intertrochanteric area (proximal epiphysal area) and the shaft of femur. FIT_{AREA} which depicts the strength of the femoral epiphysal or intertrochanteric area would also be useful in this regard. We recommend the possible use of the parameters measured in this study to improve prediction and management of proximal femoral fractures as they better elucidate an understanding of the morphology and strength of the proximal extremity of the *os femora*.

Keywords: Photogrammetry, Femoral Neck Intertrochanteric Angle (FNIA), Femoral Shaft Intertrochanteric Angle (FSIA), Area of Femoral Intertrochanteric Triangle (FIT_{AREA}).

INTRODUCTION

Skeletal development is influenced by a number of factors producing differences in skeletal proportions between different geographical areas. Thus, it is desirable to have some means of specified quantitative variations to differentiate which traits are

being exhibited. This is what anthropometry constitutes [1].

Anthropometric skeletal measurements and the shape of bones can offer a guide to clinicians for the determination of risk factors for fractures. Fractures are an

important health burden as regards disability, death, and medical costs [2] [3].

Meanwhile, Hip fractures are common in elderly patients, and it is an important cause for disability, a current problem in public health, in a population that progressively grows older. The causes are multifactorial, but the major contributing factor is the reduction in the resistance of the proximal epiphysis of the femur, due mainly to osteoporosis, both primary and secondary [4].

As a region prone and inclined to fracture and many childhood and adult disorders, several of which might be related to differences in proximal femoral morphometry or whose therapy might require or entail a thorough understanding of its anatomy, numerous scientific research targeting the definition and measurement of its structural parametric landmarks have been developed [5].

These attempts yielded two renowned parametric landmarks, Femoral Neck-Shaft Angle and neck version. Neck-shaft angle is considered one of the most commonly measured indicators of hip anatomy [6]. A multi-national analysis of 8271 femora found that human neck-shaft angles varied from 120° to 140° , with a mean of 126.4° [7]. A recent study showed a mean value of 131.3° [8]. These values are subject to a wide range of discrepancies, as it was demonstrated that age varies inversely with the angle [9].

Despite the fact that the neck-shaft relationship of the *os femora* has been metrically assessed by several researchers for over a century, analytic and decisive appraisal of the neck head relationship is still relatively at infancy [10]. Besides,

numerous controversies are extant in literatures among established proximal morphometric parametric landmarks (HAL, FNAL, FNVA, FNW) of the *os femora* in their ability to predict and manage proximal femoral fractures as these measures are not conforming with anatomical facts of the head-neck-shaft relationship of the proximal *os femora* but consider only relationship between femoral neck and diaphysis and see the head as a mere extension. [11]

For this reason, present-day scientific investigators have introduced and quantified new morphometric parameters in an attempt to improving the understanding of the morphology and biomechanics of the proximal extremity of the *os femora* and defined its neck-head relationship. These parametric landmarks are listed in the work of Gasper and Crnkovic [11].

However, Gasper and Crnkovic [11] recommended that further research should include head, neck and proximal shaft (epiphysis) relationship that will be compatible with anatomical facts. This echoes the works of Toogood *et al.* [10], Dacleere *et al.* [12], Pasen and Gefen [13], and Faulker *et al.* [14]. These researchers have shown that the femoral trabecular bone provides the biomechanical strength of the proximal femur [12] [13]. Hence, Faulkner *et al.* [14], Menezes *et al.* [15], Bob-Manuel *et al.* [5], Tokpınar *et al.* [16], Tumusiime *et al.* [17], Gupta *et al.* [18], and Skaria *et al.* [19] introduced and measured parameters to meet this need.

Thus, Bob-Manuel *et al.* [5] in their study introduced and measured the Femoral Neck Intertrochanteric Angle (FNIA), Femoral Shaft Intertrochanteric Angle (FSIA), and the area of the Femoral Intertrochanteric

Triangle (FIT_{AREA}). They showed the right and left mean values of FNIA, FSIA and FIT_{AREA} for males as 93.86° , 39.29° , & 11.92mm^2 and 94.30° , 40.00° & 12.03mm^2 respectively. Besides, the stated right and left mean values of FNIA, FSIA and FIT_{AREA} for females as 92.87° , 40.26° , & 11.32mm^2 and 93.87° , 39.21° & 10.53mm^2 respectively.

Several researchers have directly measured dry femur bone [15, 16, 17, 18, 19] while others [5, 20, 21, 22] employed the use of radiograph in assessing the morphometry of *os femora* as it is important to the design and develop orthopaedic implants and prosthesis of the proximal portion of the femur; and for prognosis and management of proximal femoral fractures [20,21], hence in this study photogrammetry like Toogood *et al.* [10] was employed which has not really been explored in the study of proximal morphometric parameters of the *os femora* that will conform to the biomechanical and anatomical features of the head, neck, proximal intertrochanteric or epiphyseal area and shaft of the femur.

This study aimed at accessing the angular morphometric parameters of the proximal end of the femur that will conform to the biomechanical and anatomical features of the head, neck, proximal intertrochanteric or epiphyseal area and shaft of the femur. This included noting the osteometric characteristics of the proximal femur for Nigerians while promoting the discussion for designing and developing standard domestic implants and prostheses peculiar to Nigerians.

MATERIALS AND METHOD

This scientific investigation was a non-experimental, analytic study, investigating

the photogrammetry of the proximal portion of the femur bone. The study population consisted of standard anteroposterior photographs of the normal proximal end of the *os femora* of adult Nigerians obtained from the Department of Anatomy in University of Port-Harcourt, Choba and Madonna University, Elele in Rivers State, Nigeria.

Convenient sampling technique was done (i.e., only available femur bones in the archives were photographed and measured). One hundred and twenty-seven (127) normal anteroposterior standard photographs of the proximal portion of femur were used for this study. Samples included for photographic assessment were only femurs with no visible deformity or disease. Femurs showing incomplete proximal end of *os femora*, incomplete ossification, deformed or diseased, reported abnormal and bio data not indicating Nigerian origin were excluded in this study.

Data Collection and Instrumentation

The biophysical data collection protocol was adopted for photogrammetric study of the proximal femur of selected Nigerians.

Instruments used include; camera, graded graph sheet, smooth horizontal laboratory table, pencil, and goniometer were used for this photogrammetric study of the proximal *os femora*.

To collect data for this photogrammetric investigation of the proximal *os femora*, three (3) main steps were adopted.

Step 1: Selection of normal adult femur

Using the inclusion and exclusion criteria, one hundred and twenty-seven (127) normal *os femora* were selected from the Anatomy

Museum of Department of Anatomy of two 2 chosen universities (mentioned above).

Step 2: Photography of the proximal portion of the femur

Each of the specimens was digitally photographed in a standardized position, termed anteroposterior (AP).

For the AP photographs:

- I. Each femur was first placed in a supine position on graded (each box representing 1cm) graph sheet on a flat laboratory bench with anterior surfaces directed toward the ceiling. In this position, specimens rested distally on the convex surfaces of the medial and lateral condyles and proximally on the greater trochanter.
- II. The femoral neck then was made parallel to the superior surface of the laboratory bench by either rotating the femoral shaft internally and supporting the lateral condyle if the neck axis was anteverted or rotating the femoral shaft externally and supporting the medial condyle if the neck axis was retroverted. Parallelism between the femoral neck and laboratory bench was determined through visual inspection.
- III. The investigator taking the photographs (PAT) used square cards, approximately 1mm in thickness, to increasingly support the medial or lateral condyle until the axis appeared parallel to the laboratory bench surface.
- IV. By taking a photograph from directly overhead (camera lens parallel to the laboratory bench and femoral neck axis as confirmed by a level), we

obtained accurate AP pictures; any potential distortion resulting from neck version was eliminated by making all components of the setup parallel.

Step 3: Photographic Measurement of the Morphometric parameters of the proximal extremity of the femur.

The angular morphometric landmarks of the proximal *os femora* (right and left sides) were measured from standard anteroposterior (AP) photographs of the femur.

To measure each parameter (metric landmark or canon): the photographs were placed on the flat laboratory bench; parameters or metric landmark traced using pencil and measured using a 30cm rule in centimetres (cm), number of boxes counted and value calculated using goniometers in degrees (°) for angular metric landmarks.

The definition of measurements of the angular landmarks or parameters studied was taken as described by Bob-Manuel *et al.* [5], Toogood *et al.* [10] Bob-Manuel *et al.* [22].

The angular morphometric parameters or landmarks of the proximal end or portion of the *os femora* measured are femoral neck shaft angle (FNSA), femoral neck intertrochanteric angle (FNIA) and femoral shaft intertrochanteric angle (FSIA) and the sides of femoral intertrochanteric.

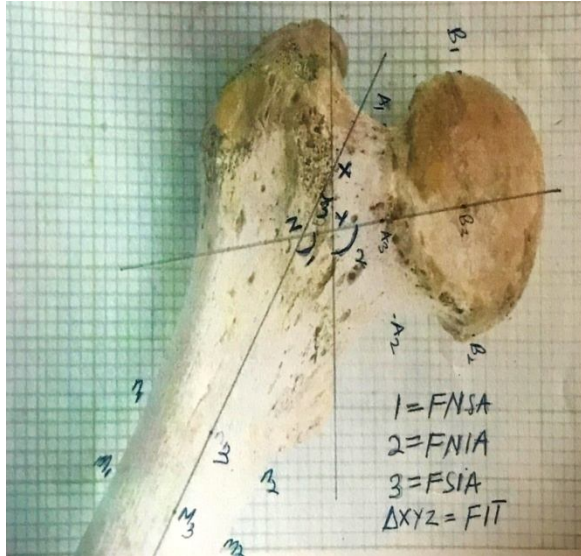


Fig 1: Diaphragm showing angular morphometric parameters of the proximal end of *os femora*.

MORPHOMETRIC ANGLES OF THE PROXIMAL EXTREMITY OF THE OS FEMORA

Femoral Neck-Shaft Angle(FNSA)

The femoral neck-shaft angle formed at the intersection of the femoral shaft axis and the femoral neck axis lines. The femoral shaft axis line was drawn through the midpoint of the body (shaft) of the *os femora* just below the minor trochanter and the midpoint of its distal end while the femoral neck axis line was drawn through midpoints of the narrowest part of the femoral neck and head of the *os femora*. The goniometer was then placed on the lines at their intersection. The red lines on the two arms of the goniometer were then made to align with the femoral neck axis and femoral shaft axis lines and the angle between the redlines was measured (See angle labelled “1” in Fig 1).

Femoral Neck Intertrochanteric Angle (FNIA)

This is the angle formed at the junction of the axis of the neck of the *os femora* and the intertrochanteric axis. The intertrochanteric axis is a line passing through superior margin of intertrochanteric line and the superomedial margin of the lesser trochanter. This parameter was introduced and measured by Bob-Manuel *et al.*[5]. See angle labelled “2” in Fig 1.

Femoral Shaft Intertrochanteric Angle (FSIA)

This is the angle formed at the junction of the femoral shaft axis and the intertrochanteric axis. This parameter was introduced and measured by Bob-Manuel *et al.*[5]. (See angle labelled ‘3’ in Fig 1.)

Femoral Intertrochanteric Triangle (FIT)

This is a scalene triangle formed by the intersection of the lines passing through the shaft, neck and intertrochanteric axis at the intertrochanteric area of the proximal *os femora* (see XYZ in Figure 1). The sides of the FIT were measured as follows:

FIT_{XY} – Distance between intersection point of the shaft and neck axis lines and the intersection point of the intertrochanteric and neck axis lines,

FIT_{YZ} – Distance between the intersection point of the intertrochanteric and neck axis lines and the intersection point of the shaft and intertrochanteric axis lines and

FIT_{XZ} – Distance between the intersection point of the shaft and neck axis lines and the intersection point of the shaft and intertrochanteric axis lines. The area of the

Femoral Intertrochanteric Triangle
(FIT_{AREA}) was calculated using Heron's
formula: $Area = \sqrt{p(p-x)(p-y)(p-z)}$.

Where $p = (x+y+z)/2$: x, y, and z are sides of the triangle. This parameter was introduced and measured by Bob-Manuel *et al.* [5]. (See angle labelled '3' in Fig 1.)

Data Analysis

All measurement were taken twice and the average recorded by the researcher. Data collection for this study were analysed with the help of Statistical Package for Social Science (SPSS) 23.0 version to establish baseline descriptive statistical data. Two tailed z-test was used to compare mean values to establish gender and side differences and Pearson correlation was done to show relationship between measured parameters. $P < 0.05$ was taken as statistically significant while P-value less than 0.01 were taken as highly significant. All linear measurements were taken in millimetres and angles in degree. Summary of results obtained are presented in tables.

RESULT AND DATA ANALYSIS

The data analysis for this research work was performed using SPSS version 23.0. The mean, standard error, standard deviation, P value and Z value was analysed using two tailed Z-test. The result of this work is represented in tables.

Table 1 shows the mean, standard error, standard deviation of measured parameters femoral neck shaft angle (FNSA), femoral neck intertrochanteric angle (FNIA), femoral intertrochanteric width (FIW), femoral intertrochanteric triangle (FIT_{AREA}) of the left proximal femur, the right proximal femur and the total of left and right proximal femur.

Table 2 shows the mean, standard error, standard deviation, p-value, z-value and interference of the femoral neck shaft angle (FNSA), femoral neck intertrochanteric angle (FNIA), femoral shaft intertrochanteric angle (FSIA), femoral intertrochanteric triangle (FIT), of both right and left proximal femur.

Table 3: Shows the correlation of FNSA, FNIA, FSIA, FIT_{AREA} of the proximal femur. Highly significant ($p < 0.01$) positive correlation exists between FNSA and FSIA, and FSIA and FNIA is shown from this table.

TABLE 1: Mean, Standard error and Standard deviation of the seven measured parameters

SIDE		FNSA	FNIA	FSIA	FIT _{AREA}
ALL	Mean	132.91	96.50	35.93	61.57
	SE	0.35	0.55	0.45	0.27
	SD	3.97	6.18	5.08	3.08
LEFT	Mean	133.07	96.98	35.41	62.23
	SE	0.54	0.79	0.67	0.33
	SD	4.03	5.89	5.00	2.47
RIGHT	Mean	132.79	96.11	36.34	59.38
	SE	0.47	0.76	0.61	0.42
	SD	3.94	6.42	5.14	3.50

Femoral Neck Shaft Angle (FNSA), Femoral Neck Intertrochanteric Angle (FNIA), Femoral Shaft Intertrochanteric Angle (FSIA), Area of Femoral Intertrochanteric Triangle (FIT_{AREA}).

TABLE 2: Test of inference of six (6) measured parameters

SIDE	LEFT			RIGHT			P-VALUE (P < 0.05)	Z-CAL	INFERENCE
	Mean	SE	SD	Mean	SE	SD			
FNSA	133.07	0.54	4.03	132.79	0.47	3.94	0.69	0.49	NOT SIGNIFICANT
FNIA	96.98	0.79	5.89	96.11	0.76	6.42	0.43	0.79	NOT SIGNIFICANT
FSIA	35.41	0.67	5.00	36.34	0.61	5.14	0.31	1.03	NOT SIGNIFICANT
FIT _{AREA}	62.23	0.33	2.47	59.38	0.42	3.50	0.86	0.18	NOT SIGNIFICANT

Femoral Neck Shaft Angle (FNSA), Femoral Neck Intertrochanteric Angle (FNIA), Femoral Shaft Intertrochanteric Angle (FSIA), Area of Femoral Intertrochanteric Triangle (FIT_{AREA}).

TABLE 3: Bivariant Correlation Analysis of measured parameters

PARAMETER		FNIA	FSIA	FIT _{AREA}
FNIA	Pearson Correlation	.355**	.293*	0.010
	Sig. (2-tailed)	0.007	0.028	0.089
FSIA	Pearson Correlation		-.589**	0.011
	Sig. (2-tailed)		0.000	0.147
FNSA	Pearson Correlation			0.023
	Sig. (2-tailed)			0.071

DISCUSSION

Understanding the dimensions of the structural configuration of human skeleton is requisite in anthropologic and forensic anatomy, radiologic anatomy and orthopaedics [5].

From the study of the femoral head of the SeyhHoyuk area (Southern Anatolia), the statistical analysis of all measured parameter showed no significant difference between the right and left femurs except for the vertical diameter of the right femoral head, which was significantly greater than those of the corresponding left femur [23]. This correlates to findings of this study which showed that no significance existed between the left and right *os femora*.

Angular morphometric parameters have been reported to vary in different population by numerous scientific investigators [24] [25] [26]. Comparing the means of the morphometric parameters obtained in this study with the outcome of erstwhile workers [16-19, 25] on dissimilar and distinct population reveal variation in values. Also, our value of femoral neck shaft angle (FNSA) varies slightly but similar with the research outcome of Udoaka and Agi [26], Bob-Manuel *et al.* [22], and Bob-Manuel *et al.* [5] on the Nigerian population.

This team of investigators resolve that variations are extant among the parameters of the proximal *os femora* and insignificant in similar population but data from the different populations vary significantly. From the aforementioned, it is worth accentuating that inter-population and intra-population-based differences are existing in the metric structural configuration of the *os femora*. Hence, utilizing or employing orthopaedic implants and screws designed by Caucasian manufacturers, presumably using femoral structural metric values of their population, won't be suitable for other population like ours.

In this present study, the morphometric parameters introduced by Bob-Manuel *et al.*, [5] were measured and studied. From the outcome of this study, highly significant ($p < 0.01$) positive correlation exists between FNSA and FSIA, and FSIA and FNIA. This suggest how useful the FNIA and FSIA would be when used alongside the FNSA in forecasting or foretelling and managing proximal femoral fractures as it defines the geometric relation between the neck, intertrochanteric area (proximal epiphyseal area) and the shaft of femur. This agrees with the findings of Bob-Manuel *et al.*, [5].

Haddad *et al.* [27], in a recent study revealed there was no significant difference between right and left femur FNSA among the

patients ($p=0.95$). On both sides, male FNSA was higher than female NSA ($p < 0.001$). In supine radiograph, the overall mean NSA for the supine position was $133.06^\circ \pm 5.71^\circ$. There was a significant difference between FNSA of the right and left femur among the patients in the supine position ($p < 0.001$). On supine radiographs there was no statistically significant difference between male and female FNSA ($p=0.85$). This is slightly different but similar to our study where FNSA of femurs placed antero-posteriorly was 132.91° , there was also no significant difference between right and left femur FNSA among the patients ($p=0.69$). No inference was made between the male and female femurs.

In another study done by Rogers *et al.* [28] on 203 patients to check for side-to-side variability of the FNSA using upright anteroposterior pelvis radiographs, no significant variability between the two angles was found. Similarly, a study done in India on 110 patients using supine anteroposterior pelvis radiographs concluded that the NSA angle of the contralateral femur can be used as a template during repair [29]. Both studies [28, 29] mentioned above agrees with findings of this present study.

Pasi and Gafen [24] mentioned that the trabecular bone in the epiphyses of long bones underwrites the power and ability of the proximal *os femora* by resisting and distributing impact of loads applied to the epiphyseal or metaphyseal cortex. This role may be analogous to the purpose of the trabecular lattice in allocating functional joint and muscle loads. Nevertheless, since trabecular paths are aligned to offer maximal support in line with the physiologic joint/muscle loads, the trabecular lattice is

unlikely to be optimized for supporting non-functional impacts as during traumatic injury.

The proximal end of the femur alters and adjust its structure to suit loads it is exposed such that its trabeculae orientate along the direction of the principal stress achieving full stiffness and strength [30]. Djuric *et al.* [30] studied the peripheral geometry and microscopically observed the intertrochanteric area and neck of the *os femora* and disclosed that the trabeculae pattern at this region depicts altering and varying complex loading model of the proximal *os femora* during growth. Summating the findings of Pasi and Gafen [13] and Djuric *et al.* [30], suggests that the size of the intertrochanteric area of the proximal end of the femur could determine the proximal *os femora* strength.

To this end, Bob-Manuel *et al.* [5] introduced the femoral intertrochanteric triangle (FIT) also called femoral proximal epiphyseal triangle, a scalene triangle formed at the intertrochanteric area of the proximal *os femora* by the intersection of the shaft axis, neck axis and intertrochanteric axis lines, and quantified its area (FIT_{AREA}) in their study, which could be useful in determining the proximal *os femora* strength. Our findings in this study showed no significant ($p < 0.05$) side difference in FIT_{AREA} . This is similar to the findings of the Bob-Manuel *et al.* [5]. However, mean values for FIT_{AREA} in this study was higher than the findings of Bob-Manuel *et al.*, [5]. This could be accounted for by the difference in methodology.

CONCLUSION

We conclude that dynamic and robust understanding of the geometry and

strength of the proximal end of the os femora requires parameters that conform to anatomical facts between the head, neck and proximal shaft of the os femora. This advocate how useful the FNIA and FSIA would be when used together with the FNSA in forecasting or foretelling and managing proximal femoral fractures as it defines the geometric relation between the neck, intertrochanteric area (proximal epiphyseal area) and the shaft of femur. FIT_{AREA} which depicts the strength of the femoral epiphyseal or intertrochanteric area would also be useful in this regard.

They can also serve as a guide for designing better-matched or custom-made prostheses and implants for hip surgeries in the Nigerian population.

RECOMMENDATION

Biomedical engineers should take radical and innovative steps in making femoral implants for orthopaedic surgeon. We recommend the possibility of the measured parameters in this study to better elucidate its relevance in understanding the morphology of the proximal extremity of the os femora.

REFERENCES

1. Krishan, K (2007): Anthropometry in Forensic Medicine and Forensic Science-'Forensic Anthropometry': *The Internet Journal of Forensic Science*. Volume 2, Number 1.
2. Faulkner KG, Cummings SR, Black D, Palermo L, Glüer CC, Genant HK. (1993). Simple measurement of femoral geometry predicts hip fracture: the study of osteoporotic

- fractures. *J Bone Miner Res* 1993; 8 (10) 1211-1217
3. Boonen S, Koutri R, Dequeker J, Aerssen J, Lowet G, Nijs J. (1995). Measurement of femoral geometry in type 1 and type 11 osteoporosis: difference in hip axis length content with heterogeneity in pathogenesis of osteoporotic fracture. *J Bone Miner Res*, 10:1908-1912.
4. Orwoll, E. S., Marshall, L. M., Nielson, C. M., Cummings, S. R., Lapidus, J., Cauley, J. A., et al. (2009) Osteoporotic Fractures in Men Study Group. Finite element analysis of the proximal femur and hip fracture risk in older men. *J Bone Miner Res*. 24(3):475-83.
5. Bob-Manuel IF, Didia BC, Udoaka AI (2019). Proximal Femoral Morphometry: New Morphometric Parameters for Prediction Proximal Femoral Fracture. *Journal of Anatomical Sciences* 10 (2). 131-136.
6. Boese, C. K., Dargel, J., Oppermann, J., (2016). The femoral neck-shaft angle on plain radiographs: a systematic review. *Skeletal Radiol*. 45:19–28.
7. Gilligan, I., Chandraphak, S., Mahakkanukrauh, P. (2013). Femoral neck-shaft angle in humans: variation relating to climate, clothing, lifestyle, sex, age and side. *J Anat*. 223:133–51
8. Altubasi, I., Hamzeh, H., Madi, M., (2020). Measurement of Neck-Shaft Angle Using CT Scout View in Healthy Jordanian Adults - A Reliability and Agreement Study. *J Adv Med Res*. 32:9–17
9. Fischer, C. S., Kühn, J-P, Völzke, H. (2020). The neck-shaft angle: an update on reference values and

- associated factors. *Acta Orthop.* 91:53–7.
10. Toogood, P. A., Skalak, A., Daniel, R. Cooperman D (2009). Proximal Femoral Anatomy in the Normal Human Population. *Clin OrthopRelat Res.* 467(4): 876-885.
 11. Gaspar D and Crnkovic T. (2014). Hip geometry measures can predict femoral neck and intertrochanteric fractures. Controversies in literature. *Med Jad.* 44(3-4): 101-106.
 12. Dalaere O, Dhem A, Bourgois R. (1989). Cancellous bone and mechanical strength of the femoral Neck. *Arch Orthop Trauma Surg.*108:72-75.
 13. Passi N, and Gefen A. (2005). Trabecular bone contributes to strength of the proximal femur under mediolateral impact in the avian. *Journal of Biomedical Engineering* 127: 198-203
 14. Faulkner KG, Wacker WK, Barden HS, Simonelli C, Burke S, Ragi PK and Delrio L. (2006). Femur strength index predicts hip fracture independent of bone density and hip axis length. *Osteoporos Int.* 17:593-9
 15. Menezes TM, Rocha TDS, De Oliveira BDR, De Albuquerque YML, Caiaffo V. (2015). Proximal femoral epiphysis: Manual morphometry versus digital morphometry. *International Journal Morphology.* 33(3):1114-1119.
 16. Tokpinar A, Yilmaz S, Tokpinar RK, Ates S, Kandur ME, Nisari M. (2020). Morphometric Examination of the Proximal Femur in the Hip Joint. *Experimental and Applied Medical Science.* 1(3): 82 - 88.
 17. Tumusiime G, Kirum GG and Kukiriza J. (2021). Morphometry of the Proximal End of Dry Adult Human Femora from the East African Population: A Cross-Section Study. *Austin Journal Anatomy.* 8(2): 1102.
 18. Gupta M, Devadas D, Sahni C, Nayak A, Tiwari PK, Mishra A. (2022). Morphometric Analysis of the Proximal Femur With Its Clinical Correlation in Eastern Uttar Pradesh Region. *Cureus*14(9): e28780. DOI 10.7759/cureus.28780
 19. Skaria S, Kulkarni M, Vaishnani H. (2022). Morphometric Study of Proximal Femur and its Applications in Prosthesis Designing: A Cross-sectional Study from Western India. *Journal of Clinical and Diagnostic Research.* 16(5): AC01-AC04
 20. Calis HV. Eryavuz M and Calis M (2004). Comparism of femoral geometry among cases with and without hip fractures. *Yonsei Med J.* 45:901-907.
 21. Irdesel, J., & Ari, I. (2006). The proximal femoral morphometry of Turkish women on radiographs. *European Journal of Anatomy,* 10(1), 21.
 22. Bob-Manuel IF, Didia BC and Udoaka A (2017). Radiogrammetry of the Femoral shaft angle and the angles of the hip joint Nigerians. *Journal of Anatomical Sciences.* 8(1):105-110.
 23. Strecker W, Keppler P, Gebhard F, Kinzl L. (1997). Length and torsion of the lower limb. *Br J Bone Joint Surg* 79: 1019 – 1023.
 24. De Sousa, A.P., et al. (2010) Effect of LED Phototherapy of Three

Distinct Wavelengths on Fibroblasts on Wound Healing: A Histological Study in A Rodent Model. *Photomed Laser Surg*, 28, 547-552.

25. Igbigbi, P. S., & Msamati, B. C. (2002). The femoral collodiaphyseal angle in Malawian adults. *American Journal of Orthopedics (Belle Mead, NJ)*, 31(12), 682-685.
26. Udoaka, A. I., & Agi, C. E. (2010). A study of the collo-diaphyseal angle in an adult population in Southern Nigeria. *Afr J Med Phy Biomed Eng & Sci*, 2, 67-70.
27. Haddad, B., Hamdan, M., Nawaiseh, A. I., Aldowekat, O., Alshrouf, M. A., Karam, A. M., et al. (2022). Femoral neck shaft angle measurement on plain radiography: is standing or supine radiograph a reliable template for the contralateral femur? *BMC Musculoskeletal Disorders*. 23: 1092 (2022)
28. Rogers, M. J., King, T. L., Kim, J., et al. (2021). Femoral Neck Shaft Angle and Management of Proximal Femur Fractures: Is the Contralateral Femur a Reliable Template? *J Orthop Trauma*. 35:529-34.
29. Pathak SK, Maheshwari P, Ughareja P, et al. (2016). Evaluation of femoral neck shaft angle on plain radiographs and its clinical implications. 2:383.
30. Djuric, M., Milovanovic, P., Potocnik, J., Djonic, D., Nikolic, S., Zivkovic, V., & Rakocevic, Z. (2012). Age-related deterioration in trabecular bone mechanical properties at material level: nanoindentation study of the femoral neck in women by using AFM. *Experimental gerontology*, 47(2), 154-159.