

Review Article

Chondropathy: The Roles of Fibroblast Growth Factor Receptors-3(FGFR3) in Skeletal Dysplasia Spectrum.

ABSTRACT

The FGFR3 gene codes for producing fibroblast growth factor receptor three and may be affected by a mutation leading to notable chondropathies. Achondroplasia is the most common of the spectrum of chondropathies, occurring in approximately 1 in 20,000-30,000 live births, while Hypochondroplasia has an incidence between 1 in 33,000 and 1 in 47,000 live births.

The mode of inheritance is known to be autosomal dominant, with 20% of cases inherited, while 80% of cases are due to new spontaneous mutation. Hence, FGFR3 molecular genetic testing should always be performed in children with atypical presentation or similar clinical conditions like craniosynostosis syndrome.

Different pharmacological options have been used for clinical management, including those that directly block FGFR3 activation or regulate signaling pathways that control chondrocyte proliferation and differentiation. The translation to review article follows teaching sessions and discussions among medical educators and students, aiming to ensure a better understanding of Chondropathies and improve writing skills.

Key words: Achondroplasia, Chondropathy, Hypochondroplasia, FGFR3.

INTRODUCTION

Chondroplasties are disorders that affect cartilage formation, proliferation, and differentiation [1]. Specific disorders in the spectrum include Achondroplasia, costochondritis, relapsing polychondritis, spinal disc herniation, osteoarthritis, and cartilage tumors. Chondroplasties are most commonly affected by mutations of the FGFR 3 gene.

Four fibroblast growth factor receptors are known to share similar structures and functions. They include FGFR3, FGFR3-TACC3, BAIA32L1. These four proteins have important roles: cell proliferation regulation, cell type determination, angiogenesis, wound healing, and embryogenesis. Notably, the FGFR3 protein regulates bone growth by limiting ossification, particularly in the long bones. [1]

Epidemiology

Achondroplasia is known to be the most common skeletal dysplasia/chondropathy. It occurs in approximately 1 in 20,000-30,000 live births. This genetic disorder is caused by a fibroblast growth factor receptor 3 (FGFR3) gene mutation. Affected patients have the most common genetic form of human dwarfism, characterized by short limbs with macrocephaly and characteristic facial features [frontal bossing and midface hypoplasia]. Sporadic cases of Achondroplasia have been associated with advanced paternal age, suggesting that these mutations occur preferentially during spermatogenesis. [1]

Hypochondroplasia (a milder form) has an incidence between 1 in 33,000 to 47,000 live births and is the most common form of neonatal lethal dwarfism. Newborns usually die shortly after birth from respiratory distress secondary to pulmonary hypoplasia. A more lethal

form of Hypochondroplasia is thanatophoric dysplasia: a severe skeletal disorder associated with extremely short limbs and extra folds of skin on the arms and legs. [1][2]

Fibroblast growth factor receptor 3 is the only known gene associated with all four subtypes of skeletal dysplasias (i.e., some cases of so-called idiopathic short stature). The Fibroblast growth factor receptor 3 (FGFR3) gene results in a specific amino acid substitution, G380R. This receptor is also associated with severe Achondroplasia with developmental delay and acanthosis nigricans (SADDAN), Crouzon syndrome with acanthosis nigricans, and Muenke craniosynostosis syndrome. [2][3]

Congenital chondrodysplasias that affect skeletal morphogenesis and growth have a relatively low incidence (3 to 6 cases per one million) [3]. Adult-onset diseases associated with the joint cartilage of long bones, such as rheumatoid arthritis and osteoarthritis, are much more prevalent. Osteoarthritis is the most common cartilage disorder and a significant cause of disability: affecting 32.5 million adult patients in the United States [4]. Rheumatoid Arthritis affects 0.24 to 1 percent of the population and is twice as common in women. [5].

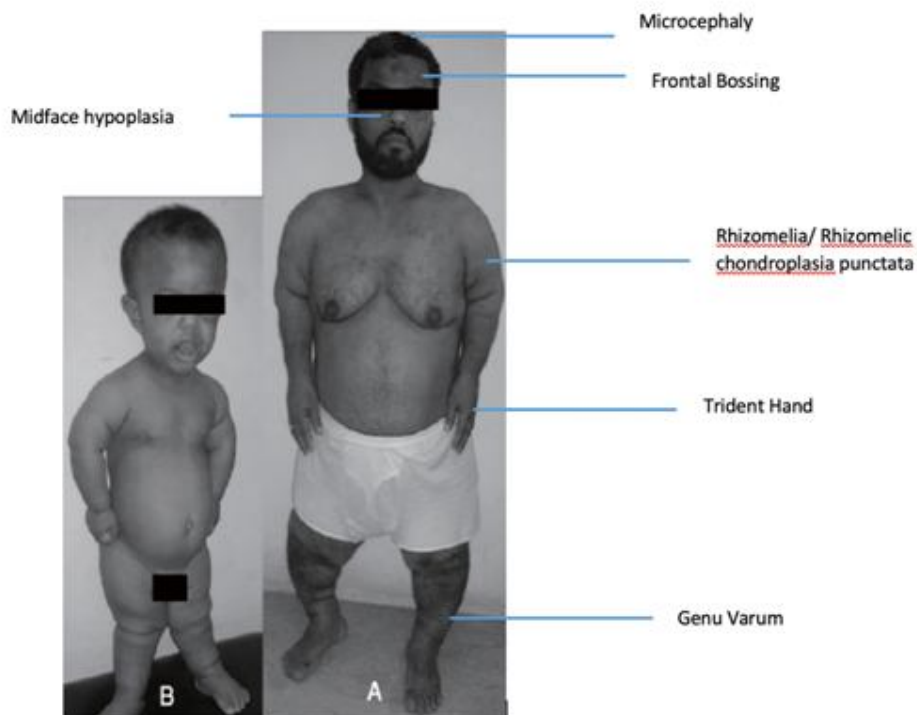


Figure 1: Father and son with characteristics features of achondroplasia.

Source: <https://www.researchgate.net/journal/Egyptian-Journal-of-Medical-Human-Genetics-1110-8630V>

Etiology

Changes in the FGFR3 gene cause a broad spectrum of conditions, from Hypochondroplasia, Achondroplasia to Thanatophoric dysplasia. Achondroplasia results from a point mutation in the gene coding for the transmembrane portion of fibroblast growth factor receptor 3

(FGFR3), which resides on the short arm of chromosome 4 [6]. The resultant abnormal chondroid production affects endochondral ossification resulting in decreased linear bone growth, among other functions. This pathologic process generally spares intramembranous ossification, which takes place in flat bones such as those in the skull (except for the base of the skull), face, and clavicles. In over 80% of cases, the condition occurs due to sporadic, or de novo, mutation. Thus, a child with Achondroplasia can be born to healthy parents with no family history of the disorder [7]. The remaining 20% of Achondroplastic individuals have at least one affected parent.

Mutations in the FGFR3 gene also cause about 70% of all cases of Hypochondroplasia. This gene provides instructions for making a protein to develop and maintain bone and brain tissue. Although it remains unclear how FGFR3 mutations lead to the features of Hypochondroplasia, researchers believe that these genetic changes cause the protein to be overly active. The overactive FGFR3 protein likely interferes with skeletal development and leads to disturbances in bone growth that are characteristic of this disorder [8].

A mutation in the fibroblast growth factor receptor 3 (FGFR3) gene is also responsible for causing Thanatophoric dysplasia [9]. Typically, the FGFR3 protein functions as the brake for endochondral bone growth, which is the type of bone formation that occurs at the growth plates of the long bone. A change in this gene increases the ability of the FGFR3 protein to slow bone growth. This type of change associated with an increased ability is called a gain of function mutation.

PATHOGENESIS OF ACHONDROPLASIA

Classical Achondroplasia

Achondroplasia is caused by mutations in the FGFR3 gene, which encodes fibroblast growth factor receptor 3 (FGFR3), a protein that facilitates cell growth, migration, and differentiation. Mutations in this gene can be inherited or acquired during development. Alterations in DNA sequences coding for the protein most commonly cause mutations in FGFR3. These mutations cause a loss of function in FGFR3, which leads to abnormal cell proliferation and improper cartilage development. As a result of the effect of this mutation on FGFR3's ability as a single pass transmembrane receptor to regulate chondrocyte cell proliferation and cartilage formation. [10][11] Achondroplasia patients are often born with severe malformations in their skeletons. FGFR3 is a key FGF-binding tyrosine kinase receptor, and the human FGFR3 gene is located on chromosome 4q16.3. This gene is 15 Kb, containing 19 exons and 18 introns. [11] An extracellular glycosylation ligand-binding domain, a hydrophobic transmembrane domain, and an intracellular tyrosine kinase catalytic domain are all encoded by the FGFR3 gene. [10][11]

A mutation of FGFR3 in the hydrophobic transmembrane domain may be the top genetic hot zone necessary to regulate cartilage development was reported in patients with Achondroplasia according to polymerase chain reaction combined with single strand conformation polymorphism (SSCP). The location of the mutation at exon ten which encodes the hydrophobic transmembrane domain, was also confirmed. The c. 1138G•A causes 99% of cases of Achondroplasia and c.1138G→C mutations. Both convert glycine (Gly) into arginine (Arg) on the 380th amino acid, leading to dysfunctional proteins. A third base mutation – Swedish and Japanese research groups found c.1123G→T in separate cases, but the mutation incidence is very low, about 1-2% of all mutations. [10]

A top component altering Achondroplasia is the deviant downstream signaling of ligand-receptor of FGF3 and FGFR3. FGF ligands bind to FGFR3, leading to the stimulation and

dimerization of the receptor and consequentially stimulating the target tyrosine kinase of FGFR3, leading to autophosphorylation of the selected tyrosine residues in the cytoplasmic domain of the receptor. FGFR3 signaling inhibits bone growth via the mitogen-activated protein kinase (MAPK) pathway and reduces chondrocyte proliferation via Stat1 [10].

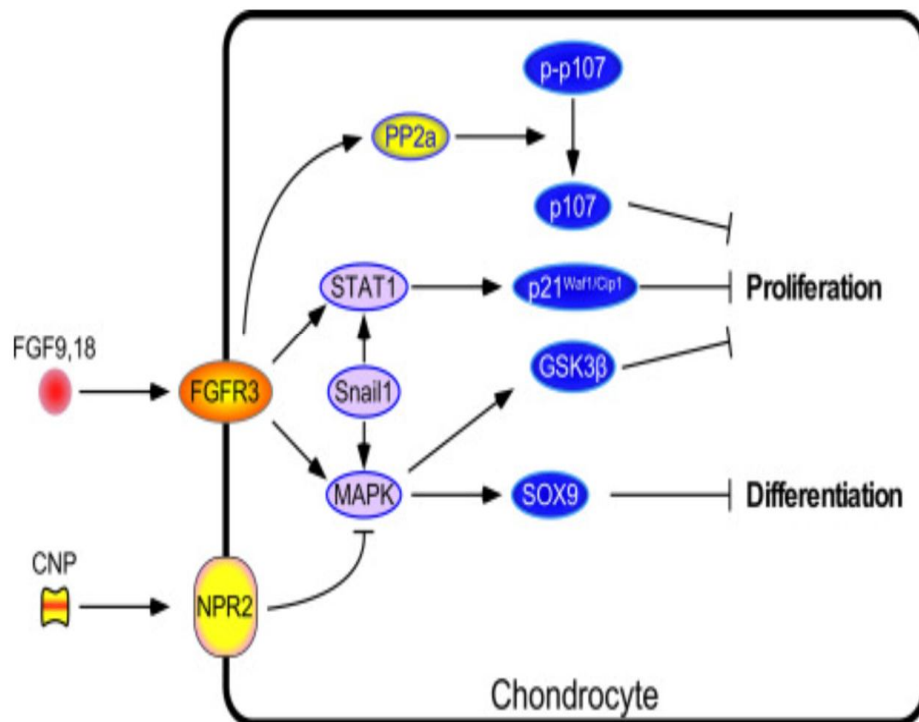


Figure 2: Schematic of cascade of genetic regulations and activities of FGFR3.

Source: <https://www.sciencedirect.com/topics/neuroscience/fibroblast-growth-factor-receptor-3>

Variants of Achondroplasia

Achondroplasia outcome is the point mutation in the gene coding for FGFR3, which is on the short arm of chromosome 4. Two viable base substitutions come from the point mutation,

which is a transition of c.1138G>A (guanine to adenine substitution, which is identified in approximately 98% of affected individuals) and a transversion of c.1138G>C (guanine to cytosine which is seen in about 1% of affected individuals). The normal GGG codon change to AGG or CGG is caused by the base substitutions leading to glycine being replaced with arginine (p.Gly380Arg) in both situations, eventually affecting the transmembrane domain of FGFR3. A gain-of-function mechanism of FGFR3 and following quantitative growth plate and cartilage defects seen in Achondroplasia is led by both substitutions that present with a pathogenic variant of FGFR3. The fundamental activation of the receptor protein and a remarkable reduction in endochondral bone formation produce the genetic mutation of FGFR3 (p.Gly380Arg) through an escalation inhibition of chondrocyte proliferation and differentiation. [10][11][12] In the case of Thanatophoric dysplasia, Lys650Met substitution in FGFR3. The pathogenic variant p.Lys650Glu was identified in all diagnosed individuals with type II. [10]

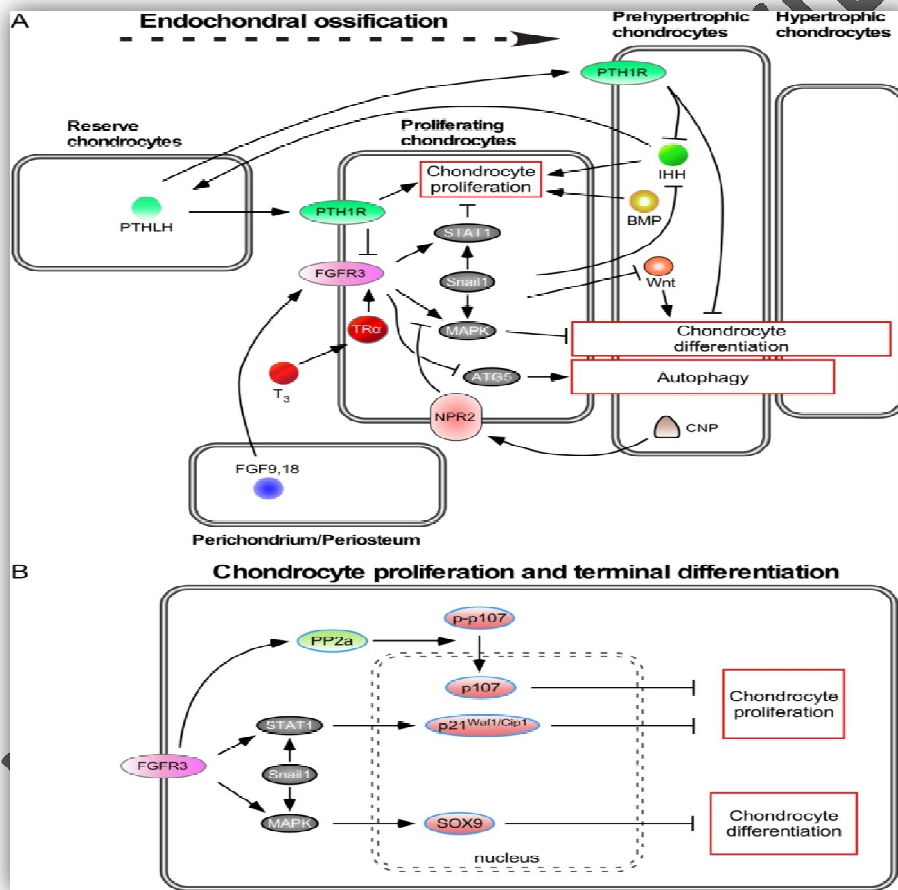


Figure 3A and B: Schematic showing the genetic cascade in the pathogenesis of Achondroplasia. (A) is Endochondral ossification and (B) chondrocyte proliferation and differentiation.

Source: <https://anatomypubs.onlinelibrary.wiley.com/doi/10.1002/dvdy.24479>

Hypochondroplasia

This comparatively humane form of dwarfism shares many phenotypic features with Achondroplasia—De novo mutations in the FGFR3 gene form hypochondroplasia in most cases. The FGFR3 missense mutation (p.Asn540Lys) causes Hypochondroplasia, isolated in tyrosine kinase domain I, and is the most common hypochondroplasia mutation that occurs in approximately 60% of cases. Tyrosine kinase domain II of FGFR3 (p.Lys650Asn) and in the extracellular domain establishes other less common missense mutations. In vitro analyses of the p.Lys650Asn mutation showed weak activation of the FGFR3 kinase domain. Analysis of the p.Asn540Lys mutation showed activation of ERK1/2 but not STAT1 [12].

DIAGNOSIS

FGFR3 molecular genetic testing should always be performed in children with atypical presentations or in the circumstances requiring differentiation from similar disorders. Achondroplasia, Hypochondroplasia, and thanatophoric dysplasia arise from similar genetic defects with differing activation of pathogenic FGFR3 variants. Over 350 skeletal dysplasias are known to cause short stature, most of which are rare—Hypochondroplasia and Thanatophoric disorders present with rhizomelic dwarfism and lesser height disparity compared to Achondroplasia [13]. Most clinical presentations and radiological findings of these clinical conditions are very similar and tend to overlap. Patients affected by this disorder may appear normal at birth. However, they tend to present with impaired linear growth, short limbs and trunk, and mild mental retardation in 10% of cases [7].

The diagnosis of Achondroplasias has routinely been made from clinical presentations, radiological findings, and genetic testing. Prenatal diagnosis may sometimes be made with shortened long bones during a routine second or third-trimester pregnancy ultrasound. Non-invasive prenatal diagnosis using cell-free fetal DNA found in the mother's serum is also available, with high sensitivity and specificity reported [7]. A pre-implantation genetic diagnosis is available for parents pursuing in-vitro fertilization and embryo implantation procedures. The prenatal detection rate has recently improved significantly from 36% from 1991-1995 to 71% during 2011-2015 [14].

A contracted skull base, rhizomelic features of long bones, proximal femoral radiolucency, generalized metaphyseal "flaring" irregularities, inverted "V-shaped or chevron-shaped" distal femoral epiphyses, a "champagne-glass" shaped pelvis (more comprehensive than a deep pelvic outlet with small Sacro-sciatic notch) may also be noticed on Skeletal survey. The radiographic features of narrowed interpedicular distances (short pedicles usually found from L1-S1), vertebral body wedging (usually found at T12 or L1), and generalized posterior vertebral scalloping are unique to Achondroplasia. Signs and symptoms of corticomedullary myelopathy are also apparent if there is evidence of sleep apnoea. [10]Hypochondroplasia is only diagnosed at birth if a prior family history exists [8]. Most affected individuals present with short stature as toddlers or young school-age children. A false positive diagnosis of Hypochondroplasia is often made because the disorder is considered relatively common and associated radiologic findings are subtle.

In the case of Thanatophoric dysplasia, the condition is usually an incidental finding during a routine prenatal ultrasound with characteristic findings of shortened long bones visible as early as 14 weeks gestation [15]. Two clinically distinct forms of short-limb dwarfism lethal in the perinatal period are known. Type I patients present with micromyelia with the bowed femur, while a patient with Type II presents with micromyelia with a straight femur. Typical

clinical findings include cloverleaf skull deformity, infantile hypotonia, macrocephaly, frontal bossing, flat facies with ocular proptosis, ventriculomegaly, increased nuchal translucency, a narrow chest cavity with short ribs, and brachydactyly. Most infants with this disorder die due to respiratory insufficiency shortly following birth. [15]

| Types | Differences | Similarities |
|-------|--------------------------------|---|
| I | Micromelia with bowed femur | Clover leaf skull deformity, infantile hypotonia, macrocephaly, brachydactyly |
| II | Micromelia with straight femur | |

Table 1: Types of Achondroplasia.

DIFFERENTIAL DIAGNOSIS

i. Severe Achondroplasia with developmental delay and acanthosis nigricans (SADDAN)

SADDAN is a dysplastic condition that arises from a different heterozygous mutation affecting the FGFR3 gene on chromosome 4p16. The patient presents with extensive acanthosis nigricans starting early childhood, with or without neurological impairments. The skin changes in acanthosis nigricans are usually progressive and thought of as a long-term complication rather than a specific clinical feature of SADDAN [17]. Impairment in endochondral bone growth similar to what is observed in Thanatophoric dysplasia Type I may also be seen in a patient with SADDAN. Apex posterior tibial and fibular bowing, curved "ram's horn" deformities of the clavicles, and femoral bowing are osseous deformities that may be seen in the disorder. [8]

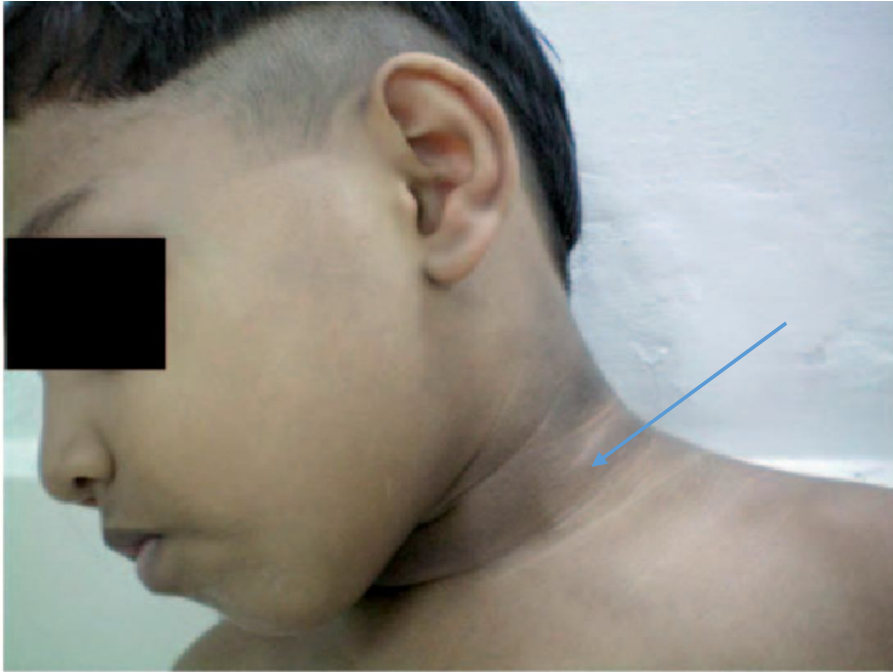

Figure 4. Acanthosis Nigricans (blue arrow)

Source: <https://www.semanticscholar.org/paper/SADDAN-syndrome.-Kumar-Shaikh/df00dd5070033d9b7367700e20e013b0a3da2387>

ii. FGFR3 Craniosynostosis Syndrome

FGFR3 Craniosynostosis Syndrome should be suspected in individuals with uni- or bi-coronal craniosynostosis or cloverleaf skull, characteristic facial features, and varying abnormal hand and foot findings. However, these clinical features may not be apparent in affected neonates or may vary from mild to severe and life-threatening presentation. Features typically become more prominent with age and based on clinical and radiologic findings in each pathogenic variant; FGFR1, FGFR2, or FGFR3. The distinguishing features can aid in the specific diagnosis of the different phenotypes. [16]

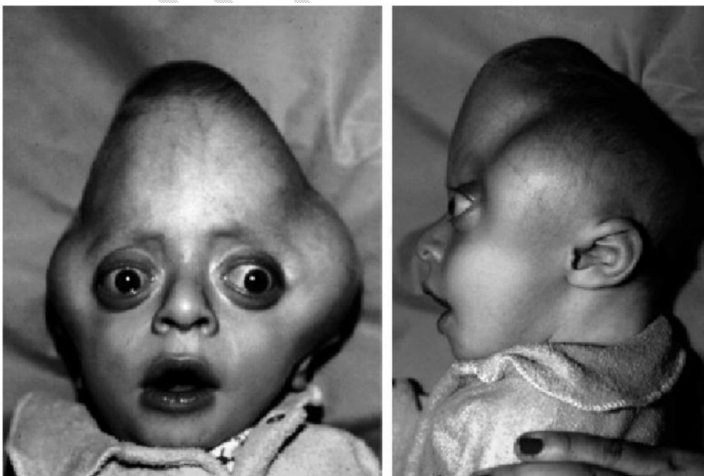


Figure 5. Clover leaf Skull.

MANAGEMENT

i. ACHONDROPLASIA

There is no cure for Achondroplasia. However, complications of Achondroplasia have been managed using symptomatic approaches, surgical intervention, and lifelong follow-up care. Health problems commonly associated with Achondroplasia such as cervical medullary compression (due to a reduced size of the foramen magnum) and otitis media, can be treated to prevent cardiopulmonary failure, lumbar spinal compression, and hearing loss [19].

Adenotonsillectomy, positive airway pressure support and tracheostomy may be needed to address sleep apnea. [20]

Surgical and nonsurgical strategies have been adopted to manage short stature and impaired linear growth. The first therapeutic strategy for Achondroplasia patients is treated with recombinant human growth hormone (r-hGH). However, the use of r-hGH to treat Achondroplasia is not routinely recommended. [21]

Some pharmacological approaches are aimed at directly blocking FGFR3 activation or regulating other signaling pathways that control chondrocyte proliferation and differentiation.

ii. HYPOCHONDROPLASIA

Parental concerns influence the management of short stature in Hypochondroplasia.

Recombinant human growth hormone is indicated for the treatment of short stature. The mechanism of action of recombinant human growth hormone does not directly act on FGFR3 signaling pathways. Rather, recombinant human growth hormone stimulates the growth of the cartilage through its pro-anabolic properties. [10][11][22] Suboccipital decompression is used if the neurologic status is affected by spinal cord compression. Treatment for thoracolumbar kyphosis or genu varum is also necessary. Developmental milestones are followed closely during early childhood so that cognitive impairments are addressed with special educational programs [11] [22]

Surgical intervention is a common therapy for proportional and disproportional dwarfism (e.g., Ach, Hch). Surgical limb lengthening classically uses the Ilizerov procedure in which long cortical bones are cut (osteotomy), external fixators are placed proximal and distal to the osteotomy, and distraction is applied gradually over many months to extend the bone length. The average length gained is ~20.5 cm after multiple procedures applied to the femurs and tibias. [10][22]

This surgical treatment allows functional gains and quality of life improvements. However, this procedure is painful and associated with complications that include infection, muscle contractures, and increased fracture risk. Limb lengthening, involving the surgical breaking of a bone, fixation, and distraction during the healing process, remains controversial and is associated with a high risk. Before surgery, a pre-operative psychological assessment is required to evaluate the high risk of complications against the expected improvement of the short stature. In the future, combining surgical limb lengthening with pharmacological strategies could further improve outcomes. [10][11][12][22]

CONCLUSION.

Parental concerns influence the management of short stature in Hypochondroplasia.

Recombinant human growth hormone is indicated for the treatment of short stature. The

mechanism of action of recombinant human growth hormone does not directly act on FGFR3 signaling pathways. Rather, recombinant human growth hormone stimulates the growth of the cartilage through its pro-anabolic properties. [10][11][22] Suboccipital decompression is used if the neurologic status is affected by spinal cord compression. Treatment for thoracolumbar kyphosis or genu varum is also necessary. Developmental milestones are followed closely during early childhood so that cognitive impairments are addressed with special educational programs [11] [22]

Surgical intervention is a common therapy for proportional and disproportional dwarfism (e.g., Ach, Hch). Surgical limb lengthening classically uses the Ilizarov apparatus in which long cortical bones are cut (osteotomy), external fixators are placed proximal and distal to the osteotomy, and distraction is applied gradually over many months to extend the bone length. The average length gained is ~20.5 cm after multiple procedures applied to the femurs and tibias. [10][22]

This surgical treatment allows functional gains and quality of life improvements. However, this procedure is painful and associated with complications that include infection, muscle contractures, and increased fracture risk. Limb lengthening, involving the surgical breaking of a bone, fixation, and distraction during the healing process, remains controversial and is associated with a high risk. Before surgery, a pre-operative psychological assessment is required to evaluate the high risk of complications against the expected improvement of the short stature. In the future, combining surgical limb lengthening with pharmacological strategies could further improve outcomes.

DISCLAIMER

There is no conflict of interest between the authors, facilities, and the government. The research is solely for academic purposes in advancing medical knowledge with the sole aim of improving the lives of our patients. Also, no financial support from any source exists, and the Authors solely fund it.

CONSENT AND ETHICAL APPROVAL

None.

REFERENCES

1. McDonald EJ, De Jesus O. Achondroplasia. [Updated 2022 May 8]. In: StatPearls [Internet]. Treasure Island (FL): StatPearls Publishing; 2022 Jan-. Available from: <https://www.ncbi.nlm.nih.gov/books/NBK559263/> .
2. Vajo Z, Francomano CA, Wilkin DJ. The molecular and genetic basis of fibroblast growth factor receptor 3 disorders: the achondroplasia family of skeletal dysplasias,

Muenke craniosynostosis, and Crouzon syndrome with acanthosis nigricans. *Endocr Rev.* 2000 Feb;21(1):23-39. doi: 10.1210/edrv.21.1.0387. PMID: 10696568.

3. Efat Khorasani, M., & Rahim Vakili, M. (2016). Congenital Adrenal Hyperplasia and Schmid Metaphyseal Chondrodysplasia in a Child. *Iranian Journal of Medical Sciences*, 64-66.
4. Thurston Arthritis Research Center, T. U. (2022). *OA PREVALENCE AND BURDEN*. Retrieved from Osteoarthritis Action Alliance: <https://oaaction.unc.edu/oa-module/oa-prevalence-and-burden/#:~:text=CDC%20estimates%20that%201%20in,million%20by%20the%20year%202040.&text=While%20there%20are%20estimated%20to,affecting%2032.5%20million%20US%20adults>.
5. Bryant R England, M. P., & Ted R Mikuls, M. M. (n.d.). *Epidemiology of, risk factors for, and possible causes of rheumatoid arthritis*. Retrieved from UpToDate: [https://www.uptodate.com/contents/epidemiology-of-risk-factors-for-and-possible-causes-of-rheumatoid-arthritis#:~:text=Rheumatoid%20arthritis%20\(RA\)%20is%20estimated,in%20women%20compared%20with%20men](https://www.uptodate.com/contents/epidemiology-of-risk-factors-for-and-possible-causes-of-rheumatoid-arthritis#:~:text=Rheumatoid%20arthritis%20(RA)%20is%20estimated,in%20women%20compared%20with%20men).
6. Swathi KV, Maragathavalli G. Achondroplasia: A form of disproportionate dwarfism - A case report. *Indian J Dent Res.* 2020 Sep-Oct; 31(5):794-798. doi: 10.4103/ijdr.IJDR_303_19. PMID: 33433522.
7. Waller DK, Correa A, Vo TM, Wang Y, Hobbs C, Langlois PH, Pearson K, Romitti PA, Shaw GM, Hecht JT. The population-based prevalence of achondroplasia and thanatophoric dysplasia in selected regions of the US. *Am J Med Genet A.* 2008 Sep 15;146A(18):2385-9. doi: 10.1002/ajmg.a.32485. PMID: 18698630; PMCID: PMC6034636.
8. Bober MB, Bellus GA, Nikkel SM, Tiller GE. Hypochondroplasia. *GeneReviews* [Internet].2020
9. Jones, Kenneth L. *Recognizable Patterns of Human Malformation*. Philadelphia, PA: Elsevier Saunders. 2006.
10. Yao, W., Zeying, L., Zhenxing, L., Heng, Z., Xiaoyan, Z., Yazhou, C., Jinxiang, H. (2013). Advances in research on and diagnosis and treatment of achondroplasia in China. *Intractable & Rare Diseases Research*, 2(2): 45-50. <https://doi.org/10.5582/irdr.2013.v2.2.45>.
11. Oberklaid F, Danks DM, Jensen F, Stace L, Rosshandler S. Achondroplasia and hypochondroplasia. Comments on frequency, mutation rate, and radiological features in skull and spine. *J Med Genet.* 1979 Apr;16(2):140-6. doi: 10.1136/jmg.16.2.140. PMID: 458831; PMCID: PMC1012739.
12. Ornitz, D.M., Legeai-Mallet, L. (2017). Achondroplasia: Development, Pathogenesis, and Therapy. *Developmental Dynamics*. 246:291-309. <https://doi.org/10.1002/dvdy.24479>.

13. Almeida MR, Campos-Xavier AB, Medeira A, Cordeiro I, Sousa AB, Lima M, Soares G, Rocha M, Saraiva J, Ramos L, Sousa S, Marcelino JP, Correia A, Santos HG. Clinical and molecular diagnosis of the skeletal dysplasias associated with mutations in the gene encoding Fibroblast Growth Factor Receptor 3 (FGFR3) in Portugal. *Clin Genet*. 2009. 75(2):150-6.
14. Coi A, Santoro M, Garne E, Pierini A, Addor MC, Alessandri JL, Bergman JEH, Bianchi F, Boban L, Braz P, Cavero-Carbonell C, Gatt M, Haeusler M, Klungsøyr K, Kurinczuk JJ, Lanzoni M, Lelong N, Luyt K, Mokoroa O, Mullaney C, Nelen V, Neville AJ, O'Mahony MT, Perthus I, Rankin J, Rissmann A, Rouget F, Schaub B, Tucker D, Wellesley D, Wisniewska K, Zymak-Zakutnia N, Barišić I. Epidemiology of achondroplasia: A population-based study in Europe. *Am J Med Genet A*. 2019.179(9):1791-1798.
15. French T, Savarirayan R. Thanatophoric Dysplasia. In: Adam MP, Ardinger HH, Pagon RA, Wallace SE, Bean LJH, Gripp KW, Mirzaa GM, Amemiya A, editors. *GeneReviews* [Internet]. University of Washington, Seattle; Seattle (WA). 2004.
16. Wenger T, Miller D, Evans K. FGFR Craniosynostosis Syndromes Overview. National Centre for Biotechnological information.
<https://www.ncbi.nlm.nih.gov/books/NBK1455/>
17. Smid CJ, Modaff P, Alade A, Legare JM, Pauli RM. Acanthosis nigricans in achondroplasia. *Am J Med Genet A*. 2018. 176(12):2630-2636.
18. Dai L, Xie L, Wang Y, Mao M, Li N, Zhu J, Kim C, Zhang Y. A novel COMP mutation in a pseudoachondroplasia family of Chinese origin. *BMC Med Genet*. 2011. 21;12:72.