

## Case study

# **Dermatomyositis: A case report and review of clinically diagnosed rare autoimmune disease.**

### **ABSTRACT.**

Dermatomyositis is a rare autoimmune disorder of unknown etiology with sparse globally reported epidemiology. It is an immunologically mediated disease in which damage to small blood vessels contributes to injury and inflammation of muscle and skin. Dermatomyositis belongs to a heterogeneous group of three autoimmune rheumatological diseases termed idiopathic inflammatory non-suppurative myopathies, with polymyopathy and inclusion body myopathy as other component diseases.

Dermatomyositis and polymyositis typically show characteristic clinical features of autoimmune inflammatory disorders, association with autoantibodies, HLA-DR genotype, and other autoimmune diseases. While it is known that inflammation plays a significant role in the pathogenesis of these diseases, its role in inclusion body myopathy remains unclear. Overlapping forms of inflammatory myopathies that defy a precise classification have also been identified. However, the clinical response to steroids and other immunosuppressive agents may help distinguish inflammatory myopathies from these other additional causes.

Dermatomyositis is a multisystemic rheumatologic disease commonly presenting with muscular and cutaneous symptoms. It is associated with malignancy in 20 – 25% of patients. Dermatomyositis occurs in children and adults, with a higher incidence among women. Diagnosis is usually made from clinical manifestations, elevated blood enzymes, autoantibody testing, and muscle biopsy. There is no known cure for Dermatomyositis, but corticosteroids, other immunosuppressive agents, and intravenous immunoglobins are routinely used for treatment.

In developing countries, establishing the clinical diagnosis of Dermatomyositis remains challenging due to several factors. The index patient in this review is a 22-year-old Afro-Caribbean woman whose presentation met the probably-to-definitive diagnosis criteria based on the Bohan and Peter Criteria. This article is a

case report and a detailed review of Dermatomyositis, with emphasizing teaching and research knowledge.

Keywords: Dermatomyositis, Myopathy, autoantibodies, Creatinine kinase.

## **INTRODUCTION.**

Dermatomyositis primarily affects connective tissues in the skin, muscles, and joints. The Incidence of the disease ranges from 2-10 cases/million per annum. Juvenile and adult forms are recognized and documented in the literature. The age of onset for the disease is bimodal: before 16 years of age and after 40 years of age. [1] In the juvenile form, the age of onset is seven years in the USA, with an incidence of three new cases per year (3000 to 5000 children). The adult form of the disease normally presents between the 4<sup>th</sup> to 6<sup>th</sup> decades of life, with ten new cases per year among adults. [1][2] The disease shows a higher incidence in females 2:1 with a peak age between 40 to 50 years. It is also the most common inflammatory myopathy seen in children.[1] However, the prognosis is better in children compared to adults. Black to white ratio is known to be 4:1, with a higher incidence among Japanese. [1]

Patients with Dermatomyositis commonly present with proximal muscle weakness that is slow in onset and associated with myalgias, with a preference for the shoulder and hip joints. Getting up from sitting, climbing stairs, and raising arms over their heads become increasingly difficult for patients. Fine movements controlled by distal muscles may be affected late in the disease. [2][3] All possible clinical manifestations and diagnostic parameters are highlighted in the discussion section.

## **CASE PRESENTATION.**

A 22-year-old Afro-Caribbean female clerk presented to the clinic with a 3-months history of progressive joint pain and proximal muscle weakness. The weakness and pain were worse in the limbs and back, and symptoms were associated with activities like getting up from chairs and climbing stairs. She reported a history of low to moderate-grade fever, weight loss, fatigue, recurring headaches, and

characteristic skin rashes on sun-exposed body areas, especially on the face, neck, and chest (Figure 1a and 1b). She had no history of trauma.

A review of systems revealed sleep disturbance, bilateral visual impairment, a non-productive cough, shortness of breath, chest pain, progressive hair loss, and anxiety. The patient has lumps in her breast suggestive of fibroadenoma and an unspecified neck swelling but no history of surgical evaluation. She was not on any medications and had no history of allergies. Family history was negative for musculoskeletal disorders, autoimmune diseases, skin diseases, hypertension, diabetes, thyroid disorders, or cancer.

A general examination revealed an anxious-looking, febrile, and pale young female with no cyanosis. There was generalized body tenderness, an erythematous rash on the face in the malar area (Figure 1b), and bilateral ankle swelling. The scalp examination shows fluffy hair with sparse hair loss (Figure 1c).

Vital assessments revealed a height of 5 feet 10 inches tall, a weight of 159 pounds, an average BMI of 22.96, blood pressure of 127/78mmHg, pulse rate of 111/min, respiratory rate of 16bpm, and body temperature of 32.8<sup>o</sup>C.

Musculoskeletal examination showed generalized muscle tenderness, weakness, decreased muscle tone, and deep tendon reflexes of +1. The chest was clinically clear, with vesicular breath sounds heard bilaterally. The cardiovascular exam was also normal; S1 and S2 heart sounds were heard, but no murmur.

## Investigations

Blood work reveals leukocytosis 16,000 cells/ml(3000-10,000), with neutrophil count of 14,990(2600-9000).Erythrocyte sedimentation rate(Automated ESR) and C-reactive protein(CRP) are 70mm/hr. (<20) and 24.9 mg/L(normal <3) respectively.

Creatinine phosphokinase kinase (CPK) was significantly elevated at 3164U/L (normal is 25 to 164) on investigations. Antibody testing was positive for the anti-nuclear antibody (ANA) and anti-Jo-1, while anti-dsDNA was negative. Urinalysis, EKG, and chest X-ray showed normal investigation findings. EMG and muscle biopsy were unavailable at the time of presentation and not done for the patient. At the time of follow-up, results of the electrolyte, urea and creatinine level,

serum albumin, liver enzymes, Thyroid stimulating hormone, aldolase, and LDH were available and were all within normal limits.

The patient was initially offered counseling and placed on NSAIDs for pain relief. She was subsequently placed on prednisolone 60mg daily and methotrexate 15mg weekly. Adherence to methotrexate was noted to be poor on follow-up visits, but the overall response to the treatment was good, with a significant drop in CPK levels to 267 U/L. The patient is alive five years after her diagnosis (dating as at December, 2022), with no complications noted on the recent follow-up visit to the clinic.

## **DISCUSSION.**

Dermatomyositis presents with a myriad of clinical manifestations, as seen in this patient, necessitating the use of diagnostic criteria for proper diagnosis. The index patient was diagnosed by adopting a criteria method as we had to contend with ethical issues like lack of consent for biopsy and financial constraints. Prior to her presentation, there was no documented report of a diagnosis of Dermatomyositis in Saint Vincent and the Grenadines from medical records reviewed manually from 2014 to 2020.

The patient met > 65% of the criteria for diagnosing the disease, strengthened by the clinical response to immunosuppressive agents and symptoms/crisis-free status for five years afterward. Electromyograms and muscle biopsies were not readily available in this part of the world. However, the presence of the following was overwhelmingly supportive of a diagnosis of Dermatomyositis in the patient.

- Age of onset (18 years).
- Progressive proximal muscle weakness.
- Myalgia
- Joint involvement.
- Skin manifestations, particularly around sun-exposed areas of the body.
- Reduced muscle tone and reflexes.
- Weight loss, fatigue, and pulmonary manifestations suggestive of restrictive lung disease.
- Markedly elevated serum creatine kinase.

- Positive anti-nuclear and anti-Jo-1 antibodies.
- An excellent response to immunosuppressive agents is typical of the disease.
- Presence of laboratory inflammatory markers like Leukocytosis, elevated ESR and CRP.
- 95% 5-year survival rate.

Dermatomyositis is an autoimmune, non-contagious, inheritable disease associated with MHC class 2 genes acting via HLA-B8/DR3, DR6, and DR52 as a result of producing antibodies like anti-nuclear antibody (ANA, 80%), Rheumatic factors (Rh factor, 10%), anti-Mi (skin manifestations), and most specifically anti-synthetase antibody called Anti-Jo1(20 -50%).[4][5]

The following criteria are enough to make a diagnosis of Dermatomyositis as proposed by Bohan and Peter (1975) using the presence of progressive proximal symmetrical weakness, elevated levels of muscle enzymes, abnormal findings on electromyography, abnormal muscle biopsy findings, and skin manifestations (see Table 1a and 1b).[5] The presence of skin involvement differentiates Dermatomyositis from polymyositis, inclusion body myositis, and undifferentiated myopathies.[4][5][6]

<b>1. Symmetrical proximal muscle weakness</b>
<b>2. Muscle biopsy evidence of myositis</b>
<b>3. Elevation in serum skeletal muscle enzymes</b>
<b>4. Characteristics of electromyography pattern of myositis</b>
<b>5. Typical rash of Dermatomyositis</b>

Table 1a: Bohan and Peter criteria for diagnosis of Dermatomyositis.

Interpretation
<b>Definite: 5 plus any three of 1 - 4</b>
<b>Probable: 5 plus any two of 1 - 4</b>
<b>Possible: 5 plus any one of 1 - 4</b>

Table 1b: Categorization of diagnosis.

#### CLINICAL MANIFESTATIONS.

Dermatomyositis is also known to present with unspecific clinical manifestations, and these may include [7] [8] [9] [10] [13]:

- Cutaneous symptoms: heliotrope rash – a lilac-colored discoloration of the eyelids with periorbital edema (90%), malar rash, Gottron papules, photosensitivity, and scaling erythematous eruption or dusky red patches over knuckles, elbows, and knees.
- Oropharyngeal muscle weakness manifests as dysphagia, dysphonia with a nasal voice, and esophageal dysmotility (10-30%).
- Raynaud's phenomenon.
- Arthralgia/arthritis (20%).
- Interstitial lung disease (>20%).
- Myocardial involvement (myocarditis, arrhythmias, and abnormal EKG findings).
- Constitutional symptoms such as fever and weight loss.
- Associated malignancies, including breast, colon, lung, ovarian, melanoma, non-Hodgkin, nasopharyngeal (Asians), and gastric (**Westerns**), may occur five years after the onset of symptoms or predate myositis. Screening for malignancies is thus mandatory in patients. [5][13]

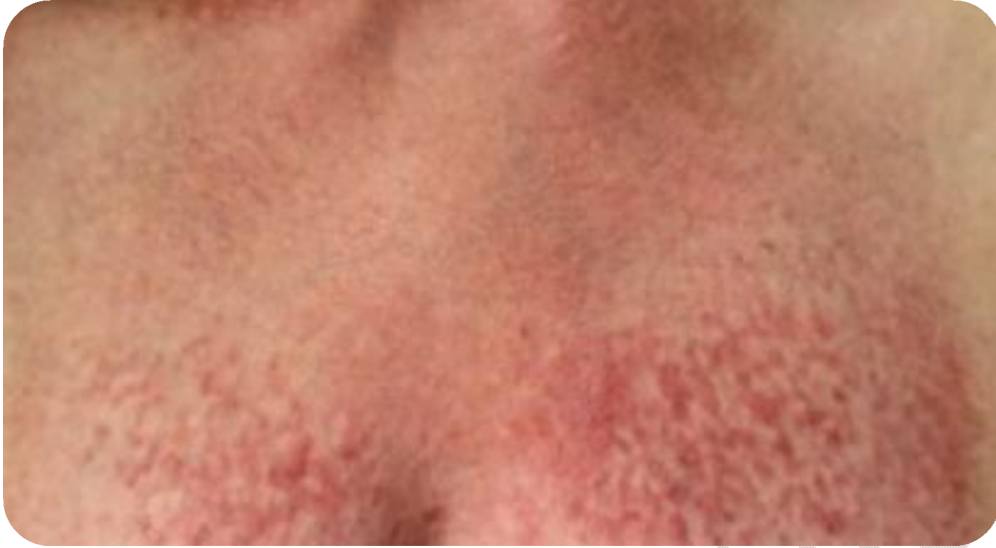

Figure 1a. The patient presented with shallow, crusted blistering in the neck and chest regions (Shawl's sign)—courtesy: Caribbean kidney and medical center, Saint Vincent and the Grenadines.

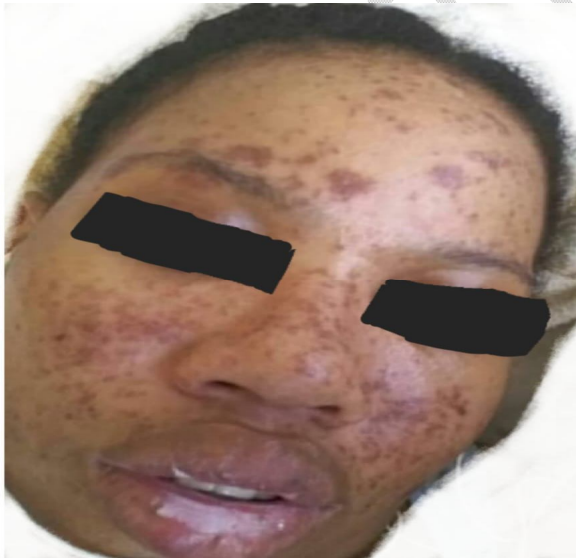

Figure 1b. In the early phase of the disease, the patient presented with crusted blistering (red spots) on the face, marked at the malar area (Malar rash) spreading to nasolabial folds, and swollen lips. Courtesy: Caribbean kidney and medical center, Saint Vincent and the Grenadines.

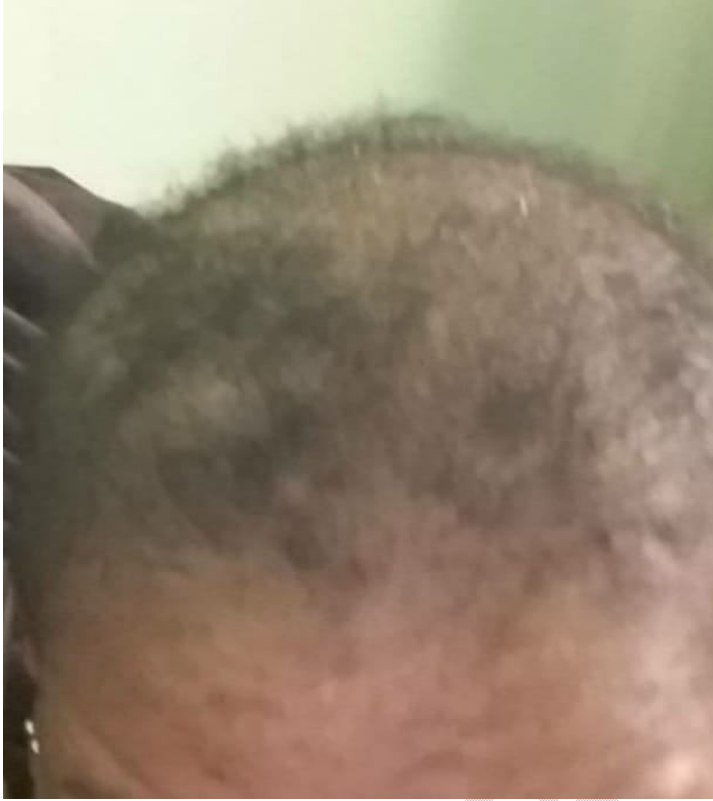

Figure 1c. The patient presented with spatial hair loss seven months after the disease onset (alopecia).

Courtesy: Caribbean kidney and medical center, Saint Vincent and the Grenadines.

There are numerous challenges in making the diagnosis of immunological diseases difficult and complex in developing countries ranging from poor knowledge to unavailability of appropriate diagnostic techniques. Thus, physicians must have a high index of suspicion to diagnose the disease because of its excellent clinical response to corticosteroids with early detection. [11][12]

Complete blood count may show lymphocytosis, especially during flare episodes, while ESR and C-reactive protein may be elevated. Myoglobinuria is rarely seen. In addition, a variety of enzymes are elevated in Dermatomyositis. Creatine Phosphokinase (CPK), lactate dehydrogenase, aspartate transaminase, alanine transaminase, and aldolase are commonly elevated due to muscle damage, with CPK and aldolase being the most sensitive. [12]

## AUTOANTIBODIES IN DERMATOMYOSITIS.

Dermatomyositis is purely immunological, being autoantibody related. Evidence-based medicine has, over the years, suggested various levels of immunogenesis and the roles of antibodies in the evolution of the disease. Auto-antibodies that are commonly associated with Dermatomyositis include: [10][12] [13]

- ANAs positivity is present in >80% of patients,
- Rheumatoid factor is usually positive in about 50% of patients.
- Anti-Mi-2 antibodies- are seen in <5% of patients and strongly associate with prominent Gottron papules and heliotrope rash.
- Anti-tRNA synthetase antibody (Anti Jo-1,) – directed against the enzyme histidyl t-RNA synthetase, is more specific and seen in more than 80% of the patients, especially those likely to develop interstitial lung disease, non-erosive arthritis, and mechanic’s hands.
- Other rarely found antibodies are anti-TIF1y, anti-NXP2, and anti-SAE associated with pulmonary fibrosis, anti-P155/P140 antibodies directed against transcription factors, and anti-MDA5, which is known to be the rarest antibody associated with Dermatomyositis.

<b>Antibodies</b>	<b>Function</b>	<b>Manifestations</b>
<b>Anti-Mi-2</b>	Regulation of gene transcription	Markedly elevated serum CK level.[12][13]
<b>Anti-Tnf-1</b>	Cell growth or differentiation, carcinogenesis.	Cancer risk; extensive skin lesion[6][13]
<b>Anti-MDA5 (CADM-140)</b>	Antiviral innate immunity	Rapidly progressive ILD; skin ulcer; palmer papule.[6][12]
<b>Anti-SAE</b>	Post-translational modification	Skin Lesion prior to muscle symptom; mostly adult.[13]
<b>Anti-NXP2</b>	Regulation of gene transcription	Calcinosis Cutis; subcutaneous edema, severe muscle symptoms.[6][12][13]

Table 2: Autoantibody specific to Dermatomyositis.

## BIOPSY AND ELECTROMYOGRAPHY FINDINGS IN DERMATOMYOSITIS.

Electromyography may show abnormality in active myositis and normal findings in the inactive stage of the disease. A triad of changes is usually seen in active myositis;

- spontaneous fibrillation potentials at rest
- short-duration potentials on voluntary muscle contraction
- repetitive potentials on mechanical stimulation of nerves.

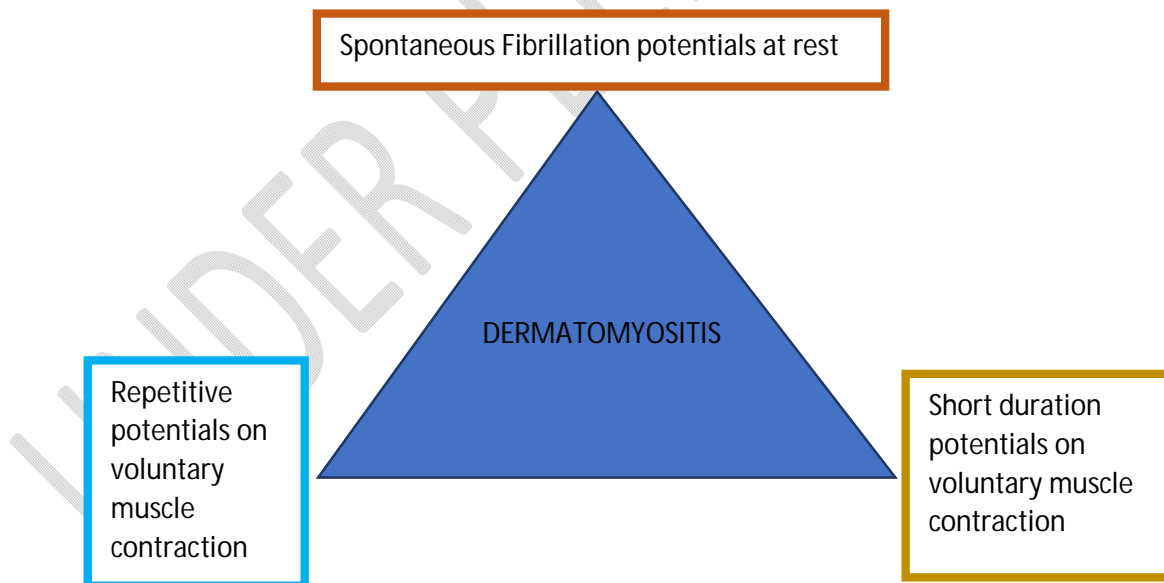


Figure 2: Diagrammatic representation of EMG findings in Dermatomyositis (Triad of changes).

Diagnosis of the disease is usually confirmed with muscle biopsy findings of a predominantly mononuclear inflammatory cell (B-cells and CD4+ lymphocytic cells) infiltration in the perifascicular, perimysial, and perivascular regions, unlike in polymyositis which shows CD8+ cells infiltration in the endomysial region. Perifascicular myofiber atrophy, segmental fiber necrosis, and regeneration are also seen. [7] Immunohistochemical studies may reveal a rich T lymphocytic cell infiltration and deposition of complement membrane attack complex (C5b-9) in the capillary beds of affected tissues. Electron microscopy may show tubuloreticular endothelial cell inclusions. [11]

Other investigations help evaluate the course of the disease, its complications, and associated malignancies. Chest X-ray, CT-Scan of the abdomen and pelvis, PET scan, Papanicolaou smear, urinalysis, CA-125, and stool occult blood testing are done for these indications. [1]

#### CLASSIFICATION.

Various forms of classification have been documented in the literature depending on the region and specialization of the authors. The six subtypes itemized below, however, describe the most common classification. [2][3][13]

1. Classical Dermatomyositis: muscle and joint involvement with characteristic skin involvement described below;
  - Malar rash - violaceous erythematous rash
  - Heliotrope rash - purple/erythematous rash
  - Gottron papules - raised papules in the joint
  - Periungual /cuticular vascular dilatation
  - Shawl sign (poikiloderma) - atrophy, reddening, and dyspigmentation in the face, neck, and upper chest regions.
2. Amyopathic Dermatomyositis with no muscle involvement.
3. Hypomyopathic Dermatomyositis - with myopathic symptoms < 6 months in patients.
4. Juvenile Dermatomyositis usually occurs before 16 to 18 years.
5. Polymyositis is strictly muscular and joint involvement without skin manifestations.

6. A dermatopathic subtype – with clinical manifestations but no histological findings.

## **MANAGEMENT**

Clinical management of Dermatomyositis is mostly done with anti-inflammatory and immunosuppressive agents. Pharmacological and non-pharmacological therapy are available to reduce associated morbidity and mortality and improve the quality of life in patients. Clinical trials on the use of stem cell transplantation and cannabinoid receptor type 2 (CB2) agonist medications with curative intent are in progress [9][11]. Non-pharmacological therapy usually involves psychiatric evaluation, counseling, bed rest, physical therapy in graded exercise programs, plasmapheresis, and occupational therapy. [1][11]

Pharmacological treatment options for Dermatomyositis include corticosteroids (oral prednisone) as a first-line therapy. Immunosuppressive agents (azathioprine, methotrexate) are used as the second-line therapy for steroid-resistant cases or as steroid-sparing agents. Third-line treatment options include intravenous immunoglobulin, cyclophosphamide, cyclosporin, mycophenolate mofetil, and biological agents (infliximab, rituximab, and etanercept). The supportive treatment options in these patients include topical tacrolimus and hydroxychloroquine for skin disease, vitamin D supplementation and use of bisphosphonates, and chemoprophylaxis for pneumocystis pneumonia. [8][9] [11]

More diagnostic and treatment options may be instituted in the nearest future, such as specific antibody testing, muscle biopsy, electromyogram, mental health evaluation, and treatment with cannabinoid receptor Type 2 (CB2) agonists and stem cell transplant from evidence-based clinical trials[11][12].

## **CONCLUSION.**

Dermatomyositis is classified as an autoimmune inflammatory myopathy with characteristic cutaneous manifestations from other forms. However, the disease presentation is not always typical, making the diagnosis challenging for

physicians, especially in developing countries. Physicians thus need to have a high index of suspicion for early detection and consider its diagnosis due to the associated risk of malignancies and other complications. Before the advent of corticosteroids and immunosuppressive therapy, the disease had a high mortality rate (up to 50%). Associated mortality is also poor in the presence of co-morbidities and complications, including old age > 65 years, malignancies, and cardiovascular and pulmonary diseases. However, with early detection and no significant complications, the 5-year survival rate for adult patients improves to about 90%. In the nearest future, more specific diagnostic options and practical treatment guidelines with cannabinoid receptor Type 2 (CB2) agonists and stem cell transplants, presently in clinical trials, may, however, become available to improve the clinical outcomes in these patients.

#### **DISCLAIMER**

There is no conflict of interest between the authors, facilities, and the government. The research is solely for academic purposes in advancing medical knowledge with the sole aim of improving the lives of our patients. Also, no financial support from any source exists, and the Authors solely fund it.

#### **CONSENT AND ETHICAL APPROVAL**

The Ministry of Health and Wellness, Saint Vincent the Grenadines, approved the research works.

Consent form signed by the patient, witness, and physicians.

#### **REFERENCES**

1. Springer, Berlin, Heidelberg. Epidemiology of Dermatomyositis.(2009)  
Online ISBN978-3-540-79313-7.
2. Reid Waldman, Madeline E. DeWane, Jun Lu. Dermatomyositis: Diagnosis and treatment, Journal of the American Academy of Dermatology, Volume 82, Issue 2, 2020, Pages 283-296,  
ISSN 0190-9622,  
<https://www.sciencedirect.com/science/article/abs/pii/S0190962219323084>

3. Morganroth PA, Kreider ME, Okawa J, Taylor L, Werth VP. Interstitial lung disease in classic and skin-predominant Dermatomyositis: a retrospective study with screening recommendations. *Arch Dermatol.* 2010 Jul;146(7):729-38. doi: 10.1001/archdermatol.2010.134. Erratum in: *Arch Dermatol.* 2010 Oct;146(10):1197. PMID: 20644033; PMCID: PMC3010864.
4. Ravi D, Prabhu S, *Clinical Dermatology Review*, Wolters Kluwer Medknow Publications. Dermatomyositis: A dermatological perspective. January 1, 2019 Volume: 3, Issue: 1, Page: 18-22.
5. Marvi U, Chung L, Fiorentino DF. Clinical presentation and evaluation of Dermatomyositis. *Indian J Dermatol.* 2012 Sep; 57(5):375-81. doi: 10.4103/0019-5154.100486. PMID: 23112358; PMCID: PMC3482801. <https://www.ncbi.nlm.nih.gov/pmc/articles/PMC3482801/>
6. Uruha, Akinori & Suzuki, Shigeaki & Nishino, Ichizo. Diagnosis of Dermatomyositis: Autoantibody profile and muscle pathology. *Clinical and Experimental Neuroimmunology.* (2017).8. 10.1111/cen3.12419. [https://www.researchgate.net/figure/Autoantibodies-specific-to-dermatomyositis\\_tbl1\\_320326344](https://www.researchgate.net/figure/Autoantibodies-specific-to-dermatomyositis_tbl1_320326344)
7. Qudsiya Z, Waseem M. Dermatomyositis. [Updated 2022 August 8]. In: StatPearls [Internet]. Treasure Island (FL): StatPearls Publishing; 2022 Jan-.
8. Bendewald MJ, Wetter DA, Li X, Davis MD. The incidence of Dermatomyositis and clinically amyopathic dermatomyositis is a population-based study in Olmsted County, Minnesota. *Arch Dermatol.* 2010 Jan;146(1):26-30. doi: 10.1001/archdermatol.2009.328. PMID: 20083689; PMCID: PMC2886726.
9. Quain RD, Werth VP. Management of cutaneous Dermatomyositis: current therapeutic options. *Am J Clin Dermatol.* 2006; 7(6):341-51. doi: 10.2165/00128071-200607060-00002. PMID: 17173468.
10. Tersiguel AC, Longueville C, Beltan E, Vincent T, Tressières B, Cordel N. P

[Prevalence of cancer in the Afro-Caribbean population presenting Dermatomyositis and anti-synthetase syndrome: a preliminary study conducted at Pointe-à-Pitre University Hospital, [2000-2012]. *Ann Dermatol Venereol*. 2014 Oct;141(10):575-80. French. doi: 10.1016/j.annder.2014.04.112. Epub 2014 May 17. PMID: 25288059.

11. Philip N. Velderman, MD, Leslie A. Bruch, MD, George V. Lawry, MD. Identifying and Managing Dermatomyositis. August 25, 2008. Vol 25 No 9, Volume 25, Issue 9
12. Hodgkinson LM, Wu TT, Fiorentino DF. Dermatomyositis autoantibodies: how can we maximize utility? *Ann Transl Med*. 2021 Mar;9(5):433. doi: 10.21037/atm-20-5175. PMID: 33842654; PMCID: PMC8033377.
13. Ricceri F, Prignano F. Gottron papules: a pathognomonic sign of Dermatomyositis. *CMAJ*. 2013 Feb 5; 185(2):148. doi: 10.1503/cmaj.111791. Epub 2012 July 23. PMID: 22825999; PMCID: PMC3563888.

UNDER REVIEW