

## **Case report**

### **A case study of gastroparesis in a patient with new Coronavirus infection after rectal cancer surgery**

#### **Abstract**

#### **Background**

Gastric manifestations of SARS-CoV-2 infection are not uncommon and may even precede respiratory symptoms. Common gastrointestinal symptoms include loss of appetite, diarrhea, nausea, vomiting and abdominal pain.

**Case Presentation:** A 50-year-old male patient complained of "blood in the stool and tenesmus for half a year" and was admitted to the hospital on March 2, 2023. Half a year ago, the patient had blood in the stool without obvious incentives, the bleeding was bright red, the habit of defecation changed, the stool became thinner, and the frequency of defecation increased, 3-5 times a day, and the amount was not much. At that time, he went to a regular medical institution for any treatment measures.

**Key Words:** Covid 19; rectal surgery; postsurgical gastroparesis syndrome;

#### **Introduction:**

Colorectal cancer (CRC) often causes systemic symptoms like blood in the stool, diarrhoea, and pain in the abdomen. This type of cancer has a high morbidity and mortality rate. The key to the treatment of CRC lies in early detection, timely diagnosis, and radical surgery, and surgical treatment is still the first choice for radical treatment. Surgery has developed rapidly in recent years and has played an important role in the treatment of CRC. For patients with traditional laparoscopic surgery or open surgery, very common postoperative complications include anastomotic leakage, anastomotic bleeding, incision infection, incision

**Comment [GA1]:** There is no references in this manuscript section, and it should be based in a comprehensive review of the literature.

bleeding, intestinal obstruction, ureteral injury, and other related complications.

However, there are no cases of gastroparesis after rectal cancer surgery at home or abroad. This study discusses a case of gastroparesis complications in a patient with low rectal cancer surgery combined with a new coronavirus infection.

Formatted: Highlight

Comment [GA2]: A quick search of Gastroparesis after colorectal surgery, reveals multiple papers addressing this topic

Formatted: Highlight

### Case Presentation:

A 50-year-old male patient complained of "blood in the stool and tenesmus for half a year" and was admitted to the hospital on March 2, 2023. Half a year ago, the patient had blood in the stool without obvious incentives, the bleeding was bright red, the habit of defecation changed, the stool became thinner, and the frequency of defecation increased, 3-5 times a day, and the amount was not much. At that time, he went to a regular medical institution for any treatment

Comment [GA3]: Be consistent with the font and size used, follow instructions for authors

Comment [GA4]: Which hospital, and where?

Formatted: Highlight

Comment [GA5]: Describe using technical language

measures. The blood in the stool increased, and the number of stools increased significantly compared with before, about 8-10 times. There was no paroxysmal abdominal pain and radiating pain, and no symptoms such as anal cessation of defecation or exhaust. In previous examination we can see flat abdomen, abdominal breathing, no gastrointestinal pattern, and peristaltic waves; the whole abdomen was soft to the touch; mild tenderness in the left upper quadrant; no obvious mass was palpable; no muscle tension; and rebound tenderness.

Auxiliary examination: electronic colonoscopy (2023-03-05): the rectum (5-8cm away from the anal verge when the mirror is withdrawn) sees an irregular mass in about 2/3 of the intestinal cavity, which is fragile and easy to bleed when touched by the mirror body. Endoscopic ultrasonography of the rectum: rectal cancer, T3N1Mx. Enhanced abdominal CT (2023-03-04): rectal space-occupying (the possibility of Ca is high), peripheral exudation changes, multiple enlarged and small lymph nodes, uniform thickening of the bladder wall; a small

Comment [GA6]: ?

Comment [GA7]: ...mass?

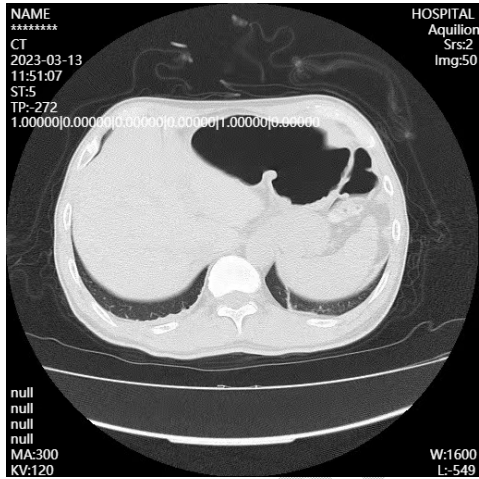
amount of pelvic fluid. Pathology: moderately differentiated adenocarcinoma of the rectum. After consultation and discussion, it was clear that there were no surgical contraindications. On March 10, 2023, the person had laparoscopic radical rectal cancer surgery (Dixon) while under general anaesthesia. One week after the operation, the patient developed a fever with a body temperature of 38.9°C. Procalcitonin, bacterial culture of drainage material, sputum culture, a new coronavirus throat swab, urine routine, and other examinations ~~are~~ were needed to further clarify the cause of the patient's fever. Inflammation, atelectasis is possible. Afterwards, Nirmatevir and Ritonavir tablets were given orally for antiviral infection. Eight days after the operation, the patient complained of epigastric pain, fullness, nausea, and vomiting, and he took the iohexol contrast agent orally during the abdominal X-ray examination. A large amount of gastric retention was observed, and there was an obvious gastric emptying disorder. After the diagnosis of postoperative gastroparesis, the patient was instructed to fast immediately, decompress the stomach and intestines, perform gastric lavage with 3% hypertonic warm saline intermittently, encourage more activities on the ground, and provide timely parenteral nutrition support to reduce the burden on the digestive tract, and at the same time give morphine and mosapride to promote gastric motility. After symptomatic treatment, the patient's above-mentioned symptoms were significantly relieved 15 days after the operation, and the novel coronavirus antigen turned negative. After the gastric tube was removed, the patient resumed eating without complaining of discomfort and was discharged from the hospital 20 days after the operation.

Formatted: Highlight

**Comment [GA8]:** It has not been described a previous coronavirus swab, neither a clinical assessment of pulmonary/respiratory symptoms.

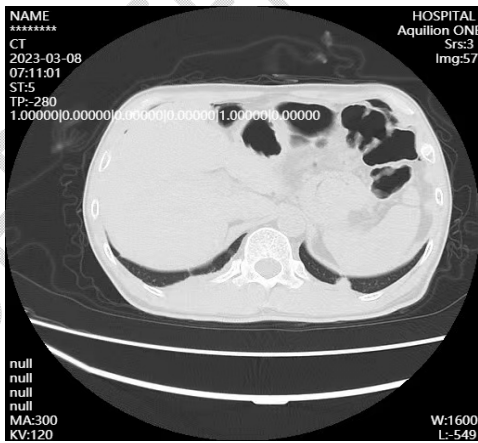
Formatted: Highlight

Formatted: Highlight



**Fig .1 Chest CT 7 days after operation**

**Comment [GA9]:** Each figure should have a concise description of what it wants to show. Do no assume everybody is a radiologist



**Fig .2 Chest CT 13 days after operation**

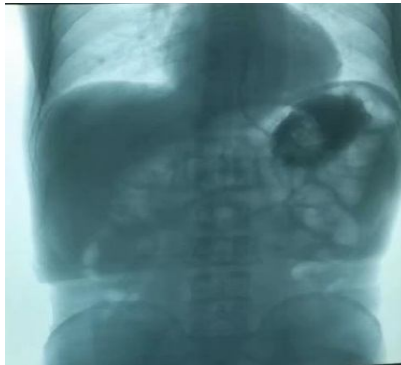
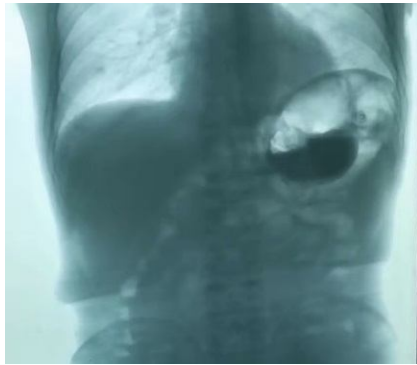
Fig .3Abdominal X-ray 7 days after surgeryFig .4Abdominal X-ray 13 days after surgery

## Discussion

Comprehensive treatment that focuses on surgery is an important way to treat colorectal cancer and give it a chance of being cured. However, surgery will also bring corresponding complications while removing the cancer focus. The more common complications of gastrointestinal surgery include postoperative gastroparesis, also known as postsurgical gastroparesis syndrome (PGS), which is characterised by non-mechanical obstruction of gastric emptying after abdominal surgery. Gastric motility syndrome [1]. According to the time of onset, PGS can be divided into acute and chronic forms, of which acute is more common. Acute PGS occurs 1–2 days after eating; chronic gastroparesis often occurs weeks, months, or even years after surgery [2]. According to reports, after colorectal surgery, PGS is more common after right colon cancer, with an incidence rate of 1.9% to 3.8% [3, 5]. After gastrointestinal surgery, early satiety, nausea, postprandial abdominal distension, and other clinical symptoms of dyspepsia will appear in patients at the initial stage, which are highly similar to the initial symptoms of postoperative

gastroparesis [6], which are often easily ignored by clinicians and lead to aggravation of the condition. The most common postoperative complications of rectal cancer are anastomotic stenosis, intestinal obstruction, and anastomotic leakage. At present, there are no related literatures reporting cases of gastroparesis after operation for low rectal cancer. This article provides the case of a patient who was positive for the new coronavirus after rectal cancer surgery and developed gastroparesis. The purpose is to explore and review the literature on the role of the new coronavirus on the gastrointestinal tract. Corona viruses include a large family of viruses that can cause patients to progress from the common cold to more severe diseases such as Middle East Respiratory Syndrome (MERS) and Acute Respiratory Syndrome (SARS) [7]. In December 2019, a novel coronavirus that had never been found in humans before was discovered in Wuhan, China.

And it's been linked to a new respiratory syndrome called COVID-19. The disease spread so rapidly that cases were reported all over the world in a short period of time, and it was declared a pandemic by the World Health Organization and became the sixth public health emergency of international concern. The main symptoms of 2019-nCoV infection include fever, dry cough, fatigue, shortness of breath, and other respiratory symptoms [8–11]. However, some foreign evidence shows that some patients with 2019-nCoV infection also have gastrointestinal manifestations. Sellevoll et al. reported a woman who was first diagnosed with suspected cholecystitis. When she was admitted to the hospital, she complained of acute abdominal pain and did not have any symptoms of respiratory tract infection. However, the final examination results suggested that the new coronavirus test was positive [12]. A foreign study of pregnant women infected

Formatted: Highlight

Comment [GA10]: Several papers report this complication after the treatment of colorectal cancers, please explain

Comment [GA11]: This citation refers to SARS-Cov2 in pregnant women

with SARS-CoV-2 showed that in addition to respiratory-related symptoms, there were also gastrointestinal symptoms such as abdominal pain, nausea, vomiting, and diarrhea [13–14]. In addition, there is also evidence that diarrhea is a symptom of COVID-19 in approximately 2% to 33% of patients [15–16]. Chan et al. pointed out that 10.6% of SARS patients and 30% of MERS patients developed diarrhea [17]. Previous studies have shown that MERS-CoV can survive in simulated gastrointestinal fluids and cause intestinal infections. Although the main mechanism of gastrointestinal manifestations caused by the new coronavirus is still unclear, foreign scholars have proposed two possible mechanisms. They believe that SARS-CoV-2, like SARS-CoV, can interact with ACE-2 receptors combined [18]. Pan et al. proposed that SARS-CoV-2 itself can cause a gastrointestinal flora imbalance, which in turn leads to a series of gastrointestinal symptoms in patients [19]. Another possible mechanism is that changes in the composition and function of the gastrointestinal and respiratory microbiota interact. This effect is known as the "gut-lung axis", which may also help explain why patients with COVID-19 often experience gastrointestinal symptoms [20]. There are also literature reports in China that the novel coronavirus can directly attack the stomach and duodenum, leading to inflammatory reactions and intestinal malabsorption. About 11.5% of patients will experience diarrhea, followed by nausea, vomiting, abdominal pain, and other discomforts [21]. Scholars such as Xu Jiabin collected the clinical data of COVID-19 clinical patients and obtained the results through statistical analysis; 25% (12/48) of COVID-19 patients had gastrointestinal symptoms, among which sore throat (7/48) was the most common, followed by Diarrhea (3/48),

## Conclusions

In conclusions we fineout the patients with rectal cancer complicated by a new Coronavirus infection, if the diagnosis is made before surgery, it is recommended that the patients receive a course of neoadjuvant therapy first and then undergo radical surgery according to the situation. If the tumor has already caused the patient to have obvious obstructive symptoms, surgery cannot be postponed, gastric tube placement may be considered before surgery, and postoperative activities should be strengthened while drugs can be given to promote gastrointestinal motility. If the patient is diagnosed during the postoperative recovery period, the fasting time should be extended according to the patient's condition. If the patient has obvious nausea, vomiting, and other discomfort, gastrointestinal decompression should be performed immediately to reduce the burden on the digestive tract. Avoid postoperative gastroparesis and a series of gastrointestinal symptoms.

## References

1. SoykanI, SivriB, Sarosiekl, et al. Demography, clinical characteristics, psychological and abuse profiles, treatment, and long-term follow-up of patients with gastroparesis[J]. Dig Dis Sci, 1998, 43 (11): 2398-2404. DOI: 10.1023/a: 1026665728213.
2. Qin Xinyu, Liu Fenglin. Diagnosis and Treatment of Postoperative Gastroparesis [J]. Chinese Journal of Digestion, 2005, 3(3): 206-208. DOI: 10.3870/j.issn.1001-117X.2008.03.017.
3. DengY, HuangS, HuangM, et al. Gastrocolic ligament lymph-node dissection may increase the incidence of delayed gastric emptying after colon cancer surgery

Comment [GA12]: ?

Formatted: Highlight

with D3 lymphadenectomy[J]. Surg Today, 2021, 51 (6) : 897-905. DOI: 10.1007/s00595-020-02200-6.

4. Ye Zhibin, Zhang Lixiao, Zhang Lifei, et al. Analysis of Influencing Factors of Gastroparesis after Laparoscopic Right Colon Cancer Surgery [J]. Shandong Medicine, 2022, 62 (10): 64-66. DOI: 10.3969/j.issn.1002-266X.2022.10.015.

5. Yue Jing. Analysis of the incidence and influencing factors of postoperative gastroparesis syndrome in patients with colon cancer [J]. Modern Diagnosis and Treatment, 2021, 32 (11): 1687-1689.

6. Parkman HP, Hasler WL, Fisher RS, et al. American Gastroenterological Association medical position statement: diagnosis and treatment of gastroparesis[J]. Gastroenterology, 2004, 127 (5) : 1589-1591. DOI: 10.1053/j.gastro.2004.09.054.

7. Qiao J. What are the risks of COVID-19 infection in pregnant women? The Lancet. 2020;395:760–2. |

Comment [GA13]: Relevance

Comment [GA14]:

8. Huang C, Wang Y, Li X, Ren L, Zhao J, Hu Y, et al. Clinical features of patients infected with 2019 novel coronavirus in Wuhan, China. The lancet. 2020;395:497–506.

9. Wong SF, Chow KM, Leung TN, Ng WF, Ng TK, Shek CC, et al. Pregnancy and perinatal outcomes of women with severe acute respiratory syndrome. AJOG 2004. 191:292–7.

10. Dashraath P, Jeslyn WJL, Karen LMX, Min LL, Sarah L, Biswas A, et al. Coronavirus Disease 2019 (COVID-19) Pandemic and Pregnancy. AJOG. 2020;222:521. |

Comment [GA15]: relevance

11. Rajkumar RP. COVID-19 and mental health: A review of the existing literature. *Asian J Psychiatr.* 2020;52:102066.
12. Sellevoll HB, Saeed U, Young VS, Sandbæk G, Gundersen K, Mala T. Acute abdomen as an early symptom of COVID-19. *TidsskrNorLegeforen.* 2020;10:4045.
13. Chen L, Li Q, Zheng D, Jiang H, Wei Y, Zou L, et al. Clinical Characteristics of Pregnant Women with Covid-19 in Wuhan, China. *N Engl J Med.* 2020;382:e100.
14. Zamaniyan M, Ebadi A, Aghajanpoor Mir S, Rahmani Z, Haghshenas M, Azizi S. Preterm delivery in pregnant woman with critical COVID-19 pneumonia and vertical transmission. *PrenatDiagn.* 2020;10:1002.
15. Liang W, Feng Z, Rao S, Xiao C, Xue X, Lin Z, et al. Diarrhoea may be underestimated: a missing link in 2019 novel coronavirus. *BMJ.* 2020;69:1141–3.
16. Holshue ML, DeBolt C, Lindquist S, Lofy KH, Wiesman J, Bruce H, et al. First case of 2019 novel coronavirus in the United States. *N Engl J Med.* 2020;382:929–36.
17. Wang D, Hu B, Hu C, Zhu F, Liu X, Zhang J, et al. Clinical characteristics of 138 hospitalized patients with 2019 novel coronavirus–infected pneumonia in Wuhan, China. *JAMA.* 2020;323:1061–9.
18. Guan G, Gao L, Wang J, Wen X, Mao T, Peng S, et al. Exploring the mechanism of liver enzyme abnormalities in patients with novel coronavirus-infected pneumonia. *ZhonghuaGanZang Bing ZaZhi.* 2020;28:E002.
19. Pan L, Mu M, Yang P, Sun Y, Wang R, Yan J, et al. Clinical characteristics of COVID-19 patients with digestive symptoms in Hubei, China: a descriptive, cross-sectional, multicenter study. *Am J Gastroenterol.* 2020;115:766–73.

20. Budden KF, Gellatly SL, Wood DL, Cooper MA, Morrison M, Hugenholtz P, et al. Emerging pathogenic links between microbiota and the gut–lung axis. *Nat Rev Microbiol.* 2017;15:55–63.
21. Silva FAFD, Brito BB, Santos MLC, et al. COVID-19 gastrointestinal manifestations: a systematic review. *Rev Soc Bras Med Trop.* 2020 Nov 25;53:e20200714.
22. Xu Jiabin, Chu Mei, Zhong Fan, Guan Chenyu, Liang Yujie, Liao Guiqing. Gastrointestinal symptoms of 2019 coronavirus disease and expression of ACE2 in digestive tract organs **【C】** .461

UNDER PEER REVIEW