

## **Efficacy, safety and tolerability of intralesional vitamin D in the treatment of Libyan cutaneous wart patients**

### **Abstract**

**Background:** Warts are common viral infection of the skin, usually treated with destructive methods like electrocautery, cryotherapy or laser ablation. Topical vitamin D has been used to treat warts with variable success is to evaluate the efficacy of intralesional vitamin D3 linjection in the treatment of common warts.

**Aim of the study:** To assess the efficacy, safety and tolerability of intralesional injection of vitamin D3 in the Libyan patients with cutaneous warts.

**Patients and methods:** The selected warts were injected first with 0.2 ml of lignocaine (20 mg/ml) then; after a few minutes, from 0.1 to 0.4 ml of Vitamin D3 (15 mg/ml) was injected slowly into the base of each wart with a 30-gauge-insulin syringe.

**Results:** The total number enrolled in the study was 36 patients and were equal number in gender. The age of < 18 years was 58.3%. Positive family history of the disease was reported in 47%, while atopy was in 75% of cases. Plantar warts were seen in 50% Palmar in 22% and common warts in 17%. A number of more than 2 lesions was reported in nearly 50% of the patients. A response to treatment was statistically significant and marked improvement and clearance was seen in 89% of cases. Plantar warts were cleared in 84%. Almost all cases of periungual cases were completely resolved. Adverse outcomes, including itching and pain were only observed in 25.0% of cases.

**Conclusion:** Intralesional Vitamin D is highly effective and relatively safe and well tolerate in the treatment of cutaneous warts and it could be a better choice for plantar and periungual warts, children and diabetic patients.

**Keywords:** Warts, vitamin D, intralesional, Plantar, warts, Libya

### **Introduction:**

Warts are benign common proliferations of skin and mucosa (epidermal growths) caused by the human papillomavirus (HPV). Currently, more than 100 types of HPV have been identified.

Warts often cause significant discomfort and embarrassment (1).

Certain HPV types tend to infect the skin at particular anatomic sites; however, warts of any HPV type may occur at any site (2). The primary clinical manifestations of HPV infection include common warts, genital warts, flat warts, and deep palmoplantar warts (myrmecia). Many studies have documented the prevalence of cutaneous warts in children ranging widely from 3.3% in the USA to 33% in the Netherlands (3-5).

Data on the prevalence of cutaneous warts in young adults are limited compared with those in children. In an earlier UK, study with a modest sample size, the prevalence was reported to be 3.5% in people aged 25 to 34 years and 0.3% in those aged 35 to 54 years (6).

Vitamin D has been discovered to show a modulator and regulatory role in multiple processes involving immunity, host defense, inflammation and epithelial repair, in addition to its essential functions in the regulation of calcium homeostasis (7).

Vitamin D also plays a role in various infectious processes. The fact that vitamin D is an immune-modulator plays a major part in the pathophysiology of many conditions the cellular immunity involved with (8).

Warts are benign proliferations of the skin and mucosa caused by infection with human papillomavirus (HPV), which are the most frequently recurring infections (9).

An important mechanism for innate immune influence came with the discovery that vitamin D directly induces human cathelicidin expression via a vitamin D response element located in the promoter region of the cathelicidin gene (10).

The anti-viral effects of vitamin D could be explained by cathelicidin (in the form of LL-37), human beta defensin 2, and perhaps through the release of reactive oxygen species. Similar interactions may occur with the lipid envelopes of viruses.

### **Aim of the study**

- 1) To assess the efficacy, safety and tolerability of intralesional injection of vitamin D3 in the treatment of Libyan wart patients.
- 2) To assess the efficacy of intralesional injection of vitamin D3 in relation to the age group, clinical type of warts, site involved and severity of the disease.

### **Patients and Methods**

In this quasiexperimental longitudinal study, a total of 36 patients attending dermatology department, outpatient clinics at Benghazi medical center were enrolled in this study. Detailed disease history was taken from all patients. A complete dermatological examination was carried out in all patients including hands, feet and face according to the prepared proforma.

Demographic characteristics, description of lesions and past history of atopy or chronic conditions were recorded. Cutaneous warts were diagnosed by history and clinical features. Baseline evaluation was employed at the first visit and the demographic data were recorded. At each visit, every patient's location, number, size and type of wart were recorded. The selected warts were injected first with 0.2 ml of lignocaine (20 mg/ml) then; after a few minutes, 0.2 ml of Vitamin D3 (15 mg/ml) was then injected slowly into the base of each wart with a 30-gauge insulin syringe.

Clinical response was documented at 2 weekly intervals for 4 sessions and 6 months after the last injection. Complete clearance was considered if both treated and distant warts resolved completely. Moderate response if there were 50 to <100% reductions in both size and number of lesions and mild response was considered if response was between 1% and <50%.

Statistical analysis:

Data were analyzed using statistical package for social science (SPSS) version 23. Descriptive statistics: as mean, standard deviation and median were estimated.

Inferential statistics: were applied as needed. Student t test (or Mann-Whitney U test) were used to find the difference between the means of the groups, and Chi-square (X<sup>2</sup>) to find the difference in the distribution of the categorical variables between the groups.

P-value was considered significant when  $\leq 0.05$ .

### **Results**

Among 36 patients included in this study, 18 patients (50%) were males. The age was ranging from 5 years to 45 years ( Mean age 23 years). The commonest age group was 0-10 years ( 47.4%) followed by 21 - 30 years which is seen in 19.7%. Plantar warts were seen in 50% of

cases followed by palmar warts and seen in 22.2% of cases (Fig.1) and the commonest site involved was foot (Fig.2). Figure (3) showed that 47% of patients presented with more than 3 lesions and in 30% they were presented with single lesion. The disease duration of more than one year was recorded in 77% of patients. Warts was reported in other family members in 47% of patients.

Family history of atopy was recorded in 75 % the total cases .Twenty seven percent of patients had positive family history of diabetes mellitus. .

The first dose was enough to clear lesions among 27.8% (Fig.4,5). Average number of doses to achieve complete clearance = 2.1 and clearance was achieved finally among 75.0% of the study population. No significant reactions among 75.0% of the study population. Only pain and mild itching were reported (Fig.6). Figures (7 a and b, 8 a and b, 9 a and b) presented the clinical improvement to intralesional vitamin D in plantar, periungual and common warts. Only male gender was associated with significantly higher rate of final clearance (Table1). Factors associated with statistical significance with first dose clearance were palmoplantar warts and no use of local anesthesia (Table 2).

### **Discussion:**

Williams HC et al (1993) stated that cutaneous warts are benign common condition which involve growth of proliferations of skin and mucosa (epidermal growths) which are caused by the human papillomavirus (HPV)(1).

Kilkenny M. et al (1998) described clinical varieties of cutaneous warts include common warts, genital warts, flat warts, and deep palmoplantar warts (myrmecia)(2). Certain HPV types tend to infect skin at particular anatomic sites; however, warts of any type of warts. The total number enrolled in the study was 36 patients. Both genders were distributed in equal numbers. The age of < 18 years was 58.3%. Positive family history of the disease was reported in 47% while atopy in 75% of cases. Regarding types of warts, plantar warts was seen in 50%, palmar in 22% and common warts in 17%. The number of more than 2 lesions was reported in nearly 50% of patients.

Response to treatment was statistically significant and marked improvement and clearance was seen in 89% of cases. Plantar warts were cleared in 84%. All participating cases of periungual cases were completely resolved.

The first dose was enough to clear lesions among 27.8% and clearance was achieved finally among 75.0% of the study population. Among those, 4 cases (11.1%) showed flare up then clearance. In fact, only one case (2.8%) showed no response. The rate of a complete resolution was higher than the rate reported by Kareem IMA et al (2019) 40%(11), Latif I et al (2021) 65.85% (with as high as 7.32% showed no response at all) (12) and Jain S et al (2021) 60%(13). Anyhow, compared to Raghukumar S et al (2017) , a complete resolution was observed in 90% with no response in 3.33%(14). Nevertheless, the later study had longer duration of follow up; 6 months and higher average number of injections required to achieve a complete resolution; 3.66 against only 2.11 in the present study. In addition, they used 600,000 i.u. in all injections on the contrary to only 9.3% in the present study. The present study used mostly low dose of vitamin D3 (300,000 i.u.) with maximum of 4 sessions of treatment and 9 weeks follow up which is shorter than other studies.

Only male gender was associated with statistically significant higher rate of final clearance (complete resolution); a rate of complete resolution among males was 94.4% and among females was 55.6%.

Nevertheless, a noticeable observed difference in a complete resolution according to the type of warts (Palmoplantar 84.6% versus other types 50.0%) and according to duration of lesion (within one year; 82.1%, longer than one year; 50.0%). However, those differences were not statistically significant. Tendency of more recent lesions to heal was also demonstrated by Fathy G et al (2019) (15).

Factors associated with statistical significance with first dose clearance was palmoplantar warts (38.5% healing for no healing in the other subgroup) and no use of local anesthesia (37.0% healing with no local anesthesia for no healing among those given local anesthesia).

The dose of vitamin D3 of 300,000 i.u. may be considered sufficient for treatment and for economic purpose, no need for larger dose.

Local anesthesia was used in 25.6% of injections. No significant reactions among 75% of the study population. Only pain (16.7%) and mild itching (8.3%) were reported. However, this was noticeable when compared to other studies by Raghukumar S et al (2017) and Jain S et al (2021) as no reactions reported (13,14).

Regarding other options of intralesional treatment modalities, Fathy G et al (2019) found that intralesional vitamin D3 was superior to treatment by Candida antigen(15). Nevertheless, the present study showed higher rate of complete resolution with intralesional vitamin D3 than described by Jain S et al despite the shorter duration and less total dosing.

The ultimate clearance rate of 63.9% (without flare up) demonstrated in this study in comparison with destructive methods was convincing and in some interventions or situations lower. The rate described in this study is close to 66.6% recently demonstrated by Almabrouk A and Duweb G. (2022) (16).

According to Lipke MM./ (006), formic acid gives a rate of clearance of 92% while CO2 laser and glutraldehyde 10% reach 71.0% and 72.0% clearance rates respectively(17). Sterling JC et al (2014) described 64.0%, 70.0 and 80.0% clearance rates for citric acid, pyruvic acid and formaldehyde respectively (18). Bradley A et al (2014) investigated the effect of using Echinacea (purple coneflower) a plant used for remedies and as an immune therapy and achieved 86.0% (19).

The benefit of intralesional vitamin D3 not only restricted to the relatively high clearance rate, but also to the economic value; safety and lower rate of adverse outcomes. The study showed a high clearance rate of planter and periungual warts which are usually not responding, recurring or not responding to other modalities of treatment like cryotherapy.

**Conclusion:** Intralesional Vitamin D is highly effective and relatively safe and well tolerate in the treatment of cutaneous warts and it could be a better choice for plantar and periungual warts, children and diabetic patients.

## Consent

Written consent and right of withdrawal and ensuring confidentiality were issued for every participant.

**Ethical Approval:** As per international standard or university standard written ethical approval has been collected from the Ministry of health and Environment/ scientific committee.

## References

- 1) Williams HC, Pottier A, Strachan D. The descriptive epidemiology of warts in british schoolchildren. *Br J Dermatol* 128, 504–511 (1993).
- 2) Kilkenny M, Merlin, K, Young R [et.al](#); the prevalence of common skin conditions in australian school students: 1. common, plane and plantar viral warts. *Br J Dermatol* 138, 840–845 (1998).
- 3) van Haalen FM., Bruggink SC, Gussekloo J [et.al](#); warts in primary schoolchildren: prevalence and relation with environmental factors. *Br J Dermatol* 161, 148–152 (2009).
- 4) Yamamah GA et al. epidemiologic study of dermatologic disorders among children in south sinai, Egypt *Int J Dermatol* 51, 1180–1185 (2012).
- 5) Silverberg JI, Silverberg NB; The US prevalence of common warts in childhood: a population-based study. *J Invest Dermatol* 133, 2788–2790 (2013).
- 6) Rea JN, Newhouse MI & Halil T; Skin disease in lambeth. a community study of prevalence and use of medical care. *Br J Prev Soc Med* 30, 107–114 (1976)
- 7) Zdrengeha MT, Makrinioti H, Bagacean C [et.al](#); vitamin D modulation of innate immune responses to respiratory viral infections. *Rev Med Virol* 2016; 10:1–12.
- 8) Kearns MD, Alvarez JA, Seidel N, [et.al](#); The impact of vitamin D on infectious disease: a systematic review of controlled trials. *Am J Med Sci* 2015; 349:245–262.
- 9) Nofal A, Nofal E. Intralesional immunotherapy of common warts: successful treatment with mumps, measles and rubella vaccine. *J Eur Acad Dermatol Venereol* 2010; 24:1166–1170.
- 10) Wang TT, Nestel FP, Bourdeau V et al. cutting edge: 1, 25-dihydroxyvitamin D3 is a direct inducer of antimicrobial peptide gene expression. *J Immunol* 2004; 173:2909–2912.
- 11) Kareem IMA, Ibrahim IM, Mohammed SFF [et.al](#); Effectiveness of intralesional vitamin D3 injection in the treatment of common warts: single-blinded placebo-controlled study. *Dermatol Ther.* 2019 may;32(3):e12882.
- 12) Latif I, Sultan J, Aslam A [et.al](#); Role of intralesional vitamin D3 in the treatment of cutaneous warts. *J Cutan Aesthet surg.* 2021;14(4):404-408.
- 13) Jain S, Marfatia YS. A comparative study of intralesional vitamin D3, measles mumps rubella vaccine, and tuberculin purified protein derivative in the treatment of recalcitrant warts: an approach to solve a therapeutic conundrum. *J Clin Aesthet Dermatol.* 2021;14(11):26-34.
- 14) Raghukumar S, Ravikumar BC, Vinay KN [et.al](#). Intralesional vitamin D3 injection in the treatment of recalcitrant warts: a novel proposition. *journal of cutaneous medicine and surgery.* 2017;21(4):320-324.
- 15) Fathy G, Sharara MA, Khafagy AH. Intralesional vitamin D3 versus candida antigen immunotherapy in the treatment of multiple recalcitrant plantar warts: a comparative case-control study. *dermatol ther.* 2019;32(5):e12997.

- 16) Almagrouk A, Duweb G. Comparison of intralesional vitamin D3 injection, 5% KOH cream and their combination in treatment of cutaneous warts. *the Egyptian Journal of Hospital Medicine*, 2022; 88(1): 2593-2598.
- 17) Lipke MM. An armamentarium of treatments. *Clin Med Res*. 2006;4(4);273-293.
- 18) Sterling JC, Gibbs SS, Hussain H [et.al](#); British association of dermatologists' guidelines for the management of cutaneous warts 2014. *Br J Dermatol*. 2014;171(4):696-712.
- 19) Bradley A, Boyle D, Rossidis M. Efficacy of topical agents (se, 5-fu, and imq) for treatment of verruca plantaris: a systematic review. *Pe3diatr Med Mev*. 2013-2014;23:57-67.

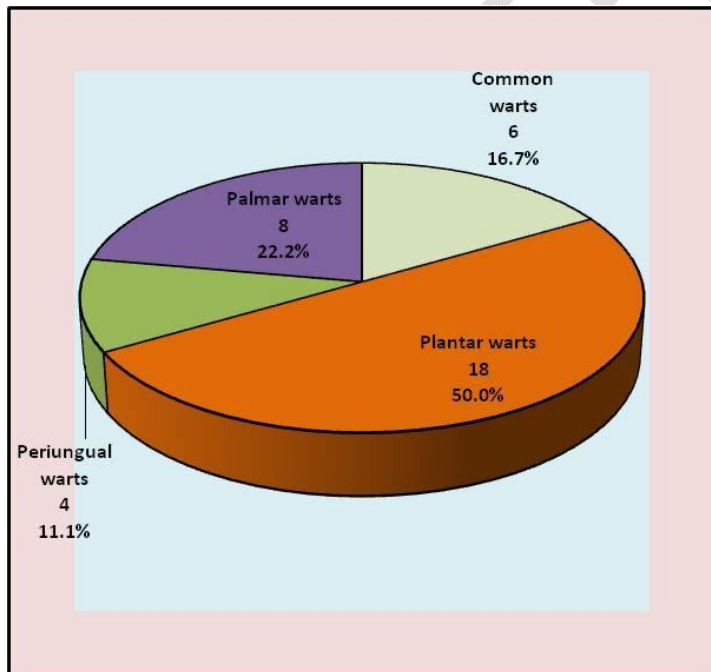


Fig.1: Distribution of clinical types of warts

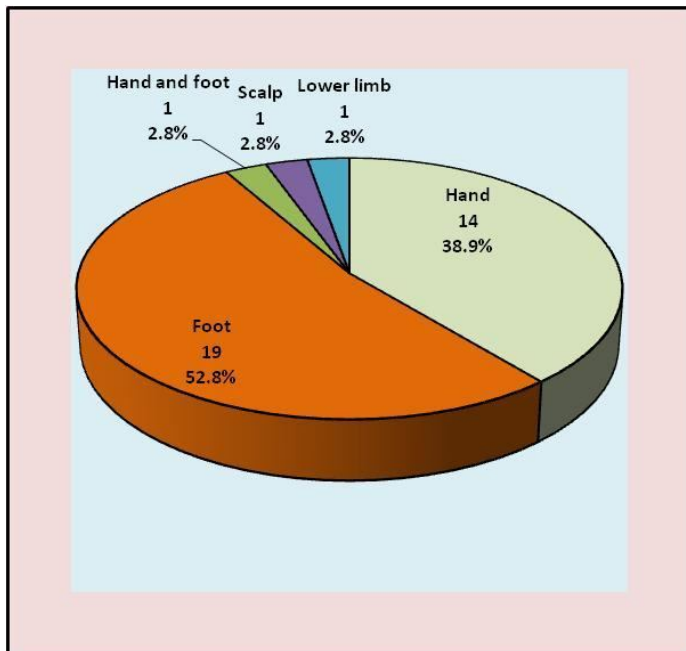


Fig. 2: Distribution of wart sites

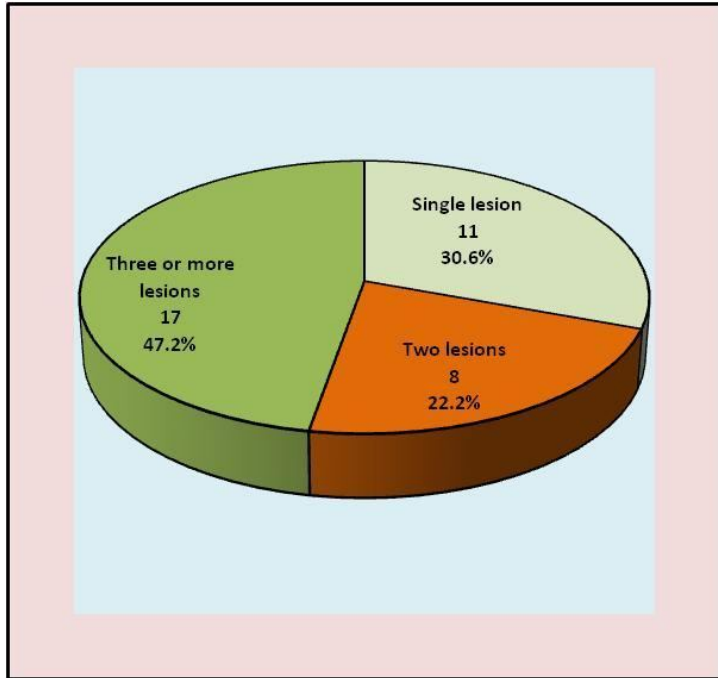


Fig. 3: Distribution of number of lesions

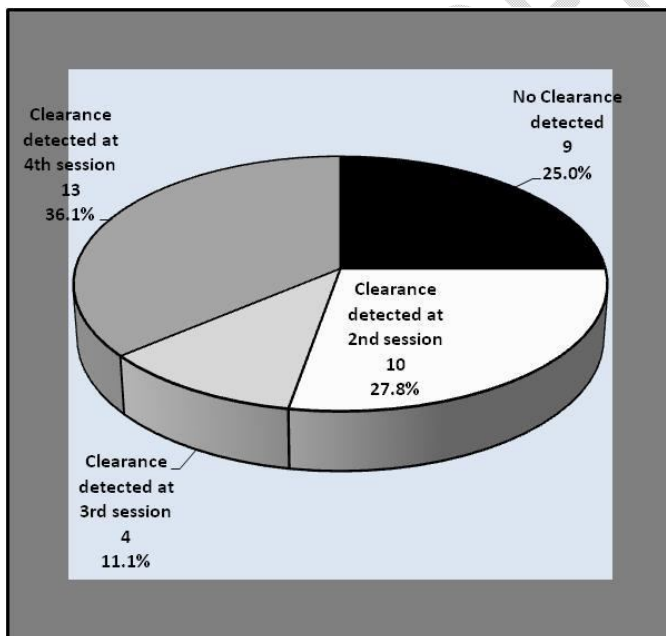


Fig.4: Percentages of clearance of warts to intralesional vitamin D at different sessions

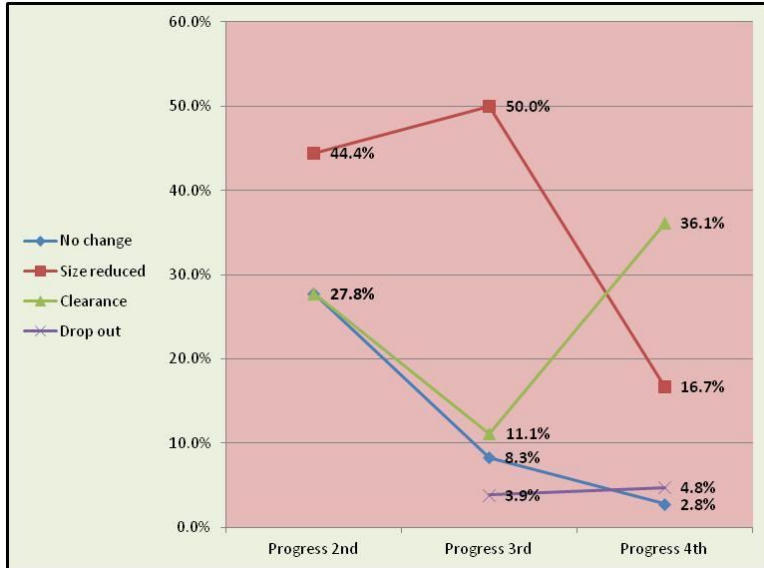
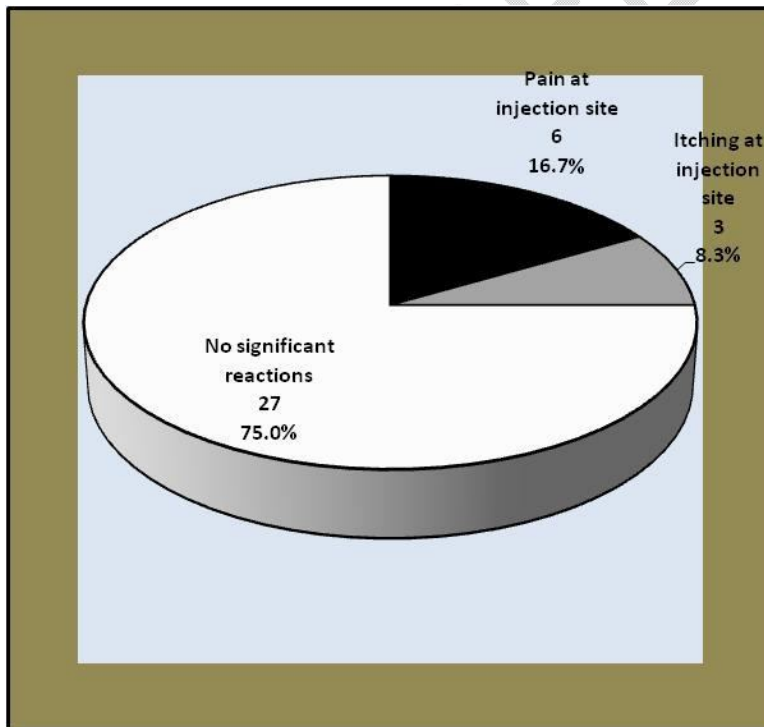
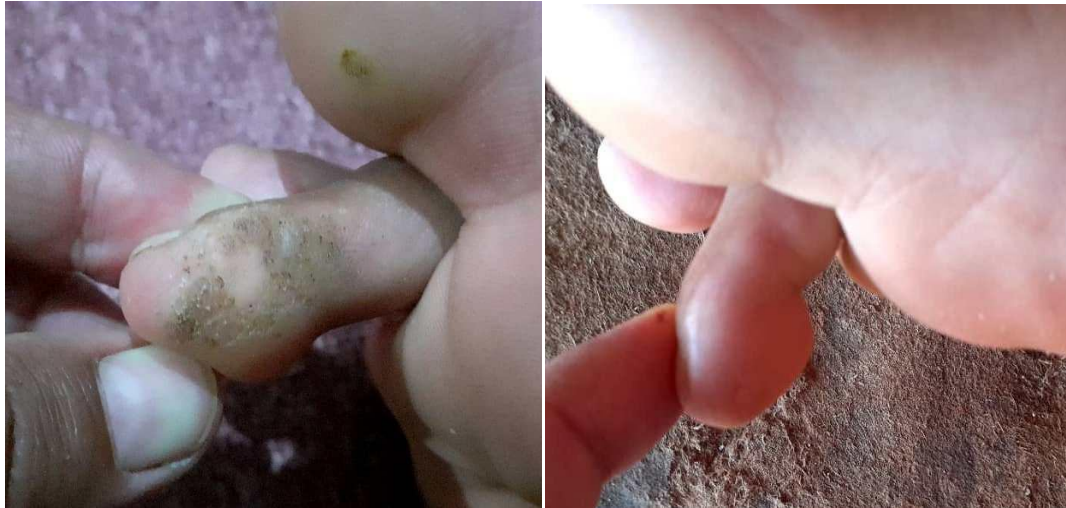

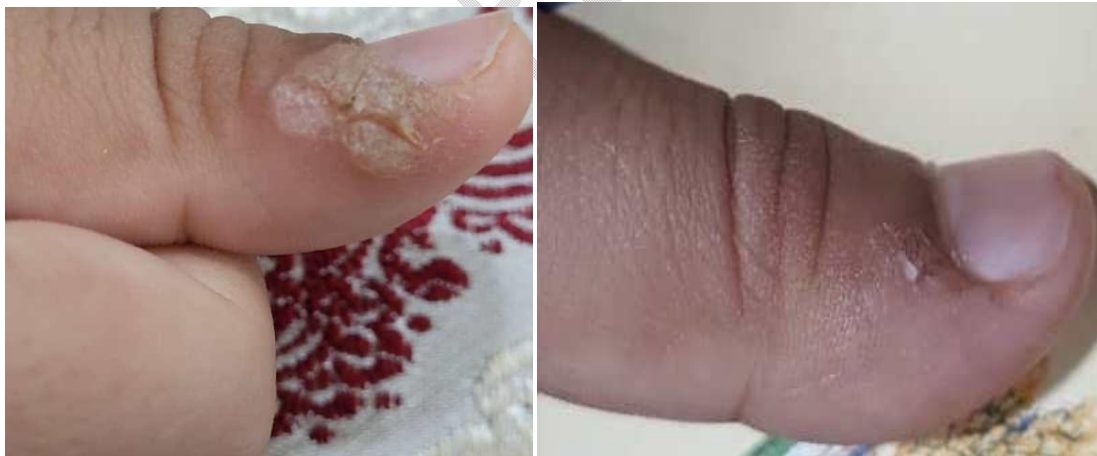Fig. 5: Different responses of warts to intralesional vitamin D at different the sessions



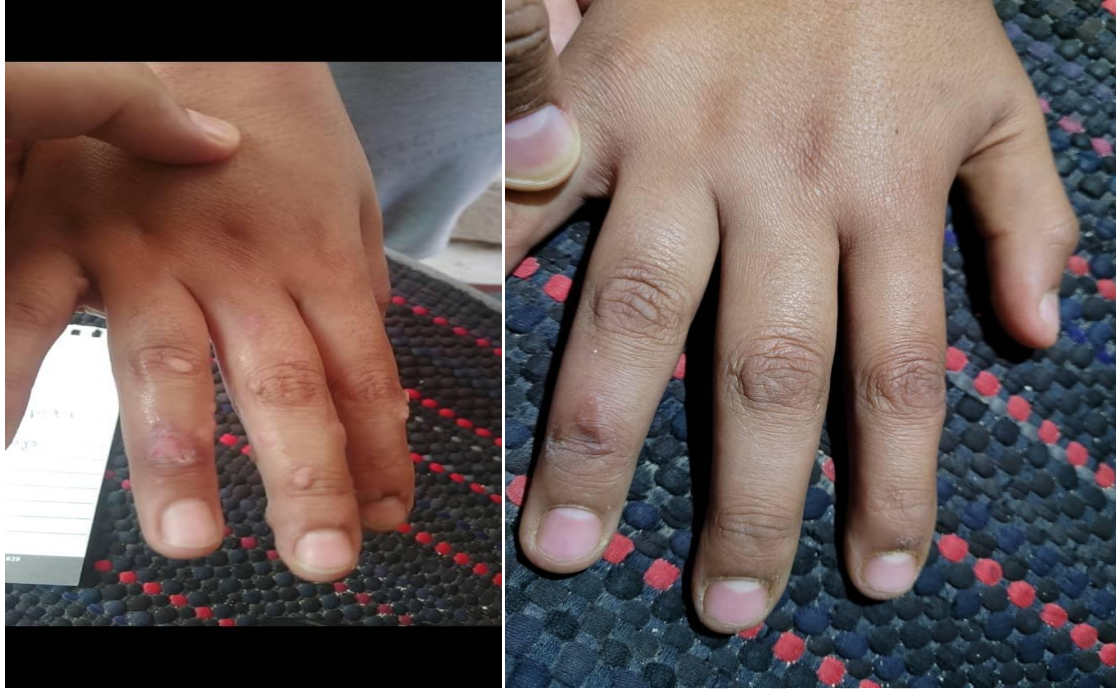**Fig. 6: Side effects of intralesional Vitamin D in the of warts**



**Fig. 7: Plantar wart: Before and after treatment ( Clearmce) with intralesional vitamin D**



**: Fig.8: Periungual warts::Before and after treatment ( Clearance) with intralesional vitamin D**



**Fig. 9: Common warts (multiple)::Before and after treatment ( Clearance) with intralesional vitamin D**

UNDER PEER REVIEW

**Table 1: Analysis of associations of different factors with attaining final clearance**

Factor		Final clearance attained	P
Age	18 years or older	11	1.0
		73.3%	
	< 18 years	16	
		76.2%	
Gender	Male	17	0.018*
		94.4%	
	Female	10	
		55.6%	
Type of wart	Palm plantar warts	22	0.079
		84.6%	
	Other types	5	
		50.0%	
Lesions number	Single lesion	7	0.409
		63.6%	
	Multiple lesions	20	
		80.0%	
Duration	Within one year	23	0.086
		82.1%	
	Longer than one year	4	
		50.0%	
Family history of warts	Positive history	14	0.451
		82.4%	
	No history	13	
		68.4%	
History of atopy	Positive history	19	0.396
		70.4%	
	No history	8	
		88.9%	
Use of LA at 1 <sup>st</sup> session	Local Injection	8	0.396
		88.9%	
	No anesthesia	19	
		70.4%	
Dose of vitamin D3 used at 1 <sup>st</sup> session	600,000 i.u.	7	0.156
		100.0%	
	300,000 i.u.	20	
		69.0%	

\* Significant at level of confidence of 95%, LA local anesthesia

**Table 2: Analysis of associations of different factors with attaining clearance after first dose**

Factor		Clearance attained after first dose	P
Age	18 years or older	6 40.0%	0.26
	Younger than 18 years	4 19.0%	
Gender	Male	5 27.8%	1.00
	Female	5 27.8%	
Type of wart	Palm plantar warts	10 38.5%	0.035*
	Other types	0 0.0%	
Lesions number	Single lesion	4 36.4%	0.454
	Multiple lesions	6 24.0%	
Duration	Within one year	9 32.1%	0.397
	Longer than one year	1 12.5%	
Family history of warts	Positive history	3 17.6%	0.274
	No history	7 36.8%	
History of atopy	Positive history	8 29.6%	1.00
	No history	2 22.2%	
Use of LA at 1 <sup>st</sup> session	Local Injection	0 0.0%	0.039*
	No anesthesia	10 37.0%	
Dose of vitamin D3 used at first session	600,000 i.u.	1 14.3%	0.645
	300,000 i.u.	9 31.0%	

\* Significant at level of confidence of 95% LA local anesthesia

UNDER PEER REVIEW