

## **Case study**

### **A RARE CASE REPORT OF “TORSADE DE POINTS” INDUCED BY CIPROFLOXACIN-FLUCONAZOLE-LEVETIRACETAM COMBINED THERAPY**

#### **Abstract**

Drugs used to treat cardiovascular disease as well as those used in the treatment of multiple other conditions can occasionally produce exaggerated prolongation of the QT interval on the electrocardiogram and the morphologically distinctive polymorphic ventricular tachycardia “torsade de pointe”. “Torsade de pointe” (TdP) is a characteristic polymorphic ventricular arrhythmia associated with delayed ventricular repolarization as evidenced on the surface electrocardiogram by QT interval prolongation. It typically occurs in self-limiting bursts, causing dizziness and syncope, but may occasionally progress to ventricular fibrillation and sudden death. This rare case report showed the potential high risk of the occurrences of Tdp when levetiracetam (KEPPRA) was used in combination therapy with fluconazole which is already a known medication with the risk of causing ventricular arrhythmia.

**Keywords :** Torsades de pointes, prolong QT interval, fluconazole-ciprofloxacin-levetiracetam, magnesium

#### **Introduction**

Torsade de pointes (TdP), a rare polymorphic ventricular tachycardia, is characterized by a gradual change in the amplitude and twist of QRS complexes around the isoelectric line on an electrocardiogram [1,16]. TdP is associated with QTc interval prolongation, which is the prolongation of the QT interval value adjusted for heart rate. Prolongation of the QT interval is one of the major adverse effects of certain medications, as it can lead to sudden cardiac death [2, 18]. Fluconazole is one of many drugs that have the potential to cause QT interval prolongation and/or PDD, either alone or in a drug-drug interaction situation [3, 4]; we report a case of “torsade de pointe” induced by a combination therapy fluconazole in association with levetiracetam (KEPPRA).

#### **Observation:**

A 70-year-old patient with a medical history of pulmonary tuberculosis treated and declared cured 40 years ago, and episodes of convulsive seizures lasting for 2 months was admitted to the intensive care unit for status epilepticus, before tonic seizures - generalized clonic without regaining consciousness between crises. Patient intubated, ventilated with a Glasgow score of 11/15, his initial cardiovascular examination findings was normal (Figure 1).

The complete blood count and the other blood workout assessment were initially normal but with a disturbed CSF balance, which was in favor of bacterial and fungal meningitis (cryptococcus)

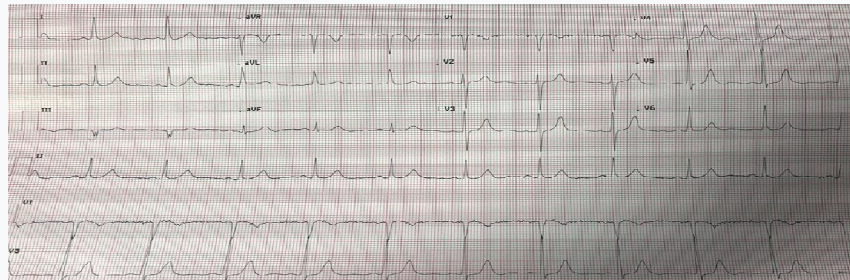


Figure 1:12 leads Electrocardiogram (ECG): Regular sinus rhythm with no conduction disorder

The electrocardiogram and echocardiography were also normal and the cerebral MRI was in favor of Creutzfeldt Jakob disease.

The initial treatment with Imipenem (Tienam) 500mg x 4 a day; doxycillin; triflucan (fluconazole), sodium valproate (depakine) 500mg x 3 par day; Levetiracetam (keppra) 100mg x 3 par day was instituted.

Her clinical outcome on the 8<sup>th</sup> day of Fluconazole and the 21<sup>st</sup> day of KEPPRA treatment was marked by a cardiac complication with the occurrence of torsade de pointes (figure 2).

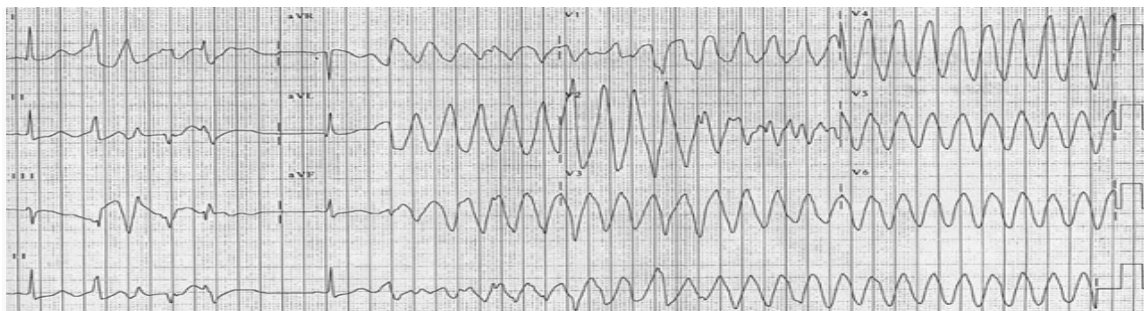


Figure 2: 12-leads Electrocardiogram: Polymorphic ventricular tachycardia “torsades de pointes”

The blood work assessment marked a hypokalemia at 2.6 mEq/l, and normal magnesium level. This cardiac complication was resolved after discontinuation of the offending drugs (fluconazole and keppra), correction of the hypokalemia, magnesium sulphate attack dose of 3g in intravenous followed by maintenance dose of 6g/24h in continuous IV electric syringe perfusion; the evolution being marked by a return to sinus rhythm, the echocardiography carried out concomitantly as well as the troponin were normal.

### **Discussion:**

Torsade de pointes, a rare polymorphic ventricular tachycardia, described in 1996 by François Dessertenne, and associated with prolongation of the QT interval, either congenital or induced by drugs [5]. Many drugs, such as antiarrhythmics, antifungals, different classes of antibiotics, can induce torsade de pointes, alone or in combination [3, 4]. Anti-infectious combination drugs used in several situations that includes treating bacterial and fungal infectious diseases, sometimes combined with antiepileptic drugs in patients with epilepsy. However, some of the agents have the potential to prolong the QTc interval and increase the risk of torsade de pointes [7]. Although cases of torsade de pointes have been reported during treatment with fluconazole alone or in combination therapies such as in combination with antibacterial drugs [4, 6, 17]. To our knowledge, there are no reported cases of “torsades de pointes” induced by fluconazole-levetiracetam combination therapy.

Levetiracetam (Keppra), a new generation of multi-acting antiepileptic drug, which binds to the SV2A protein, can induce QTc interval prolongation, when taken concomitantly with drugs known to prolong the QT interval or in the event of electrolyte disturbances [8, 9, 19]. Electrophysiological studies have demonstrated that the main mechanism by which drugs prolong individual action potentials and which manifests itself on the baseline ECG as an elongation of the QT interval is the blockade of potassium channels specific to the heart [10]. These potential effects are increased by drug interactions linked to the inhibition of

cytochrome P450 [10, 11] as well as other risk factors predisposing patients on these drugs to develop ventricular arrhythmia, these factors include female sex, advanced age, electrolyte disturbances, congenital long QT syndrome, cardiac pathologies and of course the use of other potentially arrhythmogenic drugs [12, 20].

Our patient presented hypokalemia under the treatment of imipenem and cisplatin which similar to some reported cases in the literature [12]; her age, her sex and especially the electrolyte disorder places her at a higher risk and fluconazole combination therapy with levetiracetam increased her risk more in developing ventricular arrhythmias. Magnesium treatment is the best option in cases of “torsade de pointes” induced by drugs which should be administered effectively in patients [13, 14, 15] like in our case.

### **Conclusion**

Although the prevalence of QTc interval prolongation in patients using fluconazole is low, clinicians should be cautious in patients with risk factors and especially when taking concomitant medications known to prolong QT interval like fluconazole. A surface ECG should always be performed before drug combination therapy known to increase the risk of QT prolongation. Adequate magnesium therapy should be appropriately administered to reduce recurrences and sudden death.

### **ETHICAL APPROVAL**

As per international standard or university standard written ethical approval has been collected and preserved by the author(s).

### **CONSENT**

As per international standard or university standard, patient(s) written consent has been collected and preserved by the author(s).

### **COMPETING INTERESTS DISCLAIMER:**

Authors have declared that they have no known competing financial interests OR non-financial interests OR personal relationships that could have appeared to influence the work reported in this paper.

### **References**

1. Drew BJ, Ackerman MJ, Funk M, Gibler WB, Kligfield P, Menon V, et al. Prevention of torsade de pointes in hospital settings: a scientific statement from the American Heart Association and the American College of Cardiology Foundation. *Circulation*. 2 mars 2010;121:1047-60.
2. A. Yap YG, Camm AJ. Allongement de l'intervalle QT médicamenteux et torsades de pointes. *Cœur*. 2003 ; 89 :1363–1372.

3. Tholakanahalli VN, Potti A, Hanley JF, Merliss AD. Fluconazole-induced torsade de pointes. *Ann Pharmacother.* avr 2001; 35:432-4. 6.
4. Zeuli JD, Wilson JW, Estes LL. Effect of Combined Fluoroquinolone and Azole Use on QT Prolongation in Hematology Patients. *Antimicrob Agents Chemother.* mars 2013; 57 :1121-7
5. Dessertenne F. [Ventricular tachycardia with 2 variable opposing foci. *Arch Mal Coeur Vaiss*;1966; 59 :263-72. .
6. Tholakanahalli VN, Potti A, Hanley JF, Merliss AD. Fluconazole-induced torsade de pointes. *Ann Pharmacother.* avr 2001; 35 :432-4.
7. Li M, Ramos LG. Drug-Induced QT Prolongation And Torsades de Pointes. *Pharmacy and Therapeutics.* juill 2017; 42 :473.
8. Gurgul S, Buyukakilli B, Komur M, Okuyaz C, Balli E, Ozcan T. Does Levetiracetam Administration Prevent Cardiac Damage in Adulthood Rats Following Neonatal Hypoxia/Ischemia-Induced Brain Injury? *Medicina (Kaunas).* 2018 ; 54 :12.
9. Le lévétiracétam (KEPPRA) peut entraîner un allongement de l'intervalle. <https://pharmacie.ma/article/6795/>
10. Roden DM. Predicting drug-induced QT prolongation and torsades de pointes. *J Physiol.* 2016; 594 :2459-68.
11. Prior TI, Baker GB. Interactions between the cytochrome P450 system and the second-generation antipsychotics. *J Psychiatry Neurosci.* 2003; 28:99-112.
12. Kumar V, Khosla S, Stancu M. Torsade de Pointes Induced by Hypokalemia from Imipenem and Piperacillin. *Case Rep Cardiol.* 2017: 4565182.
12. Drug-drug interactions between COVID-19 treatments and antipsychotics drugs: integrated evidence from 4 databases and a systematic review. Beatriz Oda Plasencia-García, Gonzalo Rodríguez-Menéndez, María Isabel Rico-Rangel, Ana Rubio-García, Jaime Torelló-Iserte, Benedicto Crespo-Facorro, *Psychopharmacology (2021) 238:329–340*
13. Magnesium treatment in pediatric patients. Anderson S, et al. *J Pediatr Health Care.* 2021 PMID:34479684
14. Atrial fibrillation and QT prolongation due to proton pump inhibitor-induced hypomagnesemia. N Noirderc et al. *Ann Cardiol Angeiol*: 2020; 69: 201-203.
15. Pharmacological treatment of acquired QT prolongation and torsades de pointes Simon H, L. Thomas & Elijah R. Behr. *Br J Clin Pharmacol*: 2015; 81: 420–427
16. Predicting drug-induced QT prolongation and torsades de pointes. Dan M. Roden *Physiol* 594.9 (2016) pp 2459–2468.
17. Drug-induced QT Interval Prolongation in the Intensive Care Unit Cecilia Villa Etchegoyen, Guillermo Alberto Keller, Sebastian Mrad, Sixuan Cheng, Guillermo Di Girolamo. *Curr Clin Pharmacol.* 2017;12(4):210-222.
18. Torsade de pointes associated with chloroquine, hydroxychloroquine, and azithromycin: a retrospective analysis of individual case safety reports from VigiBase. Diego Macías Saint-Gerons, Rafael Tabares-Seisdedos. *European Journal of Clinical Pharmacology (2021) 77:1513–1521.*
19. QTc prolongation by antiepileptic drugs and the risk of torsade de pointes in patients with epilepsy. Ashley E. Feldman, Barry E. Gidal. *Epilepsy & Behavior* 26 (2013) 421–426.
20. Tosardes de pointes. Cohagen B et al. *StatePearls (Internet)* : 2022 : PMID 2908378