

Case report

UNSAFE ABORTION WITH PERFORATED CERVICAL INJURY AND CONSEQUENTIAL SEVERE HAEMORRHAGE: A CALL FOR MULTI-SECTORAL ACTION. "CASE REPORT"

Abstract.

Unsafe abortion is a leading but preventable cause of maternal morbidity and mortality. Nearly 73 million induced abortions occur globally every year. This case reports the experience of a young unmarried woman who suffered a life threatening hemorrhage from punctured injury to the cervix resulting in false tract creation during the procedure of unwanted pregnancy termination performed by a quack. She was successfully managed, offered post abortion counselling and contraceptive among other post abortion care.

Unsafe abortion is a global phenomenon unlimited by national boundaries. The brunt is deeply suffered by women in the developing countries. To tackle these problems multi-sectoral efforts should be aimed at improving access to contraceptives in a non judgemental, adolescent friendly manner. Human right issues surrounding illiteracy, unemployment and socio-cultural deprivation infringe upon women should be eradicated through gender sensitive legislations and women friendly policies. Global approach involving political stakeholders and public health to discuss the alarming rate of unsafe abortion and galvanize resources at improving family planning services.

Keywords

Unsafe abortion, cervical punctured injury, life threatening hemorrhage, post abortion care, gender sensitive legislations.

Introduction

Unsafe abortion is a leading but preventable cause of maternal morbidity and mortality.

Nearly 73 million induced abortions occur globally every year. About 60% of all unintended pregnancies and 29% of all pregnancies end up as induced abortion.¹ Global data estimated from 2010- 2014 shows that nearly half of induced abortions are unsafe.² About 33% were performed under the least safe conditions either by an untrained personnel through an invasive and dangerous means.²

The highest burden of unsafe abortion takes place in Africa, Latin America and South Asia. In Africa, about half of all induced abortion occur under unsafe circumstances.² In Nigeria there is restrictive law prohibiting induced abortion, it is surprising that the proportion of women who procure induced abortion is on the increase and most unintended pregnancy ended up being terminated by non medical personnel, in an unhygienic and unsafe manner thus resulting in complications.³ Women with intentions of terminating unwanted pregnancies end up procuring the service of untrained persons in order to avoid the judgemental attitude of the medical personnel and ultimately escape being prosecuted in countries with restrictive abortion law.^{4,5} However, they are consequently put in harm's way. Among the numerous short term complications of unsafe abortion are hemorrhage, genital injuries such as cervical laceration, uterine perforation, bowel injury and sepsis. Late complication may include infertility, ectopic gestation, and uterine synechia, cervical incompetence, psycho-sexual problems among many others.⁶ Aside from medical complications, unsafe abortion contributes significant economic burden on health systems in the developing countries. It was estimated that over 553 million United States dollars was spent yearly on post abortion treatments. Curbing the menace of unsafe abortion through right strategies;

involving wide coverage and greater access to modern contraceptives and quality induced abortion services could save many countries of mammoth of funds spent managing the complications of unsafe abortion.⁷⁻¹⁰ This is a case report of a young unmarried woman who suffered severe consequence of unsafe abortion performed by a patent drug seller who carried out procedure of induced abortion with a metallic sharp instrument on a table inside the room where he sells drugs, resulting in life threatening haemorrhage from perforating injury to the cervix in an attempt to gain access into the uterine cavity.

Presentation of Case

A 24 year old G2P0+1 single university student was referred from a peripheral hospital on account of bleeding per vagina of 12 hours and severe body weakness of 2 hours duration. She was amenorrhic for 8 weeks 5 days and confirmed pregnancy with positive pregnancy test kit. She opted for termination of the pregnancy and a patent drug seller offered her medication which was inserted into her vagina. Following which she started having profuse bleeding per vagina and she was rushed back to the same shop where she was offered surgical procedure to remove the remains of the fetal tissues from her uterus. The procedure was said to have been carried out with a hook like metallic instrument which resulted in severe pelvic pain and uncontrollable bleeding from the vagina. This necessitated her presentation in the referring hospital before she was eventually sent to our facility for expert care. She had voluntary termination of pregnancy at gestational age of 6 weeks done 2 years before the index presentation and it was through medical means. There was no post abortion complication.

At presentation she was lethargic, pale, anxious, dehydrated, afebrile, with temperature of 36.8 degree centigrade and nil pedal edema. Her pulse rate was 120 beats per minutes small

volume, blood pressure was 90/60mmhg. Respiratory rate was 26 cycle per minutes. Abdomen was full moves with respiration, there was suprapubic tenderness, no guarding, no rebound tenderness and bowel sound was normoactive. Pelvic examination revealed vulva that was smeared with fresh blood and vagina canal packed with gauze. Speculum examination revealed a closed cervical Os, with a punctured injury on the posterior wall of the cervical body at around 6 o' clock position, measured about 3 cm x 3cm communicating with the uterine canal. [Figure 1,2,3] There was product of conception protruding through the punctured wound. A sponge holding was used to remove the product of conception plugging the punctured false tract and the bleeding abated afterwards.

Samples were taken for full blood count, blood group and cross match of 4 units of blood, retro-viral screening and serology for hepatitis. Packed cell volume was 18%, a white blood cell count of 8.5×10^6 , platelet count of 200,000/ml. Blood group was O positive, HIV 1 and 2 were non reactive, Hepatitis B surface antigen and Hepatitis C virus screening were negative. Urinalysis was essentially normal. Urgent abdomino-pelvic ultrasound scan revealed a bulky uterus measuring 6cm by 8cm with a thickened and irregular endometrial lining but no product of conception was noted. The internal Os is about 8mm opened. The adnexa are bilaterally free and there was no fluid collection in the pouch of Douglas. The bowel echoes were normal with adequate peristalsis. No bowel wall thickening, the stomach contained some fluid content, no gaseous accumulation. Other abdominal organs were sonographically normal. There was no evidence of fluid in the peritoneal cavity. Chest x ray was done and there was no air under the diaphragm, erect abdominal x ray was also normal.[Figure 4]

An assessment of hypovolemic shock secondary to unsafe incomplete miscarriage with punctured injury to the cervix to rule out uterine perforation and bowel injury was made.

She was admitted into the gynaecological emergency ward, had 2 wide bore cannulae fixed and Immediate resuscitation with normal saline was commenced. Intravenous fluid with 20 unit of oxytocin in 500ml of saline was commenced to run over 4 hours, had 3 units of blood transfused in quick successions and her vitals became stable. She also had intravenous coamoxiclav 1.2 g 12 hourly, metronidazole 500mg 8 hourly, gentamycin 80mg 8 hourly for 48 hours, tetanus toxoid 0.5ml stat, 1500 IU of anti-tetanus immuno-globulin was also administered. The punctured wound site on the cervix was cleaned with antiseptic solution and repaired with vicryl 2 suture in continuous fashion starting from one centimetre above the apex of the wound.[Figure 5] All these were done to stabilize the patient before the radiological investigations were sent for after she became stable several hours later. She was placed on nil per oris and abdominal girth was measured at the level of the umbilicus daily for 48 hours and it remained 67cm.

She remained stable with no feature of bowel injury, medications were converted to orals and commenced oral feeding after 48 hours of observation. Her post transfusion packed cell volume was 26%. Another two units of blood were transfused and post transfusion packed cell volume was 31%. She was counselled on the danger of unsafe abortion and the need for her to use contraceptive in order to prevent future occurrence. She made satisfactory recovery and was subsequently discharged home on 4th day on antibiotics and haematinics.

She was seen at the gynaecological clinic 2 weeks later without complaint, the cervix had healed and she was considering implanon insertion. Her second follow up visit 3 weeks later was satisfactory, she had just finished her menstruation and eventually had implanon

insertion done in the same visit. To prevent sexually transmitted infection, she was counselled on the use of barrier contraceptive as well and to keep a mutually exclusive sexual relationship.

The hospital team comprising of social workers, doctors and servicom unit staffs were sent to the address of the personnel that performed the procedure on a fact finding visit and for counselling on the need for him to refrain from such an illegal, life threatening act, however the drug store was met closed.

She was excited with the quality of care provided to her by the staffs of the hospital during her stay. She promised to educate her colleagues on the negative impacts unsafe abortion could have on their well-being and preventive strategies to forestall such occurrence.

Discussion

Unsafe abortion is a global phenomenon as it is unlimited by national boundaries.¹ The brunt is deeply suffered by women in the developing countries as they lack access or prohibited from safe abortion services due to socio-cultural, economic, religious, restrictive laws among other political factors.^{4,5} This serious reproductive health neglect has posed grave threat to overall health of millions of women of reproductive age group and the society at large.⁶⁻⁸ Until unsafe abortion is dealt with, the vulnerable groups and many developing nations will continue to suffer the grave aftermath of this ugly incidents.⁶⁻⁸ Patients with complications of unsafe abortion account for significant proportion of gynecological inpatient admissions in developing countries such as Africa.⁷ This means that regardless of restrictive laws, abortion seekers still procure the procedure in an illegal, unsafe and clandestine manner with its attendant consequences as it was seen in the index case. Mortality is common among adolescent and young women due to inaccessibility to

abortion services resulting from the restrictive abortion law, lack of fund to access quality care, delay in hospital presentation for post abortion care after unsafe abortion.^{4,5}The index case was a near miss, fortunate to survive due to the seeming timely presentation in tertiary facility even though she had suffered a life threatening hemorrhage from punctured injury to the cervix resulting in false tract creation during the procedure of unwanted pregnancy termination. The mediocrity and lack of knowledge of female genital tract on the path of the personnel who performed the procedure was displayed by the failure to identify the external Os of the cervix and the eventual creation of false tract through the posterior cervical wall to gain entrance into the endometrial cavity. This is quackery and such is an abomination in any modern society. She was offered immediate resuscitative measures including blood transfusion, antibiotics and removal of the remnants of products of conception from the uterine cavity. Debridement of the avulsed cervical tissues and repair of the injury was done. She was subsequently evaluated for an accompanied uterine perforation and bowel injury which were not present. Before she was discharged from the hospital, she was offered post abortion counselling which include the use of contraceptives, safe sex practices and educated on other essential reproductive services that can be of immense benefits to her.

Evidence based strategies have been postulated in curbing the menace of unsafe abortion. Tackling these problems, multi-sectoral efforts should be at improving sexuality education, access to contraceptives in a non judgemental, adolescent friendly manner with medical personnel upholding confidentiality, provision of comprehensive abortion care services, women friendly, human right upholding government policies among others.^{6,9-10}

Recommendation

Human right issues surrounding illiteracy, unemployment and socio-cultural deprivation infringe upon women should be eradicated through gender sensitive legislations and women friendly policies aim at breaching the lacuna that has been in existence for hundreds of years. A global approach will be to call for public forum involving political stakeholders and public health experts across the world to discuss the alarming rate of unsafe abortion and galvanize resources at improving family planning services especially for women in the developing countries. Also, the authorities should regulate and properly monitor the activities of patent medicine outlets, maternity homes and clinics as most of these clandestine pregnancy termination take place therein. Lastly, training and retraining of lower cadres healthcare workers on safe procedures to assist women with incomplete miscarriages should be encouraged as it is apparent that some women still end up with complications even after seeking such care from some trained medical personnel.

Conclusion

Unsafe abortion is a global issue with most of the havocs among women of the developing countries. A multi-sectoral approach including female empowerment, widespread provision of contraceptives, gender sensitive legislation and women friendly policies, and also proper regulation of activities of community patent medicine outlets and private clinics where most of these clandestine abortion practices take place will reduce the scourge of unsafe abortion in our society.

Competing interest

Authors have declared that no competing interests exists.

Authors contributions

Case management was done by Fijabiyi Matthew, Ochima Onazi, Ojurongbe Adegoriola

Draft of the first manuscript was written by Fijabiyi Matthew, Aworinde Olufemi

Editing of the second manuscript was done by all the Authors

Proof Reading of the manuscript was done by Toyin Fijabiyi, Matthew Fijabiyi, Ojurongbe Adegioriola

Final manuscript writing and editing was done by all authors

Consent

Consent was taken from the patient before her information and pictures were provided in this manuscript.

References

1. Bearak J, Popinchalk A, Ganatra B, Moller A-B, Tunçalp Ö, Beavin C et al. Unintended pregnancy and abortion by income, region, and the legal status of abortion: estimates from a comprehensive model for 1990–2019. *Lancet Glob Health*. 2020 Sep; 8(9):e1152-e1161.
2. Ganatra B, Gerdtts C, Rossier C, Johnson Jr B R, Tunçalp Ö, Assifi A et al. Global, regional, and subregional classification of abortions by safety, 2010–14: estimates from a Bayesian hierarchical model. *The Lancet*. 2017 Sep.
3. Bankole A, Oye-Adeniran BA, Singh S, Adewole IF, Wulf D, Sedgh G, Hussain R. Unwanted pregnancy and induced abortion in Nigeria: causes and consequences. New York: Guttmacher Institute, 2006.
4. Coast E, Lattof SR, Meulen Rodgers YV, Moore B, Poss C. The microeconomics of abortion: A scoping review and analysis of the economic consequences for abortion care-seekers. *PLoS One*. 2021 Jun 9;16(6):e0252005.

5. Lattof SR, Coast E, Rodgers YVM, Moore B, Poss C. The mesoeconomics of abortion: A scoping review and analysis of the economic effects of abortion on health systems. PLoS One. 2020 Nov 4;15(11):e0237227.
6. Fact sheet: Abortion. Geneva: World Health Organization; 2021.
7. Rodgers YVM, Coast E, Lattof SR, Poss C, Moore B. The macroeconomics of abortion: A scoping review and analysis of the costs and outcomes. PLoS One. 2021 May 6;16(5):e0250692. doi: 10.1371/journal.pone.0250692. PMID: 33956826; PMCID: PMC8101771.
8. Vlassoff et al. Economic impact of unsafe abortion-related morbidity and mortality: evidence and estimation challenges. Brighton, Institute of Development Studies, 2008 (IDS Research Reports 59).
9. Fetters T, Samandari G, Djemo P, Vwallika B, Mupeta S. Moving from legality to reality: how medical abortion methods were introduced with implementation science in Zambia. Reprod Health. 2017;14(1):26.
10. Abortion Care Guidelines [internet]. Geneva: World Health Organization; 2022. Towards a supportive law and policy environment for quality abortion care: evident brief. Geneva: World Health Organization; November 2022.




Figure 1: speculum examination showing the position of the cervix Os

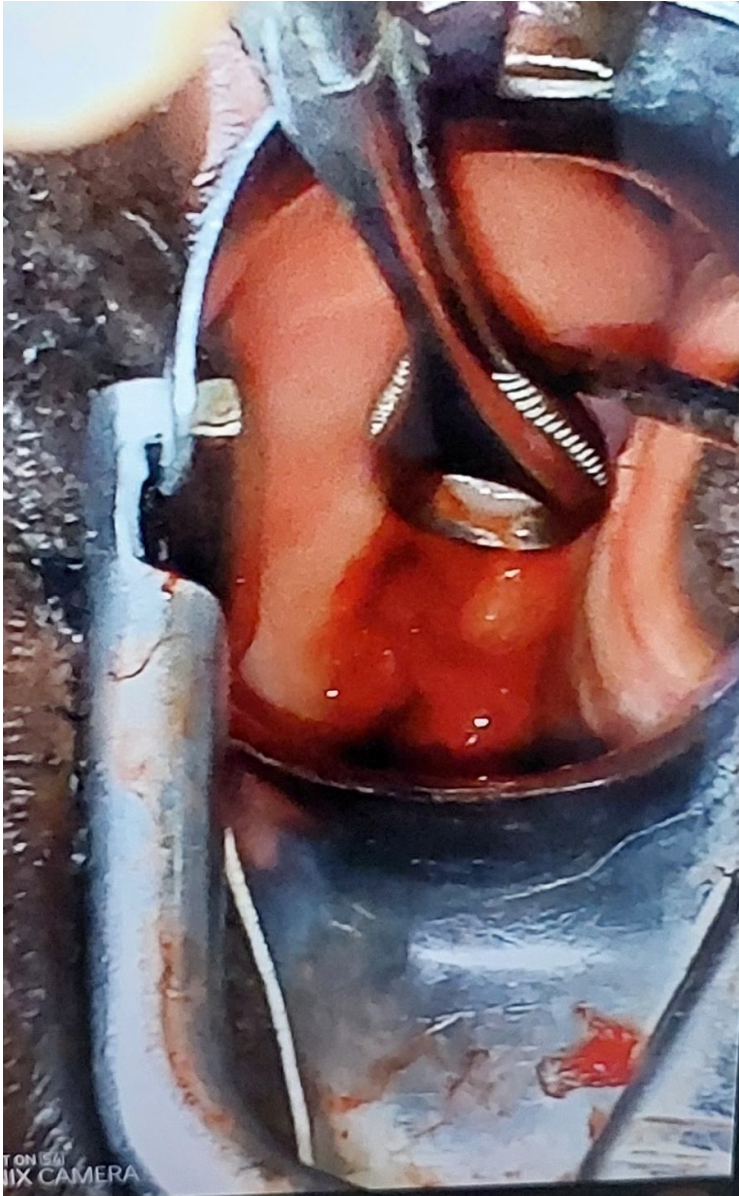


Figure 2: speculum examination showing bleeding from the cervical injury

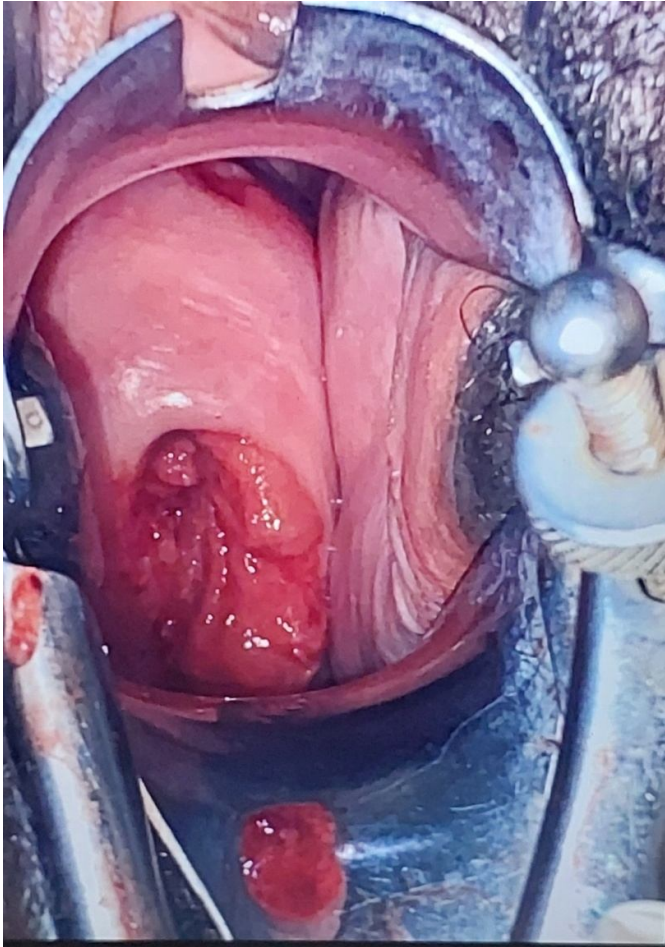


Figure 3: speculum examination showing the cervical Os and the false tract created on the posterior part of the cervix after the cessation of bleeding

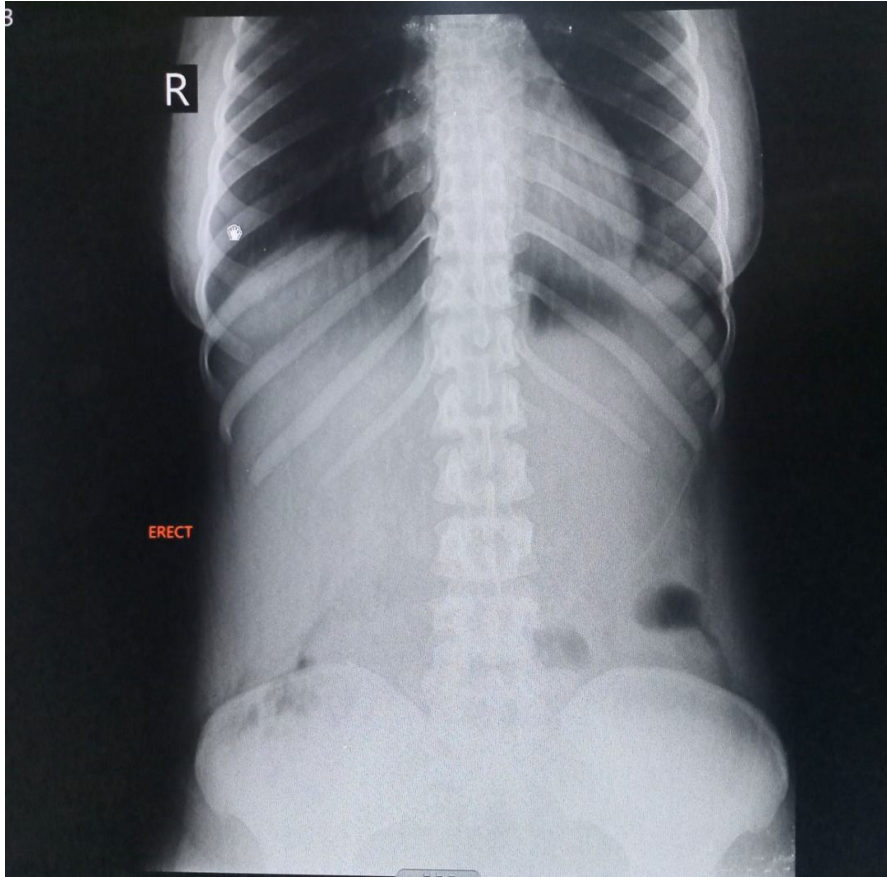


Figure 4: Abdominal X ray in the erect view

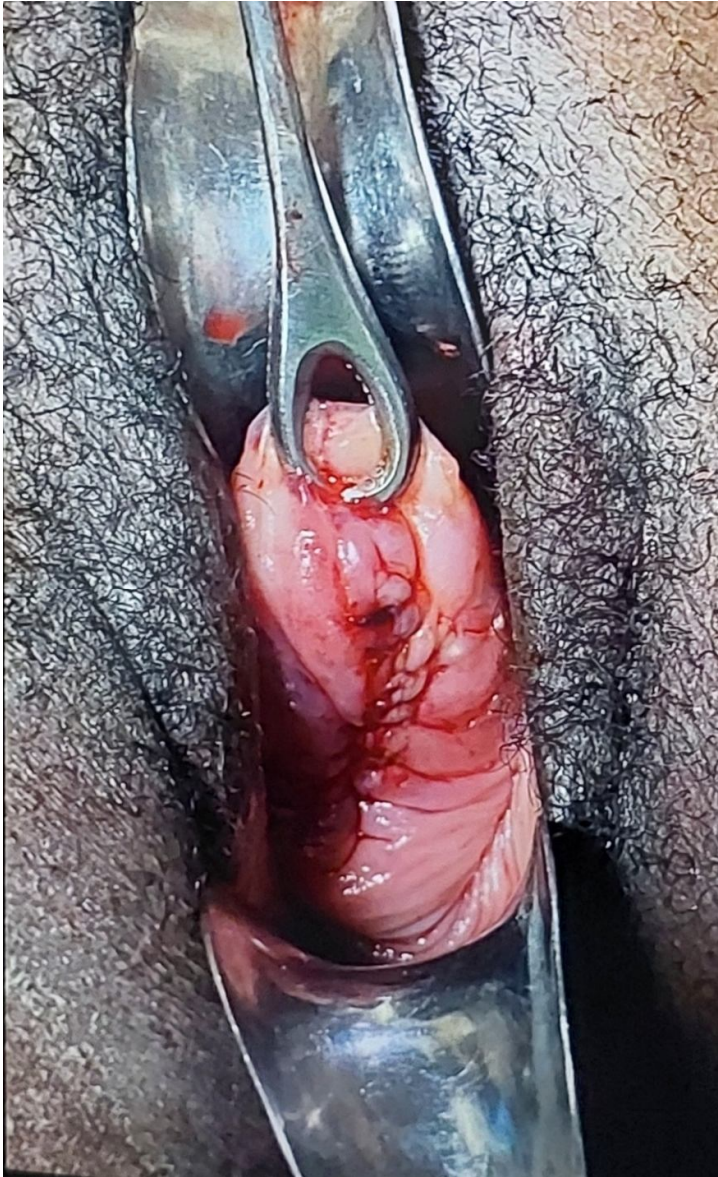


Figure 5: Appearance of the cervix immediately after successful cervical perforation repair was done