

## Case study

# Bilateral juvenile otosclerosis: case report

### **Abstract:**

Otosclerosis is a primitive osteodystrophy of the labyrinthine bone. It generally occurs in the third or fourth decade, but it is also encountered in children. Approximately, 15% of patients with otosclerosis experienced hearing loss before the age of 18. Stapes surgery is still a subject of debate in pediatric population although it has been performed for years with positive surgical outcomes. We report the case of a bilateral juvenile otosclerosis that has been successfully treated with stapes surgery.

**Keywords:** Otosclerosis, Children, Hearing loss, Stapes surgery

### **Introduction:**

Otosclerosis is a primary osteodystrophy of the temporal bone characterized by abnormal bone resorption and deposition. All of the otic capsule may be involved, the lesions begin at the fistula ante fenestram in 70% to 90% of cases. (1)

Otosclerosis occurs in 7 to 10% of the general population, usually in the third or fourth decade of life, predominating in female with a F:M ratio of ~2:1. A hereditary predisposition can be seen in up to 50% of cases. It may occur in childhood, but it is infrequent. (2)

Progressive conductive and/or mixed hearing loss and tinnitus are the two main clinical features of otosclerosis. Vertigo, aural fullness, and sensorineural hearing loss may eventually be present. The symptomatology depends on the location and extent of the otosclerotic focus.

Diagnosis in children may be difficult. Congenital stapes fixation, ossicular chain malformations, secretory otitis media and connective tissue diseases are among the differential diagnosis for the most revealing sign, which is conductive hearing loss. The diagnosis is established on the basis of the clinical history, physical examination, audiometry and imaging tests especially computed tomography.

Treatment of juvenile otosclerosis is challenging. Surgery and hearing aids are the main therapeutic options. Even though surgery is regularly performed in adults, information about surgical outcomes in children is still limited and surgery indications are still open to question.

### **Case report:**

A 15-year-old girl, with no medical past history, presented to our department complaining of bilateral progressive hearing loss which has been evolving for 4 years, with moderate intermittent right tinnitus. There were no other associated signs. The otoscopic examination didn't show any abnormality. The pure tone audiometry revealed bilateral conductive hearing loss measured at 60 dB in the right ear with an air bone gap of 40 dB and 65 dB in the left ear with an air bone gap of 50dB

Tympanometry showed a flattening curve and acoustic reflexes were absent.

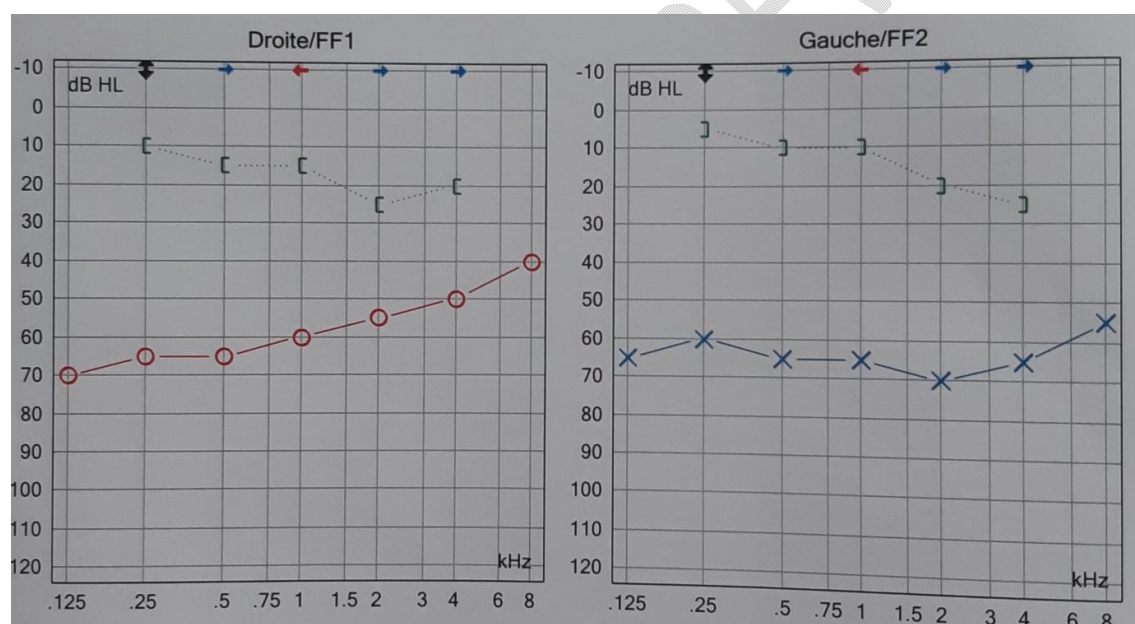


Fig 1 : preoperative pure tone audiometry.

Computed tomography of the temporal bones showed bilateral isolated anterior fenestral hypodensity measuring 1,3 mm

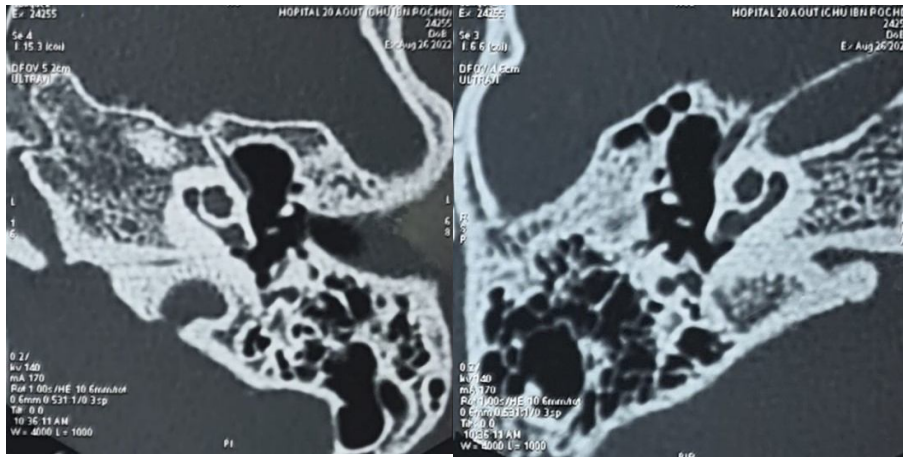


Fig 2: Axial images of the right and left temporal bones showing bilateral otosclerosis foci.

Stapes surgery was performed for the left ear with a closure of the air bone gap to 10 db. 4months later, the patient underwent surgery for the right ear with a closure of the air bone gap to 25 dB

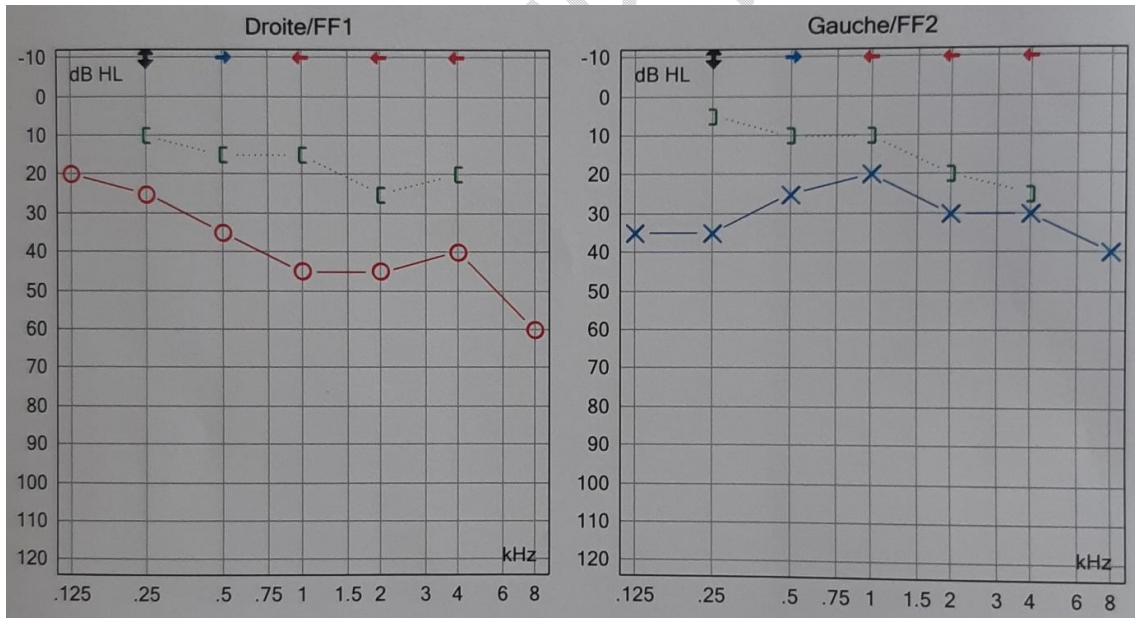


Fig 3: Postoperative pure tone audiometry.

## **Discussion:**

Juvenile otosclerosis is a rare clinical entity. Its incidence is reported to be less than 0.6% before the age of 5 years and only 4% between the ages of 5 and 18 years. This incidence is significant considering that 15.1% of patients who have undergone stapedectomies manifest hearing losses before the age of 18](1) There is a very high incidence of bilateral otosclerosis (92%) when the symptom of hearing loss appears under age of 18.(3)

The main symptom of otosclerosis is conductive hearing loss. In infancy, conductive hearing loss is often due to chronic otitis media with or without effusion. Therefore, other congenital or acquired causes of conductive hearing loss, such as otosclerosis and tympanosclerosis are generally underdiagnosed or diagnosed late, which may lead to language delay.

The diagnosis is suspected on medical history, otoscopic examination, audiometric results and imaging findings. CT scan is an excellent tool for preoperative evaluation. Its sensitivity in adults is higher than 85%, however, many false negative results were found in children, related to small hypoattenuation areas. (3)

Therapeutic management of juvenile otosclerosis is controversial. Many treatments are proposed such as anti-enzyme or bone resorption moderating drugs and personal Sound Amplification Devices (PSAD) and surgery. In children under the age of five, it is recommended to use PSAD, surgery is not indicated. After the age of 5 years, surgery is controversial. Many otologists question the validity of surgery at this age given the higher incidence of eustachian tube dysfunction and otitis media, the increased risk of re-fixation, stapes gusher, and resultant sensorineural hearing loss.(4) Moreover, surgery requires the cooperation of the child and his parents especially in the immediate postoperative period, when they should minimize activities to avoid complications.(5) thus, expectant approach should be used until adolescence. Various studies have shown that stapedotomy is a safe and effective treatment in pediatric patients. Some otologists recommend surgery at a young age, considering that juvenile otosclerosis is an aggressive process and surgery will be more challenging if delayed until adulthood. (6)

## **Conclusion:**

Although it is rare, otosclerosis should be considered in children with conductive hearing loss. Stapedotomy is an effective therapeutic option especially in bilateral juvenile otosclerosis.

### **References:**

1. Virginia Fancello, Luca Sacchetto, Chiara Bianchini, Andrea Ciorba, Daniele Monzani, and Silvia Palma. Management of Juvenile Otosclerosis: A Systematic Review Nov 2022
2. Crompton M, Cadge BA, Ziff JL, Mowat AJ, Nash R, Lavy JA, et al. The Epidemiology of Otosclerosis in a British Cohort. *Otol Neurotol.* janv 2019;
3. Chiboub D, Zoghlami I, Bouzidi D, Jameleddine E, Romdhane N, Nefzaoui S, et al. Juvenile otosclerosis: radio-clinical features and outcomes of surgical treatment.
4. Denoyelle F, Daval M, Leboulanger N, Rousseau A, Roger G, Loundon N, et al. Stapedectomy in children: causes and surgical results in 35 cases. *Arch Otolaryngol Head Neck Surg.* oct 2010;136(10):1005-8.
5. del Bo M, Bergomi A. The Surgical Problem of Juvenile Otosclerosis. *International Audiology.* 1970;9(2-4):323-5
6. Carlson ML, Van Abel KM, Pelosi S, Beatty CW, Haynes DS, Wanna GB, et al. Outcomes Comparing Primary Pediatric Stapedectomy for Congenital Stapes Footplate Fixation and Juvenile Otosclerosis. *Otology & Neurotology.* 2013;34(5):816- 20.