

Mastoid Adenocarcinoma: A Case Report

ABSTRACT

The diagnosis of primary cancer in the mastoid bone is frequently made after a mastoidectomy to control chronic mastoiditis. The main warning indications of cancer of the middle ear or external auditory canal include persistent infection, purulent otorrhea, and severe otalgia. Malignancy might be suspected if the quantity of bone mastoid destruction is out of proportion. In this case report, we present the case of an 81-year-old female patient who presented to our department with right chronic otalgia and purulent otorrhea, which been considered initially a malignant external otitis. With the non-amelioration of the symptomatology, additional tests, surgery, and histology revealed a mastoid adenocarcinoma.

Keywords: Mastoid bone; carcinoma; chronic mastoiditis; otalgia; mastoidectomy.

1. INTRODUCTION

Mastoid and middle ear malignant tumors are uncommon. Squamous cell carcinoma, the most frequent kind of malignancy in the head and neck region, is also the most prevalent type of temporal bone tumor [1]. Adenocarcinoma, mucoepidermoid carcinoma, adeno-cystic carcinoma, and ceruminous carcinoma, are some of the other types.

The incidence of primary temporal bone tumors ranges from 0.03 to 1.0 per 100,000 people per year, with squamous cell carcinoma accounting for 60-80% of cases [2].

Tumors of the tympano-mastoid area are more prevalent in the sixth and seventh decades of life. Males are more likely to be afflicted than females. Various risk factors, such as chronic suppurative otitis media, past exposure to radiations in nasopharyngeal, intracranial, and head and neck malignancies, and ultraviolet radiations, have been proposed. These tumors typically show as chronic suppurative otitis media (CSOM), making diagnosis difficult. Even after diagnosis, treatment is difficult and unsatisfying, with a high recurrence and mortality rate.

2. CASE REPORT

It's about an 81-year-old female patient, with medical history of arterial hypertension, was referred to our department for a 1 year right-

sided otalgia, purulent otorrhea and important hearing loss. The patient had not experienced any other otologic symptoms.

Clinical examination revealed an obvious inflammation and stenosis of the right ear canal, with no facial palsy.

Pure tone audiometry showed an important right cophosis, and a left sensorineural hearing loss (Fig. 1).

The CT scan showed a mucosal thickening of the different walls of the ear canal, along with lysis of the tympanic bone, and a blunted scutum, suspecting a malignant external otitis (Figs. 2 and 3).

The patient has been admitted the first time and several further times for the same symptomatology, and was treated with intravenous large spectrum of antibiotics, antifungal drugs and local treatment with no significant amelioration.

A biopsy of the right external auditory canal was performed, the histological result was not conclusive.

With the non-amelioration, and the worsening of the pain, a diagnostic mastoidectomy has been performed, revealing in the histological study a poorly differentiated and invasive adenocarcinoma (CK7+ / CK20-).

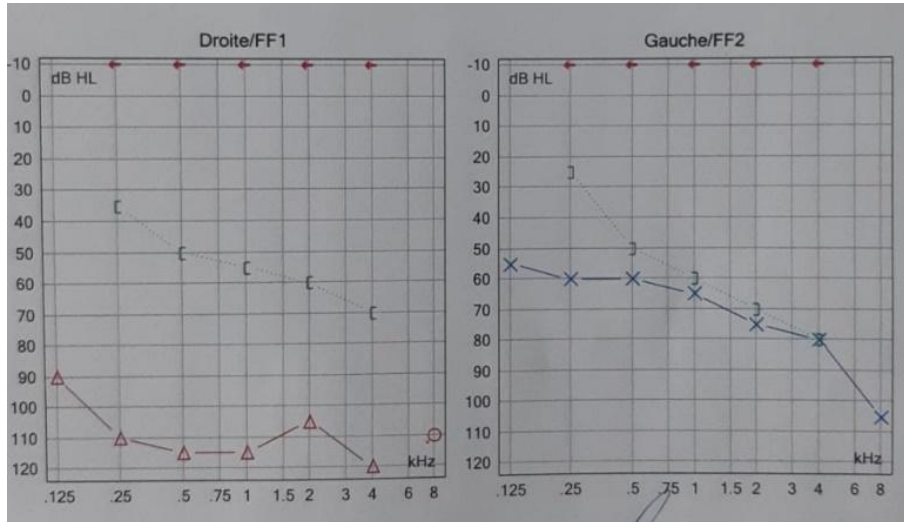


Fig. 1. Pure tone audiometry showing an right cophosis, and a sensorineural left hearing loss

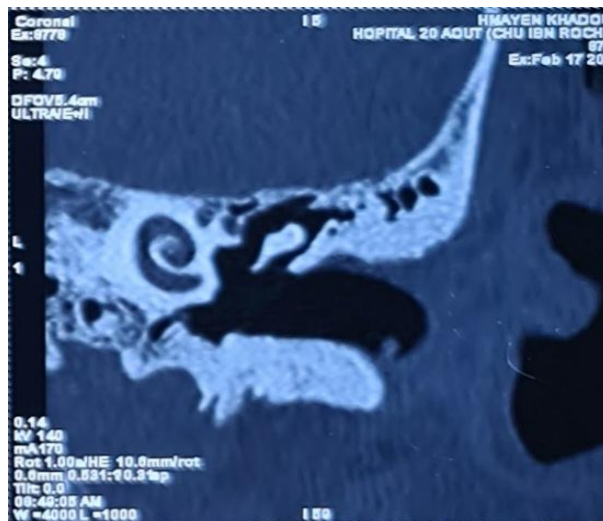
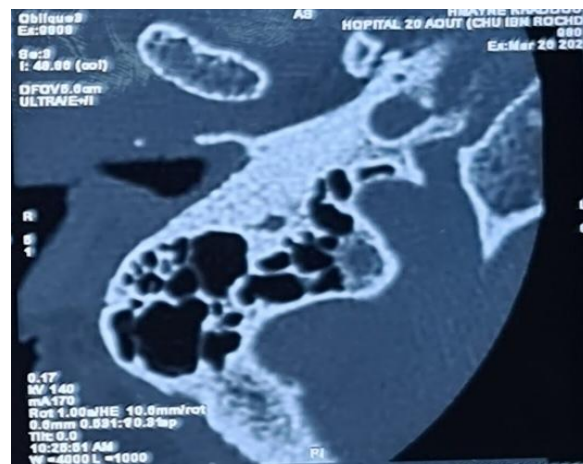


Fig. 2. Pre-op Left temporal bone CT scan (Coronal cut) showing a normal left middle ear



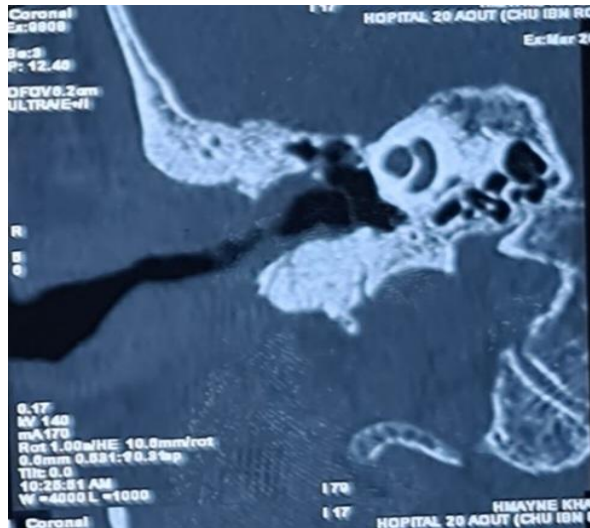


Fig. 3. Pre-op Right Temporal bone CT-SCAN (Coronal/ axial cuts) images showing mucosal thickening of the different walls of the right EAC, and a blunted scutum

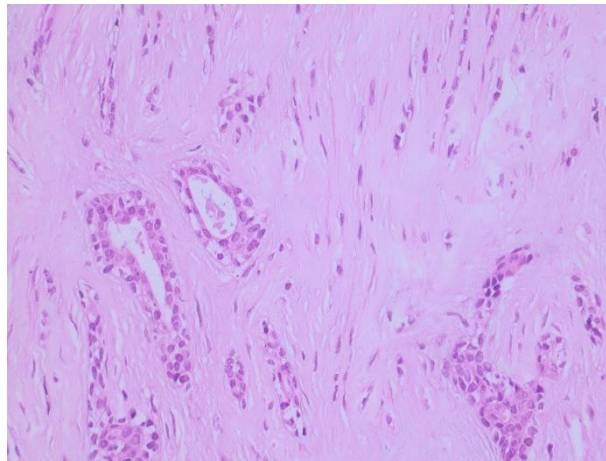


Fig. 4. Histological result showing a poorly differentiated and invasive adenocarcinoma

Later on, an open mastoidectomy was performed, before referring the patient to oncology for further treatment.

3. DISCUSSION

Tumors of the temporal bone, which include skin cancers of the pinna and external auditory canal, middle ear mastoid, petrous bone, and metastatic lesions, are extremely rare.

The reported incidence ranges between 0.03 and 1.0 per 100,000 per year, with males in their sixth and seventh decades being the most affected.

Multiple etiological factors have been identified, including prior radiation exposure, UV radiation, and chronic otitis media [1]. Many studies believe

chronically discharged ears to be a risk factor, which could be attributed to metaplasia in the middle ear mucosa caused by persistent infection.

In our care report, the patient had chronic right ear purulent otorrhea for more than one year.

Some researches have looked into probable carcinogens such as chlorinated disinfectants or human papillomavirus in cases of carcinomas associated with inverted papilloma [3-5].

The clinical characteristics are quite similar to chronic otitis media, making diagnosis difficult. Long-term blood-tinged ear discharge, intense discomfort, rapidly increasing polypoidal or granulomatous tumor in EAC or Middle Ear,

peripheral facial palsy, and painless ulceration over pinna or EAC are the most prevalent symptoms. In such circumstances, a high index of suspicion should prompt a clinician to do a thorough clinical examination and investigation to rule out cancer. Radiological tests are crucial in making a diagnosis in questionable cases. The preferred examinations are a CT scan for bone erosion and an MRI for soft tissue involvement and neural invasion. Histopathological evaluation and diagnosis require tissue sample.

Surgery and chemo-radiotherapy are the pillars of treatment [6,7].

The first-line treatments for temporal bone adenocarcinomas are surgery and postoperative radiation [8-10].

Most experts think that a combination of surgery and radiotherapy, rather than a single modality treatment, is more likely to produce the greatest results [11-13].

Chemotherapy may be recommended in cases of post-surgical residual disease or recurrence, distant metastases, and conditions where surgery and radiotherapy are contraindicated.

4. CONCLUSION

Temporal bone tumors are uncommon, and aggressive and challenging to manage. The clinical characteristics are often identical to chronic suppurative otitis media, making diagnosis problematic. To improve survival, prompt diagnosis and treatment are essential.

CONSENT

As per international standard or university standard, patient(s) written consent has been collected and preserved by the author(s).

ETHICAL APPROVAL

As per international standard or university standard written ethical approval has been collected and preserved by the author(s).

COMPETING INTERESTS

Authors have declared that no competing interests exist.

REFERENCES

1. National Cancer Institute. Cancer facts. Head and neck cancer: Questions and Answers; 2018. Available:<http://www.cancer.gov/cancertopics/factsheet/Sitestypes/head-and-neck/> Accessed on 3 February.
2. Lionello M, Stritoni P, Facciolo MC, Staffieri A, Martini A, Mazzoni A, et al. Temporal bone carcinoma. Current diagnostic, therapeutic, and prognostic concepts. *J Surg. Oncol.* 2014;110:383-92.
3. Monem SA, Moffat DA, Frampton MC. Carcinoma of the ear: a case report of a possible association with chlorinated disinfectants. *J Laryngol Otol.* 1999;113:1004-7.
4. Gaio E, Marioni G, Blandamura S, Staffieri A. Inverted papilloma involving the temporal bone and its association with squamous cell carcinoma: critical analysis of the literature. *Expert Rev Anticancer Ther.* 2005;5:391-7.
5. Marioni G, Altavilla G, Busatto G, Blandamura S, De Filippis C, Staffieri A. Detection of human papillomavirus in temporal bone inverted papilloma by polymerase chain reaction. *Acta Otolaryngol.* 2003;123:367-71.
6. Martinez Subias J, Doirinez Ugidos LI, Urpegui Garcia A, Sancho Serrano E, Royo Lopez J, Millan Guevara J, Valles Verela H. Middle ear carcinoma. *Acta Otorhinolaryngologica Espanola* 1998; 49: 234-246.
7. Maran AGD, Jacobson I. Tumours of the ear in: Maran AG, Stell PM Ed: *Clinical Otolaryngology* 3rd Edition. Blackwell Scientific Publications. 1990;35:464-474.
8. Glasscock ME 3d, McKennan KX, Levine SC, Jackson CG. Primary adenocarcinoma of the middle ear and temporal bone. *Arch Otolaryngol Head Neck Surg.* 1987; 113:822-824
9. Pallanch JF, Weiland LH, McDonald TJ, Facer GW, Harner SG. Adenocarcinoma and adenoma of the middle ear. *Laryngoscope.* 1982;92:47-54.
10. Schuller DE, Conley JJ, Goodman JH. Primary adenocarcinoma of the middle ear. *Otolaryngol Head Neck Surg.* 1983;91: 280-283.
11. Lewis 3S. Surgical management of tumours of the middle ear and mastoid. *J Laryngol Otol* 1983;97:299-311.
12. Maran AGD, Gaze M, Wilson JA. Tumours of the ear: In Stell and Maran's *Head and*

- Neck Surgery. 3rd edition. Oxford: Butterworth-Heinemann. 1993;199-212.
13. Birzgalis AR, Keith AO, Farrington WT. Radiotherapy in the treatment of middle ear and mastoid carcinoma. Clin Otolaryngol Allied Sci 1992;17: 113-116.
-