

Original Research Article

Fish gills as morphological indicators of exposure to four environmentally relevant pharmaceuticals.

Abstract

Pharmaceuticals are a fast-emerging class of environmentally relevant contaminants of concern, due to their ubiquitous presence in **surfaces** waters consequent on human and veterinary use. Their relatively unknown effects on non-target organisms and probable deleterious effects on ecosystem health and complexity make it necessary to develop the use of simple early warning detection systems to validate their probable presences in the aquatic environmental niche. In this paper, we present the results of the effects on the gills of a local farmed catfish species, *Clarias gariepinus* to four pharmaceuticals detected in the Lagos lagoon at concentrations exceeding determined no observed effect concentrations (noec) in literature. Histopathological changes observed included lamellar hyperplasia, hypertrophy, epithelial lifting, necrosis and atrophy. **Conclusions/Significance:** This study validates the continuing histological utility of fish gills as sensitive indicators of exposure to xenobiotics, and the inherent capacity of pharmaceutical residues in water to elicit detectable pathologies in various fish organs, even at extremely low concentrations.

Keywords: Pharmaceuticals, histopathology, *Clarias gariepinus*, Gills, histopathology

1. Introduction

Pharmaceuticals, human and veterinary are an important emergent contaminant group which has engendered a lot of lay and research community interest, and burgeoning concern in the last few decades. Primarily, this concern is based on the probability of effects more deleterious, than therapeutic on non-target flora and fauna in the aquatic environment. In addition, the effects of small, sustained, consumption based intake levels of tissue sequestered pharmaceutical on human consumers is an adjunct issue though links between such consumption and consequent

Comment [PA1]: ,

Comment [PA2]: of

Comment [PA3]: A sentence with information on the methods used is necessary

Comment [PA4]: Authors may add as the last sentence, a statement of the research as an important contribution to sustainable aquaculture

Comment [PA5]: Reference

Comment [PA6]: ,

ill effects remain tenuous and conjectural at best. Human and veterinary pharmaceuticals are designed for receptor specificity to engender desired effects, with physicochemical properties which enhance their uptake across bio-membranes, and their persistence in bio-fluids. Following ingestion, and metabolism, pharmaceuticals are primarily excreted through feces and bio-fluids, and their post metabolism residues and degradates, which are sometimes as potent as the intact drug, or which are environmentally mutable to active forms, necessarily end up in the environment, and ultimately in water at very low concentrations, usually in the nanogram to microgram range, well below defined acute toxicity concentrations levels. In addition, the improper disposal of unused medicaments from households and healthcare facilities contributes to environmental loading with pharmaceutically active compounds (PhACs). Effects due to residual drugs are consistent with high affinity interactions with conserved human orthologs/targets in affected wildlife species rather than with a general toxic effect (Gunnarsson *et al.*, 2008). The detection of effects on fish due to the presences of pharmaceutical substances have been determined at histological (Popoola *et al.*, 2007, Galus *et al.*, 2012), hematological (Jayaprakash *et al.*, 2013, Nwani *et al.*, 2013), biochemical (Nunes *et al.*, 2015, Ramos *et al.*, 2014), and molecular levels (Martins *et al.*, 2015, Rocco *et al.*, 2012) by several workers. This study intends to investigate and define the effects of sub lethal exposures to environmentally relevant levels of four pharmaceuticals on a predilective organ of a local fish species i.e. the gills.

Comment [PA7]: Reference

Comment [PA8]: Reference

Comment [PA9]: Reference

Comment [PA10]: previously

Comment [PA11]: recast in the past tense (e.g., was aimed, intended)

2. Materials and methods

Three antibiotics, chloramphenicol, erythromycin, and Sulphamethoxazole, and a representative NSAID, diclofenac, were used for exposure assessments at measured minimum environmental concentrations (0.36, 0.28, 1, and 1.5 µg/l respectively), and multiples of same (x10 and x100) derived from an earlier detection environmental detection study (Olarinmoye *et al.*, 2016). Duration of study was 12 days with sampling done on days 3, 6, 9, and 12. Fish were stunned using a sharp non-lethal blow to the occiput and dissected. Small representative specimens (1-3

Comment [PA12]: Information on the identification and harvest of fish, assay - how the antibiotics were administered (single or multiple) on the fish as well as maintenance (temperature, light /dark phase conditions) of each treatment tank is necessary.

mm) of the gills from each treatment tank and its replicate were removed. Removed tissue specimens from each treatment concentration were pooled and placed in collection tubes containing the fixative RNA later Stabilization Reagent (Qiagen^R) and stored at room temperature till processed. Fixed tissues were embedded in paraffin wax and 5µm sections cut and mounted on **microcode** slides for staining with (H&E). Sections were studied for histopathological lesions at X 1000 on an Olympus microscope fitted with a still camera. During microscopic observation for pathologic features, a semi quantitative scoring technique as suggested by Bernet *et al.* (1999) and used as by (Rašković *et al.*, 2016) was employed where lesions were classified into observed reaction pattern types (Table 1) in accordance with the recommendations of (Sindermann, 1979) as modified by Bernet (1999). The sum of the five reaction indices of an organ being equivalent to the organ index (I_{org}). The computation of gill lesion indices for individual fish was done by computing the reaction index using the following equation, $I_{org} = \sum_{rp} \sum_{alt} (a_{org\ rp\ alt} \times w_{org\ rp\ alt})$. Where org = organ, alt = alteration, rp = reaction pattern, a = alteration score value, and, w = pathological relevance of the alteration, . Individual I_{org} scores were summed giving total gill alteration values for each concentration-pharmaceutical group. Computed values were then used for the estimation of individual pharmaceutical toxicity at individual and whole animal/population levels.

Comment [PA13]: Reference

Table 1: Observed lesion reaction pattern types

Organ	Alteration	Functional unit of tissue	Lesion category/type	Lesion importance (weighted)
Gills	1. Lamellar hypertrophy	Epithelium	Progressive change	I
	2. Lamellar hyperplasia	Epithelium	Progressive change	II
	3. Epithelial Lifting/detachment	Epithelium	Progressive change	II
	4. Cellular (Inflammatory) infiltration	Supporting tissues	Inflammatory change	II
	5. Atrophy	Supporting tissues	Regressive change	II
	6. Necrosis	Supporting tissues	Regressive change	III

Comment [PA14]: space

3. Results The generality of assayed fish gills showed normal gill parenchymal architecture (figure 1) majority of observed gill alterations involved the secondary lamellae. Changes were generally minimal and progressive in nature with no clear concentration-severity trends. Lesions included epithelial lifting, hyperplasia, hypertrophy, atrophy and necrosis. On the basis of pooled organ indices for each pharmaceutical, an agent-damage gradation was determined as DFC > CPC > ERY/SMX (figure 2).

4. Discussion

Pharmaceuticals are an emerging class of environmental contaminants. The concern primarily about environmental presences of pharmaceuticals stem from the common knowledge of their modelled therapeutic effects in human and veterinary subjects and their incidental side effects and toxicity, the latter not always dosage (overdose) related but in a lot of cases idiosyncratic in nature. The several routes of the largely uncontrolled entry and egress of several chemical contaminant groups, including the pharmaceuticals, into the environment, and biotic networks following human use, is widely documented, and continues as an important subject for interdisciplinary scientific inquiry in the life sciences. Earlier study (Olarinmoye *et al.*, 2016) **hve** documented the presence of pharmaceuticals from several therapeutic classes in some environmental matrices especially surface water (Deo 2014., Patel *et al.*(2019).

Comment [PA15]: Reference

It is known that human use pharmaceuticals affect aquatic animals in several ways, most of **thes** disadvantageously, *in vitro*, with behavioural, genetic, and biochemical manifestations as proofs of derangements, seldom singly, but usually in a syndromous manner at environmental concentrations far below human therapeutic doses. Histology as a technique of biological inquiry usually suffices for the quick discovery of effects and lesions attributable to exposures to xenobiotic compounds and other sublethal stressors, in systematically affected target organs including the liver, kidneys, and in fish (Sinderman, 1979, Hinton *et al.*, 1990). Exposure of fish to a wide range of chemical toxicants almost invariably generates responses in these organs (Camargo *et al.*, 2006, Flores-Lopes *et al.*, 2011, Strzyżewska-Worotyńska *et al.*, 2017), indicating them as primary predilection sites for changes attributable to aquatic contamination and pollution. Such changes are readily detectable using microscopic methods for comparison against an agreed or standard "normal" parenchymatic architecture. The gills, are responsible for several functions in fish including primarily, respiration and gas exchange, osmoregulation and excretion are in direct contact with surrounding water as a result of these functions and anatomic placements. Thus any contaminant capable of generating a response (gills being very sensitive to alterations in water quality) would come in contact with these organs first and the gills are therefore "primary targets" of water borne contaminants (Poleksic *et al.*, 1994, Mazon *et al.*, 1999). Progressive, first order responses such as epithelial lifting and hypertrophy could be regarded as primary defence mechanisms activated in order to limit contaminant contact with deeper

Comment [PA16]: Since the 3 references are about an idea, put them together in one bracket in chronological order

Comment [PA17]: of

Comment [PA18]: reference

tissues and organs by impeding ingress since these responses increase the extents of the blood-environment interphase ([Hinton et al., 1990](#), [Poleksic et al., 1994](#)), which are reparable with the removal of contaminant (s) or depuration. Such lesions are almost always reported in investigations similar to the current one being reported and could be largely regarded as atypical, syndromic responses to any number of water contaminants as evidenced by such responses being elicited in fish in natural conditions. Their severity however could be selective and due to locational pollution indices ([Flores-Lopes et al., 2011](#), [Coutinho et al., 2000](#)). More chronic lesions such as the frankly regressive type including atrophy and necrosis as reported are symptomatic of “recovery potential” overload and are typically terminal if the requisite numbers of parenchymous cells are affected. The duration of the present study however may not account for these signs as observed which may explain the paucity of these signs in exposed *C. gariiepinus*. They could instead be attributed to individual idiosyncratic responses having nothing to do with contaminant concentrations, but more with individual sensitivities.

Comment [PA19]: Authors could link or compare their results, i.e., the values and features obtained, with those of other researchers who had used similar methods or conducted similar research.

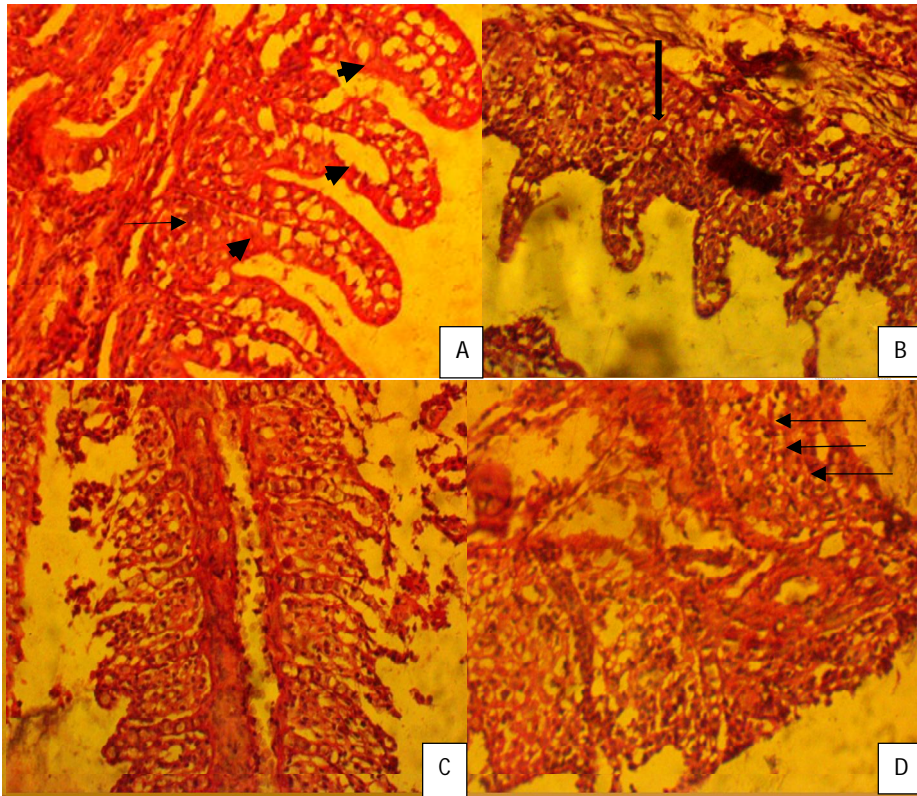


Figure 1: Micrographs showing histological changes following exposure to pharmaceuticals. Changes elicited were similar, in most cases progressive, reversible, and atypical as would be noticeable for a large number of chemical water contaminants. A: normal gill segment showing normal filament and lamellae; B: 1⁰ lamellar hyperplasia; C: lamellar necrosis; D: Lamellar cellular infiltrates.

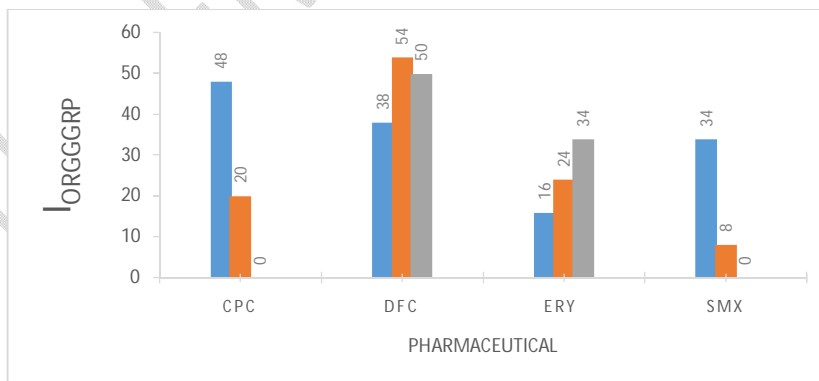


Figure 2: Banks of columns represent totals of quantified gill organ responses ($I_{orgG_{grp}}$) for each pharmaceutical toxicant. Blue bars represent minimum exposure concentrations, orange, second highest concentrations, and grey, the highest concentrations.

Conclusions

The current study reinforces the utility of histopathological changes of fish organs especially the gills, for the study of the effects of a myriad of emerging environmental contaminants alongside already established and acknowledged harmful entities. The nonspecific natures of recorded lesions make the inclusion of molecular and biochemical measurements alongside histology in test batteries, a more viable option for biomonitoring purposes.

COMPETING INTERESTS DISCLAIMER:

Authors have declared that no competing interests exist. The products used for this research are commonly and predominantly use products in our area of research and country. There is absolutely no conflict of interest between the authors and producers of the products because we do not intend to use these products as an avenue for any litigation but for the advancement of knowledge. Also, the research was not funded by the producing company rather it was funded by personal efforts of the authors.

References

- Bernet, D. Schmidt, H. Meier, W Burkhardt-Holm, P & Wahli, T (1999). Histopathology in fish: Proposal for a protocol to assess aquatic pollution. *Journal of fish diseases*, 22, 25-34.
- Camargo, MMP and Martinez, CBR (2006). Biochemical and physiological biomarkers in prochilodus lineatus submitted to in situ tests in an urban stream in southern Brazil. *Environmental Toxicology and Pharmacology*, 21, 61-69.
- Coutinho, C & Gokhale, C (2000). Selected oxidative enzymes and histopathological changes in the gills of cyprinus carpio and oreochromis mossambicus cultured in secondary sewage effluent. *Water research*, 34, 2997-3004.
- Deo, R.P. Pharmaceuticals in the Surface Water of the USA: A Review. *Curr Envir Health Rpt*, 113-122
- Flores-Lopes, F & Thomaz, AT (2011). Histopathologic alterations observed in fish gills as a tool in environmental monitoring. *Brazilian Journal of Biology*, 71, 179-188.
- Galus, M., Kirischian, N Higgins, S Purdy, J Chow, J Ranganarjan, S Li, H Metcalfe, C. and Wilson, JY (2012). Chronic, low concentration exposure to pharmaceuticals impacts multiple organ systems in zebrafish. *Aquatic Toxicology*, 15, 132-133.
- Gunnarsson, L, Jauhainen, A. Kristiansson E., Nerman, O. and Larsson, G 2008. Evolutionary conservation of human drug targets in organisms used for environmental risk assessments. *Environmental science and technology*, 42, 5807-13.
- Hinton, D. E. & Lauren, D.J. (1990). Liver structural alterations accompanying chronic toxicity in fishes potential biomarkers of exposure. In: McCarthy, J.F and Shugart, L.R (eds.) *Biomarkers of environmental contamination*. Boca Raton: Lewis publishers.
- Jayaprakash, C. & Shettu, N. 2013. Changes in the hematology of the freshwater fish, channa punctatus (Bloch) exposed to the toxicity of deltamethrin. *Journal of Chemical and Pharmaceutical Research*, 5, 178-183.
- Martins, M. and Costa, P.M (2015). The comet assay in environmental risk assessment of marine pollutants: Applications, assets and handicaps of surveying genotoxicity in non-model organisms. *Mutagenesis*, 30, 89-106.
- Mazon, A. and Fernandes, MN 1999. Toxicity and differential tissue accumulation of copper in the tropical freshwater fish p. Scrofa (prochilodontidae). *Bulletin of environmental contamination and toxicology*, 63, 794-804.
- Nunes, B., Verde, MF. & Soares, AM. (2015). Biochemical effects of the pharmaceutical drug paracetamol on anguilla anguilla. *Environ Sci Pollut Res Int*, 22, 11574-84.

Comment [PA20]: Authors should maintain uniformity in order of reference following the journal's guidelines. E.g., Bernet D, Schmidt H, Meier W, Burkhardt-Holm P, Wahli T. Histopathology in fish: Proposal for a protocol to assess aquatic pollution. *Journal of fish diseases*, 1999;22, 25-34.

- Nwani, C. D., Mkpadohi, B. N., Onyishi, G., Echi, P. C., Chukwuka, C. O., Oluah, S., N., & Ivoke, N. 2013. Changes in behavior and hematological parameters of freshwater african catfish *clarias gariepinus* (burchell 1822) following sublethal exposure to chloramphenicol. . *Drug and chemical toxicology*.
- Olarinmoye, O Bakare, A. Ugwumba, O & Hein, A (2016). Quantification of pharmaceutical residues in wastewater impacted surface waters and sewage sludge from lagos, nigeria. *Journal of Environmental Chemistry and Ecotoxicology*, 8, 14-24.s
- Manvendra Patel M, Rahul K, Kishor, K Todd, M, . Pittman C, and Dinesh Mohan, D (2019) Pharmaceuticals of Emerging Concern in Aquatic Systems: Chemistry, Occurrence, Effects, and Removal Method. *Chemical Reviews* 119 (6), 3510-3673.
- Poleksic, V. & Mitrovic-Tutundzic, V. (1994). Fish gills as a monitor of sublethal and chronic effects of pollution. . In: Müller, R. and Lloyd, R. (eds.) *Sublethal and chronic effects of pollutants on freshwater fish*. Oxford. U.K.: Fishing news books.
- Popoola, O. M. & Olufayo, M. O.-. 2007. Histological changes in the gills of oreochromis niloticus exposed to promethazine hydrochloride. *Journal of fisheries and aquatic science*., 2, 366-370.
- Ramos, A. S., Correia, A. T., Antunes, S. C., Goncalves, F. & Nunes, B. 2014. Effect of acetaminophen exposure in oncorhynchus mykiss gills and liver: Detoxification mechanisms, oxidative defence system and peroxidative damage. *Environ toxicological pharmacology*., 37, 1221-8.
- Rašković, B., ., Čičovački, S., ., Ćirić, M., Marković, Z. & Poleksić, V. 2016. Integrative approach of histopathology and histomorphometry of common carp (*cyprinus carpio* l.) organs as a marker of general fish health state in pond culture. *Aquaculture Research*, 47, 3455-3463.
- Rocco, L., Frenzilli, G., Zito, G., Archimandritis, A., Peluso, C. & Stingo, V. 2012. Genotoxic effects in fish induced by pharmacological agents present in the sewage of some italian water-treatment plants. *Environmental toxicology*, 27, 18-25.
- Sinderman, C. J. 1979. Pollution-associated diseases and abnormalities of fish and shellfish: A review. *Fishery bulletin*., 76, 717-727
- Sindermann, C. J. 1979. Pollution-associated diseases and abnormalities of fish and shellfish: A review. *Fishery Bulletin*, 76, 717-749.
- Strzyżewska-Worotyńska, E., Szarek, J., Babińska, I. & Gulda, D. 2017. Gills as morphological biomarkers in extensive and intensive rainbow trout (*oncorhynchus mykiss*, walbaum 1792) production technologies. *Environmental Monitoring and Assessment*, 189, 611.