

Original Research Article

EFFICACY OF LOCALISED APPLICATION OF TRANEXEMIC ACID AND MEFENAMIC ACID TABLET POWDER IN EXTRACTION SOCKETS FOR CONTROL OF POST EXTRACTION BLEEDING AND PAIN:A SPLIT-MOUTH RANDOMIZED CONTROLLED CLINICAL TRIAL

ABSTRACT:

Background: Post extraction bleeding and pain are two common complications in routine dental practice .There are no studies in which Tranexamic acid and Mefenamic acid combination powder is used locally to control post extraction bleeding and pain.

Methodology: This study was conducted in 18 patients indicated for orthodontic extraction of mandibular first premolar and right side was the study side in which pre crushed TRANSET MF powder was placed and compared to the left side which was the control side .Post extraction bleeding immediately and 30 min post extraction was compared along with pain using VAS pain scale on 1,2,3,7 th day post extraction..

Results: There was statistically significant difference in time of post extraction bleeding between study side (less time) and the control side .There is statistically significant difference in pain scale; less pain perceived in the study side than the control side.

Conclusion: This study is the first one to evaluate the efficacy of crushed TRANSET MF Tablet Powder in post extraction sockets and has shown significant results in reducing post extraction pain and bleeding with no local and systemic side effects .Hence this will be a simple and cost effective technique that can reduce both post extraction bleeding and pain

Registration Number: CTRI/2022/07/043744

Keyword: Post Extraction Bleeding, Post Extraction Pain, Tab TRANSET MF Tablet, Tooth Extraction

INTRODUCTION

Bleeding from the socket after extraction is one of the most commonly encountered complication in general dental practice. The incidence of post extraction bleeding varies from 0-26%. Uncontrolled post extraction bleeding can lead to severe blood loss [1,2]. The arrest of bleeding also known as hemostasis can be initially by simple vasoconstriction or by local or systemic means .Mechanical, thermal and chemical are various methods of hemostasis.[3] There are many hemostatic agents which are used locally and systemically. Local hemostatic agents include: Oxidised cellulose, fibrin glue, gelfoam. Systemic agents include:Tranexamic acid, Ethamsylate. Clot formation prevents blood loss, provides a scaffold for the adhesion of cells that will promote the healing process. Tranexamic acid at post extraction site prevents bleeding .It acts as an antifibrinolytic agent and its mechanism of action is clot stabilization by competitively inhibiting plasminogen. Tranexemic acid usage as a mouthwash to control bleeding has been proven with optimum results [4]

Mefenamic acid is an anthranilic acid derivative and comes under the classification of NSAIDs. Its mechanism of action is blockage of COX1 and COX 2 thus blocking the synthesis of prostaglandins and has analgesic anti inflammatory and antipyretic activity.[2] Another important complication, post extraction is alveolar osteitis which accounts for 1-4% after routine dental extractions. Tranexamic acid has been proven to reduce alveolar osteitis when applied locally.[5] Local application of Mefenamic acid and tranexamic acid can reduce the systemic side effects of the drugs and can increase the availability at the localised site .

METHODOLOGY

The present split-mouth randomized controlled clinical trial study was carried out in the Department of Oral and Maxillofacial Surgery, after obtaining clearance from the University Ethics Committee and registering for clinical trial with Clinical Trial Registry University– India CTRI/2022/07/043744. After obtaining ethics and research committee approval, patients visiting Department of Orthodontics who required bilateral mandibular 1st premolar extraction for orthodontic treatment were referred to Department of Oral and maxillofacial surgery. All participants in the study were required to sign an informed consent form. Special consent from parents/guardian was taken in case any patient was below 18 years of age .Inclusion criteria:Patients above 14 years of age and with bilateral mandibular premolars indicated for orthodontic extractions one tooth on each side. Exclusion criteria: Medically compromised patients

MATERIALS:

- TRANSET MF TABLET :**TRANEXEMIC ACID:MEFENAMICACID; 500MG:250 MG**
- MORTAR AND PESTLE
- LUCAS CURETTE
- Armamentarium for Tooth Extraction:
 - Local Anesthesia:Lignocaine HCl 2%
 - 2.5cc Syringe
 - Mandibular Premolar Extraction Forceps
 - Dials Periosteal Elevator
 - Gauze Pieces

This study was prospective in design.Simple random sampling method was considered.18 Clinical Cases of bilateral mandibular first premolar teeth indicated for orthodontic extraction was considered. ½ a tablet of TRANSET MF was pre crushed using Mortar and Pestle after removing the coating by scraping just before the procedure (Fig.1).

In the study side (right side) (Figure 2): Local anesthesia was given intraorally at the extraction site .Atraumatic extraction of the tooth was done under aseptic precautions. Following extraction, pre-prepared crushed TRANSET –MF powder was filled in the extraction socket by using a curette .This is followed by mild digital compression and post extraction bleeding time was noted till primary hemostasis was achieved. After 7 days patient was recalled for extraction of the mandibular premolar tooth on the control side (left side) and evaluation of healing on the control side .

In the control side (left side) (Figure 3) : Tooth was extracted in a similar manner as the study side but no TRANSET MF powder was placed post extraction. The time of bleeding post extraction, after mild

compression, was noted till primary hemostasis was achieved. Patient was recalled after 7 days for evaluation of healing.

Any presence of post extraction bleeding 30 min after the procedure was checked on both sides. TAB DICLOFENAC 50 mg SOS prescribed for both sides. VAS pain analogue scale was used to assess the pain on post op days 1,2,3,7. A follow up chart was given to the patient with VAS Scale both for study (right) side and control(left) side for post extraction days 1,2,3 along with time of intake of 1st analgesic orally and number of analgesics taken orally post extraction is noted which the patient had to fill and bring on the 7th day. VAS scale on 7th day was assessed by the clinician along with socket healing. Post extraction instructions were given.

RESULTS

The results obtained were statistically assessed. Statistical analysis was performed using SPSS Version 21 Software (Statistical Package of Social Sciences, IBM Statistics, USA). The normality assumption was verified using Shapiro Wilk's test. The Mann Whitney U Test was used to compare case and controls. P-value < 0.05 was considered statistically significant (Table 1). The participants consisted of 18 patients with bilateral mandibular first premolar teeth indicated for orthodontic extraction were considered. Time of bleeding till primary hemostasis was achieved was lower (statistically significant difference of $p < 0.001$) in study group than the control group. There was no bleeding 30 minutes post extraction in both the sides.

Post extraction pain is also lesser in the study group than in the control group and statistically significant difference of p value less than 0.001 is seen on the post extraction day 3 for pain. The average of number of Tablet Diclofenac 50 mg in study group was 3 while in the control group it was 6. In the study group the maximum time the patient had not taken an oral analgesic was 26 hrs while as in the control group it was 4hrs (Table 2). There was no incidence of alveolar osteitis / post extraction infection in both sides. Satisfactory healing was present in both sides.

DISCUSSION

The inflammatory process caused by tissue damage is responsible for the pain after tooth extraction [6]. The common method of post extraction pain control is the use of NSAIDS but these have significant side effects like gastrointestinal problems, nausea, and constipation when consumed orally [7]. In spite of all the advances in medicine, no single drug fits into the criteria of an ideal analgesic for post extraction [8]. NSAIDS although are considered safe have systemic side effects when taken orally hence local drug delivery methods are to be tried [9]. Transdermal NSAID patches are one of the methods by which post extraction pain can be controlled without taking them orally [10].

This present study uses an innovative and cost effective method of using TRANSET MF powder as local drug delivery in the post extraction socket. The statistical results ($p < 0.001$) have concluded that the post extraction pain is significantly less in the study side as compared to the control side. TRANSET MF tablet contains 500 mg tranexamic acid and 250 mg mefenamic acid and this study has proven that half a tablet applied locally reduces post extraction bleeding and post extraction pain respectively. The NSAIDS taken on the day of extraction of the tooth was considerably low in the study side as compared to the control side. Time of taking the first analgesic orally is also considerably late in the study side as compared to the control side.

Post extraction bleeding is another common complication encountered in extraction of teeth and the incidence varies from 0-26% [11]. Airway compromise is one rare but fatal complication which can arise due to post extraction hematoma [12]. Risk assessment before teeth extraction is important to avoid any bleeding complications. This includes lab investigations and a thorough medical history [13]. Although we have not done any lab investigations prior to extraction, a thorough medical history was taken.

Post extraction bleeding can lead to soft tissue hematoma ,severe blood loss and even airway compromise[14]Post extraction bleeding is difficult to control because of high vascularity and also exposure of the open socket to patient's tongue and fingers[15]. Tranexamic acid applied as solution in packs has an additional benefit of reducing incidence of alveolar osteitis according to Ajinath et al (2022) [16].

Tranexamic acid as an antifibrinolytic agent impedes proteolytic degradation of fibrin thus promoting wound healing and reducing incidence of alveolar osteitis[17]. It also has a positive effect in wound healing[18]. Different forms by which local application of tranexamic acid has been tried .One is TA release from alginate-hyaluronan sponges showed a controlled release up to 3 h, and it was faster in the presence of HA[19].

G Carter et al in a prospective randomised control trial has found that 4.8% Tranexamic acid for 2 day post op course is as effective as 5 day course in controlling bleeding in post dental extractions in patients on warfarin [20]. A literature review considering almost 8 clinical trials also stated the effectiveness of using hemostatic mouthwashes (mainly tranexamic acid) for patients on anticoagulant therapy without discontinuation of the drug[21] Glen Carter et al in 2003 suggested use of autologous fibrin glue intraoperatively along with tranexamic acid mouthwash as an effective method to control hemostasis[22]. In this study a powdered form of TRANSET MF tablet is used which is present for a longer time at the extraction socket thus increasing its time of action.

A systematic review suggested the use of single dose of mefenamic acid orally as highly effective in post extraction pain control.[23]In double blinded placebo controlled studies, Mefenamic acid was assessed for relief of post extraction dental pain and doses of 250 mg every 4-6 hrs after procedure was found superior to use of placebo and also a lesser extent superior to acetylsalicylic acid[24]Cooper et al in his study suggested use of Mefenamic acid 666 mg and then by Mefenamic acid 333 mg three times daily is both safe plus effective as mefenamic acid 500 mg - mefenamic acid 250 mg QID in controlling pain[25]The tablet used in this study is also half in number hence the amount of tranexamic acid and mefenamic acid used is very less. This study was conducted in healthy patients with no bleeding disorders hence further studies in patients with coagulopathies can be trialed.

CONCLUSION

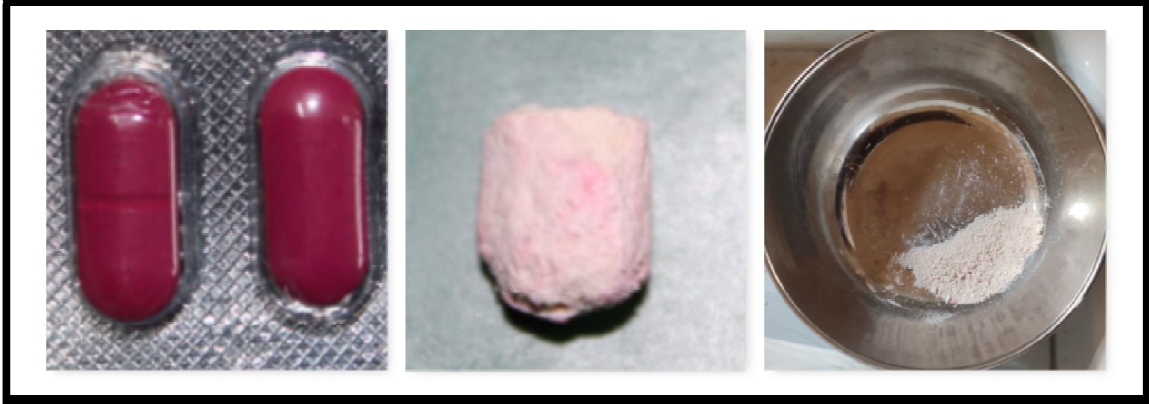TRANSET MF Tablet Powder in post extraction sockets has shown significant results in reducing post extraction pain and post extraction bleeding with no local and systemic side effects .Hence this is a simple innovative and cost effective technique which reduces both post extraction bleeding and pain without use of oral/systemic medications

REFERENCES

1. Brancaccio Y, Antonelli A, Barone S, Bennardo F, Fortunato L, Giudice A. Evaluation of local hemostatic efficacy after dental extractions in patients taking antiplatelet drugs: A randomized clinical trial. *Clinical Oral Investigations*. 2021 Mar;25(3):1159-67.
2. Talimkhani I, Jamalpour MR, Babaei H, Faradmal J. Comparison of intra-socket bupivacaine administration versus oral mefenamic acid capsule for postoperative pain management following removal of impacted mandibular third molars. *Journal of Oral and Maxillofacial Surgery*. 2019 Jul 1;77(7):1365-70.
3. Kavin T, Aravindh RJ, Narendar R, Indrakumar SP. Assessment and comparison of the hemostatic efficacy of ferrum phosphoricum against other conventional methods in minor oral surgical procedures.
4. Pabinger I, Fries D, Schöchl H, Streif W, Toller W. Tranexamic acid for treatment and prophylaxis of bleeding and hyperfibrinolysis. *Wiener klinische Wochenschrift*. 2017 May;129(9):303-16.
5. Anand KP, PATro S, MohAPATrA A, MiShrA S. The efficacy of Tranexamic acid in the reduction of incidence of dry socket: an Institutional double blind study. *Journal of clinical and diagnostic research: JCDR*. 2015 Sep;9(9):ZC25
6. Primosch RE, Nichols DL, Courts FJ. Comparison of preoperative ibuprofen, acetaminophen, and placebo administration on the parental report of postextraction pain in children. *Pediatric dentistry*. 1995 Jan 1;17:187-.
7. Ruoff G, Lema M. Strategies in pain management: new and potential indications for COX-2 specific inhibitors. *Journal of pain and symptom management*. 2003 Feb 1;25(2):21-31.
8. Shaik MM, Kumar J, Mobina S, Satyanarayana N, Sunitha P. Comparative study of tramadol and ketorolac in the pain management of third molar tooth extraction. *Journal of College of Medical Sciences-Nepal*. 2010;6(1):35-43.
9. Haley RM, von Recum HA. Localized and targeted delivery of NSAIDs for treatment of inflammation: A review. *Experimental Biology and Medicine*. 2019 Apr;244(6):433-44.
10. Bhaskar H, Kapoor P. Comparison of transdermal diclofenac patch with oral diclofenac as an analgesic modality following multiple premolar extractions in orthodontic patients: A cross over efficacy trial. *Contemporary clinical dentistry*. 2010 Jul;1(3):158.
11. Nagraj SK, Prashanti E, Aggarwal H, Lingappa A, Muthu MS, Krishanappa SK, Hassan H. Interventions for treating post-extraction bleeding. *Cochrane Database of Systematic Reviews*. 2018(3).
12. Moghadam HG, Caminiti MF. Life-threatening hemorrhage after extraction of third molars: case report and management protocol. *Journal-Canadian Dental Association*. 2002 Dec 1;68(11):670-5.
13. McCormick NJ, Moore UJ, Meechan JG. Haemostasis part 1: the management of post-extraction haemorrhage. *Dental update*. 2014 May 2;41(4):290-6.
14. Yi S, Oh JS, Youn GH, Chung K, Jung S, Park HJ, Oh HK, Kook MS. Acute Airway Obstruction Secondary to Lingual Hematoma after Lower Third Molar Extraction: A Case Report. *Journal of Korean Dental Science*. 2014;7(1):43-7.
15. Moran IJ, Richardson L, Heliotis M, Bewick A. A bleeding socket after tooth extraction. *BMJ*. 2017 Apr 3;357.

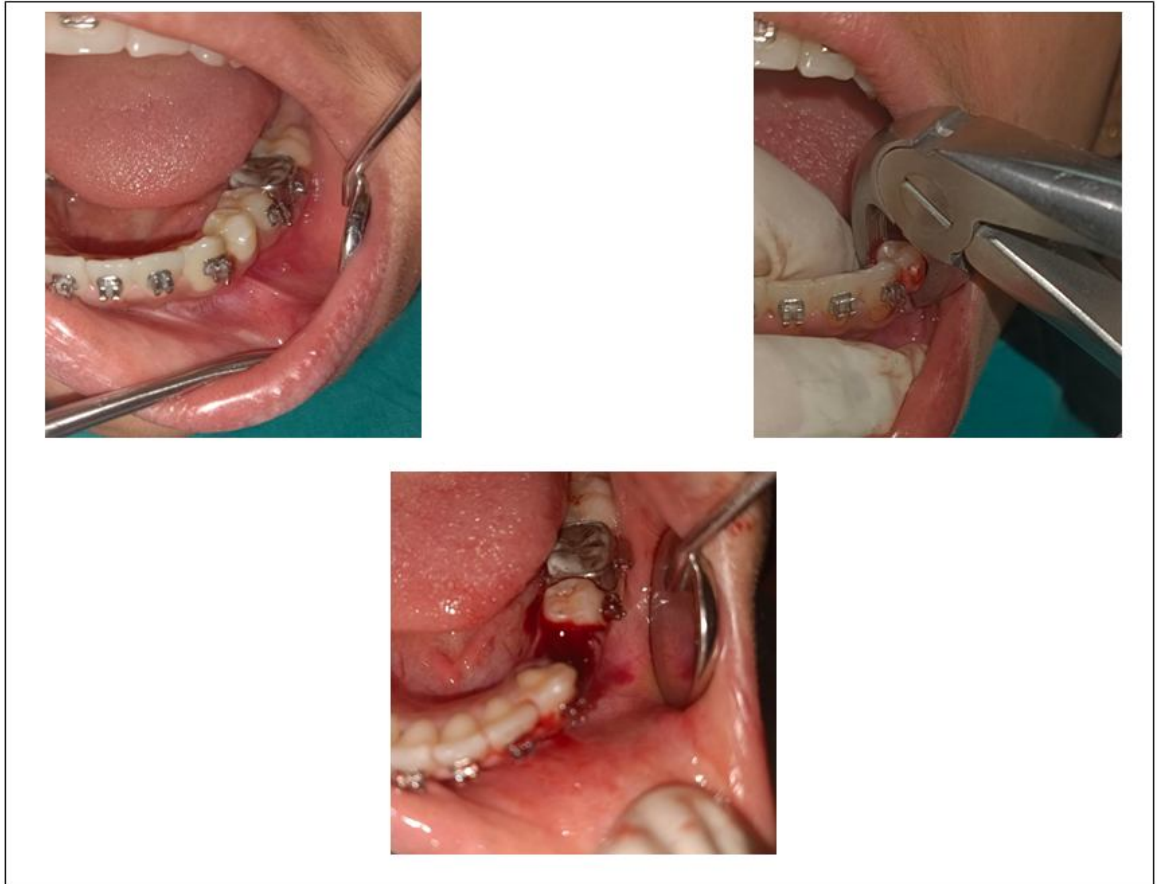
16. Jadhav AN, Shushma G, Deshmukh VD. Efficacy of tranexamic acid in prevention of alveolar osteitis following surgical removal of impacted mandibular third molar. *National Journal of Maxillofacial Surgery*. 2022 Aug 1;13(4):85.
17. Anand KP, Patro S, Mohapatra A, Mishra S. The efficacy of Tranexamic acid in the reduction of incidence of dry socket: an Institutional double blind study. *Journal of clinical and diagnostic research: JCDR*. 2015 Sep;9(9):ZC25.
18. Björlin G, Nilsson IM. The effect of antifibrinolytic agents on wound healing. *International journal of oral and maxillofacial surgery*. 1988 Aug 1;17(4):275-6.
19. Catanzano O, D'Esposito V, Formisano P, Boateng JS, Quaglia F. Composite alginate-hyaluronan sponges for the delivery of tranexamic acid in postextractive alveolar wounds. *Journal of pharmaceutical sciences*. 2018 Feb 1;107(2):654-61.
20. Carter G, Goss A. Tranexamic acid mouthwash—a prospective randomized study of a 2-day regimen vs 5-day regimen to prevent postoperative bleeding in anticoagulated patients requiring dental extractions. *International journal of oral and maxillofacial surgery*. 2003 Jan 1;32(5):504-7.
21. Patatianian E, Fugate SE. Hemostatic mouthwashes in anticoagulated patients undergoing dental extraction. *Annals of Pharmacotherapy*. 2006 Dec;40(12):2205-10.
22. Carter G, Goss A, Lloyd J, Tocchetti R. Tranexamic acid mouthwash versus autologous fibrin glue in patients taking warfarin undergoing dental extractions: a randomized prospective clinical study. *Journal of oral and maxillofacial surgery*. 2003 Dec 1;61(12):1432-5.
23. Moll R, Derry S, Moore RA, McQuay HJ. Single dose oral mefenamic acid for acute postoperative pain in adults. *Cochrane Database of Systematic Reviews*. 2011(3).
24. Cimolai N. The potential and promise of mefenamic acid. *Expert review of clinical pharmacology*. 2013 May 1;6(3):289-305.
25. Cooper SA, Hersh EV, Betts NJ, Wedell D, Quinn P, Lamp C, Herman D, Reynolds D, Gallegos LT, Reynold B. Multidose analgesic study of two mefenamic acid formulations in a postsurgical dental pain model. *Analgesia*. 1994 Jan 1;1(1):65-71.

Figure 1: TRANSET MF precrushed tablet



UNDER PEER REVIEW

Figure 2: STUDY SIDE (with Crushed TRANSET MF Tablet inside the extracted socket)



UNDEL

Figure 3: CONTROL SIDE (conventional extraction)

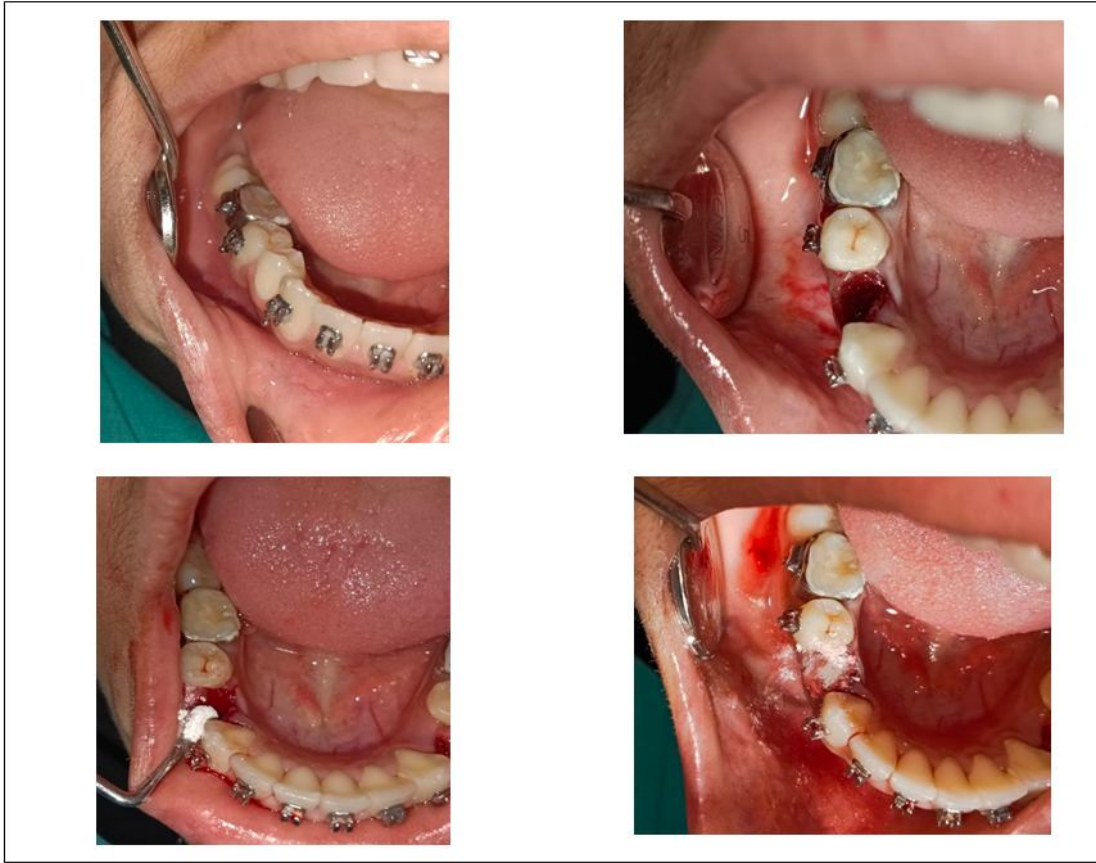


Table 1: Intergroup Comparison

Variables	Groups				Mann Whitney U test value	p value
	Case		Control			
	Median	IQR	Median	IQR		
Time of bleeding	20	16	55	30	42.00	<0.001
VAS PAIN SCALE Day 1	3	1	5	3	114.50	0.121
VAPAIN SCALE Day 2	2	3	2	2	112.00	0.105
VAS PAIN SCALE Day 3	0	0	1.5	2	63.00	<0.001
VAS PAIN SCLAE Day 7	0	0	0	1	125.00	0.105

UNDER PEER REVIEW