

Case report

Hypofibrinogenemia Revealing Localized Intravascular Coagulopathy In A Child With Venous Malformations: A Case Report

ABSTRACT:

AIMS: VMs are slow-flow vascular malformations present at birth. Only 1% are multifocal. These lesions are complicated by LIC characterized by elevated D-dimer and decreased fibrinogen levels.

The aim of this article is to report a rare case of multifocal VMs complicated with LIC, revealed by low fibrinogen level. To the best of our knowledge, no case has been reported to date in the Maghreb countries.

PRESENTATION OF CASE: A 14-year-old male patient with multifocal VMs presented for appearance of a lateral cervical mass, rapidly increasing in size. Cervical CT scan revealed a tumor-like right latero-cervical formation, measuring (67x65x96.8) mm. The patient underwent an excision of a vascular-like latero-cervical mass, complicated by a postoperative hematoma for which he was reoperated to ensure hemostasis. Haematological investigations have essentially demonstrated an elevation of the D-dimer, with a very low fibrinogen level. These biological abnormalities occurring in association with venous malformations has been termed LIC.

DISCUSSION: The correlation between LIC and VMs is known. It is characterized by the elevation of D-dimers and fibrin degradation products, low levels of fibrinogen, and sometimes minor-to-moderate thrombocytopenia. Low molecular weight heparin can be used for prevention from decompensation of severe LIC into disseminated intravascular coagulopathy (DIC).

CONCLUSION: Recognizing LIC in patients with VMs is essential for detecting clinical and biological abnormalities, optimizing therapeutic management and thus preventing hemorrhagic and thromboembolic risks which may be life-threatening.

Keywords: Venous malformations, localized intravascular coagulopathy, hypofibrinogenemia, D-dimers.

INTRODUCTION:

Venous malformations (VMs) are slow-flow vascular malformations in the venous system. They constitute more than half of all vascular abnormalities, with an approximate prevalence of 1% in the general population. The VMs might be complicated by a consumer coagulopathy known as localized intravascular coagulopathy (LIC) which is characterized by elevated D-dimers and when severe, low fibrinogen levels.

LIC in VMs is generally well tolerated in everyday life, but its clinical severity lies in the possibility of progressing to serious thrombo-hemorrhagic disorders with risk of transformation into Disseminated Intravascular Coagulopathy (DIC), which can be life-threatening.

The aim of this article is to report a rare case of multifocal VMs complicated with localized intravascular coagulation, revealed by low fibrinogen level. To the best of our knowledge, no similar case has been reported to date in the Maghreb countries.

PRESENTATION OF CASE

A 14-year-old male patient, eldest sibling (3 brothers and 1 sister), from a consanguineous marriage (parents are paternal cousins), with multiple congenital venous malformations, presented for appearance, 18 days previously, of a painless right lateral cervical mass, rapidly increasing in size.

Cervical examination revealed right submandibular and submental swelling; soft, painless and mobile, measuring about 7 cm in diameter, with inflammatory skin. The general examination showed several painless soft masses, evolving for 8 years, present at the right axillary, dorsal, lower end of the right thigh, facing the 1st right metacarpal, right inguinal region and right hip (**Figure 1- 2**).

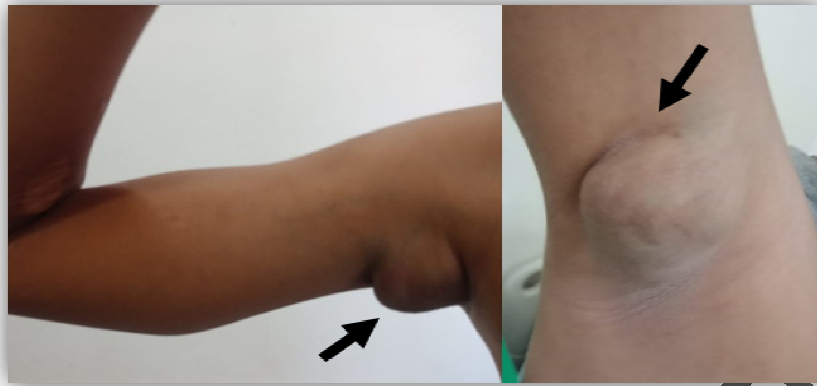

Fig. 1. Venous malformation of the right axilla

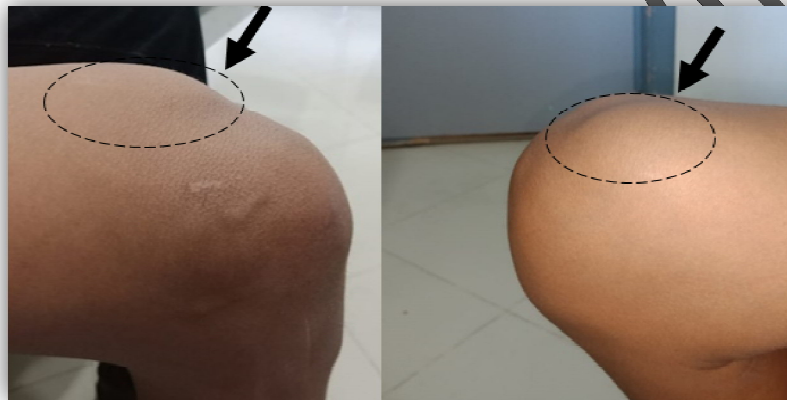

Fig. 2. Venous malformation of the lower end of the right thigh

The CT scan revealed a tumor-like right latero-cervical formation, measuring (67x65x96.8) mm, well defined, heterodense, site of calcifications, heterogeneously enhanced after injection of PDC (**Figure 3**).

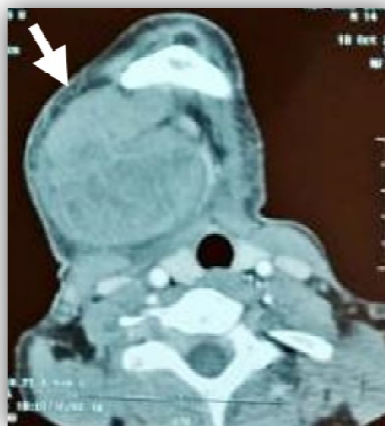

Fig. 3. CT scan results showing tumor-like right latero-cervical formation

The patient was therefore scheduled for exploratory cervicotomy, an excision of the mass with the submandibular gland was performed. On postoperative day 1, the patient presented hematoma with active bleeding and hemostasis was assured. In the post-operative period, the bleeding persisted with reappearance of the hematoma, which was evacuated by syringe punctures. Evolution was marked by the gradual regression of bleeding.

Postoperative assessments carried out in our Laboratory, revealed an anemia at 9.1 g/dl with thrombocytopenia at 125,000 elements/mm³, with a low prothrombin level at 47%, an increase in activated partial thromboplastin time to 37.5 seconds and a **deep hypofibrinogenemia at 0.55 g/l**, rechecked on a 2nd sample respecting the pre-analytical conditions. The level of D-Dimer was high, while the level of coagulation factors of the common pathway was normal (**DIC ELIMINATED**). In front of the deep hypofibrinogenemia and the suspicion of a congenital origin, an assessment was carried out in the parents and the siblings (3 boys and 1 girl), objectifying a normal level of fibrinogen (**CONGENITAL ORIGIN ELIMINATED**).

The determination of fibrinogen level in our Laboratory is carried out by the Von Clauss Functional Method, which is an indirect measurement of fibrinogen, based on the clotting time of a diluted citrated plasma, after addition of an excess of thrombin. The presence of a substance with antithrombin activity in the plasma can interfere with the time measurement and can lead to a false result, in particular a high level of D-dimers. To confirm that it is a **true hypofibrinogenemia**, a determination of the fibrogen by **heat precipitation**(1) was carried out following the steps below:

- ✓ Fill a hematocrit tube by capillary action with the patient's platelet-poor plasma, when it is full, the upper opening is closed with the index finger.
- ✓ With the microtube held vertically, push its lower part into the wax in circular movements.
- ✓ Place the microtube vertically for 15 minutes in a hemolysis tube full of water placed in a water bath at 56°C.
- ✓ Centrifuge the microtube for 3 minutes at maximum speed.

The height of the packed precipitate above the wax cap is measured in millimeters by the microscopic scale. Results and interpretation are summarized in **Figure 4**.



	<i>Our patient</i>	<i>Normal control patient</i>
<i>Fg rate by « Clauss »</i>	0.76 g/l	3 g/l
<i>Fg rate by « heat precipitation »</i>		
<i>Lecture</i>	No precipitation	16 mm precipitation
<i>Interpretation</i>	Fg less than 1.5 is not detected by this technique.	3.2 g / l (the same as the Clauss method)

Fig.4. Results of determination of fibrinogen by heat precipitation of our case compared with a normal control sample

The measurement found is converted into fibrinogen concentration according to a conversion table (precipitation in mm and its equivalent in g/l).

Finally, given a deep hypofibrinogenemia with a high D-dimer level in a child with venous malformations, **the diagnosis of LIC** was retained.

DISCUSSION:

Vascular malformations are present **since birth** and grow proportionally with the growth of patient(2). They are vascular channels, resulting from an abnormal angiogenic development, affecting all types of 6

VM is the most common congenital slow-flow vascular malformation, occurring anywhere in the body, most often in the extremities, and the cervico-facial area (3). Their approximate **prevalence** is 1% in the general population.

(4,5) The majority of venous malformations are **localized** (93%) however, they may be extensive and **multifocal** (1%) (6); as in the case of our patient, with no reported malignant transformation.

Extensive VMs are commonly **associated** with systemic coagulation disorders(7). Coagulopathy limited to vascular injury is called **LIC** (4,5). The association between VMs and LIC has been reported in several studies, estimated at 42 to 88% of venous and venous-lymphatic malformations(8).

The etiology of LIC in MV remains uncertain until now, according to different authors its pathogenesis is probably linked to the Virchow triad (9–11), which includes: venous blood stasis, damage to endothelial cells in the venous wall and a state of hypercoagulability. The extent of VM correlates with the severity of LIC and the overall risk of thrombosis formation (9,12).

“Structural or functional abnormalities of endothelial cells in these lesions lead to activation of coagulation and the formation of thrombosis” (9,10). “Thus, the endothelial lesion exposes the subendothelial collagen and the endogenous coagulation process is initiated. Thrombin converts fibrinogen into fibrin, which tightly intertwines platelets to form an irreversible clump leading to the formation of thrombosis” (10).

The static flow and accumulation of blood, due to variations in the size of the lumen, may have an additional procoagulant effect, producing a local shear force, which induces platelet aggregation and thrombosis (11). Blood flow through VMs is sometimes disrupted, turbulent and stagnant(9).

Due to the stagnation of the blood, the constant activation of coagulation within these malformations leads to the production of thrombin and consequently to the formation of phleboliths (11,16). The resulting fibrinolysis results in high levels of fibrin degradation products, such as D-dimeric epitopes (13,14) and reduced levels of fibrinogen (7).

Different studies have shown that the two main laboratory **features** of LIC are high D-dimers and, when severe, low fibrinogen levels, usually with a normal platelet count (5,9,15). In a retrospective study, 19 of 24 patients with LIC associated with extensive and painful VMs in the limbs had elevated **D-dimer levels**(9). Severe LIC found in six patients was characterized by a **concomitant low level of fibrinogen**(9). In 2008, a prospective study including 140 patients with MVs, found that 59 cases (42%) had a **high D-dimer** level and six cases had a **low level of fibrinogen**(5). Hung et al published a study including (13)24 children with MVs and LIC, where plasma **D-dimers** were increased in 33.3% of cases and were significantly increased in multifocal MV ($p = 0.028$) (25).

Studies have shown that **D-dimers** are a **highly specific** marker (96.5%) for VMs compared to other vascular malformations (13) and especially for the formation of thrombi and fibrinolysis linked to LIC (5,16). However, the **sensitivity is only moderate** (43%), this is because small or solitary VMs do not cause enough clotting to lead to systemic elevations in D-dimer levels (16) . Combined adult and pediatric case series showed that 42 to 58% of patients with large, extensive or multiple VMs had elevated levels of **D-dimer**. Overall, 6-10% of patients had **concurrently low fibrinogen levels**(5,12), usually with normal platelet counts (5).

“In the context of large or multifocal venous malformations, **elevated D-dimer** levels represents a marker of CIL linked to localized thrombosis occurring at sites of stagnant flow in these malformations” (5,12). “A **low fibrinogen** level has been reported in 4 to 5% of cases, with higher D-dimers and larger malformations, and according to the authors, this may indicate a higher risk of bleeding complications” (5,12).

“Thus a **low fibrinogen level** reflects a high consumption due to coagulation associated with high fibrinolysis and an increased risk of bleeding” (5) as is the case in our patient.

“Abnormal clotting times are not a feature of LIC and herald transformation to DIC” (9). Likewise, Domp martin et al reported that “relevant coagulation factors are not significantly involved in the LIC coagulation cascade” (5).

This is confirmed in our case, who had a preoperative hemostasis assessment with correct clotting times and normal clotting factor levels. Postoperatively, the hemostasis assessment was disturbed with a collapsed rate of fibrinogen. The operative procedure was probably a factor in the transformation of LIC into DIC responsible for significant bleeding postoperatively.

D-dimers represent an effective monitoring marker **to prevent progression from LIC to DIC**, therefore it is recommended to have an initial measurement and to perform repetitive measurements during episodes of acute pain and before an invasive procedure (12). LIC should be distinguished from other coagulation abnormalities occurring with other pediatric vascular abnormalities(9).

There are different therapeutic possibilities. Sclerotherapy, endovascular laser or operative excision may be indicated depending on the location of VMs, their size and extent (13). However, as has been clarified before, these procedures themselves can exacerbate LIC and, in extreme cases, produce DIC with life-threatening

thromboembolic complications (9,17). According to various authors, the potential worsening of LIC with DIC requires preventive management by LMWH (5), so the latter is considered the only effective treatment (2,5).

CONCLUSION:

Venous malformations are frequently accompanied by coagulopathy, called LIC, which should be systematically sought out because it is the source of many hemorrhagic and thrombotic complications, the most serious one is transformation into DIC with the risk of death.

From a pathophysiological point of view, several hypotheses suggest that LIC takes up all the components of the Virchow triad, leading to local activation of coagulation and is essentially characterized by an elevation of D-dimers, and in the event of severe LIC; a low level of fibrinogen.

Nowadays, in addition to treating VMs, the most common method used to control LIC in VMs is still believed to be subcutaneous injection of LMWH, while alternative drugs are being tested in clinical trials.

However, further studies are needed to better understand the alterations in hemostasis secondary to venous vascular malformations and the modalities of treatment with LMWH.

Consent

As per international standard or university standard, parental(s) written consent has been collected and preserved by the author(s).

Ethical Approval:

As per international standard or university standard written ethical approval has been collected and preserved by the author(s).

REFERENCES:

1. Desvignes P, Bonnet P. Direct determination of plasma fibrinogen levels by heat precipitation. A comparison of the technique against thrombin clottable fibrinogen with spectrophotometry and radial immunodiffusion. Clin Chim Acta. févr 1981;110(1):9-17.

2. Chaurasia AK, Gupta P, Purwar N. Chronic Localized Intravascular Coagulation in a Case of Sporadic Multifocal Venous Malformations with Phleboliths. *J Postgrad Med Educ Res.* sept 2017;51(3):144-9.
3. Behraves S, Yakes W, Gupta N, Naidu S, Chong BW, Khademhosseini A, et al. Venous malformations: clinical diagnosis and treatment. *Cardiovasc Diagn Ther.* déc 2016;6(6):557-69.
4. Mulliken JB, Glowacki J. Hemangiomas and vascular malformations in infants and children: a classification based on endothelial characteristics. *Plast Reconstr Surg.* mars 1982;69(3):412-22.
5. Domp Martin A, Acher A, Thibon P, Tourbach S, Hermans C, Deneys V, et al. Association of Localized Intravascular Coagulopathy With Venous Malformations. *ARCH DERMATOL.* 2008;144(7):5.
6. McRae MY, Adams S, Pereira J, Parsi K, Wargon O. Venous malformations: Clinical course and management of vascular birthmark clinic cases. *Australas J Dermatol.* févr 2013;54(1):22-30.
7. Zhuo KY, Russell S, Wargon O, Adams S. Localised intravascular coagulation complicating venous malformations in children: Associations and therapeutic options: Localised intravascular coagulation. *J Paediatr Child Health.* août 2017;53(8):737-41.
8. Mulliken JB, Burrows PE, Fishman SJ. *Mulliken and Young's Vascular Anomalies: Hemangiomas and Malformations.* Oxford University Press; 2013. 1139 p.
9. Mazoyer E, Enjolras O, Laurian C, Houdart E, Drouet L. Coagulation abnormalities associated with extensive venous malformations of the limbs: differentiation from Kasabach–Merritt syndrome. *Clin Lab Haematol.* 2002;24(4):243-51.
10. Han YY, Sun LM, Yuan SM. Localized intravascular coagulation in venous malformations: A system review. *Phlebol J Venous Dis.* févr 2021;36(1):38-42.
11. Adams DM. Special considerations in vascular anomalies: hematologic management. *Clin Plast Surg.* janv 2011;38(1):153-60.
12. Mazoyer E, Enjolras O, Bisdorff A, Perdu J, Wassef M, Drouet L. Coagulation disorders in patients with venous malformation of the limbs and trunk: a case series of 118 patients. *Arch Dermatol.* juill 2008;144(7):861-7.
13. Hung J, Leung M, Liu C, Fung D, Poon W, Yam F, et al. Venous Malformation and Localized Intravascular Coagulopathy in Children. *Eur J Pediatr Surg.* 18 avr 2016;27(02):181-4.
14. Budge EJ, Khalil Allam MA, Mechie I, Scully M, Agu O, Lim CS. Venous malformations: Coagulopathy control and treatment methods. *Phlebol J Venous Dis.* 6 déc 2020;026835552097291.
15. Hermans C, Dessomme B, Lambert C, Deneys V. Malformations veineuses et coagulopathie. *Ann Chir Plast Esthét.* août 2006;51(4-5):388-93.
16. Domp Martin A, Ballieux F, Thibon P, Lequerrec A, Hermans C, Clapuyt P, et al. Elevated D-dimer level in the differential diagnosis of venous malformations. *Arch Dermatol.* nov 2009;145(11):1239-44.
17. Simon F, Le Clerc N, Salvan D, Sauvaget E, Faucon B, Borsik M, et al. Diode endovascular laser treatment in venous malformations of the upper aerodigestive tract. *J Cranio-Maxillofac Surg.* 1 mai 2016;44(5):533-7.