

HYPERTROPHIC CARDIOMYOPATHY SIMULATING ACUTE ANTERIOR MYOCARDIAL INFARCTION: CASE REPORT

Abstract

Electrocardiographic changes resulting from hypertrophic cardiomyopathy may mimic an acute coronary syndrome. We report a case of 57 years old man, with history of smoking, presented to the emergency department with chest pain and electrocardiographic findings of a ST elevation in the precordial leads from V1 to V4. He was treated as an acute ST-elevation myocardial infarction and transferred to our catheter lab. The coronary angiography did not reveal any coronary lesion. Transthoracic echocardiography, and cardiac magnetic resonance imaging were consistent with hypertrophic cardiomyopathy.

Keywords: Acute myocardial infarction, Hypertrophic cardiomyopathy, ST segment elevation.

INTRODUCTION:

“Hypertrophic cardiomyopathy (HCM) is the most common hereditary cardiac disease and the most frequently found cardiomyopathy” [1]. HCM represents a very broad nosological framework and can be responsible for different clinical pictures. Among these pictures, there is a clinically painful form, with a symptomatology that can simulate a myocardial infarction, and the presence of repolarization disorders on the electrocardiogram contributes to this confusion.

CASE REPORT:

We report a case of a 57 years-old man, who was admitted to the emergency for a constrictive, retrosternal chest pain. Past medical history was non contributory except for smoking. There was no family history of sudden cardiac death.

The patient's vital signs included the following: blood pressure was 130/80 mm Hg, resting heart rate was 85 beats/min, respiratory rate was 16 breaths/min, oxygen saturation was 97%, and temperature was 37.3°C.

Cardiac auscultation revealed a 4/6 systolic murmur over the apex.

There were no signs of pulmonary congestion, no congested neck veins and no lower limb edema.

The initial ECG revealed a ST elevation in the precordial leads from V1 to V4 (Figure 1). The initial diagnosis of acute coronary syndrome (ST elevation myocardial infarction) was established.

After initiating treatment by Clopidogrel (300 mg) ,Aspirin (300 mg), and intravenous heparin, the patient was immediately transferred to our catheter lab.

The coronary angiography didn't reveal any coronary lesion.

The echocardiography showed symmetrical parietal hypertrophy with a thickness of up to 17 mm at the side wall (Figure 2), a non-dilated left ventricle with normal LV systolic function and revealed an intra-cavity obstruction with a peak systolic pressure gradient at 37 mm Hg at rest.

Holter monitor showed a sinus rhythm with infrequent asymptomatic premature atrial contractions and no ventricular ectopy.

The cardiovascular magnetic resonance (CMR) confirmed the diagnosis of hypertrophic cardiomyopathy (Figure 3).

The patient received a medical treatment including a β -blocker. After 3 months, he was asymptomatic, whereas transthoracic echocardiography showed a gradient of 20 mmHg across the left ventricular outflow tract obstruction (LVOT).

DISCUSSION:

“The HCM is the most common genetic disease associated with more than 1000 mutations in 11 genes [1,2], and the most common cause of sudden death in young patients”. “This causes the heart to become abnormally thick, particularly at the septum between the left and right sides of the heart, which may cause obstruction of blood flow from the heart during each contraction”. [2]

“HCM can have many clinical manifestations. While some people have no symptoms, others may present chest pain, dyspnea, or fainting, especially on exertion” [2].

Chest pain on exertion or at rest is part of the clinical picture in 40-50% of cases. There are many possible explanations for this, which are still debated: pathology of the small intramyocardial vessels [3], compression of the septal perforating arteries in systole, spasm of the small coronary arteries [4], limitation of the possibility of oxygen extraction in the event of increased needs and, finally, insufficient capillary density [4].

“In 75% to 95% of patients with HCM, the ECG shows changes in the pattern of left ventricular hypertrophy. 25% of patients had left anterior hemiblock or left bundle branch block. Pseudo infarct Q waves are typical features of HOVM, giant negative T wave morphology are typical features of HNCM, and Hyperacute negative T waves are characteristic of the apical form of HCM” [6].

“A microvascular dysfunction is a well-recognized feature of HCM, and its severity is a strong predictor of clinical deterioration and death. This dysfunction may precede clinical deterioration by several years” [6]. “Individuals can also experience palpitations due to abnormal electrical activity within the heart that causes abnormal heart rhythms due to thickening of the heart muscle and disturbance of the muscle cells. The clinical diagnosis of HCM is usually made using cardiac imaging, most commonly two-dimensional echocardiography and, increasingly, CMR” [7].

Today, CMR is a complementary imaging technique to echocardiography, which can quantify and localize left ventricular hypertrophy by SSFP and assess tissue characteristics by DCE. In addition, previous studies have shown that CMR can diagnose HCM in the lateral and apical wall segments with higher sensitivity than echocardiography [8].

Negative inotropes, such as beta-blockers or non dihydropyridine calcium channel blockers, are the most appropriate initial therapeutic interventions [9].

“ β -blockers and calcium channel blockers reduce the obstructive gradient in HCM by reducing catecholamine-mediated contractility” [10]. “Dual-chamber pacing has been used in drug-refractory HCM. Right ventricular pacing with a short AV delay results in asynchronous LV contraction and reduces LVOT obstruction” [11]. “ICDs are the primary therapy for the prevention of SCD and are a class I indication for secondary prevention in patients with a history of ventricular fibrillation or hemodynamically unstable ventricular tachycardia” [12].

CONCLUSION:

HCM is a clinical condition that can cause various complications.

It can be hidden behind a wide variety of cardiological clinical pictures. Among these masks, there is a clinical form of algesic type, with a symptomatology that can simulate unstable angina or myocardial infarction.

Its diagnosis can rule out ACS in patients with atypical ST-segment elevation. TTE is usually sufficient to establish a diagnosis and initiate appropriate treatment.

Consent

As per international standard or university standard, patient(s) written consent has been collected and preserved by the author(s).

Ethical Approval:

As per international standard or university standard written ethical approval has been collected and preserved by the author(s).

REFERENCES:

[1] Alpendurada F, Prasad SK. The missing spade: apical hypertrophic cardiomyopathy investigation. *Int J Cardiovasc Imaging* 2008; doi 10.1007/s10554-008-9335-z.

[2] Alcalai R, Seidman JG, Seidman CE. Genetic basis of hypertrophic cardiomyopathy: from bench to the clinics. *Journal of Cardiovascular Electrophysiology*. 2008;**19**(1):104–110. [PubMed] [Google Scholar]

[3] Maron BJ, Wolfson JK, Epstein SE, Roberts WC. Intramural (“small vessel”) Coronary artery disease in hypertrophic cardiomyopathy. *Circulation* 1986;**8** :545-57

[4] Roos-Hesselink JW, Ruys TP, Stein JI, Thilen U, Webb GD, Niwa K, Kaemmerer H, Baumgartner H, Budts W, Maggioni AP, Tavazzi L, Taha N, Johnson MR, Hall R, Investigators R. Outcome of patients with

structural or ischaemic heart disease: results of a registry of the European Society of Cardiology. *Eur Heart J* 2013;34:657–665.

[5] C. Prinz, M. Farr, D. Hering, D. Horstkotte, and L. Faber, “The diagnosis and treatment of hypertrophic cardiomyopathy,” *Deutsches Ärzteblatt international*, vol. 108, no. 13, pp. 209–215, 2011.

[6] Eriksson MJ, Sonnenberg B, Woo A, et al. Long-term outcome in patients with apical hypertrophic cardiomyopathy. *J Am Coll Cardiol*. 2002;39:638-645.

[7] Jan MF, Todaro MC, Oreto L, Tajik AJ. Apical hypertrophic cardiomyopathy: present status. *Int J Cardiol* 2016;222:745-59.

[4] Rickers C, Wilke NM, Jerosch-Herold M, et al. Utility of cardiac magnetic resonance imaging in the diagnosis of hypertrophic cardiomyopathy. *Circulation* 2005;112(6):855–61.

[9] Y.Daralammouri, M.El Garhy, K.Same and B.Lauer : Hypertrophic Cardiomyopathy Mimicking Acute Anterior Myocardial Infarction Associated with Sudden Cardiac Death-Case Reports in Medicine, 2012; 2012: 236154. Published online 2012 Aug 16.

[10] - F.Luzza, S.Carerj, G.Oreto - Hypertrophic cardiomyopathy with persistent ST segment elevation simulating acute

myocardial infarction- BMJ journals- Volume 90, Issue 4 ;
Online issue publication March 12, 2004.

[11] R.A.Nishimura and D.R.Holmes Jr., "Hypertrophic obstructive cardiomyopathy," *New England Journal of Medicine*, vol. 350, no. 13, pp. 1320–1327, 2004.

[12] M. A. Fifer and G. J. Vlahakes, "Management of symptoms in hypertrophic cardiomyopathy," *Circulation*, vol. 117, no. 3, pp. 429–439, 2008.

Abbreviations :

CMR cardiovascular magnetic resonance
HCM hypertrophic cardiomyopathy
LVOT left ventricular outflow tract

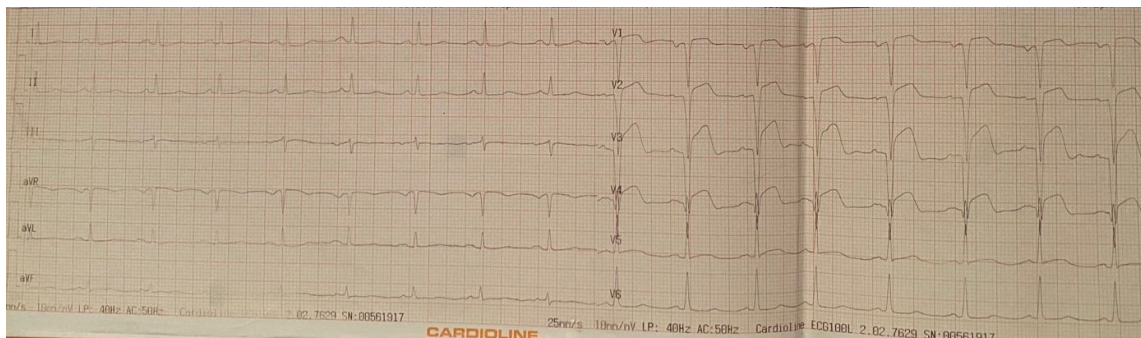


Figure 1: Standard 12-lead ECG shows sinus rhythm at 85 bpm, ST segment elevation in V1–V4.

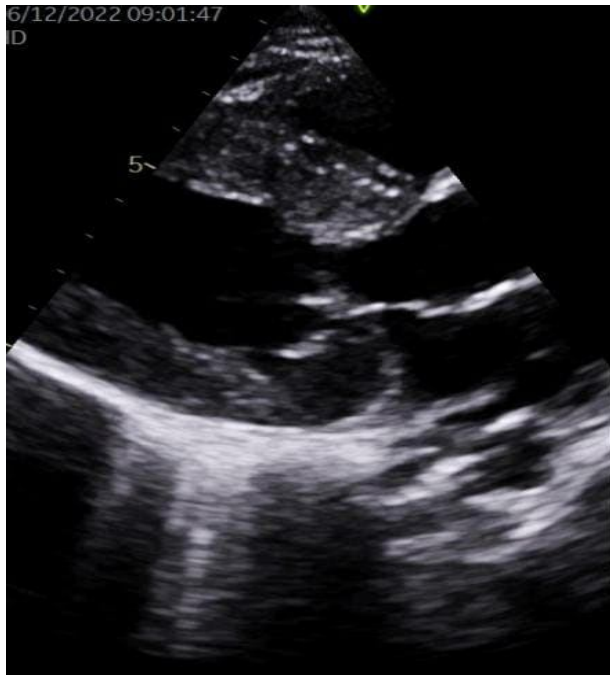

Figure 2: Parasternal long axis view revealed thickened left ventricular walls

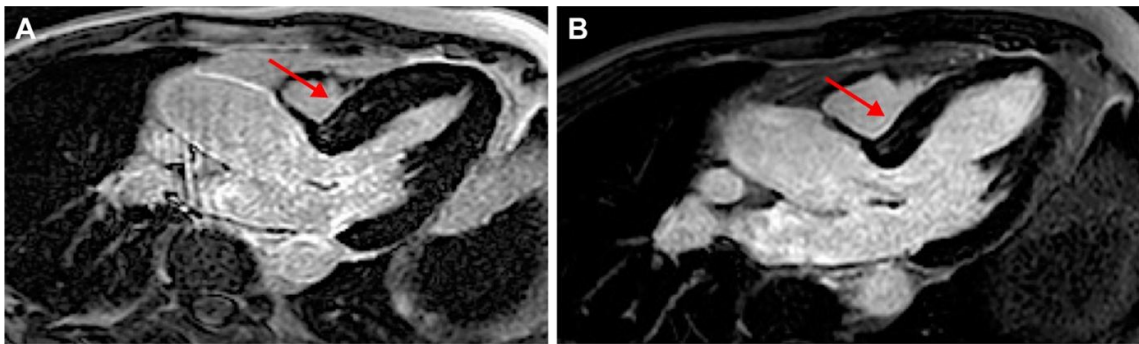


Figure 3: CMR 3-chamber view late Gadolinium enhancement images