

Original Research Article

METOPISM: ITS PREVALENCE & MORPHOMETRY IN ADULT NIGERIAN DRY SKULLS

Comment [SA1]: ITS

ABSTRACT

BACKGROUND: Metopic suture also known as the frontal, interfrontal, or median frontal suture is formed in the midline at the meeting of the two halves of the frontal bone. Normally it gets obliterated by early childhood, but in some cases it persists and is described as metopism. This study is aimed at investigating metopism prevalence in dry Nigerian skull. **METHOD:** This study was conducted on ninety-six (65 males and 31 females) adult Nigerian dry skulls from 5 selected Universities in the Southern part of Nigeria. Metopic suture (metopism) was considered to be complete when it continued uninterruptedly from the nasion to the bregma and incomplete when it was not present over its entire length. The incomplete metopic sutures were further classified into shapes. **RESULT:** Metopism was observed in 31 skulls (32.3%) of which 22 (21.9%) were males and 9 (9.4%) were females. Complete metopic suture was found in only 1 skull (1.04%) and incomplete metopic suture was seen in 30 skulls (31.25%). Among the incomplete ones, linear shape metopic suture was the most common in 16 skulls (16.67%). 7 (7.29%) were V-shaped metopic suture and another 7 (7.29%) were double-type metopic suture. Prevalence of metopic suture was slightly higher in males than in females. However, there was no statistical level of association with respect to sexual dimorphism. **CONCLUSION:** The prevalence and morphometry of metopism in the 96 adult Nigerian skull studied, revealed complete metopism to be 1.04% with a length of 127.0mm as against incomplete metopism of 31.25% making a total prevalence of 32.29%. The prevalence of metopic suture was slightly higher in males than in females with the linear metopic suture occurring the most. Sexual dimorphism with respect to incomplete metopism types and shapes revealed no association. This study is important for radiologists and neurosurgeons in diagnosis of frontal bone fractures and during surgical intervention including frontal craniotomy.

KEYWORDS: Prevalence, Metopism, Linear shape

INTRODUCTION

Metopic suture also known as the frontal, interfrontal, or median frontal suture is a vertical fibrous joint that divides the two halves of the frontal bone present in a newborn and a few

adults. It is a dentate-type suture extending from the nasion to the bregma, through the midline across the frontal bone and is often be incomplete [1, 2].The fusion of the metopic suture normally begins at the nasion proceeding superiorly and terminates at the anterior fontanelle [3]. The term metopic is from Greek meaning “in the middle of the face” [4].

The metopic suture separates the two frontal bones at birth and is the first skull suture to close physiologically, starting as early as at 3 months and generally being completely fused at the age of 8 months [5, 6]. It may fuse as early as 3 months of age and should fuse in nearly all patients by around 9 months of age [6-9]. Also, it usually close within the first or second year of life, but it has been reported to take up to seven years to fuse [10].Racial variations have been reported in the literature [11],as well as complications related to incomplete development of the frontal sinus. Its Premature fusion is termed metopic synostosis – a type of craniosynostosis which results in a growth restriction of the frontal bones, which leads to a skull malformation known as trigonocephaly. The metopic suture is usually obliterated by about 7or 8 years of age, however, ifit persists into adulthood it is known as “metopism”[2, 11].According to some authorities, this suture also disappears by the second or third year of life. It is thought to be a normal variant of the cranial sutures [12]. It is rare to find this suture in adults and its presence is not considered pathological, but in rare cases, it can persist [6] as an anatomical variant of little clinical significance that it can be mistaken for a frontal bone fracture. Persistence of the metopic suture may be associated with frontal sinus agenesis or hypoplasia [13].The suture is best identified in an A-P view of the skull. This view can help differentiate it from a vertical skull fracture[1]. Del Sol [14] suggested that metopism can be related to abnormal growth of the cranial bones, hydrocephalus, heredity, or atavism. The genetic factor is the one currently accepted by most scientists [15].

Comment [SA2]: individuals

Comment [SA3]: closes

Metopism is found in approximately 5% of Asians and 9% of European Caucasians and 1% of Blacks [12,16]. Bergman [12] reported the persistence of the metopic suture in approximately 1-12% of skulls. One author, Agarwal [17] reported the finding of 38.17% in Indian skulls, and Linc [18] observed it in 11% in Czech skulls, and finally Woo [19] reported the finding in 10% in Mongoloid skulls. The data may suggest that metopism is higher in temperate climates than in warmer climates [20].

Berry and Berry [21] reported a 0%-7% incidence associated with ethnicity. Metopism has been found by several investigators as being more prevalent in males than females [22,23].The persistence of the metopic suture has been reported in frequencies ranging from 1% to 12% of skulls [24]. Castillo reported a world index of incidence of 2.75%.It has also been reported to be perhaps associated with frontal sinus abnormalities but those studies seem flawed [4]. Some authors reported various suspected causes of metopism, including active expression of cytokines during cranial fusion and even resorption of the chondroidal tissue [11].The knowledge of the anatomy of the metopic suture is important because its permanence can be mistaken for a cranial fracture in radiological images, or even for the sagittal suture and it is also important for

Comment [SA4]: why?

paleodemography and forensic medicine [25]. Again, persistence of the suture and its relation to age and to race have excited comments over a long period of time. Hence, this study provides data-base information on the prevalence of metopism in Nigerian skulls

MATERIALS AND METHODS

Ninety-six (96) dry skulls were used for this study, selected from anatomy museums in 5 universities in the Southern part of Nigeria (University of Port-Harcourt, Choba, Rivers State, Niger Delta University, Amassoma, Bayelsa State, Imo State University, Owerri, Imo State, Abia State University, Okigwe, Abia State and Madonna University, Elele, Rivers State). The data being a primary data were obtained in accordance with the Anatomy Act, Chapter 17 of the Nigerian Constitution from anatomical museums in the Department of Human Anatomy of Universities listed. This allows any student attending a course of study in a school of anatomy licensed under this act to examine anatomically the body of any person deceased, if permitted or directed so to do by a person who had at the time of giving such permission or direction had power, in pursuance of the provisions of the act to permit or cause the body to be examined.

INCLUSION/EXCLUSION CRITERIA

These were put into consideration as selection criteria: teeth type (permanent) as a confirmation for adulthood and the complete state or undamaged state of the dry skull especially intactness of the frontal bone.

Only confirmed and intact adult Nigerian human dry skulls without visible deformities (especially frontal bone deformity) and skulls that show the permanent dentition were selected for the study. Dry skulls with visible deformities (especially frontal bone deformity) such as those that had cranial surgery, bony malformation and trauma were excluded from the study.

The skulls having met the selection criteria were washed with soap, water and soft brush and wiped with a clean dry cloth. The skulls which were already identified or labelled as male and female in the museum were then differentiated into male and female groups while the sexually unidentified were identified and differentiated into male and female based on the criteria of identification of sexual dimorphism. The criteria are as follows:

- Male skulls generally tend to have larger, thicker and heavier skulls
- Pronounced temporal ridge in males than in females.
- Sharper ridge in the lower section of the orbit in females than in males.
- Supraorbital ridge is prominent in males than in females [26].

Thereafter, the skulls were macroscopically inspected at the norma frontalis for the presence of the metopic suture. The inspected skulls were then divided into 3 groups based on sex [27]; skulls with complete metopic suture, skulls with incomplete metopic suture and skulls without metopic suture. Metopic suture is considered complete if it extends from the nasion to the bregma uninterrupted and incomplete if it extends from the nasion or bregma to varied points on the

frontal bone or in between [17, 28]. Based on the reports of some authorities [15, 16.28], the incomplete metopic sutures were further classified with respect to their shapes.

The complete metopic suture was also evaluated in terms of their continuation as the internasal suture anteriorly or the sagittal suture posteriorly. In addition, the length of the complete metopic suture was measured with the help of a thread spread straight from nasion to bregma [4] and later with a millimeter ruler.

The findings or data were then recorded, tabulated and analyzed.

Comment [SA5]: ruler

RESULTS

TABLE 1: DESCRIPTIVE STATISTICS OF TOTAL PREVALENC OF METOPIC SUTURE AND SHAPES OF INCOMPLETE METOPIC SUTURE

METOPIC SUTURE	FREQUENCY (n)	PERCENT (%)
Complete	1	1.04
Incomplete:		
Linear	16	16.67
V-shaped	7	7.29
Double-type	7	7.29
No metopic suture	65	67.71
TOTAL	96	100.0

TABLE 2: % PREVALENCE OF METOPISM

TYPES OF METOPIC SUTURE	MALE	FEMALE	TOTAL
	n (%)	n (%)	n (%)
Complete	1 (1.0%)	0 (0.0%)	1 (1.0%)
Incomplete	21 (21.9%)	9 (9.4%)	30 (31.3%)
None	43 (44.8%)	22 (22.9%)	65 (67.7%)
TOTAL	65 (67.7%)	31(32.3%)	96 (100%)

Comment [SA6]: according to sex

TABLE 3 PREVALENCE OF SHAPE OF INCOMPLETE METOPIC SUTURE

SHAPES	MALE	FEMALE	TOTAL
	n (%)	n (%)	n (%)
Linear	12 (40.0%)	4 (13.33%)	16 (53.33%)
V-shaped	5 (16.67%)	2 (6.67%)	7 (23.34%)
Double	4 (13.33%)	3 (10.0%)	7 (23.33%)
TOTAL	21(70.0%)	9 (30.0%)	30 (100.0%)

Comment [SA7]: according to sex

TABLE 4: SEXUAL DIMORPHISM IN TYPESOF METOPIC SUTURE

TYPES OF METOPIC SUTURE	MALE	FEMALE	TOTAL
	n (%)	n (%)	n (%)
Complete	1 (1.0%)	0 (0.0%)	1 (1.0%)
Incomplete	21 (21.9%)	9 (9.4%)	30 (31.3%)
None	43 (44.8%)	22 (22.9%)	65 (67.7%)
TOTAL	65 (67.7%)	31(32.3%)	96 (100%)

Values are presented as frequencies and percentages. Chi-square (X^2) = 0.423; P=0.516. P: statistical level of association was determined using Chi-square test. P<0.05 means there is an association (or relationship) between variables. From the above it can be seen that P>0.05, therefore there is no association or relationship between the type of metopic suture and sex.

TABLE 5: SEXUAL DIMORPHISM IN SHAPES OF INCOMPLETE METOPIC SUTURE

SHAPES	MALE n (%)	FEMALE n (%)	TOTAL n (%)
Linear	12 (40.0%)	4 (13.33%)	16 (53.33%)
V-shaped	5 (16.67%)	2 (6.67%)	7 (23.34%)
Double	4 (13.33%)	3 (10.0%)	7 (23.33%)
TOTAL	21(70.0%)	9 (30.0%)	30 (100.0%)

Values are presented as frequencies and percentages. Chi-square (X^2) = 0.748; P=0.688. P: statistical level of association was determined using Chi-square test. P<0.05 means there is an association (or relationship) between variables. From the above it can be seen that P>0.05, therefore there was no association or relationship between shape of incomplete metopic suture and sex.

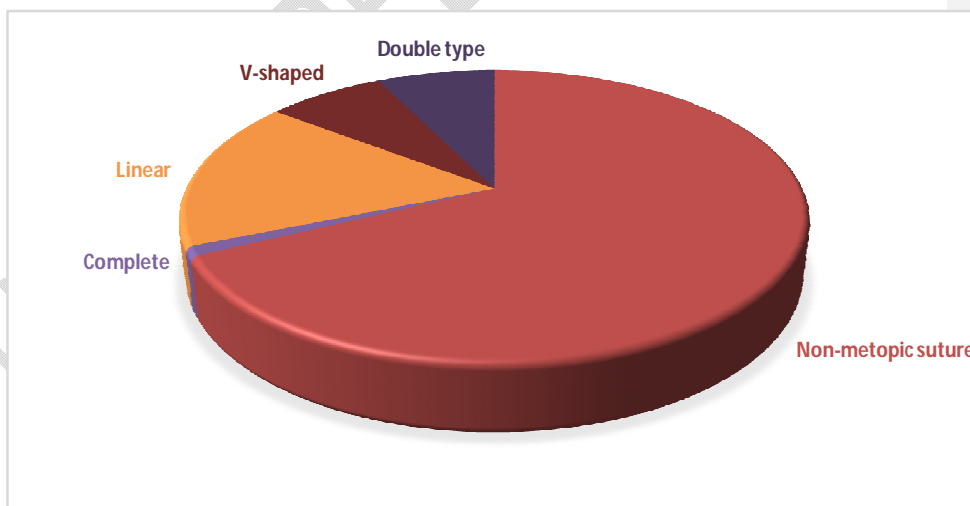


FIGURE 1: PIE CHART SHOWING PREVALENCE OF METOPIC SUTURE IN NIGERIAN SKULLS

TABLE 6: PREVALENCE OF METOPIISM AS REPORTED BY VARIOUS STUDIES

Researcher	Year of study	Skulls studied	No of skulls studied	Percentage of metopism
Bryce et al	1915	European		8.70%
		Scottish		9.50%
		Mongolian		5.10%
		Australian		1%
		Negro		1.2%
Keith et al	1948	Subject to race		3.80%
Inderjit and Shah	1948	Indian (Punjabis)		5%
Woo et al	1949	Mongoloids		10%
		Negroids		2%
Breathnach et al	1958	European		7 to 10%
		Yellow races		4 to 5%
		Africans		1%
Romanes et al	1972	Europeans		8%
Das et al	1973	Indian (U.P)		3.31%
Berry et al	1975	Various ethnic groups		7.4%
Agarwal et al	1979	Indians (Kanpur)	1,276	2.66%
Ajmaniet al	1989	Nigerians	206	3.4%
Bilodiet al	2003	Nepalese	51	3.92%
Baatenet al	2003	Lebanese		0.82%
Castilho et al	2006	Brazilian	71	7.04%
Yadav et al	2007	North Indian	1020	3.5%
Murlimanjuet al	2010	Indian	81	1.2%
Saheb et al	2010	South Indian	125	3.2%
Chandrasekaran et al	2011	South Indian	160	5%
Chakravarthiet al	2012	South Indian	80	6.25%
Masih et al	2013	Indian (Rajasthani)	200	6.5%
Chanwitet al	2013	Northeastern Thai		10.12%
Ivan do	2013	Brazilians	134	4.48%
Nascimentoet al				
Aksu et al	2013	Turkish West	106	7.50%
		Anatolian		
Saikia	2014	Indian (Assamese)	126	3.17%
Wadekaret al	2014	Indian	80	1.25%
Khamanaronget al	2015	Thai	706	2.83%
Present study	2021	Nigerian	96	1.04%

TABLE 7: PREVALENCE OF SHAPES OF INCOMPLETE METOPIC SUTURE AS REPORTED BY DIFFERENT AUTHORS

Researchers with year of study	Skulls studied	No of skulls studied	No of skulls with incomplete metopic suture	Shapes of incomplete metopic suture (%)						% Incidence of incomplete metopic suture	
				Linear	U-shaped	V-shaped	Double type	Inverted Ushaped	H-shaped		Y shaped
Inderjit and Shah, (1948)	Indians (Punjabis)							11.25	1.25	1.25	
Das <i>et al.</i> , (1973)	Indian (U.P)					1.01		1.93		0.28	17.57
Agarwal <i>et al.</i> , (1979)	Indian (Kanpur)	1,276	473	23.12		3.25		2.43	1.57	0.63	35.51
Ajmaniet <i>al.</i> , (1983)	Nigerian	206	65	24.27		0.49		0.97	3.88		31.57
Castilho <i>et al.</i> , (2006)	Brazilian	71	23	22.53	5.63		4.22				32.38
Chandra sekarane <i>t al.</i> , (2010)	South Indian	160	64	17	15	7.5					40
Murlimanjuet <i>al.</i> , (2011)	Indian	81	51	22.22	21%		19.7				62.9
Chakravarthiet <i>al.</i> , (2012)	South Indian	80	31	18.75	10	10					38.75
Masihet <i>al.</i> , (2013)	Indian (Rajasthan)	200	68	40	16	12					34

Aksuet <i>al.</i> , (2013)	Turkish West Anatolian	160	108	39.40	23.10		5				67.50
Saikia, (2014)	Indian (Assamese)	126	42	16.66	12.96	3.96					33.33
Wadekar <i>et al</i> (2014)	Indian	80	18	16.25	5			1.25			22.5
Present study (2021)	Nigerian	96	30	16.67	7.29		7.29				31.25

DISCUSSION

From the 96 dry skulls studied in this present research, metopic sutures were found to be present in 31 (32.3%) of the skulls; of this number, 22 were males (22.9%), 9 were females (9.4%). The metopic sutures in this study were classified into two types: complete and incomplete metopic sutures (Table 1). The complete metopic suture also referred to as metopism was found in only one skull (1.04%), a male skull which in turn showed continuity with the internasal suture anteriorly while posteriorly, the upper end of the metopic suture (median frontal suture) failed to meet the anterior end of the median sagittal suture with a deflection of 2mm. This agrees with Jones [30] who stated that the posterior end of the metopic suture does not meet the sagittal suture end-to-end and may miss it by an interval as great as 15mm. The length of the complete metopic suture in this study was 127.0mm which was below that of Yadav *et al.*, [29] whose mean suture length was computed to be 128.0mm in North Indian skulls, and below 129.2mm in Brazilian skulls, as reported by Castilho *et al.* [15]. However, it was above those reported by Das

et al., for Uttar Pradesh Indian skulls: 121.4mm [31], Skrzatet *al.*, for Polish skulls: 123.1mm [32] and Aksu *et al.*, for Turkish West Anatolian skull: 123.0cm [33].

In the present study, the incomplete metopic sutures were the most common and were found only in the lower part of the frontal bone (close to the nasion) known as nasion-incomplete metopic suture according to Khamanaronget *al.*, [34]. This is not so different from earlier studies where it was subdivided into bregma-incomplete metopic suture (BIMS) and nasion-incomplete metopic suture by Khamanaronget *al.*, and into upper, upper middle, lower middle and lower by Ajmaniet *al.*, [28]. The incomplete metopic suture were found in 30 (31.3%) skulls of which 21 skulls (21.9%) were males and 9 (9.4%) were females (table 2)..

Variations in shape of incomplete metopic sutures in the lower part of the frontal bone have been reported and described by several researchers. Ajmaniet *al.*, [28] reported the variations out of 206 Nigerian skulls as linear in 50 skulls (24.7%), H-shaped in 8 skulls (3.88%), V-shaped in 2 skulls (0.97%), inverted 'U-shaped' in 1 skull (0.49%) and wide side to side excursion shaped in 1 skull (0.49%).

Agarwal *et al.*, [17], described the shape variations out of 1,276 Indian skulls studied to be linear (23.12%), H-shaped (1.57%), V-shaped (3.25%), inverted 'U-shaped' (2.43%) and Y-shaped (1.96%). However, in this study out of the 96 skulls studied, the linear shape was observed in 16 skulls (53.34%), V-shaped in 7 skulls (23.34%) and double type in 7 skulls (23.33%) (table 3). This variations in shape is similar to the shapes observed by Murlimanjuet *al.*, of Indian skulls studied [22], Aksu *et al.*, of Turkish West Anatolian skulls studied [33] and Castilho *et al.*, of Brazilian skulls studied [15]. Variations like H-shaped, Y-shaped and inverted 'U-shaped' were not observed in this study. The linear shape was more common with equal prevalence in V-shaped and Double-type shape (table 3).

Metopic suture was absent in 65 of the skulls studied (67.7%), of which 43 were male skulls (44.8%) and 22 female skulls (22.9%). This is as a result of obliteration of the median frontal suture. Despite having been studied for decades there is no consensus about the correlation between cranial development and suture closure/obliteration. Calvarial suture obliteration is said to be associated with increased osteoblast proliferation and reduced suture cell apoptosis, which is induced by growth factors such as fibroblast growth factor 2 (Fgf2), bone morphogenic protein 4 (Bmp4) and transforming growth factor-beta 2 (Tgf- β 2) [35]. A study revealed that in vivo transforming growth factor-beta 3 (Tgf- β 3), delayed fusion of the posterior inter-frontal suture in Sprague-Dowley rats. Conversely, the cause of metopic suture in humans might stem from Tgf- β 3 [36]. The study also suggested that chondroid tissue is responsible for suture closure and maintenance of an open suture occurs by the process of active osteoclastic resorption. Levine *et al.*, from their animal models discussed the role of the dura mater-suture complex in determining metopic suture patency. It was indicated that some cytokines showed increased expression during active cranial suture fusion [37].

The prevalence of metopic suture is just slightly higher in males than in females especially when analyzed separately, because the metopic suture was found in 9 out of 31 female skulls (29.03%) and 22 out of 65 male skulls (33.85%) analyzed. Complete metopism was observed in only 1.54% (1 out of 65) and incomplete metopism 32.31% (21 out of 65) of male skulls. Metopic sutures in female skulls were all incomplete metopic sutures. With respect to shape, male skulls had higher prevalence of linear and V-shaped skulls except in the double type where females had a higher prevalence. However, there was no statistical level of association with respect to sexual dimorphism (tables 4 & 5)

Comparing the percentage prevalence of complete metopism among races, the prevalence in the present Nigerian study was 1.04% and this was slightly lower than Murlimanjuet *al.*, study [22] and Wadekaret *al.*, [38] who worked on 81 Indian skulls (1.2%) and 80 Indian skulls (1.25%) respectively. This agrees with Breathnach who reported metopism to be present in 1% of African skulls [39] and Bryce [40] who stated metopism to be present in 1.2% of Negroes. However, this is lower compared to other races, 7-10% in Europeans, 4-5% in yellow races [39] and 9.5% in Scottish skulls, 8.7% in European crania, 5.1% in Mongolian subjects, 1% in Australian skulls [40]. A summary of the prevalence of metopism, as reported by different research workers in different world population is represented in table 6.

The prevalence of complete metopism in Nigerian skulls in this present study of 1.04% is lower compared to the previous study in same Nigerian skulls by Ajmaniet *al.*, [28] whose prevalence was 3.40%. However, the incidence of incomplete metopism in this present study (31.25%) even if lower when compared to that of Ajmaniet *al.*, – 31.57%, both prevalence almost fall within the same range. This shows that incidence of incomplete metopic suture from both studies is similar. The difference in prevalence of metopism may be as a result of differences in height of people in Northern and Southern part of Nigeria, as Bryce stated that metopism is more frequent in the taller individuals [40]. This may also be as a result of time interval both researches were carried out, that is, 1983 and 2021 which is more than 30 years difference. Ajmaniet *al.*, from their study observed metopic sutures in the upper, upper-middle and lower-middle parts of the frontal bone and also observed the H-shaped and inverted 'U-shaped' incomplete metopic sutures. However, from this present study there was no metopic suture in those positions and with those shapes.

CONCLUSION

The prevalence and morphometry of metopism in the 96 adult Nigerian skull studied, complete metopism was 1.04% with a length of 127.0mm as against incomplete metopism of 31.25% making a total prevalence of 32.29%. The prevalence of metopic suture was slightly higher in males (33.85%) than in females (29.03%) and the linear, V-shaped and Double-type shapes of incomplete metopic sutures were observed of which the linear-shape metopic suture occurred the most. Sexual dimorphism with respect to incomplete metopism types and shapes revealed no association

REFERENCES

1. Gardner S. A Persistent Metopic Suture: A Case Report. *Austin J Anat.* 2016; 3(1): 1049. ISSN : 2381-8921
2. Bilgin S, Kantarcı UH, Duymus M, Yildirim CH, Ercakmak B, Orman G, et al. Association between frontal sinus development and persistent metopic suture. *Folia Morphol (Warsz).* 2013; 72: 306-310.
3. Chaoui R, Levailant JM, Benoit B, Faro C, Wegrzyn P, Nicolaidis KH. "Three-dimensional sonographic description of the fetal frontal bones and metopic suture". *Ultrasound in obstetrics & gynecology.* 2005; 26: 618-621.
4. Guerram A, Le Minor JM, Renger S, Bierry G. "Brief communication: The size of the human frontal sinuses in adults presenting complete persistence of the metopic suture". *American Journal Of Physical Anthropology.* 2014; 154: 621-627.
5. Vu HL, Panchal J, Parker EE, Levine NS, Francel P. The timing of physiologic closure of the metopic suture: a review of 159 patients using reconstructed 3D CT scans of the craniofacial region. *J Craniofac Surg.* 2001;12:527-532. doi: 10.1097/00001665-200111000-00005. [PubMed] [CrossRef] [Google Scholar]
6. Weinzwieg J, Kirschner RE, Farley A, Reiss P, Hunter J, Whitaker LA, Bartlett SP. Metopic synostosis: defining the temporal sequence of normal suture fusion and differentiating it from synostosis on the basis of computed tomography images. *Plast Reconstr Surg.*

2003;112:1211–1218. doi: 10.1097/01.PRS.0000066008.40176.EF. [PubMed] [CrossRef] [Google Scholar]

7. Vu HL, Panchal J, Parker EE et-al. The timing of physiologic closure of the metopic suture: a review of 159 patients using reconstructed 3D CT scans of the craniofacial region. *J Craniofac Surg*. 2001;12 (6): 527-32. *J Craniofac Surg* (link) - Pubmed citation
8. Murlimanju BV, Prabhu LV, Pai MM et-al. Median frontal sutures - incidence, morphology and their surgical, radiological importance. *Turk Neurosurg*. 2011;21 (4): 489-93. doi:10.5137/1019-5149.JTN.4293-11.0 - Pubmed citation
9. Glass RB, Fernbach SK, Norton KI et-al. The infant skull: a vault of information. *Radiographics*. 2004;24 (2): 507-22. *Radiographics* (full text) - doi:10.1148/rg.242035105 - Pubmed citation
10. Baaten PJ, Haddad M, Abi-Nader K, Abi-Ghosn A, Al-Kutoubi A, Jurjus AR. Incidence of metopism in the Lebanese population. *Clin Anat*. 2003; 16: 148-151.
11. Vikram S, Padubidri JR, Dutt AR. "A rare case of persistent metopic suture in an elderly individual: Incidental autopsy finding with clinical implications". *Archives of Medicine and Health Sciences*. 2016; 2: 61.
12. Bergman RA, Afifi AK, Miyauchi Ret. "Compendium of human anatomical variation: text, atlas and world literature". Baltimore, Urban and Schwarzenberg. 1988; 41: 282-288
13. Çakur B, Sumbullu MA, Durna NB. Aplasia and agenesis of the frontal sinus in Turkish individuals: a retrospective study using dental volumetric tomography. *Int J Med Sci*. 2011;8 (3): 278-82. Free text at pubmed - Pubmed citation
14. Falk D, Zollikofer CPE, Morimoto N, de León MSP. "Metopic suture of Taung (*Australopithecus africanus*) and its implications for hominin brain evolution". *Proceedings of the National Academy of Sciences*. 2012; 109: 8467-8470.
15. Castillo SMA, Oda YJ, Santana GDM. "Metopism in Adult Skulls from Southern Brazil". *International Journal of Morphology*. 2006; 24: 61-66.
16. Verma P. *International Journal of Anatomical Variations*. 2014; 7: 7-9.
17. Agarwal SK, Malhotra VK, Tewari SP. Incidence of the metopic suture in adult Indian crania. *Acta Anat (Basel)*. 1979; 105: 469-474.
18. Linc R, Fleischman J. Incidence of Metopism in the Czech Population and its causes *C.R. Ass. Anat. Comptesrendus Del' Association des Anatomistes'*. 1969; 142: 1192-1202.

19. Woo JK. Ossification and growth of the human maxilla, premaxilla and palate bone. *Anat Rec.* 1949; 105: 737-761.
20. Anjoo Yadav, Vinod Kumar, Srivastava RK. "Study of Metopic Suture in the Adult Human Skulls of North India". *Journal of the Anatomical Society of India.* 2010; 59: 144-244.
21. Carolineberry A, Berry RJ. Epigenetic variation in the human cranium. *J Anat.* 1967; 101: 361-379.
22. Murlimanju BV, Prabhu LV, Pai MM, Goveas AA, Dhananjaya KV, Somesh MS. "Median frontal sutures-incidence, morphology and their surgical, radiological importance," *Turkish Neurosurgery.* 2011; 21: 489-493.
23. Baaten PJ, Haddad M, Abi-Nader K, Abi-Ghosn A, Al-Kutoubi A, Jurjus AR. Incidence of metopism in the Lebanese population. *Clin Anat.* 2003; 16: 148-151.
24. Hussain SS, Mavishetter GF, Thomas ST and Prasanna LC (2010). Incidence of metopic suture in adult South Indian skulls. *J Biomed Sci and Res.* 2 (4): 223-226.
25. Hauser G, Mnazi G, Vienna A and De Stefana GF (1991). Size and Shape of human cranial sutures – a new scoring method. *Am J. Anat.* 190: 231-244.
26. Manzanares MC, Goret-nicaise M and Dhen A (1988). Metopic sutural closure in the human skull. *J Anat.* 161:203-25.
27. Ivan do Nascimento S, Fernandes KLM, Ramalho AJC, Bispo RFM, Rodrigues CFS and AragaoJA (2013). Occurrence of Metopism in dry crania of adult Brazilians. Accessed 19th January 2017 at 14:05pm. <http://dx.doi.org/10.5402/2013/158341>
28. Ajmani ML, Mittal RK, and Jain SP (1983). Incidence of metopic suture in adult Nigerianskulls. *J. Anat.* 137 (1): 177-83.
29. Yadav A, Kumar Vand Srivastava RK (2010). A study of metopic suture in the adult human skulls of North India. *J. Anat. Soc. India.* 59(2):232-236.
30. Jones FW (1946). *Buchanan's Manual of Anatomy.* 7th ed. London:Balliere, Tindall& Cox. pp 226-229.
31. Das AC, Saxena RC and Beg MA (1973). Incidence of metopic suture in UP subjects. *J of Anat. Soc. of India.* 22:241.
32. SkrzatJ, WalochaJ, Zawilwiski J (2004). A note on the morphology of the metopic suture in the human skull. *Folia. Morphol. (Warsz).* 63 (4): 481-4.
33. Aksu F, Cirpan S, Mas NG, Karabekir, S and Magden AO (2014). Anatomic features of metopic suture in adult dry skulls. *J. Craniofac. Surg.* 25 (3): 1044-1046.

34. Khamanarong K, Tuamsuk P, Woraputtapom W, Namking MS, Sawatpanich T, Toomsani Y and Iamsaard S (2015). Incidence of metopism in adult Thai skulls. *Int. J. Morphol.* 33 (1): 51-54.
35. Opperman LA, Adab K and Gakunga PT (2000). Transforming growth factor-beta2 and TGF-beta3 regulate fetal rat cranial suture morphogenesis by regulating rates of cell proliferation and apoptosis. *DevDyn.* 219: 237-247.
36. Manzanares MC, Goret-nicaise M and Dhen A (1988). Metopic sutural closure in the human skull. *J Anat.* 161:203-25.
37. Levine J, Bradley J, Roth D, McCarthy J and Longaker M (1998). Studies in cranial suture biology. Regional duramater determines overlying suture biology. *PlastReconstr Surg.* 101: 1441-1447.
38. Wadekar PR, Pundge SJ, Fulpatil MP and Pandat SV (2014). Study of incidence of metopic suture in adult skulls. *Indian Journal of Basic and Applied Medical Research.* 4 (1):277-283.
39. Breathnach AS (1958). Frazer's Anatomy of the human skeleton, 5th ed. London, Churchill Livingstone. pp 177-185.
40. Bryce TH (1915). Osteology and anthropology in Quain elements of anatomy. 11th edition Vol 4, London: pp 177.