

# Eisenmenger Syndrome with Dextrocardia, Ectopic Left Kidney and Right sided Infantile Scoliosis: A Rare Case Report

---

## ABSTRACT

Eisenmenger syndrome is defined as any untreated congenital cardiac defect with intracardiac communication resulting in pulmonary hypertension, flow reversal, and cyanosis. The previous left-to-right shunt is converted into a right-to-left shunt secondary to elevated pulmonary artery pressures and associated pulmonary vascular disease. Young male presented progressive dyspnoea, chest pain and anasarca and having cyanosis, dextrocardia, right scoliosis and ectopic kidney. A favourable prognosis for ES is achieved with early diagnosis and surgical intervention, whereas a poor prognosis is achieved with a late diagnosis and the onset of heart failure and pulmonary hypertension. Most patients die from heart failure, cardiac arrhythmia, and thromboembolic cerebrovascular disease. Patients with ventricular septal defects may benefit from taking medications like sildenafil and furosemide to improve their prognosis and quality of life. The longevity of these patients with functional limitations is still grim, despite therapy advancements. Further therapeutic interventions need to be made to reduce the symptoms.

*Keywords: Cyanosis; dextrocardia; eisenmenger; heterotaxy; hypoxemia.*

## 1. INTRODUCTION

A rare birth disorder, heterotaxy syndrome, also called Isomerism, with a global incidence of 1 in 10,000, is associated with at least 3% of congenital cardiac abnormalities [1]. Visceral malposition and dismorphism are two signs of heterotaxy syndrome (within both the thorax and abdomen). Heterotaxy syndrome is defined by severe cardiovascular malformations. The majority of individuals with the heterotopia syndrome die naturally from difficulties as children. Visceral malposition and dismorphism are also characteristics of heterotaxy syndrome (within both the thorax and abdomen). Complex cardiovascular abnormalities are a feature of heterotaxy syndrome. Heart failure, abrupt cardiac death, and intrapulmonary bleeding are among the sequelae of extensive congenital heart abnormalities that most people with the heterotaxy syndrome experience before they reach adulthood [2].

Eisenmenger Syndrome (ES) is not a congenital heart disease. It is an entirely preventable, multisystem disorder that arises as a complication of congenital heart disease. It is the most severe type of congenital shunt-related

pulmonary arterial hypertension (PAH), which is characterised by the triad of a large intra- or extra-cardiac congenital defect with an initial systemic to pulmonary shunt; PAH with shunt reversal (from right to left) or bidirectional shunting, which eventually leads to hypoxemia and cyanosis [3,4].

Scoliosis is defined as the curvature of the spine in the coronal plane. The spinal column rotates to varying degrees in conjunction with it. Conventionally, scoliosis is defined as having a Cobb's angle greater than 10 degrees [5]. The direction (left or right) of a scoliotic curve is defined by the curve's convexity. The objective of this article is to describe, for the first time, an adult patient who had heterotaxy syndrome with dextrocardia, complicated by Eisenmenger syndrome with a large ventricular septal defect (VSD) and right-sided infantile scoliosis.

## 2. CASE REPORT

A 20 year young adult male presented with progressive dyspnoea on exertion which later progressed to PND followed by orthopnea over a period of 2 months which was progressive it was associated dull aching, retrosternal chest pain

---

with chest tightness, aggravated after strenuous work lasting for 5-15 minutes.

The patient had generalised swelling of body for past 2 months which progressed gradually starting from peri-orbital swelling later causing fullness of abdomen and abdominal tightness with bilateral lower limbs swelling upto ankle region.

On examination, the patient was poorly built and malnourished with BMI-14.67 kg/m<sup>2</sup> cyanosis of tongue, lips and all the digits and grade 2 clubbing. His pulse was 104/minute, regular but low volume and blood pressure was 84/62 mmHg. His respiratory rate was 26/ minute with oxygen saturation of 76% on room air. JVP was elevated. His cardiovascular examination revealed that he had Right sided bulging asymmetric chest wall with apical impulse present in Right 6th intercostal space in mid-axillary line, 11 cms away from sternal border. Parasternal heave was present. On auscultation Loud S2 was heard in pulmonary area with no murmurs appreciated. His lungs had bilateral fine basal crepitations. His abdominal examination revealed hepatomegaly with tenderness hypochondriac and epigastric region. Back showed drooping of shoulder of right side with scoliosis. Routine investigation showed erythrocytosis with hemoglobin 18.9 g/dl (12-15 g/dl), packed cell volume was 57.5%, platelets 1,50,000 cells/cu.mm, Mean Corpuscular Volume (MCV) 88.8 fl , Mean.

Corpuscular Hemoglobin (MCH) 29.2 pg/cell, creatinine was 1.2 mg/dl and urea 91 mg/dl, Bleeding time 1 minute 10 seconds and activated clotting time 3 minutes 25 seconds. Uric Acid 13.8 mg/dl. Peripheral smear examination showed Normocytic Normochromic blood picture with Reticulocyte count of 3%. ECG revealed signs of both Left Ventricular Hypertrophy (LVH) and Right Ventricular Hypertrophy (RVH), Large Biphasic QRS complexes in V2V5, with LV strain pattern in V6, Right Atrial Enlargement .

Echocardiography report showed SitusSolitus and Dextrocardia, with Criss-cross AV connection and L-looping of ventricle. Large upper muscular Ventricular Septal Defect extending upto sub-aortic region with Severe Pulmonary Arterial Hypertension and Bi-ventricular dysfunction with LVEF 20-25% and Dilated IVC. USG Abdomen showed Rt kidney appears malrotated 9.8x4.4cm the hila is seen to be facing supero-medially with unremarkable

hila/focal lesion or collection, left kidney is not visualized in left renal fossa?absent?ectopic however it's location /position in abdomen can't be ruled out due to excessive bowel gas.

Further evaluation with CT KUB is recommended. CT-KUB (Image 3) revealed left kidney was small in size measuring 6.5x 4.5cm visualised in left pelvic cavity suggestive of ectopic left kidney. HRCT- thorax report showed that Dextrocardia, Cardiomegaly, Prominent mean pulmonary artery measuring 30mm and Ground Glass Opacities with peribronchial and interlobular septal thickening noted in right middle and lower and left lower lobes along with Scoliotic deformity.

With evidence obtained from above investigations, patient is known to have Dextrocardia (Image 1), Congenital heart disease- ES, Ventricular septal defect with PAH and ectopic left kidney in left pelvic cavity.

Patient in hospital for 10 days and during his stay he was given Inj Amoxicillin+ clavulanic acid (1.2gm) TDS for 5 days, Tab Digoxin (0.25) once daily, Tab furosemide (10) 1/2 tab once daily, Tab Ecosprin (75) once daily, Tab Folic Acid (5) once daily, Tab Febuxostat (40) once daily, Tab Calcium and Tab Vitamin D3 Patient had undergone phlebotomy 4 times after which improvement of cyanosis as well as well as orthopnea and PND and significant fall in hemoglobin levels from 18.9 g/dl to 15.6 g/dl.

### 3. DISCUSSION

A complicated variation in clinical manifestations known as heterotaxy syndrome might result from mechanical malrotation during lateralization as well as from gene mutations. Clinically, there are two types: Right atrial isomerism and left atrial isomerism. Our case is unique as patient presented with dextrocardia with large VSD which complicated to ES, left ectopic small sized kidney and right sided scoliosis. Variable complications are brought on by heterotaxy syndrome across multiple organ systems. Dysrhythmia, heart failure, thromboembolism, and infectious endocarditis are the main cardiac complications. Extra-cardiac complications include plastic bronchitis, liver dysfunction/ cirrhosis/ hepatocellular carcinoma, renal dysfunction, diabetic mellitus, mental illness, and female infertility [6].

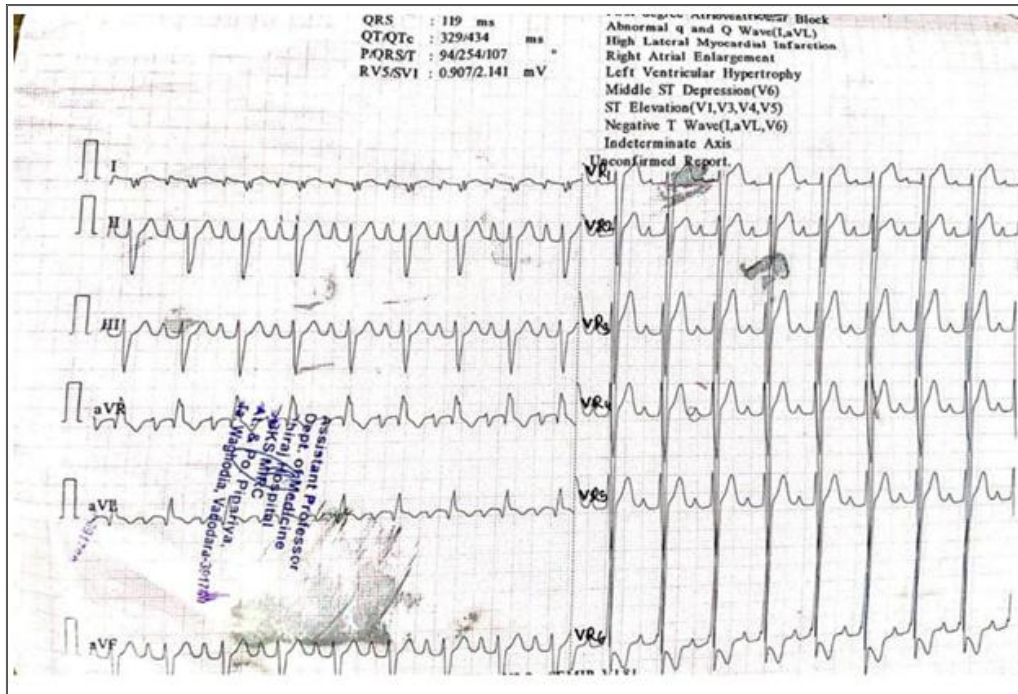


Image 1. ECG suggestive of LVH, RVH, large biphasic QRS complexes, LV strain pattern

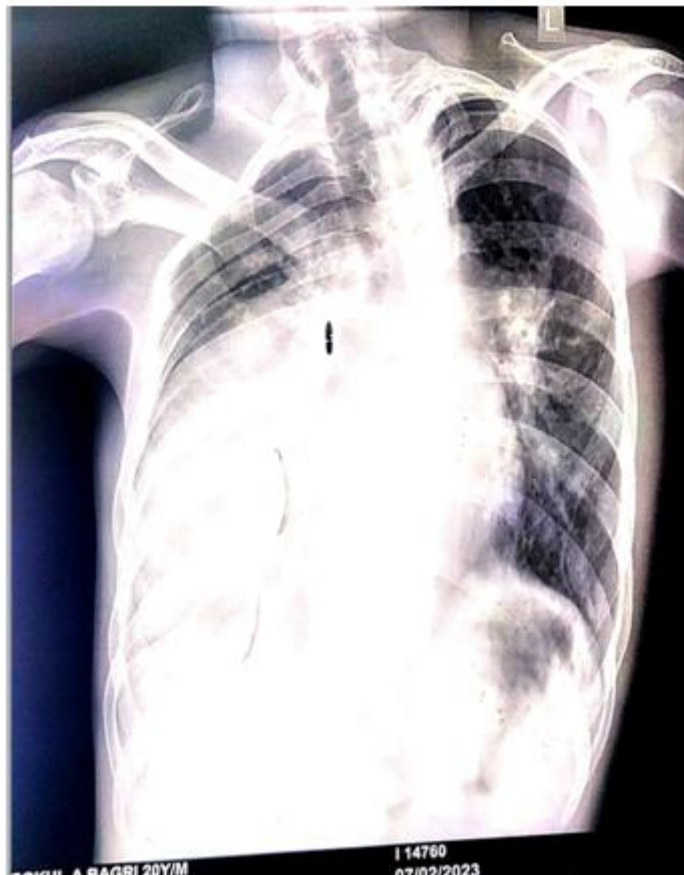


Image 2. Chest Xray (PA view) showing dextrocardia and right sided scoliosis

The Eisenmenger Syndrome (ES) is a complex multisystem disease that develops as a result of a significant right-to-left shunt that has a negative

influence on the pulmonary vasculature and causes supra-systemic pulmonary artery pressure [7]. Shunt direction reverses when PVR

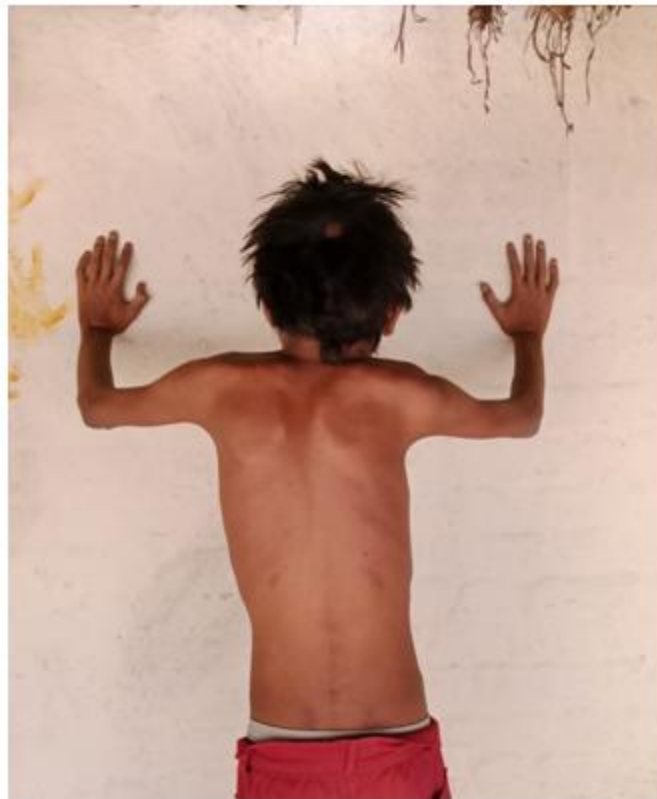exceeds SVR, which causes cyanosis. Eisenmenger syndrome most frequently manifests in infants and young children who have extensive, un-repaired post-tricuspid shunts, such as AVSDs, VSDs, or PDA. If left untreated, Eisenmenger syndrome is frequently observed in patients with truncus arteriosus but can also occur in people with complex intra-cardiac architecture. Several genetic or environmental factors may play a role in Eisenmengersyndrome, which is more prevalent in women. Eisenmenger syndrome is uncommon in high-income countries due to advancements in CHD diagnosis and care, but it is nonetheless common in areas with limited access to congenital heart surgery. Persistent cyanosis causes secondary erythrocytosis, which results in an iron depletion and hyperviscosity [8].

Individuals with ES typically live through their third or fourth decade of life, but their life expectancy is shortened by symptoms like

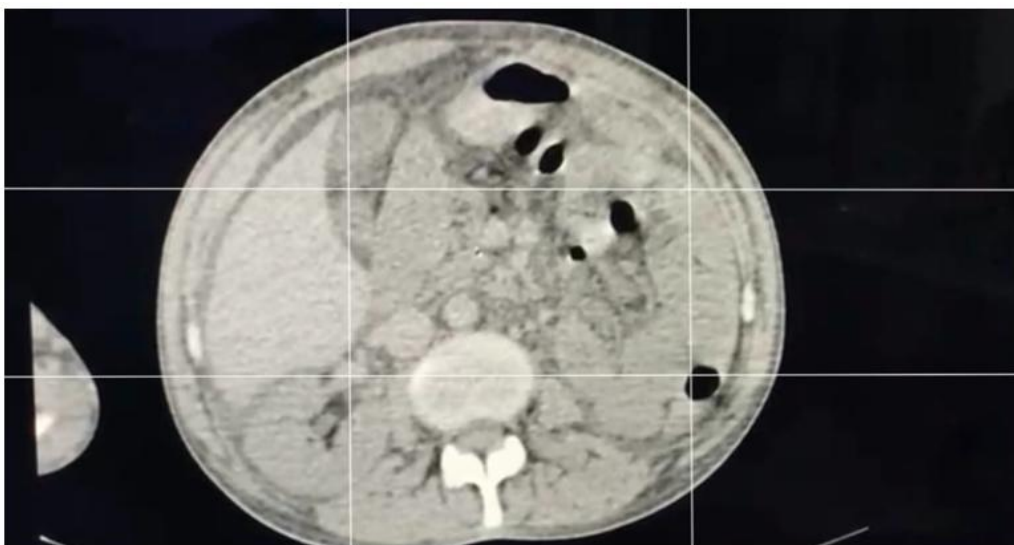
dyspnea, cyanosis, clubbing, lethargy, dizziness, and syncope.

In addition, cardiac arrhythmias, a prominent delayed complication of ES, are a frequent reason for unexpected mortality in ES patients. Both in men and women, ES does not appear to have a variable prevalence [9].

However, cardiac catheterization, an invasive procedure to measure the pressure in the heart and lungs, may be necessary to make the diagnosis of ES. In addition, a chest X-ray, an electrocardiogram (ECG), a pulmonary function test, an iron level check, and a complete blood count were performed (CBC). Using echocardiography, the cardiac abnormality is primarily identified, and the possibility of increased lung pressure is also raised. Imaging techniques, such as magnetic resonance imaging (MRI) of the heart, can provide useful anatomical data [10].



**Image 3. Back showing right sided scoliosis**



**Image 4. CT-KUB suggestive of Right kidney in normal shape and position while left kidney appearing small in size and in left pelvic cavity suggestive of ectopic left kidney**

In order to treat the hyperviscosity syndrome associated with increased red blood cell production, phlebotomy with isovolumic replacement is used; however, only patients who exhibit particular hyperviscosity symptoms should undergo this procedure [11].

Cardiac glycosides, diuretics, anti-arrhythmic medicines, and/or anticoagulants were frequently used in the pharmacological care; however, these strategies barely had a significant impact on survival or the risk of disability. Cardiopulmonary transplantation, which is impracticable in most contexts, can treat ES. Eisenmenger Syndrome has historically been treated with warfarin to prevent clotting. In older patients, surgical correction of the underlying heart defect is primarily unsuitable [12]. When sildenafil and furosemide are administered together, cGMP elevation-mediated cochlear toxicity may result in hearing loss with sensorineural origin. The reason that the index patient experienced hearing improvement after stopping sildenafil is indicative that this hearing loss is reversible. Hence, if at all co-administration of ototoxic drugs such loop diuretics/CYP3A4 inhibitors, and PDE5 inhibitors is required, careful prudence and monitoring are indicated.

Individuals with advanced symptoms of ES who are resistant to medical treatment may be eligible for lung or heart transplantation along with correction of the cardiac defect. In terms of outcomes, ES is comparable to other cases where combined heart-lung transplantation is being used. 63 patients who underwent heart-

lung or lung transplantation for ES were identified in a recent international survey. Early mortality was 11%, and 15 years after transplantation, survival was 41% [13].

The severity of the underlying cardiac anomalies significantly affects the heterodoxy syndrome prognosis. Although these patients are undergoing reducing surgical and medical treatment, whose long-term outlook is still not favourable [6]. Eisenmenger patients have a variable prognosis, but it is better when compared to individuals with much more severe forms of PAH. Mortality in childhood is unusual, but it becomes significantly more prevalent in the fourth or later decades of life [14].

#### **4. CONCLUSION**

A favourable prognosis for ES is achieved with early diagnosis and surgical intervention, whereas a poor prognosis is achieved with a late diagnosis and the onset of heart failure and pulmonary hypertension. Most patients die from heart failure, cardiac arrhythmia, and thromboembolic cerebrovascular disease. Patients with ventricular septal defects may benefit from taking medications like sildenafil and furosemide to improve their prognosis and quality of life. The longevity of these patients with functional limitations is still grim, despite therapy advancements. Further therapeutic interventions need to be made in order to reduce the symptoms. This case illustrates Heterodoxy syndrome with Dextrocardia and ES with right sided scoliosis with Left ectopic kidney. This

case is very crucial among physicians for complex and multi organ involvement. Hence, through investigations and management is required for treating such complex case.

## CONSENT

As per international standard or university standard, parental(s) written consent has been collected and preserved by the author(s).

## ETHICAL APPROVAL

As per international standard or university standard written ethical approval has been collected and preserved by the author(s).

## COMPETING INTERESTS

Authors have declared that no competing interests exist.

## REFERENCES

1. Brueckner M. Heterotaxia, congenital heart disease and primary ciliary dyskinesia. *Circulation*. 2007;115(22):2793-2795.
2. Jo DS, Jung SS, Joo CU. A case of unusual visceral heterotaxy syndrome with isolated levocardia. *Korean Circ J*. 2013; 43(10):705-709.
3. Hopkins WE. The remarkable right ventricle of patients with Eisenmenger syndrome. *Coron Artery Dis*. 2005;16:19.
4. Hopkins WE, Waggoner AD. Severe pulmonary hypertension without right ventricular failure: The unique hearts of patients with Eisenmenger syndrome. *Am J Cardiol*. 2002;89:34.
5. Kane WJ. Scoliosis prevalence: a call for a statement of terms. *Clin Orthop Relat Res*. 1977;43.
6. Shiraishi I, Ichikawa H. Human heterotaxy syndrome - From molecular genetics to clinical features, management, and prognosis. *Circ J*. 2012;76(9):2066-2075.
7. Skeith L, Yamashita C, Mehta S, Farquhar D, Kim RB. Sildenafil and furosemide associated ototoxicity: Consideration of drug-drug interactions, synergy, and broader clinical relevance. *J Popul Ther Clin Pharmacol*. 2013;20(2):e128-31.
8. Arvanitaki A, Giannakoulas G, Baumgartner H, Lammers AE. Eisenmenger syndrome: diagnosis, prognosis and clinical management. *Heart*. 2020;106:1638–1645.
9. Galiè N, Beghetti M, Gatzoulis MA, Granton J, Berger RM, Lauer A, et al. Bosentan therapy in patients with Eisenmenger syndrome: A multicenter, double-blind, randomized, placebo-controlled study. *Circulation*. 2006;114(1): 48-54.
10. Young D, Mark H. Fate of the patient with the Eisenmenger syndrome. *Am J Cardiol*. 1971;28(6):658-69.
11. Gertz MA. Acute hyperviscosity: Syndromes and management. *Blood*. 2018;132(13):1379-85.
12. Beghetti M, Galiè N. Eisenmenger syndrome: A clinical perspective in a new therapeutic era of pulmonary arterial hypertension. *J Am Coll Cardiol*. 2009;53 (9):733-40.
13. Hjortshoj CS, Gilljam T, Dellgren G, et al. Outcome after heart-lung or lung transplantation in patients with Eisenmenger syndrome. *Heart*. 2020;106: 127–132.
14. Kempny A, Hjortshoj CS, Gu H, et al. Predictors of death in contemporary adult patients with Eisenmenger syndrome: A multicenter study. *Circulation*. 2017;135: 1432–1440.