

# Case report

## A rare case of Congenital Hypothyroidism

### ABSTRACT

Congenital Hypothyroidism(CH) is a common preventable cause of mental retardation. The incidence of CH is 1 in 2500 to 1 in 3000 newborns. Most common causes are thyroid dysgenesis and dyshormonogenesis. Some disorder like maternal autoantibodies, maternal intake of anti thyroid medication, iodine deficiency or iodine excess can result in transient CH. Common symptoms include decreased activity and increased sleep, feeding difficulty, constipation, and prolonged jaundice. In this case report, A 3 day old baby was admitted to SNCU with chief complain of yellowish discoloration upto abdomen and respiratory distress. On examination, common signs include myxedematous facies, large fontanels, macroglossia, a distended abdomen with umbilical hernia, and hypotonia. Thyroid dysgenesis accounts for 85% of permanent, primary CH, while inborn errors of thyroid hormone biosynthesis (dyshormonogeneses) account for 10-15% of cases. Secondary or central CH may occur with isolated TSH deficiency, but more commonly it is associated with congenital hypopituitarism. Transient CH most commonly occurs in preterm infants born.

Key words: Congenital Hypothyroidism, mental retardation, Thyroid dyshormonogenesis, anti thyroid medication

### Introduction

"Congenital Hypothyroidism(CH) is a common preventable cause of mental retardation. Some disorders, such as maternal autoantibodies, maternal antithyroid medication use, iodine deficiency or excess, can result in transient CH. Common symptoms include lowered activity and increased sleep, feeding difficulties, constipation, and prolonged jaundice"[1,5]. "In the majority of patients, CH is caused by an abnormal development of the thyroid gland (thyroid dysgenesis) that is a sporadic disorder and accounts for 85% of cases and the remaining 15% of cases are caused by dyshormonogenesis"[6]. "After making diagnosis if the treatment is started within in a few weeks of birth, neurodevelopmental outcome is generally normal".[7] "The clinical features of CH are often subtle and many newborn infants remain undiagnosed at birth".[8] "This is due in part to passage of maternal thyroid hormone across the placenta providing a protective effect, especially to the fetal

brain and masking the clinical signs".[9] This report presents a rare case of Congenital Hypothyroidism.

## CASE PRESENTATION

A 3 day old baby was admitted to SNCU with chief complain of yellowish discoloration upto abdomen and respiratory distress. The baby was born to 2nd Gravida with history of one abortion at 2 month which was spontaneous and the mother was on antithyroid medication for last 6 month before the delivery. The baby was born at 38 weeks 2days with birth weight 1.75kgs with birth history uneventful. Baby was fed within one hour of life and passed stool within 24hrs and urine within 48hrs.

General physical examination revealed a well alert and active baby with tachypnea and mild retraction and icteric upto abdomen with facial dysmorphism , Quebec score-4.

On Examination there was open posterior fontanelle with facial dysmorphism ( upslanting palpebral fissure, depressed nasal bridge, low set ears, no skeletal deformity, no umbilical hernia. Assymetrical IUGR ( ponderal index - 1.9). Respiratory examination shows tachypnea with mild intercoastal retraction and mild subcoastal retraction.

So the baby was put on oxygen support and single surface phototherapy for 2days for neonatal jaundice

And on 6th day of admission there was an episode of regurgitation of the feed and feed intolerance was seen so drop domperidone and drop ranitidine was given followed by burping after half feed and there were no sign of constipation.

Investigation shows normal blood picture , sepsis profile positive, USG neck shows both thyroid lobes were normal, TORCH- rubella IgG- 104 IU/ml and CMV-93 IU/ml , blood culture and sensitivity shows MRCONS, CSF analysis was in normal limits, Urine culture and sensitivity was positive for enterococcus , Mother anti TPO antibody - 0.84IU/ml which was in normal limit,

Serum TSH- 10.6, freeT4-1 ng/dl , free T3- 2.2 pg/dl

Dried blood spot test revealed urea cycle defect to be presumptive positive with abnormal amino acid metabolism and decrease in citrulline levels

In view of TSH- 10.6. Tab Levothyroxine was started and The patient was discharged after a hospital stay of 17 days on the attendant's persistent request on Tab Levothyroxine.

A provisional diagnosis of Term/VD/ Assymetrical IUGR/Neonatal Jaundice/ Late onset neonatal sepsis/ Dysmorphic facies/ Urosepsis / Congenital Hypothyroidism/ Quebec score- 4

## DISCUSSION

Congenital Hypothyroidism with citrullinemia is one of urea cycle defects and is caused by argininosuccinic acid synthetase deficiency which includes a failure to synthesize urea, resulting in the accumulation of ammonium, glutamine, and citrulline[2]. The neonatal form presents the most severe onset and a fatal course with vomiting, failure to feeding, irritability, apnea, convulsion, lethargy, stupor and coma with respiratory arrest. Although citrullinemia is reported as a rare urea

cycle[3,4]. Our patient with open posterior fontanelle, feed intolerance, with facial dysmorphism met the necessary criteria of congenital hypothyroidism.

Above all congenital hypothyroidism with facial dysmorphism and urea cycle defect is rarely reported in India. Thus, this rare case of congenital hypothyroidism with citullinemia in a baby with unusual findings draws indispensable attention.

## CONCLUSION

Before neonatal screening programs, congenital hypothyroidism was rarely recognized in the newborn because most affected infants are asymptomatic at birth. So the thyroid profile should be done on 3rd day of life and newborn screening should include dried blood spot for inborn error of metabolism to rule out any metabolic disorder and its association with congenital hypothyroidism.

## Consent

As per international standard or university standard, parental(s) written consent has been collected and preserved by the author(s).

## Ethical Approval:

As per international standard or university standard written ethical approval has been collected and preserved by the author(s).

## REFERENCE

1. American Academy of Pediatrics, Rose SR, Section on Endocrinology and Committee on Genetics, American Thyroid Association, Brown RS, Public Health Committee, Lawson Wilkins Pediatric Endocrine Society. Update of newborn screening and therapy for congenital hypothyroidism. *Pediatrics*. 2006 Jun;117(6):2290-303.
2. Maestri NE, Clissold DB, Brusilow SW. Long-term survival of patients with argininosuccinate synthetase deficiency. *The Journal of pediatrics*. 1995 Dec 1;127(6):929-35.
3. SUMMER M. Proceedings of Consensus Conference for the Management of Patients With Urea Cycle Disorders. Current strategies for the management of neonatal urea cycle disorders. *J Pediatr*. 2001;138:S30-9.
4. Häberle J, Boddaert N, Burlina A, Chakrapani A, Dixon M, Huemer M, Karall D, Martinelli D, Crespo PS, Santer R, Servais A. Suggested guidelines for the diagnosis and management of urea cycle disorders. *Orphanet journal of rare diseases*. 2012 Dec;7:1-30.
5. Olivieri A, Corbetta C, Weber G, Vigone MC, Fazzini C, Medda E, Italian Study Group for Congenital Hypothyroidism. Congenital hypothyroidism due to defects of thyroid development and mild increase of TSH at screening: data from the Italian National Registry of infants with congenital hypothyroidism. *The Journal of Clinical Endocrinology & Metabolism*. 2013 Apr 1;98(4):1403-8.
6. Wassner AJ. Congenital hypothyroidism. *Clinics in perinatology*. 2018 Mar 1;45(1):1-8.
7. LaFranchi SH, Austin J. How should we be treating children with congenital hypothyroidism?. *Journal of Pediatric Endocrinology and Metabolism*. 2007 May 1;20(5):559-78.
8. La Franchi SH. Hypothyroidism. *Pediatr Clin North Am*. 1979;26:33-51.
9. Julvez J, Alvarez-Pedrerol M, Rebagliato M, Murcia M, Fornis J, Garcia-Esteban R, Lertxundi N, Espada M, Tardón A, Galán IR, Sunyer J. Thyroxine levels during pregnancy in healthy women and early child neurodevelopment. *Epidemiology*. 2013 Jan 1:150-7.

#### ABBREVIATIONS

1. CH ( Congenital hypothyroidism)
2. IUGR ( Intrauterine growth restriction)
3. SNCU ( Sick newborn care unit)
4. TORCH ( Toxoplasma, Rubella, Cytomegalovirus, herpes virus)
5. MRCONS ( Methicillin resistance coagulase negative staphylococcus)
6. CMV ( Cytomegalovirus)
7. CSF ( Cerebrospinal fluid)
8. USG ( Ultrasound)
9. VD ( vaginally Delivered)
10. TSH ( Thyroid stimulating hormone)
11. T3 ( Triiodothyronine)
12. T4 ( Thyroxine)

Fig 1 congenital hypothyroidism and investigation reports.

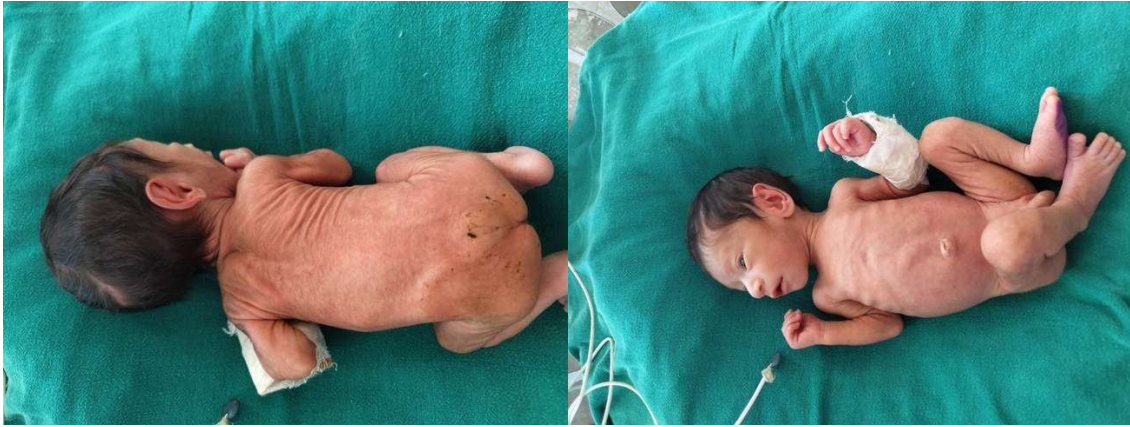

Fig 2-Thyroid profile

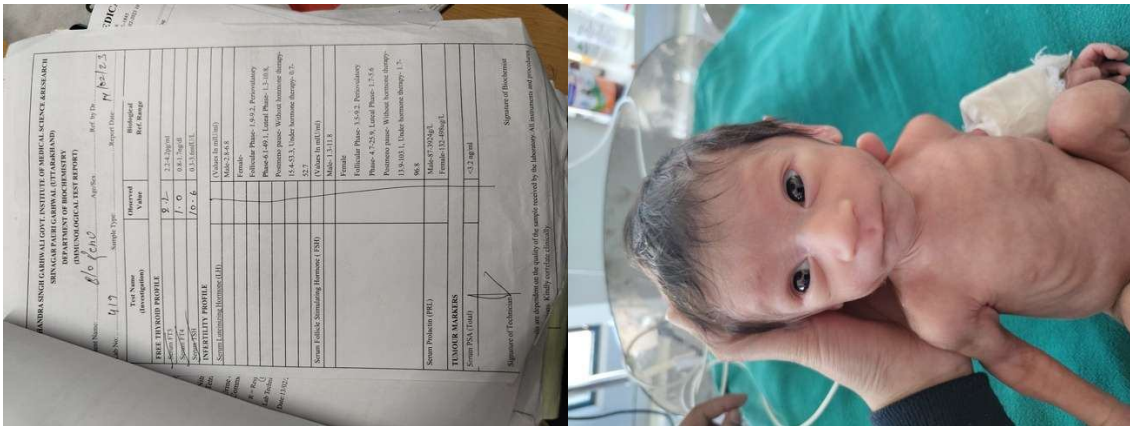


Fig 3- Dried blood spot for inborn error of metabolism



