

Case report

Achalasia an unusual indication for esophagectomy case report

Abstract: achalasia is a rare disease. Treatment options in delayed stages like sigmoid esophagus are heller myotomy and esophagectomy. This case report aims to show the anatomy variations, strength, and outcomes of esophagectomy with and hybrid technique.

Presentation of Case: A 69-year-old man presented with a long history of dysphagia, regurgitation, and smoking history. An esophagectomy was done. A common complication presented (fistula) and other not so common; pyloric obstruction. Then the patient improved with conservative management

Discussion: The presence of an aberrant left hepatic artery can be found in the creation of a gastric pull-up. Esophagectomy in patients with achalasia seems a safe procedure.

Conclusion: It is important to know the anatomical variations that can be found in esophagectomy to reduce complications in the patient. knowledge of postoperative complications and their treatment has important implications for the right management.

Keywords: achalasia, esophagectomy, minimally invasive approach, three-hole esophagectomy, left aberrant hepatic artery.

Introduction

Achalasia is a rare esophageal motor disorder with a prevalence of 8 cases per 100,000 inhabitants(1). In which there is loss of peristalsis predominantly in the distal esophagus as well as loss of relaxation of the lower esophageal sphincter (LES). The etiology is unknown, however, the most accepted theory proposes that there is a decrease in inhibitory ganglion cells of the myenteric plexus of the esophagus. Consequently producing an imbalance in neurotransmitters and motor alterations such as decreased peristalsis, increased esophageal body pressure, and hypertonia of the LES due to the absence of its relaxation(2).

There are multiple treatments, from pharmacological treatments based on nitrates, botulinum toxin and calcium antagonists which cause smooth muscle relaxation and decrease LES pressure, nevertheless, the main disadvantage of these treatments is that they are temporary (3)

Esophageal dilatation is another treatment modality with an efficacy of 65-85% in a short period time. On the other hand, this treatment has a long-term efficacy of 40 %. Additionally, gastroesophageal reflux disease presents as a complication. (4).

The standard surgical treatment is cardiomyotomy, which consists of an anterior myotomy of the fibers of the LES, and the association with an anti-reflux procedure (180° fundoplication either anterior or posterior) with an effectiveness of up to 80% and 65% at 20 years(5,6). Several studies have shown superior efficacy in endoscopic treatment with botulinum toxin (7).

Finally, esophagectomy is considered only in the presence of a tortuous esophagus, sigmoid esophagus, megaesophagus, or failure in a patient treated surgically with a myotomy procedure(8). While there are a few reports of esophagectomy secondary to achalasia we decided to present this report as an uncommon indication for esophagectomy as well as the strength, outcomes, and limitations of the surgical technique.

Case report: A 69 year-old man presented with a long history of dysphagia, regurgitation, and smoking history. No loss of weight or nodal mass in CT. Manometric assessment reports a pattern of I of the Chicago classification, esophageal endoscopy reveals intrinsic narrowing and hiatal hernia type III .

Contrasted radiography of the upper intestinal tract shows a distal filling defect and a sigmoid esophagus (figure 1) Previously the intervention laboratory test revealed leukocytes 50000 /mcl, hemoglobin 17 g/dl, hematocrit 51 %, platelets 340000/mcl, glucose 119 mg/dl, urea 3 mg/dl, creatinine .80 mg/dl

Operative technique: Under endotracheal intubation, and general anesthesia, the patient was placed in the left lateral position. An incision of 5 mm was made in the right thorax at the level of the 5° intercostal space, at the anterior axillary line an optic trocar was placed, pneumotorax started up to 8 mmHg, two other trocars were set for the assistant, dissection of the esophagus was started in the parietal pleural by advanced monopolar energy, the dissection was followed dorsally. (Figure 2) The azygos vein was clipped, then it was cut.

The abdominal dissection was started by dissecting the greater curvature of the stomach and the lesser curvature, preserving the right gastroepiploic artery. We found a left aberrant hepatic artery, so we stopped the dissection at this point, the gastric tube was created with 3 linear staplers of 60 mm. 4.8 mm. We decided to use 200 units of botulinum toxin in the pylorus as a drainage procedure. Lateral incision to the sternocleidomastoid muscle, dissection until the esophagus is located then esophagus is extracted. (Figure 3)

We decided to convert to a laparotomy because both sides of the future anastomosis were tense. Kocher maneuver was made to reach a larger gastric tube. An enteral access to nutrition was made with a tube jejunostomy created for enteral nutrition.

Hand sewn anastomosis was performed with PDS 3-0 in one fashion running suture and Connell-mayo suture (Figure 4). Pen rose drainage was placed in the cervical surgical bed, and two closed drainages in the thorax and abdomen were placed. Abdominal wall closure was performed conventionally. An endopleural tube was placed in the right pleural cavity, continuous suction was started. A chest x-ray of the thorax 24 hours later showed a gastric tube placed in the mediastinum without complications. An apparent complex collection was observed in the right thorax, a thorax CT-Scan was obtained, and a dilated gastric tube was observed secondary to a closed pyloric and delayed gastric emptying, decompression was started with a nasogastric tube.

On the 13th postoperative day esophageal fistula was diagnosed the patient continued decompression of the gastric tube. The patient was discharged on the 15th postoperative day and was followed weekly until the cervical drainage was removed. Accidentally, the jejunostomy tube was removed one month later, because the above, contrast study was done, and it revealed the correct passing of contrast beyond the pylorus.

Discussion

As mentioned above, achalasia is a rare motor disorder that had a palliative treatment in all the options of management. The indication of esophagectomy in a long-term disease with anatomical changes is offered in approximately 5 % of the patients. (9)

The long-term changes in patients with achalasia are the sigmoid esophagus, a tortuous supradiaphragmatic segment, clinically with delayed emptying. Our patient presented with a similar presentation.

In 2012 a classification was proposed regarding the morphology of the esophagus, this divides it into 3 types: I (<3 cm), II (3.5-6 cm), and III (6 cm). It takes into account the radiographic findings, measuring the maximum transverse diameter and the angulation it creates in the esophageal axis. (10). Moreover, the sigmoid esophagus is defined as having a diameter of 10 cm. (11)

In Latin America the indication for esophagectomy tends to raise, which is considered a safe procedure in benign causes of esophagectomy, one of the largest reported series was published by Pinotti et. al. (12) The etiology of the sigmoid esophagus in this series of patients was Chagas disease, with similar clinical characteristics as our patient but the pathology differs.

There is literature supporting heller myotomy in patients with megaesophagus. (13) However, in patients with a diameter greater than 6-7 cm in the upper third of the esophagus, beneath 55 years of age, severe mucosal inflammation and moderate to severe dysphagia. The outcomes showed that the reflux is attributed to the Heller myotomy, conversely, the dysphagia improves with surgery, except for 27% of patients that were submitted to myotomy of heller with a preoperative diagnosis of sigmoid esophagus, which suggests the resection of the esophagus from the beginning. (14)

In the context of patients with megaesophagus or sigmoid esophagus as in our patient, resection and reconstruction are recommended. (15,16). Esophagectomy is the best treatment to release esophageal obstruction, dismissing pulmonary complications in patients with achalasia and megaesophagus, This treatment is by far superior to myotomy or cardioplasty.

Regarding the technical difficulties that can be encountered in a gastric pull-up, the most common anatomical variant is the aberrant left hepatic artery, a branch of the left gastric artery. The patient presented an aberrant left hepatic artery, so it was decided to left in place, not knowing the implications that could occur, such as distal ischemia of the gastric tube, and hepatic ischemia, the last mentioned complication has already been described previously. (17,18). The incidence of hepatic ischemia is as high as 6.3%. The presence of an aberrant left hepatic artery is reported in 4.3-22.4%. (17).

Outcomes in esophagectomies for other causes versus achalasia have the same overall results; mortality, readmission, reoperation, and overall complications are not statistically significantly associated in patients undergoing esophagectomy for achalasia and non-achalasia patients. (19) The patient remained hospitalized for 15 days.

Anastomotic leakage is one of the most feared complications. (20), is present in 6.6-17 % of anastomoses at the cervical level. An anastomotic leak is defined as a "full-thickness gastrointestinal defect involving the esophagus, anastomosis, staple line, or conduit, regardless of presentation or method of identification". (21)

The incidence of anastomotic leakage is reported to be 2% in the minimally invasive Ivor Lewis approach and 6.6% in the Mckeown approach. (22) Another large series of patients (n=501) reported an incidence of 11.8 % overall, leakage was predominant in the minimally invasive approach with a rate of 20 %. (23).

In the particular case of our patient, conservative management was decided since it was fitted in the classification of Lerut et al. We detected it by radiological studies. (21) The clinical evolution did not show any inflammatory response and the upper intestinal tract contrasts did not show collections in cervical anatomic planes. Some risk factors have been identified concerning the patient's medical history: malnutrition (albumin <3.0 g/dL), obesity (body mass index [BMI] > 30 kg/m²) or underweight patients (BMI < 18.5 kg/m²), heart failure, hypertension, diabetes, renal failure, steroids, and tobacco use.(24)

Regarding the surgical technique and anastomotic leaks, it is debated whether there are factors that influence the leakage of the anastomosis, it is more common as mentioned above in cervical leaks, requiring a longer segment of the stomach and the site where the anastomosis is performed, which is at the level of the gastric fundus, a site that presents some restriction of blood supply. (24) Despite preserving the left gastric artery in this case, having a double irrigation tube, a leak occurred. Currently, there are no studies comparing the results and the rate of leakage in patients operated on with minimally invasive esophagectomy techniques in comparison with the open or hybrid approach as well as in favor of or against hand-sewn or mechanical anastomosis in this type of patient. The maximum evidence we have is in oncologic patients in whom it has been demonstrated that there is no difference between the technical factors: hand-sewn anastomosis versus EGA, minimally invasive approach versus open esophagectomy, or the route of the ascent of the gastric tube. (24,25)

Although there is evidence comparing non-draining versus intrapyloric Botulinum Toxin injection versus pyloroplasty, pyloroplasty is not associated with short-term complications, only with long-term morbidity. Intervention at the level of the pylorus may be necessary. Despite the use of intrapyloric botulinum toxin injection, the patient developed delayed gastric emptying.(26)

It is important to know the anatomical variations that can be found in esophagectomy to reduce complications. Knowledge of postoperative complications and their treatment has implications for a right management. Although there is not much evidence of the results of esophagectomies for advanced-stage achalasia, the current evidence shows a solid basis for guidance and a safe procedure.

Competing interests

There is not influence from other people or organizations in the presentation and interpretation of the information in this case report by the authors.

References:

1. Epidemiology and demographics of achalasia - PubMed [Internet]. [cited 2023 Mar 6]. Available from: <https://pubmed.ncbi.nlm.nih.gov/11319059/>
2. Townsend CM, Beauchamp RD, Evers BM, Mattox KL, Sabiston DC. Sabiston textbook of surgery : the biological basis of modern surgical practice. 21°. 2021. 1049–106 p.
3. Annese V, Basciani M, Perri F, Lombardi G, Frusciante V, Simone P, et al. Controlled trial of botulinum toxin injection versus placebo and pneumatic dilation in achalasia. Gastroenterology [Internet]. 1996 [cited 2023 Mar 6];111(6):1418–24. Available from: <https://pubmed.ncbi.nlm.nih.gov/8942719/>

4. Leyden JE, Moss AC, Macmathuna P. Endoscopic pneumatic dilation versus botulinum toxin injection in the management of primary achalasia. Vol. 2014, Cochrane Database of Systematic Reviews. John Wiley and Sons Ltd; 2014.
5. Jara FM, Toledo-Pereyra ; L H, Lewis ; J W, Magilligan ; D J. Long-term Results of Esophagomyotomy for Achalasia of Esophagus [Internet]. Vol. 114, Arch Surg. 1979. Available from: <http://archsurg.jamanetwork.com/>
6. Ortiz A, De Haro LFM, Parrilla P, Lage A, Perez D, Munitiz V, et al. Very long-term objective evaluation of Heller myotomy plus posterior partial fundoplication in patients with achalasia of the cardia. *Ann Surg*. 2008 Feb;247(2):258–64.
7. Campos GM, Vittinghoff E, Rabl C, Takata M, Gadenstätter M, Lin F, et al. Endoscopic and surgical treatments for achalasia: A systematic review and meta-analysis. *Ann Surg*. 2009 Jan;249(1):45–57.
8. Lin J, Iannettoni MD. Transhiatal esophagectomy. Vol. 85, *Surgical Clinics of North America*. 2005. p. 593–610.
9. Duranceau A, Liberman M, Martin J, Ferraro P. End-stage achalasia. Vol. 25, *Diseases of the Esophagus*. 2012. p. 319–30.
10. Descriptive Rules for Achalasia of the Esophagus, June 2012: 4th Edition. *Esophagus* [Internet]. 2017 Oct 1 [cited 2023 Mar 7];14(4):275–89. Available from: <https://pubmed.ncbi.nlm.nih.gov/28983228/>
11. Roll GR, Rabl C, Ciovica R, Peeva S, Campos GM. A controversy that has been tough to swallow: is the treatment of achalasia now digested? *J Gastrointest Surg* [Internet]. 2010 Feb [cited 2023 Mar 7];14 Suppl 1(Suppl 1). Available from: <https://pubmed.ncbi.nlm.nih.gov/19760373/>
12. Pinotti HW, Ceconello I, da Rocha JM, Zilberstein B. Resection for achalasia of the esophagus. *Hepatogastroenterology* [Internet]. 1991 Dec;38(6):470—473. Available from: <http://europepmc.org/abstract/MED/1778572>
13. Patti MG, Feo C V., Diener U, Tamburini A, Arcerito M, Safadi B, et al. Laparoscopic Heller myotomy relieves dysphagia in achalasia when the esophagus is dilated. *Surg Endosc* [Internet]. 1999 Sep [cited 2023 Mar 7];13(9):843–7. Available from: <https://pubmed.ncbi.nlm.nih.gov/10449836/>
14. Ruffato A, Mattioli S, Lugaresi ML, D'Ovidio F, Antonacci F, Di Simone MP. Long-term results after Heller-Dor operation for oesophageal achalasia. *Eur J Cardiothorac Surg* [Internet]. 2006 Jun [cited 2023 Mar 7];29(6):914–9. Available from: <https://pubmed.ncbi.nlm.nih.gov/16675239/>
15. Orringer MB, Stirling MC. Esophageal resection for achalasia: indications and results. *Ann Thorac Surg* [Internet]. 1989 [cited 2023 Mar 7];47(3):340–5. Available from: <https://pubmed.ncbi.nlm.nih.gov/2649031/>
16. Peters JH, Kauer WKH, Crookes PF, Ireland AP, Bremner CG, Demeester TR. Esophageal resection with colon interposition for end-stage achalasia. *Arch Surg* [Internet]. 1995 [cited 2023 Mar 7];130(6):632–7. Available from: <https://pubmed.ncbi.nlm.nih.gov/7763172/>
17. Maki H, Satodate H, Satou S, Nakajima K, Nagao A, Watanabe K, et al. Clinical evaluation of the aberrant left hepatic artery arising from the left gastric artery in esophagectomy. *Surgical and Radiologic Anatomy*. 2018 Jul 1;40(7):749–56.

18. Oki E, Sakaguchi Y, Hiroshige S, Kusumoto T, Kakeji Y, Maehara Y. Preservation of an aberrant hepatic artery arising from the left gastric artery during laparoscopic gastrectomy for gastric cancer. *J Am Coll Surg*. 2011 May;212(5).
19. Torres-Landa S, Crafts TD, Jones AE, Dewey EN, Wood SG. Surgical Outcomes After Esophagectomy in Patients with Achalasia: a NSQIP Matched Analysis With Non-Achalasia Esophagectomy Patients. *Journal of Gastrointestinal Surgery*. 2021 Oct 1;25(10):2455–62.
20. Famiglietti A, Lazar JF, Henderson H, Hamm M, Malouf S, Margolis M, et al. Management of anastomotic leaks after esophagectomy and gastric pull-up. *J Thorac Dis [Internet]*. 2020 Mar 1 [cited 2023 Mar 7];12(3):1022–30. Available from: <https://pubmed.ncbi.nlm.nih.gov/32274171/>
21. Fabbi M, Hagens ERC, Van Berge Henegouwen MI, Gisbertz SS. Anastomotic leakage after esophagectomy for esophageal cancer: definitions, diagnostics, and treatment. *Dis Esophagus [Internet]*. 2021 Jan 1 [cited 2023 Mar 7];34(1). Available from: <https://pubmed.ncbi.nlm.nih.gov/32476017/>
22. Brown AM, Pucci MJ, Berger AC, Tatarian T, Evans NR, Rosato EL, et al. A standardized comparison of peri-operative complications after minimally invasive esophagectomy: Ivor Lewis versus McKeown. *Surg Endosc [Internet]*. 2018 Jan 1 [cited 2023 Mar 7];32(1):204–11. Available from: <https://link.springer.com/article/10.1007/s00464-017-5660-4>
23. Fumagalli U, Baiocchi GL, Celotti A, Parise P, Cossu A, Bonavina L, et al. Incidence and treatment of mediastinal leakage after esophagectomy: Insights from the multicenter study on mediastinal leaks. *World J Gastroenterol [Internet]*. 2019 Jan 1 [cited 2023 Mar 7];25(3):356. Available from: </pmc/articles/PMC6343094/>
24. Kassis ES, Kosinski AS, Ross P, Koppes KE, Donahue JM, Daniel VC. Predictors of anastomotic leak after esophagectomy: an analysis of the society of thoracic surgeons general thoracic database. *Ann Thorac Surg [Internet]*. 2013 Dec [cited 2023 Mar 7];96(6):1919–26. Available from: <https://pubmed.ncbi.nlm.nih.gov/24075499/>
25. Markar SR, Arya S, Karthikesalingam A, Hanna GB. Technical factors that affect anastomotic integrity following esophagectomy: systematic review and meta-analysis. *Ann Surg Oncol [Internet]*. 2013 [cited 2023 Mar 7];20(13):4274–81. Available from: <https://pubmed.ncbi.nlm.nih.gov/23943033/>
26. Nobel T, Tan K S, Barbetta A, Adusumilli P, Bains M, Bott M, Jones D, & Molena D. (2019). Does pyloric drainage have a role in the era of minimally invasive esophagectomy?. *Surgical endoscopy*, 33(10), 3218–3227. <https://doi.org/10.1007/s00464-018-06607-8>

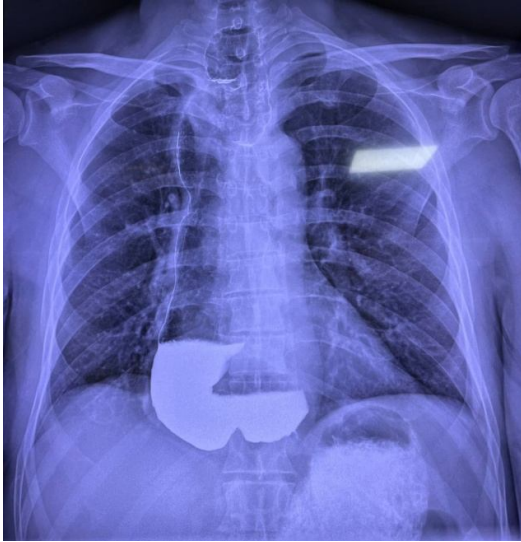


Figure 1. Contrasted radiographic study showing dilated esophagus in all its portions

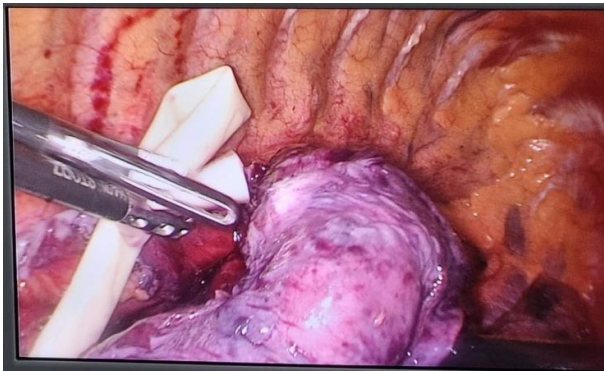

Figure 2. Esophageal dissection

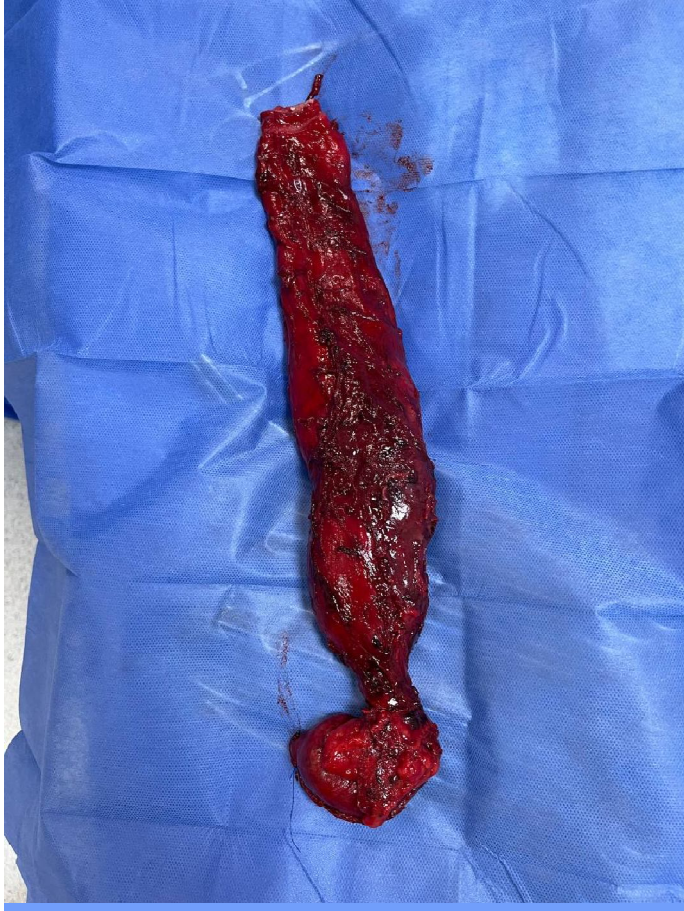
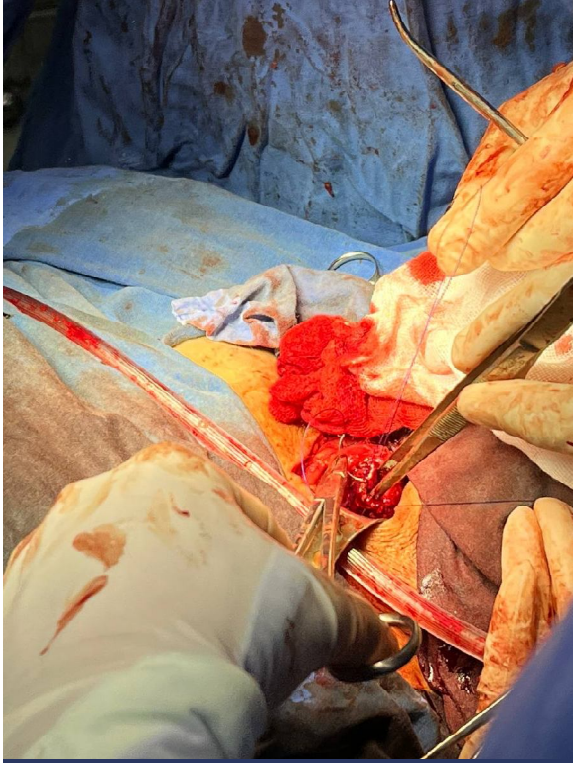
Figure 3. Surgical specimen resected esophagus from its cervical portion to the esophagogastric junction

Figure 4. Gastric-esophageal hand sewn anastomosis in 1 layer with PDS-3-0



UNDER PEER REVIEW