

## **Case study**

### **Parotid abscess in an ulcerative colitis patient on infliximab: a case report**

#### **Abstract**

Anti-Tumor Necrosis Factor- $\alpha$  (anti-TNF) is a widely used immunosuppressive drug in inflammatory bowel disease (IBD). Parotid abscess results as a complication of the primary parotitis. It is an uncommon condition, that occurs in immunocompromised host. To our knowledge, it seems to be the first case described in the literature of an ulcerative colitis who developed a parotid abscess as an adverse effect to infliximab.

Keywords: Infliximab- Crohn's disease- parotid- abscess- Antibody

#### **Introduction**

Anti-tumor necrosis factor (anti-TNF) is highly effective therapeutic tool in inflammatory bowel disease's (IBD) treatment [1]. However, infections and malignancy are well recognized serious complications associated with this therapy [2]. The parotid gland is the largest and the most commonly affected salivary gland by inflammation [3]. We report an unusual case of parotid gland abscess that developed in an Ulcerative colitis (UC) patient while on anti-TNF $\alpha$  therapy.

#### **Case report**

A 16 year old female patient without significant past medical history was admitted to the hospital because of acute severe ulcerative colitis. High-dose intravenous methylprednisolone (50 mg IV) were ineffective. She was considered corticosteroid refractory. After screening for latent infections, a rescue biological therapy with infliximab was begun at the dose of 5 mg/kg with an excellent clinical response. Before the second infusion dose of infliximab, the patient presented with a history of painful, red and warm right sided facial swelling and fever (39°C). On examination, there was a 5×5 cm warm, tender, erythematous swelling overlying the right parotid gland which was mildly fluctuant and not discharging (Figure 1)

Ultrasound of the parotid region revealed a hypoechoic lesion consistent with fluid collection posterior to the angle of the mandible (Figure 2). Computed tomography (CT) scan of the neck revealed a hypodense nodular lesion of 44,7mmx 6,5 mm suggestive of parotid abscess with submandibular lymphadenitis measuring 8mm. (Figure 3)

The initial Blood tests found an elevated C-reactive protein CRP 177 mg/dL and neutrophilia 9850 / $\mu$ L. Pus was exuded from right Stensen's duct on compression of the gland externally yielding 3cc of purulent material. Bacterial cultures didn't identify any organism on gram stain and culture. The patient was treated with intravenous antibiotics (amoxicillin/clavulanate) for 4 weeks then switched to oral antibiotic for 2 weeks. She achieved a total of 6 weeks antibiotic. After discharge, there was a noticeable clinical improvement, biological parameters normalized and abscess disappear on the ultrasound. (Figure 4)

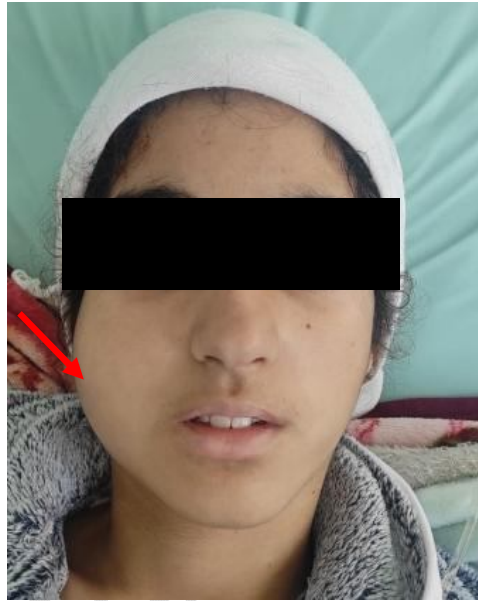

Figure 1: Clinical picture showing tumefaction of the right parotid

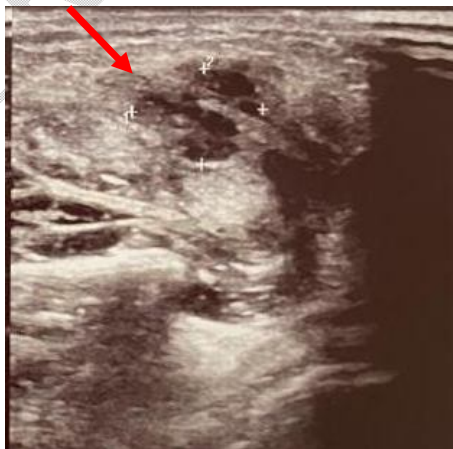

Figure 2: Ultrasound image showing hypoechoic lesion of the right parotid gland with

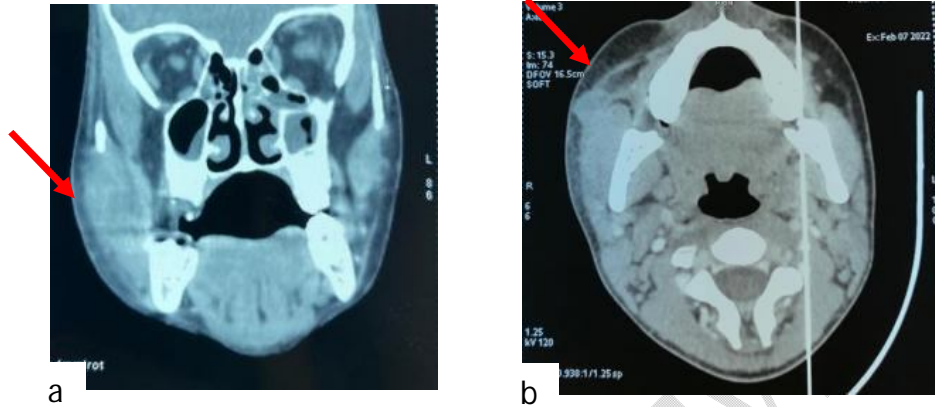


Figure 3: CT scan head and neck with contrast at initial presentation  
a) Coronal image  
b) Axial image

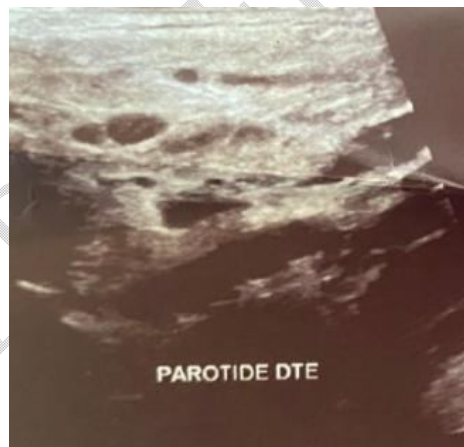


Figure 4: Ultrasound image after the resolution of the parotid abscess

## Discussion

We present the first reported case of parotid gland abscess in a patient on infliximab therapy.

Infliximab is a chimeric anti-TNF-alpha monoclonal antibody who inhibit the TNF-alpha, a pro-inflammatory cytokine produced by macrophages and other

inflammatory cells. It is used in the treatment of several immune-mediated inflammatory diseases such as IBD: Crohn's disease and Ulcerative colitis [1]. The literature supports an increased rate of infection with TNF- $\alpha$  inhibitors. Infliximab can be responsible of bacterial, fungal, viral and parasitic infections [2]. The parotid gland is a superficial salivary gland [3], most commonly infected by direct extension of microorganisms from the oral cavity via Stensen duct [4]. Other less common routes are hematogenous spread and lymphatic spread from distant pulmonary focus. Predisposing factors of parotitis include ductal dysfunction, immunosuppression, dehydration, poor oral hygiene or dental infections [5]. In our case the patient was immunocompromised. The most frequently causative pathogen is *Staphylococcus aureus* [6]. However, low rate of positive culture of parotid abscess has been reported [7], as with our case

Clinical features include pain, warm, erythematous swelling and palpable mass in the preauricular region associated with marked fever and leukocytosis [8]. Our patient had presented this symptoms. The infection may be bilateral. On ultrasound, the parotid gland would be usually enlarged with oedema and increased vascularity and the collection would be seen as an hypoechoic lesion [9]. CT provide useful additional diagnostic imaging and permit to exclude possible underlying malignancy.

Management usually focuses on the use of intravenous empirical antibiotics guided thereafter by the culture results. Surgical drainage is indicated if failure of medical therapy or facial nerve involvement [8, 10]. The prognosis of parotid abscess is good after adequate treatment. Fortunately, our patient did not develop facial nerve dysfunction and responded the treatment well without significant complication.

## **Conclusion**

We report the first case of parotid gland abscess in a patient under anti-TNF. Given the increasing incidence of IBD, the use of biologic therapies is expected to increase in the coming years. Thus, it is important to know the infectious risks associated with these drugs due to its immunosuppressive effects. So, a close follow-up is recommended.

## **References**

- [1] Hazeseleer C, Martiny D, Van Laethem Y, Cantinieaux B, Martin C. Reactivation of Plasmodium infection during a treatment with infliximab: A case report. *Int J Infect Dis.* 2020;91:101-103. doi: 10.1016/j.ijid.2019.11.016
- [2] Scheinfeld N. A comprehensive review and evaluation of the side effects of the tumor necrosis factor alpha blockers etanercept, infliximab and adalimumab. *J Dermatolog Treat* 2004;15:280-94.

- [3] Vorrasi J, Zinberg G. Concomitant suppurative parotitis and condylar osteomyelitis. *J Oral Maxillofac Surg* 2017; 75: 543–549.
- [4] Sikora A. G., Rothstein S. G., Garay K. F., Spiegel R. Tuberculosis of the head and neck. In: Rom W. N., Garay S. M., editors. *Tuberculosis*. 2nd. Philadelphia, PA, USA: Lippincott Williams and Wilkins; 2004. pp. 477–488.
- [5] Viselner G, van der Byl G, Maira A, et al. Parotid abscess: mini-pictorial essay. *J Ultrasound* 2013; 16: 11–15.
- [6] Pampín Ozán D, Cariati P, Arroyo Rodriguez S. Parotid abscess by *Candida glabrata*. *Med Clin (Barc)*. 2021;156(10):528. doi:10.1016/j.medcli.2020.01.017
- [7] Ganesh R, Leese T. Parotid abscess in Singapore. *Singapore Med J* 2005;46:553–6.
- [8] Tan VE, Goh BS. Parotid abscess: a five-year review – clinical presentation, diagnosis and management. *J Laryngol Otol* 2007; 121: 872–879
- [9] Kolekar S, Chincholi TS, Kshirsagar A, Porwal N. Acute neonatal parotid abscess: A rare case report. *Afr J Paediatr Surg*. 2016;13(4):199-201. doi:10.4103/0189-6725.194675
- [10] Lakshmi Narayana M, Azeem Mohiyuddin SM, Mohammadi K, et al. Parotid abscesses in children: a tertiary rural hospital experience. *Int J Pediatr Otorhinolaryngol* 2015;79:1988–90.