

## Original Research Article

### INCIDENCE OF PERINEURAL INVASION OF ORAL SQUAMOUS CELL CARCINOMA AND ITS ASSOCIATION WITH WORST PATTERN OF INVASION AND STAGING OF TUMOR- A RETROSPECTIVE STUDY

#### **ABSTRACT**

**Background:** Histological parameters are the most reliable factors in diagnosis, management and prognosis of oral squamous cell carcinoma (OSCC). The incidence of perineural invasion (PNI) and its association with staging of tumor and worst pattern of invasion (WPOI) have influenced the outcome of the disease. This retrospective study was conducted to determine the association of PNI with staging of tumor and WPOI

**Methodology:** Sixty-six cases of histopathologically confirmed OSCC treated surgically without neo-adjuvant chemo-radiotherapy between 2019 Jan -2020 June were included in the study. The subjects were divided into group A with PNI negative subjects and Group B with PNI positive subjects.

**Results:** Out of 66 cases ,42 patient were PNI negative (63.6%) and 24 patients were PNI positive (36.4%). WPOIIV-V was present in 38 (57.6 %) of the cases and I-III was seen in 28 (42.4%) of the 66 patients.

**Conclusion:** WPOI and PNI are significantly important risk factors for predicting LN metastasis in all stages of Oral squamous cell carcinoma and are associated with a poorer outcome in early-stage tumors.

**Keywords:** Oral squamous cell carcinoma (OSCC), Worst pattern of invasion (WPOI), Perineural invasion (PNI).

#### **INTRODUCTION**

Oral cancer is a disease of antiquity with incidence of OSCC ranked one amongst men and third among women in India <sup>[1]</sup>. “There is no progress in the 5-year survival rates of patients with OSCC over the last 20 years” <sup>[5]</sup>. “However, despite increased detection of early-stage oral cavity squamous cell carcinoma, disease-specific mortality rates for stages I and II oral cavity squamous cell carcinoma remains at 25% and 37%, respectively” <sup>[2]</sup>. “Surgical resection, neck dissection, radiotherapy and chemotherapy are preferred therapeutic strategies for OSCC. A delayed diagnosis of nodal metastasis may lead to an increase in the risk of extra-capsular spread

and involvement of a larger number of nodes by the time of surgery is commenced. Treatment failure and loco-regional recurrence occur in and about 30% of early staged OSCC patients which indicates aggressive treatment protocols to be warranted for such subset of patients” [3]. Negative surgical margins governs better prognosis.

“Various factors such as margin status, perineural invasion (PNI), lymphovascular invasion (LVI), muscle invasion, WPOI, tumor budding, depth of invasion (DOI) and/or tumor thickness (TT) are suggested prognostic factors for lymph node metastasis. Prognosis is affected by PNI) which is one of the several clinicopathological factors. PNI is due to tropism of tumor cells for nerve bundles in the surrounding stroma”<sup>[4]</sup>. “Incidence of PNI in head and neck cancer is as high as 80%”.<sup>[3]</sup>

“Worst pattern of invasion (WPOI) describes the invading tumor front. There is scarcity about WPOI in the literature pertaining to OSCC. Patterns of invasion is divided into five categories which have been defined to denote the manner in which cancer infiltrates tissues at the tumor–host interface. Pattern 1-3 is considered to be cohesive pattern and 4-5 are considered to be invasive pattern with bad prognosis”.<sup>[2]</sup>

This retrospective study aims to note the incidence of PNI in different stages of tumor in OSCC and whether it is associated with WPOI.

### **AIMS AND OBJECTIVES:**

**Aim:** To evaluate the incidence of perineural invasion (PNI) positive and perineural invasion negative patients and co-relating it with staging of oral cancer and worst pattern of invasion (WPOI).

**Objective:**

- To evaluate incidence of perineural invasion in oral squamous cell carcinoma (OSCC).
- To evaluate and co-relate the significance of PNI invasion with worst pattern of invasion (WPOI) and staging of tumour.

### **METHODOLOGY**

After obtaining ethics committee approval, the records of the subjects having visited to the Department of Oral and Maxillofacial Surgery, and Department of Surgical Oncology, Yenepoya Medical college and hospital, Mangalore, Karnataka, between January 2019 to June-2020 for treatment of oral cancer were included in the study.

All the patients who were biopsy proven OSCC and who had undergone wide local excision of the primary tumor and neck dissection, were included in this study. Patient with history of

radiotherapy or chemotherapy, recurrent disease or second primary and below 18 years of age were excluded from **this** study.

The slides were archived from Department of Onco-pathology and reviewed for histological parameters including WPOI, **Stage of tumor**, Perineural invasion (PNI). The sample size consisted of 66 records were divided into group A and group B, of which Group A consisted of PNI negative patient and Group B consisted of PNI positive patients. WPOI I-III is considered to be cohesive pattern and WPOI IV-V is considered to be invasive pattern as shown in Tab.1<sup>[2]</sup>. Chi-square analysis was used to find the co-relation between PNI+ve and –ve with WPOI and staging of tumor.

### **RESULTS:**

Records of 66 subjects with oral cavity squamous cell carcinoma fulfilled our inclusion criteria and were assigned to categories accordingly as discussed before.

Patients in group A consisted of 42 subjects (63.6%) and group B consisted of 24 subjects (36.4%) [tab.2]. Frequency of WPOI I-III was seen in 28 (42.4%) patients, whereas WPOI IV-V was seen in 38(57.6%) patients[tab.3]. pT2 was seen in 43.9% of the cases followed by pT4 19.7% [tab.4].

Chi-square analysis test was used to co-relate PNI with WPOI, it was concluded that there is a significant association between PNI and WPOI (p value<0.0001) [tab.5]. There is no significant association between PNI and pT [tab.6]. Whereas, lymph node positive status was significantly associated with invasive WPOI [tab.7].

### **DISCUSSION:**

“The incidence of oral cavity carcinoma is steadily increasing worldwide due to tobacco consumption and has become a public health problem in developing countries such as India. A few Indian studies have been done on the prevalence of HPV in OSCC in Indian population. The overall prevalence of HPV in OSCC in India has been reported as ranging from 20% to 50%”<sup>[9]</sup>. In general, the prognosis of these patients remains poor. Lymph node metastasis is considered as an independent poor prognostic factor for OSCC.

“ However, clinical examination and radiological investigations such as computed tomography scan is routinely used to determine LN metastasis, with variable sensitivity. Previous studies have evaluated various histological parameters that can predict cervical LN metastasis in OSCC. Debajyoti Chatterjee et al in 2019 reported that WPOI IV-V was significantly associated with poor prognosis and higher recurrence rate compared to cohesive patterns”<sup>[1]</sup>. Namita Sinha et. Al in 2018 found out recurrence and death was seen 41% and 23% respectively were associated with invasive POI. WPOI IV- V are associated with higher risk of LN metastasis which co-relates with the present study<sup>[2]</sup>. Pattern of invasion is strongly associated with risk of LN and distant metastasis. Invasive POI is able to predict the risk of occult LN metastasis efficiently and seen in the present study as well. We also found a significant correlation between invasive WPOI and LN.

“However, some studies have reported contradictory findings. Lundqvist et al and Kane et al didn't find any adverse effect of WPOI on risk of LN metastasis”<sup>[6-7]</sup>. Almangush et al found out that “high-risk WPOI are associated with poor prognosis in early-stage oral tongue SCC”<sup>[8]</sup>. Perineural invasion (PNI), also called perineural spread and neurotropism, is used to describe the process of cancer cells “invasion in, around and through the nerves”<sup>[11]</sup>. Our study comprised of association of WPOI with PNI (Perineural Invasion) and it was found out that PNI positive patients were significantly associated with invasive WPOI, but WPOI is an independent risk factor irrespective of PNI -ve or PNI +ve group, as proven in the present study. In the present study we were not able to co-relate the survival rate of the patient as of 66 patients only 13 patients were seen for follow -up.

## CONCLUSION:

Thus, association of invasive WPOI with PNI will give us the risk of LN cervical spread and help us plan the treatment accordingly. In future co-relating WPOI with loco-regional recurrence will help us to avoid possible recurrence. Based on the findings of this study and the previous studies, we recommend that these parameters should be routinely evaluated both in resection and in preoperative biopsy specimens and should be a part of standard reporting format for OSCC, which may help in individualization of treatment in those patients.

## Consent

As per international standard or university standard, patient(s) written consent has been collected and preserved by the author(s).

### Ethical Approval:

As per international standard or university standard written ethical approval has been collected and preserved by the author(s).

### REFERENCES:

- 1 Chatterjee D, Bansal V, Malik V, Bhagat R, Punia RS, Handa U, Gupta A, Dass A. Tumor budding and worse pattern of invasion can predict nodal metastasis in oral cancers and associated with poor survival in early-stage tumors. *Ear, Nose & Throat Journal*. 2019 Aug;98(7):E112-9.
- 2 Sinha N, Rigby MH, McNeil ML, Taylor SM, Trites JR, Hart RD, Bullock MJ. The histologic risk model is a useful and inexpensive tool to assess risk of recurrence and death in stage I or II squamous cell carcinoma of tongue and floor of mouth. *Modern Pathology*. 2018 May;31(5):772-9.
- 3 Alkhadar H, Macluskey M, White S, Ellis I. Perineural invasion in oral squamous cell carcinoma: Incidence, prognostic impact and molecular insight. *Journal of Oral Pathology & Medicine*. 2020 Nov;49(10):994-1003.
- 4 Varsha BK, Radhika MB, Makarla S, Kuriakose MA, Kiran GS, Padmalatha GV. Perineural invasion in oral squamous cell carcinoma: Case series and review of literature. *Journal of oral and maxillofacial pathology: JOMFP*. 2015 Sep;19(3):335.
- 5 Cracchiolo JR, Xu B, Migliacci JC, Katabi N, Pfister DG, Lee NY, Patel SG, Ghossein RA, Wong RJ. Patterns of recurrence in oral tongue cancer with perineural invasion. *Head & neck*. 2018 Jun;40(6):1287-95.
- 6 Lundqvist L, Stenlund H, Laurell G, Nylander K. The importance of stromal inflammation in squamous cell carcinoma of the tongue. *J Oral Pathol Med*. 2012;41(5):379-383.
- 7 Kane SV, Gupta M, Kakade AC, D' Cruz A. Depth of invasion is the most significant histological predictor of subclinical cervical lymph node metastasis in early squamous carcinomas of the oral cavity. *Eur J Surg Oncol*. 2006;32(7):795-803.
- 8 Almagush A, Bello IO, Keski-Santti H, et al. Depth of invasion, tumor budding, and worst pattern of invasion: prognostic indicators in early-stage oral tongue cancer. *Head Neck*. 2014;36(6): 811-818.
- 9 Chocolatewala NM, Chaturvedi P. Role of human papilloma virus in the oral carcinogenesis: an Indian perspective. *Journal of cancer research and therapeutics*. 2009 Apr 1;5(2):71.
- 10 Schmitd LB, Scanlon CS, D'silva NJ. Perineural invasion in head and neck cancer. *Journal of dental research*. 2018 Jul;97(7):742-50.
- 11 Yang X, Tian X, Wu K, Liu W, Li S, Zhang Z, Zhang C. Prognostic impact of perineural invasion in early stage oral tongue squamous cell carcinoma: results from a prospective randomized trial. *Surgical oncology*. 2018 Jun 1;27(2):123-8.
- 12 Nair D, Mair M, Singhvi H, Mishra A, Nair S, Agrawal J, Chaturvedi P. Perineural invasion: Independent prognostic factor in oral cancer that warrants adjuvant treatment. *Head & neck*. 2018 Aug;40(8):1780-7.

- 13 Zhu J, Zhou R, Wang Y, Yu M. Perineural invasion as a prognostic factor in head and neck squamous cell carcinoma: a systematic review and meta-analysis. *Acta Oto-Laryngologica*. 2019 Nov 2;139(11):1038-43.
- 14 Cracchiolo JR, Xu B, Migliacci JC, Katabi N, Pfister DG, Lee NY, Patel SG, Ghossein RA, Wong RJ. Patterns of recurrence in oral tongue cancer with perineural invasion. *Head & neck*. 2018 Jun;40(6):1287-95.
- 15 Chinn SB, Spector ME, Bellile EL, McHugh JB, Gernon TJ, Bradford CR, Wolf GT, Eisbruch A, Chepeha DB. Impact of perineural invasion in the pathologically N0 neck in oral cavity squamous cell carcinoma. *Otolaryngology–Head and Neck Surgery*. 2013 Dec;149(6):893-9.
- 16 Dantas AN, Morais EF, Macedo RA, Tinôco JM, Morais MD. Clinicopathological characteristics and perineural invasion in adenoid cystic carcinoma: a systematic review. *Brazilian journal of otorhinolaryngology*. 2015 May;81:329-35.
- 17 Bapat AA, Hostetter G, Von Hoff DD, Han H. Perineural invasion and associated pain in pancreatic cancer. *Nature Reviews Cancer*. 2011 Oct;11(10):695-707.
- 18 Yeh CF, Li WY, Chu PY, Kao SY, Chen YW, Lee TL, Hsu YB, Yang CC, Tai SK. Pretreatment pain predicts perineural invasion in oral squamous cell carcinoma: A prospective study. *Oral Oncology*. 2016 Oct 1;61:115-9.
- 19 Bakst RL, Wong RJ. Mechanisms of perineural invasion. *Journal of Neurological Surgery Part B: Skull Base*. 2016 Apr;77(02):096-106.
- 20 Kolokythas A, Cox DP, Dekker N, Schmidt BL. Nerve growth factor and tyrosine kinase A receptor in oral squamous cell carcinoma: is there an association with perineural invasion?. *Journal of oral and maxillofacial surgery*. 2010 Jun 1;68(6):1290-5.
- 21 Ye Y, Dang D, Zhang J, Viet CT, Lam DK, Dolan JC, Gibbs JL, Schmidt BL. Nerve Growth Factor Links Oral Cancer Progression, Pain, and CachexiaAnti-NGF as a Therapy in Head and Neck Cancer. *Molecular cancer therapeutics*. 2011 Sep 1;10(9):1667-76.
- 22 Yu EH, Lui MT, Tu HF, Wu CH, Lo WL, Yang CC, Chang KW, Kao SY. Oral carcinoma with perineural invasion has higher nerve growth factor expression and worse prognosis. *Oral diseases*. 2014 Apr;20(3):268-74.
- 23 Shen WR, Wang YP, Chang JY, Yu SY, Chen HM, Chiang CP. Perineural invasion and expression of nerve growth factor can predict the progression and prognosis of oral tongue squamous cell carcinoma. *Journal of oral pathology & medicine*. 2014 Apr;43(4):258-64.

Table 1. Worst pattern of invasion.[2]

Variable	Definition
WPOI-I	Pushing borders
WPOI-II	Finger like growth
WPOI-III	Large separate islands,>15 cells per island
WPOI-IV	Small tumor islands,15 cells or fewer,per island.
WPOI-V	Tumor satellites, =>1mm from the main tumor or next closest satellite.

Table 1:(I-III: cohesive pattern, IV-V: invasive pattern)

Table 2 .Frequency table for PNI

GROUP - PNI	Frequency	Percentage
<b>GROUP A- Negative</b>	42	63.6
<b>GROUP B- Positive</b>	24	36.4

Table 2: (PNI- perineural invasion)

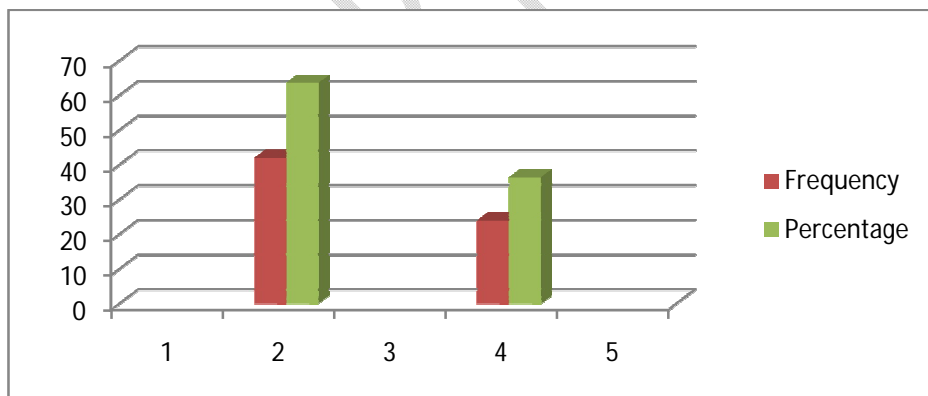


Fig 1. Frequency table for PNI

Table 3. Frequency table for WPOI

PATTERN	FREQUENCY	PERCENTAGE
1-3	28	42.4
4-5	38	57.6

Table 3: (Pattern I-III: Cohesive, Pattern IV-V: Invasive)

Table 4 Frequency for pT:

Staging	Frequency
pT1	43.9%
pT2	19.7%
pT3	18.2%
pT4	18.2%

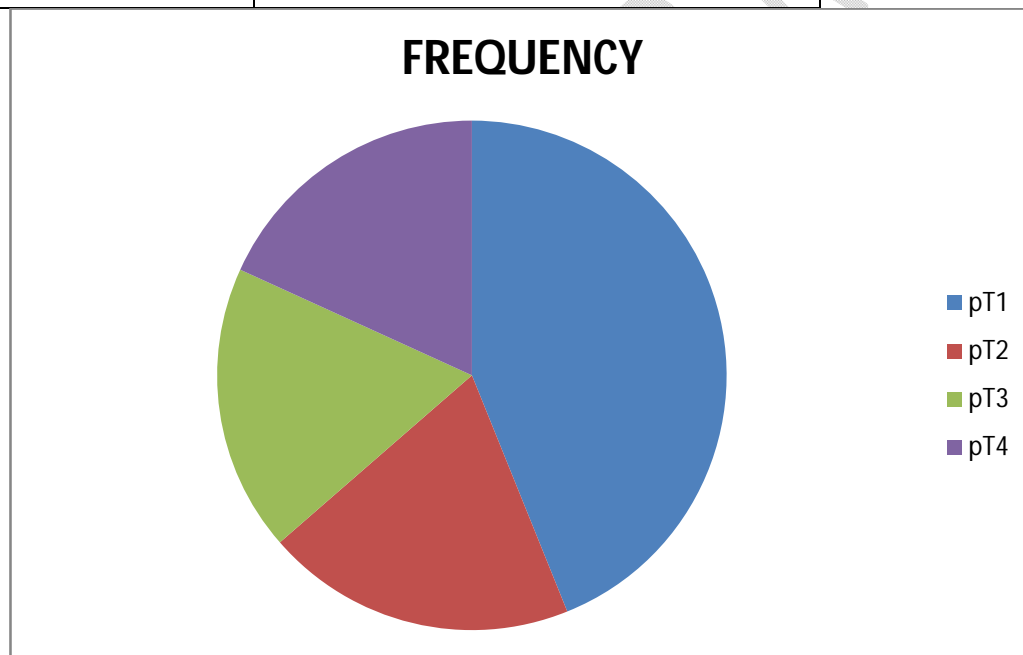


Fig 2. *Frequency for pT)*

Table 5. Chi-square table for PNI with WPOI:

PNI		WPOI		Chi-square value	p value
		1-4	5		
		Negative	25(37.9%)	17(25.8%)	13.826
Positive	3(4.5%)	21(31.8%)			

**Conclusion:** There is a significant association between PNI and WPOI. (p value<0.0001)

Table 6. Chi-square table for PNI with pT:

PNI		pT				Chi-square value	p value
		pT1	pT2	pT3	pT4		
Negative	10(15.2%)	16(24.2%)	10(15.2%)	6(9.1%)	6.639	0.084	
Positive	2(3.0%)	13(19.7%)	2(3.0%)	7(10.6%)			

**Conclusion:** There is no significant association between PNI and pT

Table 7. Chi-square table for WPOI with LN:

WPOI		LN		Chi-square value	p value
		-ve	+ve		
1-4	22(37.3%)	3(5.1%)	5.017	0.025	
5	21(35.6%)	13(22.0%)			

Table 7: (There is a significant association between WPOI IV-V and LN +ve). **Conclusion:** There is a significant association between WPOI and LN.

UNDER PEER REVIEW