

Original Research Article

Three Dimensional Tomographic Ultrasound and Doppler Studies in Morbidly Adherent Placenta

Abstract

Background: Morbidly adherent placenta (MAP) describes a spectrum of disorders including adherence of all or part of placenta to uterine wall. The aim of this study was to evaluate the potential role of the 3D Tomographic Ultrasound Imaging (TUI) and Doppler studies in diagnosis of morbidly adherent placenta.

Methods: This prospective study was conducted on 50 female patients, aged from 20 to 40, who were pregnant with history of one or more caesarean section deliveries or hysterotomies, diagnosed by 2D ultrasound as placenta previa with its lower edge covering the scar of previous caesarean section (mMajor and minor anterior), with antepartum haemorrhage, and gestational age from 28 weeks to full term. The whole placenta was scanned in a systematic fashion using both 2D grayscale and 3D power Doppler ultrasound then displayed by 3D TUI

Results: By 2D grayscale ultrasound, the obliteration of retroplacental hypoechoic area was found in 48% of patients with sensitivity 88.89% and accuracy 94%. Placental lacunae were found in 54% of patients with sensitivity 100% and accuracy 100%. Myometrial thinning was found in 40% of patients with sensitivity 74.07% and accuracy 86% and interruption of bladder uterine interface was found in 28% of patients with sensitivity 51.85% and accuracy 74%. By 2D colour Doppler study, the vascular gap was found in 40% of patients with sensitivity 74.07% and accuracy 86%. By 3D power Doppler study, vascularity was found in 26% of patients with sensitivity 96.3% and accuracy 96% and bridging vessel was found in

26% of patients with sensitivity 48.15% and accuracy 72%. Tomographic ultrasound image could predict MAP presence with 96.3% sensitivity and accuracy reach 98%.

Conclusions: The 3D TUI technique facilitates the evaluation of the myometrial thickness and the depth of placental invasion due to much better differentiation between various tissues compared to the conventional 2D. The 3D TUI is a useful adjunctive tool to the 3D power Doppler or color Doppler to refine the diagnosis of MAP.

Keywords: Three-dimensional tomographic ultrasound, doppler ultrasound, morbidly adherent placenta.

UNDER PEER REVIEW

Introduction:

Placenta accreta occurs when placental trophoblasts infiltrate the endometrium beyond the Nitabuch's layer of decidua basalis, whereas placenta increta and placenta percreta occur when placental trophoblasts enter the myometrium and serosa, respectively [1-4]. In general, morbid adherent placenta (MAP) is related with excessive blood loss, bladder damage, and hysterectomies. MAP risk factors include a history of caesarean birth, placenta previa, and injury to the Nitabuch's layer of the decidua basalis due to intrauterine infection or scarring. The frequency of MAP increases along with the rise of caesarean delivery [3, 5-7]. Over the past 50 years, the prevalence of MAP has risen dramatically. The incidence of MAP ranges from 3.3% in pregnant women with no history of caesarean delivery and placenta previa to 40% in pregnant women with two caesarean deliveries and placenta previa [2, 8, 9]. If MAP was identified or suspected before to birth, the optimal period for planned delivery is between 34 and 35 weeks, after a course of corticosteroids and multidisciplinary team care [4, 10, 11]. A correct diagnosis of MAP is critical for preparing both the patient and health care professionals for potential delivery problems [12-16]. For MAP detection, 3D ultrasound and 3D power Doppler have been introduced. During pregnancy, conventional two-dimensional (2D) ultrasonography has been routinely utilised to evaluate the placenta.

This 2D ultrasound evaluation covers an assessment of the placenta's morphology, anatomy, position, implantation, abnormality, size, color/power, and pulsed Doppler sonography. The advent of three-dimensional (3D) ultrasonography would permit innovative placenta evaluations, such as volumetric and surface-rendered imaging. With recent advancements in 3D power Doppler (3DPD) ultrasonography and quantitative 3DPD histogram analysis, quantitative and qualitative analyses of placental vascularization and blood flow are now possible [17]. Obliteration of a clear space between the uterus and placenta, visualisation of the placental lacunae (irregular vascular spaces), moth-eaten appearance of the placenta,

interruption of the posterior uterine serosa-bladder interface, and exophytic mass invading the bladder [18] are suggestive of MAP. Tomographic ultrasound imaging improves the accuracy of focal MAP diagnosis over 2D grey scale ultrasound by providing several thin slices of the required inspected region, hence facilitating the detection of focal areas of invasive diseases. Therefore, TUI has demonstrated its added utility to 2D grey scale in predicting invasive placental diseases [18].

This study's objective was to assess the potential relevance of 3D Tomographic Ultrasound Imaging (TUI) and Doppler investigations in the identification of morbidly adhered placenta.

Patients and Methods:

This prospective study was conducted on 50 female patients, aged from 20 to 40, who were pregnant with history of one or more caesarean section deliveries or hysterotomies, diagnosed by 2D ultrasound as placenta previa with its lower edge covering the scar of previous caesarean section (major and minor anterior), with antepartum haemorrhage, and gestational age from 28w to full term. Patients were selected from the outpatient and inpatient obstetric department in Tanta university hospital in collaboration with Radiology Department at Tanta University Hospital during the period from March 2020 till March 2021. After approval from institutional ethical committee, an informed consent was taken from each subject. Written informed consent was obtained from all patients.

Patients refused to participate in the study were excluded.

All the patients were subjected to the following:

- Full history taking.

- Ultrasound examination:

Ultrasound and colour Doppler examinations were done by using abdominal and vaginal probes, abdominal ultrasound examination was difficult in one patient with preeclampsia and significant abdominal wall edoema. The patient was positioned in the supine position,

and an abdominal ultrasound examination was performed with the bladder partially full, allowing for excellent imaging of the uterine serosa and bladder wall. Routine foetal viability testing was performed. The whole placenta was systematically scanned using both 2D grayscale and 3D power Doppler ultrasonography, followed by 3D TUI, in order to confirm whether patients suspected of having advanced invasive placentation indeed had it. Doppler velocimetry was done on both sides of the uterine artery to assess the mean resistive index (RI) and pulsatility index (PI).

2D ultrasound grayscale scan: Total and marginal placenta previa were diagnosed when the internal cervical os was totally covered by the placenta or when the leading edge of the placenta was less than 2 cm from the internal os, but not completely covered. Results indicating a severely adhered placenta. Destruction of the gap between the uterus and placenta. Visualization of placental lacunae (irregular vascular gaps), placenta with a moth-eaten look. Interruption of the posterior uterine serosa-bladder contact and invasion of the bladder by an exophytic tumour.

2D Colour Doppler ultrasound scan:

Findings suggesting morbidly adherent placenta: Diffuse or focal lacunar flow, vascular lakes with turbulent flow, Hypervascularity of serosa-bladder interface and markedly dilated vessels over peripheral sub placental zone.

3D power Doppler:

The 3D power Doppler was targeted to analyse and define the vasculature of the lower uterine segment and placenta. In general, two perspectives of 3D power Doppler are analysed: the lateral view to examine the intra-placental vasculature and the basal view to investigate the serosa-bladder interface. At least one of the following 3D power Doppler results was indicative of MAP: Disruption of the retro-placental sonolucent zone and/or aberrant placental lacunae in lateral view, as well as foetal growth restriction. Numerous

vessels invading the uterine serosa-bladder interface and/or congested vessels across the peripheral sub-placental zone, as seen from the bottom up.

During 3D TUI, the 3D volume transducer was physically and methodically moved across the designated area of interest (ROI) to gather volume data in three planes (sagittal, coronal, and axial). The volume data were stored on the hard disc of the computer. TUI permitted the simultaneous display of numerous parallel cuts per volume, up to 24 parallel cuts (slices) from a volume that were preselected. Slices may be created from either the initial or a different rebuilt ROI. In addition, vasculature was acquired in power mode inside a specific ROI. Comparable to 2D grey scale, 3D TUI findings were indicative of MAP, however TUI represented successive parts of the scanned ROI, similar to MRI technology. ROI scans may be rotated and slices can be altered to achieve the optimal plane for analysis.

Uterine artery Doppler: The uterine artery Doppler measurements were obtained using a multi frequency volumetric transabdominal transducer at their crossing with the external iliac artery on both sides of the uterus, and colour Doppler images were generated. Using Doppler imaging, the uterine artery was identified. When three consecutive uniform waveforms were recorded, left and right uterine artery Doppler measurements (RI & PI) were done. Just distal to the crossing with the iliac artery, before the uterine artery divides into arcuate arteries, measurements were collected. For measurements of PI & RI, a transvaginal probe was utilised, with the transducer positioned in the vaginal fornix. Typically, the uterine artery was located in the paracervical region at the level of the internal cervical os, while a characteristic pattern of low resistance blood flow was audible and visible. The PI was automatically computed by the computer as the difference between the peak systolic and minimum diastolic velocities during the cardiac cycle divided by the mean velocity.

Statistical calculations

SPSS (Statistical Package for the Social Sciences) version 20 for Windows® was used to encode, process, and analyse the obtained data (IBM SPSS Inc, Chicago, IL, USA). Frequencies and relative percentages were used to depict qualitative data. As shown, the Chi square test (2) was employed to quantify the difference between qualitative variables. The quantitative data were presented as mean SD and range. Student's t-test was utilised to compare two distinct sets of normally distributed variables (parametric data). The diagnostic value of quantitative variables in predicting categorical outcomes was computed.

Probability that the test result will be positive when the illness is present (true positive rate, expressed as a percentage). Specificity: - Probability of negative test findings when the illness is absent (true negative rate, expressed as a percentage). PPV stands for Positive Predictive Value (probability that the disease is present when the test is positive). NPV stands for Negative Predictive Value (probability that the disease is present when the test is negative). Accuracy: - the proportion of true positives to true negatives across all patients.

Probability (P-value): P-values 0.05 were deemed significant, P-values 0.05 were deemed inconsequential, and P-values 0.01 were deemed extremely significant.

Results:

Regarding the final outcome of the studied females depending on operative data (in all females) and histopathological findings (in 27 females) which were accepted as standard reference, MAP was present in 27 (54%) of pregnant females and classified into increta in 11 (40.74%) pregnant females, percreta in 12 (44.44%) pregnant females, and accreta in 4 (14.81%) pregnant females as shown in (Table 1).

Table 1: Presence and subtypes Morbidly adherent placenta in the studied pregnant females (n =50) according to the standard reference.

		N %
MAP Presence	No	23 (46%)
	Yes	27 (54%)
Subtypes of MAP	Increta	11 (40.74 %)
	Percreta	12 (44.44%)
	Accreta	4 (14.81%)

MAP: Morbidly adherent placenta

By Chi-square and student's t-tests, there were insignificant correlations between demographics of studied pregnant females (age and age groups) and presence of MAP The

gestational age studied females ranged from 34 to 38 weeks with a mean of 36.22 ± 1.46 . Thirty-seven of the studied females (74%) complained from pain and 31 of them (62%) complained from bleeding. By student's t-test, there was an insignificant correlation between PI of both uterine arteries and MAP Presence (Table 2).

Table 2: Correlation between Age, Gestational age and PI of both uterine arteries of the studied pregnant females and MAP presence (n =50).

	MAP Presence						T-Test		
	No			Yes			t	P-value	
Age	29.478	±	3.788	29.630	±	4.542	-0.127	0.900	
T-Test							t	P-value	
Gestational age	Range	34	-	38	34	-	38	-1.182	0.243
	Mean ±SD	35.957	±	1.461	36.444	±	1.450		
	Mean ±SD	31.452	±	3.826	32.907	±	3.665		

MAP: Morbidly adherent placenta. t: Student t-test.

P- value: Probability value; statistically significant at $p \leq 0.05$.

By Chi-square, there were insignificant correlations between number of caesarian sections and hysterotomies of studied pregnant females and presence of MAP. By Chi-square test, there was significant correlations between subtypes of placenta previa, and presence of MAP ($p < 0.001$). By Chi-square test, there was significant correlations between occurrence of hysterectomy and presence of MAP ($p < 0.001$), and insignificant correlations between the outcomes (antepartum blood loss, blood transfusion, bladder injuries, ICU admission, and preterm delivery) and MAP Presence (Table 3).

Table 3: Correlation between number of caesarean sections, hysterotomies, subtypes of placenta previa and outcomes of the studied pregnant females and MAP presence (n =50).

Chi-Square	MAP Presence				Chi-square		
	No		Yes		X ²	P-value	
Previous CS	No	3 (13.04%)		0 (0.00%)		4.736	0.315
	One	2 (8.70 %)		2 (7.41%)			
	Two	5 (21.74 %)		8 (29.63%)			
	Three	9 (39.13 %)		9 (33.33%)			
	Four	4 (17.39 %)		8 (29.63 %)			
Previous Hysterotomies	No	18 (78.26 %)		24 (88.89 %)		1.044	0.307
	Yes	5 (21.74%)		3 (11.11%)			
Subtypes of placenta previa	MAP Presence				Chi-Square		
	No		Yes		X ²	P-value	
	N	%	N	%			
Incomplete centralis anterior	1 (4.35 %)		0 (0.00%)		24.174	<0.001*	
Complete centralis anterior	7 (30.43%)		26 (96.30%)				
Complete centralis posterior	9 (39.13%)		1 (3.70%)				
Marginalis	6 (26.09%)		0 (0.00%)				
Outcome	MAP Presence				Chi-Square		

		No		Yes		X ²	P-value
		N	%	N	%		
Antepartum blood loss	No	9	(39.13%)	12	(44.44%)	0.144	0.704
	Yes	14	(60.87%)	15	(55.56%)		
Blood transfusion	No	11	(47.83%)	15	(55.56%)	0.297	0.586
	Yes	12	(52.17%)	12	(44.44%)		
Mortality	No	23	(100%)	27	(100%)	-	-
	Yes	0	(0.00%)	0	(0.00%)		
Hysterectomy	No	23	(100%)	0	(0.00%)	50.000	<0.001*
	Yes	0	(0.00%)	27	(100%)		
Bladder injuries	No	15	(65.22%)	22	(81.48%)	1.708	0.191
	Yes	8	(34.78%)	5	(18.52%)		
Ureteric injuries	No	23	(100%)	27	(100%)	-	-
	Yes	0	(0.00%)	0	(0.00%)		
ICU admission	No	15	(65.22%)	21	(77.78%)	0.972	0.324
	Yes	8	(34.78%)	6	(22.22%)		
Neonatal ICU	No	23	(100%)	27	(100%)	-	-
	Yes	0	(0.00%)	0	(0.00%)		
Preterm delivery	No	7	(30.43%)	13	(48.15%)	1.624	0.203
	Yes	16	(69.57%)	14	(51.85%)		

X²: chi-square test. P- value: Probability value.

*Statistically significant as p <0.05

Chi-square test detected significant correlation between 2D US criteria of MAP and presence of MAP. The Obliteration of retro placental ypoechoic area could predict MAP presence with 88.89% sensitivity, 100% specificity, 100% PPV, 88.46% NPV, and 94% accuracy (p <0.001). The placental lacunae could predict MAP presence with 100% sensitivity, 100% specificity, 100% PPV, 100% NPV, and 100% accuracy (p <0.001). Myometrial thinning could predict MAP presence with 74.07% sensitivity, 100% specificity, 100% PPV, 76.67% NPV, and 86% accuracy (p <0.001). Interruption of bladder uterine interface could predict MAP presence with 51.85% sensitivity, 100% specificity, 100% PPV, 63.89% NPV, and 74% accuracy (p <0.001). There was also significant correlation between 2D Doppler US findings and presence of MAP. The vascular gap by 2D can predict MAP Presence with 74.07% sensitivity, 100% specificity, 100% PPV, 76.67% NPV, and 86% accuracy (p <0.001). The vascularity by 3D can predict MAP Presence with 100% sensitivity, 100% specificity, 100% PPV, 100% NPV, and 100% accuracy (p <0.001). Bridging vessels by 3D can predict MAP Presence with 48.15% sensitivity, 100% specificity, 100% PPV, 62.16% NPV, and 72% accuracy (p <0.001) (Table 4).

Table 4: Correlation between 2D US and doppler criteria with MAP presence and their accuracy (n =50).

2D US criteria		MAP Presence		Chi-Square		Sensitivity	Specificity	PPV	NPV	Accuracy
		No	Yes	X ²	P-value					
		N	N							
Obliteration	No	23	3 (11.11)	39.	<0.00	88.89	100.0	100.0	88.46	94%

of retro placental hypoechoic area		(100%)	(%)	316	1*					
	Yes	0 (0.00%)	24 (88.89%)							
Placental lacunae	No	23 (100%)	0 (0.00%)	50.000	<0.001*	100.0	100.0	100.0	100.0	100%
	Yes	0 (0.00%)	27 (100%)							
Myometrial thinning	No	23 (100%)	7 (25.93%)	28.395	<0.001*	74.07	100.0	100.0	76.67	86%
	Yes	0 (0.00%)	20 (74.07%)							
Interruption of b ladder uterine interface	No	23 (100%)	13 (48.15%)	16.564	<0.001*	51.85	100.0	100.0	63.89	74%
	Yes	0 (0.00%)	14 (51.85%)							
Doppler signs		MAP Presence		Chi-Square		Sensitivity	Specificity	PPV	NPV	Accuracy
		No	Yes	X2	P-value					
Vascular gap by 2D	No	20 (89.96%)	7 (25.93%)	28.395	<0.001*	74.07	86.96	100.0	76.67	86%
	Yes	3 (69%)	20 (74.07%)							
Vascularity by 3D	No	22 (95.65%)	1 (4.35%)	50.000	<0.001*	96.3	95.65	96.3	95.7	96%
	Yes	1 (3.7%)	26 (96.29%)							
Bridging vessels by 3D	No	23 (100%)	14 (51.85%)	14.965	<0.001*	48.15	100.0	100.0	62.16	72%
	Yes	0 (0.00%)	13 (48.15%)							
Tomographic ultrasound image	No	23 (100%)	1 (3.70%)	45.22	<0.001*	96.3	100.0	100.0	95.8	98%
	Yes	0 (0.00%)	26 (96.29%)							

2D: Two-dimensional. 3D: Three-dimensional. X²: chi-square test, P- value: Probability value. PPV: Positive predictive value, NPV: Negative predictive value, MAP: Morbidly adherent placenta. *Statistically significant as p < 0.05

By Chi-square test, there was significant correlation between TUI findings and presence of MAP (p < 0.001). And there was significant correlations between operative findings and presence of MAP as shown at (Table 5).

Table 5: Correlation between outcomes diagnosed by TUI and operative findings and MAP (n =50).

Diagnosis by TUI	MAP Presence		Chi-Square	
	No	Yes	X ²	P-value
	N %	N %		
Focal increta	0 (0%)	8 (29.63%)	50.000	<0.001*
Focal percreta	0 (0%)	5 (18.52%)		
Focal accreta	0 (0%)	2 (7.41%)		
Increta	0 (0%)	3 (11.11%)		
Percreta	0 (0%)	7 (25.93%)		

Accreta	0 (0%)	2 (7.41%)		
Placenta previa with no features of invasive placentation	23 (100%)	0 (0%)		
Operative findings	MAP Presence		Chi-Square	
	No	Yes	X²	P-value
N %	N %			
Focal increta	0 (0%)	8 (29.63%)	50.000	<0.001*
Focal percreta	0 (0%)	5 (18.52%)		
Focal accreta	0 (0%)	2 (7.41%)		
Increta	0 (0%)	3 (11.11%)		
Percreta	0 (0%)	7 (25.93%)		
Accreta	0 (0%)	2 (7.41%)		
Placenta previa with no features of invasive placentation	23 (100%)	0 (0%)		
Total	23 (100%)	27 (100%)		

*Statistically significant as p <0.05

TUI: Tomographic ultrasound imaging. **X²:** chi-square test.

P- value: Probability value. *Statistically significant as p <0.05.

By student's t-test, there was significant correlation between estimated blood loss and presence of MAP (p =0.013). And there was an insignificant correlation between PI of both uterine arteries and MAP Presence as shown in (Table 6).

Table 6: Correlation between estimated blood loss and PI of both uterine arteries MAP (n =50).

	MAP Presence		T-Test	
	No	Yes	t	P-value
Outcome Estimated blood loss	1414.286 ± 560.024	2020.000 ± 663.540	-2.647	0.013*
	MAP Presence		T-Test	
	No	Yes	t	P-value
PI right UT artery	0.758 ± 0.353	0.851 ± 0.300	-1.006	0.319
PI left UT artery	0.638 ± 0.434	0.812 ± 0.359	-1.547	0.128

PI: Pulsatility index, **UT:** Uterine. **t:** student's t-test.

P- value: Probability value; statistically significant as p <0.05.

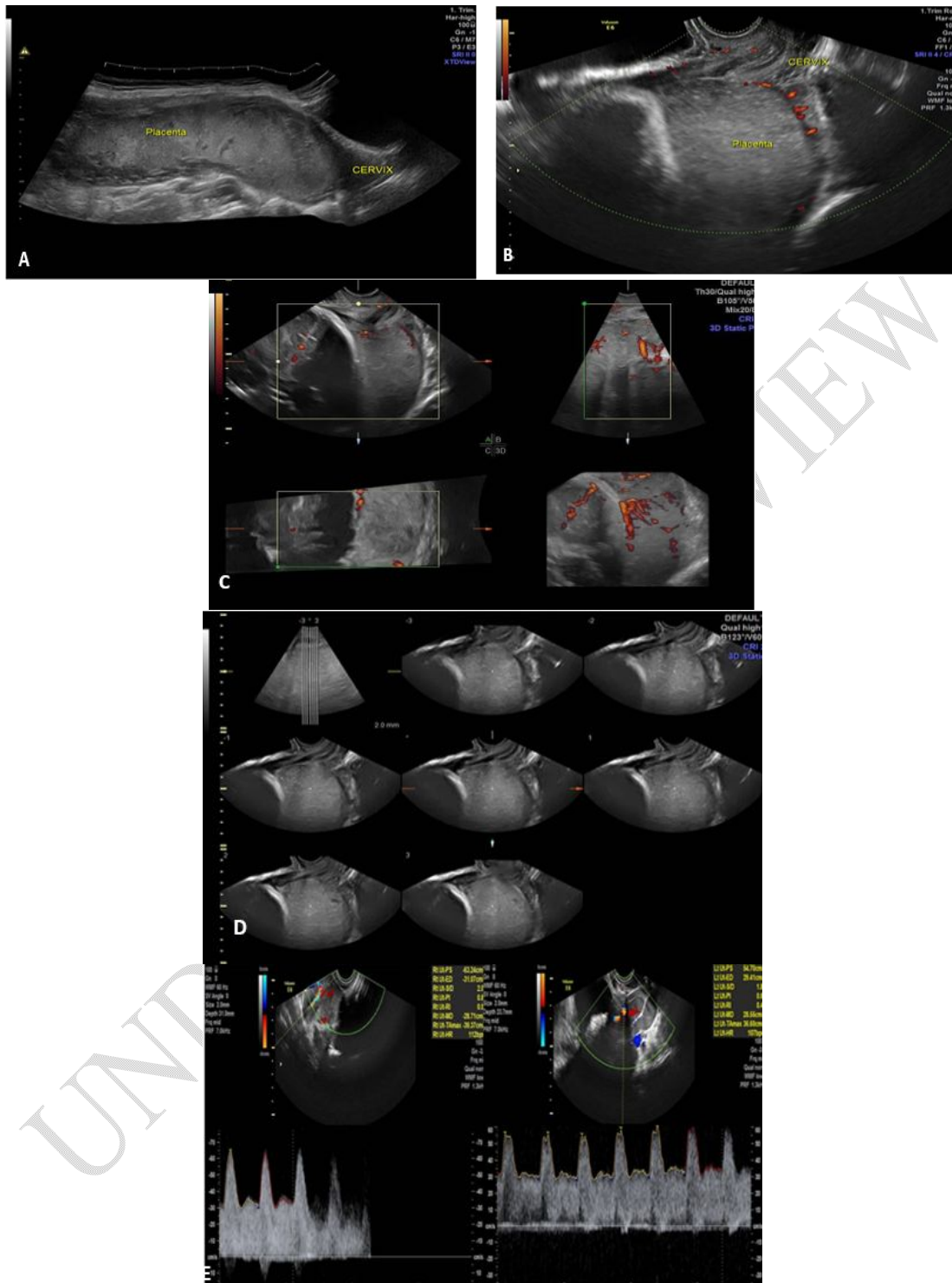


Figure 1): (A-E images): (A) 2D US panoramic view of placenta previa overlapping the internal cervical os with preserved Sonolucent retro placental area (placenta previa complete centralis). **(B) Power Doppler image** showing normal vessels between placenta and uterine wall with no evidence of placental lacunae. **(C) 3DPD image** showing no increased vascularity or placental lacunae. **(D) 3D TUI cuts** showing preserved retroplacental hypoechoic area, no placental lacunae confirming diagnosis of placenta previa complete centralis. **(E) Uterine artery Doppler image** showing measurements of PI & RI of right and left uterine arteries (0.82,0.51),(0.69,0.48) respectively.

Discussion

Before birth, ultrasonography might be a helpful tool for assessing placental invasion of the myometrium. An extended portion of the lower uterine segment had a thickness of just 1 mm, indicating extensive placenta increta/percreta invasion of the myometrium and serosal uterine layer. Tomographic ultrasound imaging (TUI), a new application of 3D ultrasound involving the presentation of a narrow slice from an obtained volume, best revealed this. This technique's primary objective is to reduce ultrasonic artefacts [20]. Consequently, the purpose of our study was to assess the possible usefulness of the 3D tomographic ultrasound imaging (TUI) and Doppler tests in the identification of morbidly adherent placenta.

In prenatal placenta accrete evaluation, 2D grayscale ultrasonography is the preferred approach. In this study, the best 2D gray-scale ultrasound parameters for detecting difficult placental separation and significant intraoperative blood loss were abnormal placental lacunae (100 % sensitivity), interruption of uterine serosa in cases of placenta percreta only (100 % specificity & 100 % PPV), and thinning myometrium (76.67 % NPV). In addition, the best 2D gray-scale ultrasonography criteria for detecting emergency hysterectomy in the participants were the obliteration of the Sonolucent retro placental region (88.89% sensitivity). According to the study by Moniem et al. [18], the best 2D grayscale ultrasonography parameter for detecting difficult placental separation and significant intraoperative blood loss was the absence of the retroplacental sonolucent zone (74.2% NPV). In addition, the best 2-dimensional gray-scale ultrasonography criteria for detecting emergency hysterectomy in patients were disruption of the hyperechoic uterine serosa-bladder interface (81.8% sensitivity) and invasion of the bladder by an exophytic mass (94.9% specificity, 66.7% PPV, and 84.9% NPV).

The hypoechoic retroplacental space symbolises the decidua basalis, and its absence is thought to indicate placenta accreta. There have been reports of its utility, with a claimed

detection rate of 93%; nevertheless, the false positive rate may be unacceptable, ranging from 21% to 50%, since this result can be observed in otherwise normal placenta [4, 20, 30]. Comstock et al.[31] discovered that the lack of the gap between the placenta and the myometrium is not a diagnostic indicator for MAP, as the space may be missing regularly without MAP. While Wong et al.[32] determined that the disappearance of the placental-uterine interface and the presence of aberrant arteries crossing this interface were the most precise diagnostic criteria for MAP utilising a 2D gray-scale ultrasonography image. The accuracy of the loss of retroplacental hypoechoic region in diagnosing placenta accreta was determined to be 94%.

In placenta accreta, the interface between the echogenic uterine serosa and the bladder wall becomes uneven, thicker, or interrupted; other findings include increased vascularity, varicosities, and placental protrusion into the bladder. It has been shown that these findings have a high sensitivity and specificity for MAP [31]. Rac et al.[33] discovered in 2015 that the existence of lacunar spaces had the strongest positive predictive value for the presence of accreta, with the chance of placenta accreta rising with the amount of lacunar gaps. When there are four or more lacunar gaps, the probability of a morbidly adherent placenta is 100 percent, and the false-positive rate is negligible. Eighty to ninety percent sensitivity has been found for this feature in the diagnosis of placenta accreta. Others have not only reported the occurrence of such placental lacunae, but also graded them. In 2014, researchers discovered that a higher grade of lacunae was substantially related with the requirement for huge blood transfusions and a higher risk of caesarean hysterectomy [34]. In 2014, Bowman et al. [35] reported that a true positive (the ultra-sonographer detecting an accreta when it was there) was enhanced in the presence of lacunae, loss of retro placental myometrial zone space, and colour Doppler abnormalities. The non-anterior position of a placenta accreta may make ultrasonography identification more challenging [35, 36].

In our study, the best 2D Doppler parameters for detecting difficult placental separation and significant intraoperative blood loss in the subjects were crowded vessels over the peripheral sub-placental zone (sensitivity: 74%) and bridging vessels over the peripheral sub-placental zone (NPV: 62,16%). In addition, placental hyper vascularity was the best 3D power Doppler measure for detecting emergency hysterectomy in the participants (96.3% sensitivity and 95.65% specificity). In all patients with placenta percreta, we discovered that bridging vessels identified by 3D Doppler and uterine bladder interface interruption detected by grey scale US were present, thereby representing the most specific and sensitive indicators in the diagnosis of MAP, particularly percretas.

The sensitivity of individual studies for identifying morbidly adherent placentation ranged from 61% to 100%, with a pooled sensitivity of 91%, according to a recent meta-analysis by D'Antonio et al. [37] comprising twenty-three research and more than 3,700 patients. They discovered that aberrant vasculature on colour Doppler ultrasonography provided the best combination of sensitivity and specificity, whereas anomalies at the uterine-bladder interface had the highest specificity for predicting accreta [37]. Chou et al. discovered that the colour Doppler had a sensitivity of 82.4% (14/17) with a specificity of 96.8% (61/63) and positive and negative predictive values of 95.3% (61/64) and 87.5% (14/16), respectively. Chou et al. [38] reported a substantial correlation between bladder invasion in MAP and 3D power Doppler results, namely hyper vascularization of the uterine serosa-bladder interface and a huge rosette of varicosities in the region of the bladder base. Shih et al. [39] demonstrated that 3D power Doppler raised the placenta accreta detection rate to 76% compared to grayscale (51%) and colour Doppler (47%) ultrasonography. It permits specific study of the angioarchitecture of the placenta [39] and may be effective as a companion approach to grayscale ultrasonography for the prenatal diagnosis or exclusion of placenta accreta.

The true benefit of uterine artery Doppler screening lies in the fact that a mean uterine artery PI accurately predicts the majority of women who will have severe preterm effects of poor placentation. In problematic pregnancies, the PI of the uterine artery was more than 1.45 than in those with a normal result. In addition, its predictive sensitivity for severe unfavourable outcomes was improved. This was not applicable to the current investigation, as an increase in uterine artery PI had no connection with CS hysterectomy and blood transfusion [40]. Cho et al. [41] observed that the mean uterine artery PI was considerably lower in the group with placenta accreta compared to the group with placenta previa. The sensitivity of TUI in demonstrating invasive placentation problems was 96.3% (P 0.001), indicating that it has a strong connection with the diagnosis of MAP.

Tomographic ultrasound image technique increased the accuracy of diagnosing focal MAP compared to 2D grey scale ultrasound because it displays the entire myometrial thickness by displaying multiple thin slices of the required examined area, thereby facilitating the detection of focal areas of invasive diseases. Therefore, TUI has demonstrated its efficacy in addition to 2D grey scale in predicting invasive placental diseases.

According to Henrich and Stupin.,[42] the transabdominal and transvaginal conventional 2D scan frequently encounters challenges due to penetration and insonation angle limitations. With greater picture quality, the 3D TUI approach improves the measurement of myometrial thickness and the level of placental invasion compared to the standard 2D scan due to significantly better tissue differentiation. After 2D grayscale ultrasound and tomographic ultrasound image_(TUI) inspection and comparison with surgeries and histological findings, the number of placenta accrete was discovered to be 4 (14.81%), increta 11 (40.74%), and percreta 12 (44.44%). According to several research in this field, the majority of identified instances of MAP are accreta, increta, and percreta, respectively. For example, in the study by Millar et al. [43], 75% of cases were accreta, 18% increta, and 7% percreta. While just a

fraction of instances in our research had accreta, this may be attributed to the fact that we are a tertiary facility.

In the current study, no maternal fatalities occurred. This might be because the sample sizes were insufficient to identify the true maternal death rate. It may also be attributed to preoperatively accurate patient diagnosis, adequate blood and blood products for transfusion, an experienced surgical team, and the availability of resources, all of which contributed to improved mother and foetal outcomes and reduced maternal and foetal mortality. In up to 7% of instances, maternal death has been observed in the research in question. This may be owing to the fact that the majority of cases involved percretas and incretas [44]; bladder injuries were noted in 13 instances, and 14 patients were referred to ICU. In a similar research, it was shown that pregnancies complicated with placenta accreta were related with greater occurrences of bladder damage, ureteral injury, and intensive care unit (ICU) admission, resulting in a longer hospital stay for the mother [2].

The primary drawback of the study was the difficulties of histopathological follow-up following caesarean section.

Conclusions:

Ultrasound is the preferred method for prenatal evaluation of placenta accreta. The 3D TUI approach allows the measurement of myometrial thickness and the degree of placental invasion as a result of superior tissue differentiation in comparison to the classic 2D technique. In order to refine the diagnosis of MAP, the 3D TUI is a valuable addition to the 3D power Doppler or colour Doppler. Therefore, we advocate the addition of 3D TUI to standard 2D grayscale ultrasonography and Doppler examinations in high-risk pregnancies for MAP. In addition, this approach should be utilised regularly in future study on placental features in order to gather more specific data that will aid in the identification of morbidly adherent placenta.

References:

1. Usta IM, Hobeika EM, Musa AA, Gabriel GE, Nassar AH. Placenta previa-accreta: risk factors and complications. *Am J Obstet Gynecol.* 2005;193:1045-9.
2. Silver RM, Landon MB, Rouse DJ, Leveno KJ, Spong CY, Thom EA, et al. Maternal morbidity associated with multiple repeat cesarean deliveries. *Obstet Gynecol.* 2006;107:1226-32.
3. ACOG committee opinion. Placenta accreta. Number 266, January 2002. American College of Obstetricians and Gynecologists. *Int J Gynaecol Obstet.* 2002;77:77-8.
4. Abuhamad A. Morbidly adherent placenta. *Semin Perinatol.* 2013;37:359-64.
5. Khong TY. The pathology of placenta accreta, a worldwide epidemic. *J Clin Pathol.* 2008;61:1243-6.
6. Getahun D, Oyelese Y, Salihu HM, Ananth CV. Previous cesarean delivery and risks of placenta previa and placental abruption. *Obstet Gynecol.* 2006;107:771-8.
7. Gielchinsky Y, Rojansky N, Fasouliotis SJ, Ezra Y. Placenta accreta--summary of 10 years: a survey of 310 cases. *Placenta.* 2002;23:210-4.
8. Wortman AC, Alexander JM. Placenta accreta, increta, and percreta. *Obstet Gynecol Clin North Am.* 2013;40:137-54.
9. Rao KP, Belogolovkin V, Yankowitz J, Spinnato JA, 2nd. Abnormal placentation: evidence-based diagnosis and management of placenta previa, placenta accreta, and vasa previa. *Obstet Gynecol Surv.* 2012;67:503-19.
10. Oyelese Y, Smulian JC. Placenta previa, placenta accreta, and vasa previa. *Obstet Gynecol.* 2006;107:927-41.
11. Eshkoli T, Weintraub AY, Sergienko R, Sheiner E. Placenta accreta: risk factors, perinatal outcomes, and consequences for subsequent births. *Am J Obstet Gynecol.* 2013;208:219.e1-7.

12. Chou MM, Ho ES, Lee YH. Prenatal diagnosis of placenta previa accreta by transabdominal color Doppler ultrasound. *Ultrasound Obstet Gynecol.* 2000;15:28-35.
13. Warshak CR, Eskander R, Hull AD, Scioscia AL, Mattrey RF, Benirschke K, et al. Accuracy of ultrasonography and magnetic resonance imaging in the diagnosis of placenta accreta. *Obstet Gynecol.* 2006;108:573-81.
14. Zhang L, Li P, He GL, Liu XH, Yang TZ, Luo H, et al. [Value of prenatal diagnosis of placenta previa with placenta increta by transabdominal color Doppler ultrasound]. *Zhonghua Fu Chan Ke Za Zhi.* 2006;41:799-802.
15. Dwyer BK, Belogolovkin V, Tran L, Rao A, Carroll I, Barth R, et al. Prenatal diagnosis of placenta accreta: sonography or magnetic resonance imaging? *J Ultrasound Med.* 2008;27:1275-81.
16. D'Antonio F, Bhide A. Ultrasound in placental disorders. *Best Pract Res Clin Obstet Gynaecol.* 2014;28:429-42.
17. Noguchi J, Hata K, Tanaka H, Hata T. Placental vascular sonobiopsy using three-dimensional power Doppler ultrasound in normal and growth restricted fetuses. *Placenta.* 2009;30:391-7.
18. Abdel Moniem AM, Ibrahim A, Akl SA, Aboul-Enen L, Abdelazim IA. Accuracy of three-dimensional multislice view Doppler in diagnosis of morbid adherent placenta. *J Turk Ger Gynecol Assoc.* 2015;16:126-36.
19. Mohamed Zakria AE-M, Abd El-Kader El-Tabakh A, Ahmed Mahmoud Amer M. Uterine artery doppler and placental morphological features as predictors of peripartum complications in placenta previa and placenta previaaccreta. *Al-Azhar Medical Journal.* 2019;48:455-66.
20. Goh WA, Zalud I. Placenta accreta: diagnosis, management and the molecular biology of the morbidly adherent placenta. *J Matern Fetal Neonatal Med.* 2016;29:1795-800.

21. Matalliotakis M, Niraki E, Patelarou A. Association of Placenta Previa with a History of Previous Cesarean Deliveries and Indications for a Possible Role of a Genetic Component. *Balkan J Med Genet.* 2017;20:5-10.
22. Guarino A, Di Benedetto L, Assorgi C, Rocca A, Caserta D. Conservative and timely treatment in retained products of conception: a case report of placenta accreta retention. *Int J Clin Exp Pathol.* 2015;8:13625-9.
23. Abd El-Halim YAM, Kassab FA, Sedek AM. Management of Placenta accreta and its complications in cases of previous cesarean section with placenta previa anterior at Al-Hussein University Hospital. *A I M J.* 2020;1:83-7.
24. Karpathiou G, Chauleur C, Dridi M, Baillard P, Corsini T, Dumollard JM, et al. Histologic Findings of Uterine Niches. *Am J Clin Pathol.* 2020;154:645-55.
25. Alchalabi ASH, Rahim H, Aklilu E, Al-Sultan II, Aziz AR, Malek MF, et al. Histopathological changes associated with oxidative stress induced by electromagnetic waves in rats' ovarian and uterine tissues. *Asian Pac J Reprod.* 2016;5:301-10.
26. Tikkanen M, Paavonen J, Loukovaara M, Stefanovic V. Antenatal diagnosis of placenta accreta leads to reduced blood loss. *Acta Obstet Gynecol Scand.* 2011;90:1140-6.
27. Wright JD, Silver RM, Bonanno C, Gaddipati S, Lu YS, Simpson LL, et al. Practice patterns and knowledge of obstetricians and gynecologists regarding placenta accreta. *J Matern Fetal Neonatal Med.* 2013;26:1602-9.
28. Stafford IA, Dashe JS, Shivvers SA, Alexander JM, McIntire DD, Leveno KJ. Ultrasonographic cervical length and risk of hemorrhage in pregnancies with placenta previa. *Obstet Gynecol.* 2010;116:595-600.
29. Rac MWF, McIntire DD, Wells CE, Moschos E, Twickler DD. Cervical Length in Patients at Risk for Placenta Accreta. *Journal of Ultrasound in Medicine.* 2017;36:1431-6.

30. Mar WA, Berggruen S, Atueyi U, Sekhon S, Garzon SA, Knuttinen MG, et al. Ultrasound imaging of placenta accreta with MR correlation. *Ultrasound Q.* 2015;31:23-33.
31. Comstock CH. Antenatal diagnosis of placenta accreta: a review. *Ultrasound Obstet Gynecol.* 2005;26:89-96.
32. Wong HS, Cheung YK, Tait J. Sonographic study of the decidua basalis in the first trimester of pregnancy. *Ultrasound Obstet Gynecol.* 2009;33:634-7.
33. Rac MW, Dashe JS, Wells CE, Moschos E, McIntire DD, Twickler DM. Ultrasound predictors of placental invasion: the Placenta Accreta Index. *Am J Obstet Gynecol.* 2015;212:343.e1-7.
34. Yoon SY, You JY, Choi SJ, Oh SY, Kim JH, Roh CR. A combined ultrasound and clinical scoring model for the prediction of peripartum complications in pregnancies complicated by placenta previa. *Eur J Obstet Gynecol Reprod Biol.* 2014;180:111-5.
35. Bowman ZS, Kennedy AM. Sonographic appearance of the placenta. *Curr Probl Diagn Radiol.* 2014;43:356-73.
36. Koai E, Hadpawat A, Gebb J, Goffman D, Dar P, Rosner M. Clinical outcomes and efficacy of antenatal diagnosis of placenta accreta using ultrasonography and magnetic resonance imaging. *Obstet Gynecol.* 2014;123:61S.
37. D'Antonio F, Iacovella C, Palacios-Jaraquemada J, Bruno CH, Manzoli L, Bhide A. Prenatal identification of invasive placentation using magnetic resonance imaging: systematic review and meta-analysis. *Ultrasound Obstet Gynecol.* 2014;44:8-16.
38. Chou MM, Chen WC, Tseng JJ, Chen YF, Yeh TT, Ho ES. Prenatal detection of bladder wall involvement in invasive placentation with sequential two-dimensional and adjunctive three-dimensional ultrasonography. *Taiwan J Obstet Gynecol.* 2009;48:38-45.

39. Shih JC, Palacios Jaraquemada JM, Su YN, Shyu MK, Lin CH, Lin SY, et al. Role of three-dimensional power Doppler in the antenatal diagnosis of placenta accreta: comparison with gray-scale and color Doppler techniques. *Ultrasound Obstet Gynecol.* 2009;33:193-203.
40. Barati M, Shahbazian N, Ahmadi L, Masihi S. Diagnostic evaluation of uterine artery Doppler sonography for the prediction of adverse pregnancy outcomes. *J Res Med Sci.* 2014;19:515-9.
41. Cho HY, Hwang HS, Jung I, Park YW, Kwon JY, Kim YH. Diagnosis of Placenta Accreta by Uterine Artery Doppler Velocimetry in Patients With Placenta Previa. *J Ultrasound Med.* 2015;34:1571-5.
42. Henrich W, Stupin JH. 3D volume contrast imaging (VCI) for the visualization of placenta previa increta and uterine wall thickness in a dichorionic twin pregnancy. *Ultraschall Med.* 2011;32:406-11.
43. Millar L, Streiner N, Webster L, Yamamoto S, Okabe R, Kawamata T, et al. Early placental insulin-like protein (INSL4 or EPIL) in placental and fetal membrane growth. *Biol Reprod.* 2005;73:695-702.
44. Ahmed SR, Aitallah A, Abdelghafar HM, Alsammani MA. Major Placenta Previa: Rate, Maternal and Neonatal Outcomes Experience at a Tertiary Maternity Hospital, Sohag, Egypt: A Prospective Study. *J Clin Diagn Res.* 2015;9:Qc17-9.