Prosthetic rehabilitation in carcinoma of the tongue and oral pelvis: presentation of a clinical case

ABSTRACT

Aims: the authors want to describe a case of prosthetic rehabilitation in a 50 years old woman who has undergone a removal surgery of a neoplastic lesion that involved the oral pelvis and the lingual border. The inherent literature regarding the prosthetic rehabilitation of post-irradiated bones is also evaluated.
Presentation of Case: A 50-year-old Caucasian woman with a history of smoking and alcohol consumption has come to our attention with an ulcerative lesion of the left lingual pelvis.
Discussion: The patient's clinical, radiological, and anamnestic data enabled the preoperative staging of the oral cavity's neoplasm, which has been treated with a transmandibular conservative surgical resection of the lesion associated with a mRND and bilateral neck dissection (LV. I to III); this was then followed by an immediate surgical reconstruction with a radial antebrachial bundle-cutaneous free flap.
Conclusion: One year after surgery, excluding the presence of recurrences through MR with contrast, the dental residues have been removed, and rehabilitation with an implanted prosthesis has been completed. Aesthetic outcome was remarkable. Both the preoperative multi-specialist evaluation and the definition of a common rehabilitation program represent essential prerequisites in order to avoid some possible and serious complications of the treatment. Postoperative radiotherapy for oral cancer is now universally associated with implant-prosthetic rehabilitation therapy.

Keywords: [Oral cancer], [Forearm free flap], [Reconstruction], [Radiotherapy], [Oral implantology], [Antebrachial bundle-cutaneous free flap]

1. INTRODUCTION

Oral cavity reconstruction secondary to removal surgery of neoplastic lesions has undergone significant changes over the last twenty years in order to reach an acceptable quality of life mainly thanks especially to two factors: revascularized free flaps and the use of osseointegrated dental implants.

The radial antebrachial bundle-cutaneous free flap represents one of the most commonly used revascularized free flaps for oral cavity reconstruction. This flap was first described by Yang et al. in 1981 [1], but only in 1983 did Soutar et al.[2] define it as a versatile solution for reconstruction of soft tissues and mucosal defects of the oral cavity.

Prosthetic rehabilitation following oral cancer surgery is often difficult without using endosseous implants, which are able to ensure stabilization and retention of the prostheses. The use of dental implantology during the reconstructive phase of oral cancer surgery can be divided into two categories: retention of a removable prosthesis or steady prosthetic rehabilitation with or without maxillary bone reconstruction. The reliability of dental implantology in irradiated bone has been a major point of debate in the recent literature.

The authors propose a paradigmatic clinical chase of oral cancer carcinoma treated with surgical ablation combined with adjuvant radiotherapy, reconstruction with radial antebrachial free flap, and consistent prosthetic rehabilitation on implants based on an accurate review of recent inherent literature.

2. CLINICAL CASE

A 50-year-old caucasian woman with a history of smoking (20 cigarettes per day) and alcohol consumption (less than 1 liter per day) has come to our attention at the ENT Department and Maxillo-Facial Surgery Unit of San Giovanni Bosco Hospital of Turin with an ulcerative lesion of the left lingual pelvis. This lesion involved also the left lingual border, evoking pain and a blockage of the lingual body, which was also infiltrated deeply up to involve the cortical bone of the mandibula.

Through MR (Fig. 1), it is clearly visible the involvement of the hyoglossus muscle, the whole left part of the tongue, and the presence of an homolateral lymph node lesion with a diameter smaller than 3 cm. Thanks to radiological imaging and the clinical history, it was possible to define a preoperative staging of T4N1M0.

The patient's neoplasm has been treated with a conservative transmandibular removal surgery through a translabyrinthine approach with an en bloc hemiglossectomy associated with a bone mandibular dowel and bilateral mRND (LV I to III).

Reconstruction has been performed by using an antebrachial bundle skin flap vascularized from the radial artery and its venae comitantes and cefalic. Arterial and venous anastomoses were performed between the facial and radial arteries and between the brachial venous axis and the internal jugular vein on the left, respectively. Before doing osteotomies, preplating was performed, i.e., the positioning of the synthesis plates before performing the osteotomies in order to facilitate the reconstruction. The osteotomy was performed in steps to increase the bone-facing surface and improve the stability of the subsequent fixation. Furthermore, the dentition not related to the lesion was partially preserved in order to have an extra occlusal reference. The resection monoblock includes the hemitongue, the ipsilateral oral floor, the mandibular plug, and the laterocervical dissections (Fig. 2).

The examination of the surgical specimen confirmed the clinical staging and indicated the postoperative RT (67 Gy, about one month after the operation). Fig. 3 shows the result of the surgery in the immediate post-operative period with x-ray control, which highlights the bone plug and the reconstruction. The postoperative period was regular.

12 months after surgery, an MR with contrast study has been done, which confirmed the absence of recurrences. The removal of the residual dental elements was performed, followed by the removal of most of the coronal synthesis plate in order to obtain a gain in available bone height. Six submerged implants for prosthetic purposes were then positioned.

An x-ray control was performed at 5 months and eventually the second surgical time for uncovering the implants. The prosthetic load was performed after about 1 month in order to permit adequate recovery of the soft tissues around the healing abutments.

In Fig. 4 it is possible to observe the presence of a provisional prosthesis in the patient's mouth, with large cleaning spaces.

In this case, we opted for a fixed prosthesis without mucosal support screwed onto the posterior implants and cemented on a metal structure screwed to the three anterior implants, which are therefore joined together. In this way, it was decided to obtain a better distribution of the prosthetic load across the osteotomy, a particularly critical point following the administration of postoperative radiotherapy treatment.

In Fig. 5 we can appreciate the good esthetical outcome with the preservation of the vertical dimension and good projection of the lips in spite of the translabiotomy access .

3. RESULTS AND DISCUSSION

In literature, success rates in the surgical treatment of oral carcinomas with dental rehabilitation associated with the use of free tissue grafts and radiotherapy treatment present variable percentages. Among the main factors that oppose an effective prosthetic rehabilitation are a clear reduction of the neutral zone, a reduced lingual functionality that is difficult to compensate for by remaining soft tissues and mandibular bone, and a reduced salivary production. Using these endosseous implants can partially reduce the impact of these factors.

Results are better in the mandible than in the maxilla, probably due to differences in bone structure. Recent reports find higher success rates with native bone (90%) than grafted bone (70–80%) [3]. According to some authors [4], the high percentage of implant survival failures would be related to the high percentage of patient mortality rather than the loss of osseointegration. Implant failure in radiation-treated patients is related to radiation-induced changes in both soft and hard tissues. At the bone level, vessels of the Haversian canals may become obliterated, and the periosteum could lose cellularity, vascularization, and osteoid formation. The hematopoietic proliferation becomes scattered in the bone marrow, and the sinusoids assume an irregular configuration and distribution [5]. The late effects of radiotherapy may cause a prevalence of the catabolic processes over the anabolic ones in bone formation, with a clear reduction of the mineral content in the radio-treated bone. On the other hand, at the soft tissue level, the main problem seems to be related to the reduction of salivation and, therefore, to a reduced ability to cleanse the oral cavity.

There is debate in the literature about the optimal timing of implant placement in patients requiring radiotherapy. A systematic review [6] over a period of 16 years demonstrated a comparable failure rate between implants placed before or after radiotherapy treatment (3.2% versus 5.4%, respectively). Most of the failures were recorded between 1 and 12 months after surgery. Substantial failure rates are related to radiation therapy doses exceeding 45 Gy.

Some authors believe that the implants should be placed immediately after the ablative procedure, in the same surgical session, in order to obtain better osseointegration before irradiation, thus eliminating the need for further surgery or additional therapy with hyperbaric oxygen and enabling adequate rehabilitation of speech and swallowing [7]. A combined surgical approach in a single stage seems, according to these authors, to be easy and effective, allowing total mandibular rehabilitation. Another advantage of this approach is the

wide access to bone segments with considerable surgical exposure, which allows for accurate alignment of implants with the corresponding maxillary dentition [8]. This approach cannot be done without a meticulous presurgical examination and a careful multidisciplinary evaluation with well-defined treatment planning. The major disadvantage of the immediate insertion of the implants is the risk of improper positioning in cases of gross anatomical alterations, which has a negative influence on rehabilitation. It is also necessary to consider the risk of interference with or delay of cancer therapy, including radiotherapy, in the event of the development of postoperative complications related to the implants, as well as the risk that an early tumor recurrence could render implants useless.

Other authors are against the placement of implants in the first phase of surgery. Oral reconstruction and rehabilitation could be divided into primary and secondary reconstruction. Patients who have undergone partial mandibulectomy without bone reconstruction may require secondary reconstruction before implant placement in the site of the bone defect. Due to the frequency of recurrences and metastases in the first two years following the primary treatment, it has been suggested to carry out costly treatments only after this period of high risk, since it is not appropriate to implant patients with an uncertain prognosis in the first instance. Proponents of this approach believe that blood supply to the bone flap may be compromised during the first stage of surgery due to osteotomies, so implant placement is less accurate at this time as bone and soft tissue healing is not yet complete. Others have proposed to delay implant placement from 6 to 12 months after radiotherapy and then observe an integration period of 5 to 6 months before the second surgical stage and prosthetic loading [9]. This period seems necessary to achieve appropriate osseointegration after the administration of radiotherapy. There are authors who, on the other hand, favor short healing times for implants in order to substantially prevent bone resorption [10].

It has also been proposed to use hyperbaric oxygen therapy in order to promote bone and tissue healing, but the results in the literature are not clear. Hyperbaric oxygen therapy inhibits leukocyte adhesion to endothelium, reducing tissue damage, improving leukocyte motility, and increasing microcirculation [11]. In the early stages, there is vasoconstriction, reduction of edema, activation of phagocytes, and an anti-inflammatory effect [12], while in the long term, neovascularization, osteogenesis, and stimulation of collagen production by fibroblasts are obtained, which favor wound healing. Marx in 1983 [13] had proposed a protocol consisting of 20 sessions before and 10 after therapy with osteointegrated implants, supported by Larsen in 1997 [14]. Some authors have shown themselves in favor of hyperbaric therapy as an aid to the osseointegration of the implants [15], while others [16] [17] have opposed this practice for economic reasons or potential complications. A single randomized trial [18], reported in a Cochrane review [19], does not show substantial interferences of hyperbaric therapy on the implant’s success rate.

In the case under examination, the choice made was a result of a mindful multidisciplinary preoperative evaluation, according with literature [20], associated with the patient's requests. It would have been possible to carry out a rehabilitation with a removable prosthesis on implants, but this prosthesis would have given considerable mucosal support with mechanical interference from the antebrachial flap, which, although pliable and thin, does not have the typical characteristics of oral cavity mucosa. Furthermore, this problematic mucosal support could probably have led to decubitus either on the residual mucosa or on the flap itself, both due to the mechanical interference with the flap and irregularities of the residual bone surface after the surgery, which are difficult to compensate for prosthetically; these two factors are also associated with an increased occurrence of oral cancer. Radiotherapy basically causes a salivary reduction with gingival tissue damage that is poorly suited to mobile prostheses. In our case, a large cleansing space was left between the posts in order to facilitate cleaning and make the implants last longer, avoiding dangerous peri-

implantitis. Furthermore, the patient wanted a fixed prosthesis at all costs in order to consolidate a new aesthetic appearance associated with modified voluptuous habits (smoking and alcohol cessation) in the context of a total improvement in the overall quality of life.

4. CONCLUSION

In cases of surgical success in maintaining or reconstructing a sufficient amount of bone in order to obtain a favorable anatomical set, rehabilitation on implants is, in our opinion, the best solution for patients with oral cavity neoplasms, even following combined radio-surgical treatment. Today is relatively reliable to insert endosseous implants on radiotreated bone after a suitable waiting period or even at the same time as ablative surgery.

Consent

As per international standard or university standard, patient(s) written consent has been collected and preserved by the author(s).

Ethical Approval:

As per international standard or university standard written ethical approval has been collected and preserved by the author(s).

ACKNOWLEDGEMENTS

A brief acknowledgement section may be given after the conclusion section just before the references. The acknowledgments of people who provided assistance in manuscript preparation, funding for research, etc. should be listed in this section. All sources of funding should be declared as an acknowledgement. Authors should declare the role of funding agency, if any, in the study design, collection, analysis and interpretation of data; in the writing of the manuscript. If the study sponsors had no such involvement, the authors should so state.

COMPETING INTERESTS

Authors declare that they have no conflict of interest.

AUTHORS' CONTRIBUTIONS

Authors declare that they have not received institutional funding for this study.

REFERENCES

1. Yang DY. Management of vascular problems in microsurgery. Zhonghua Wai Ke Za Zhi. 1981;19(3):131-135.

2. Soutar DS, Scheker LR, Tanner NS, McGregor IA. The radial forearm flap: a versatile method for intra-oral reconstruction. Br J Plast Surg. 1983;36(1):1-8.

3. Dholam KP, Gurav SV. Dental implants in irradiated jaws: a literature review. J Cancer Res Ther. 2012;8 Suppl 1:S85-93.

4. Nelson K, Heberer S, Glatzer C. Survival analysis and clinical evaluation of implant-retained prostheses in oral cancer resection patients over a mean follow-up period of 10 years. J Prosthet Dent. 2007;98(5):405-410.

5. Knospe WH, Blom J, Crosby WH. Regeneration of locally irradiated bone marrow. I. Dose dependent, long-term changes in the rat, with particular emphasis upon vascular and stromal reaction. Blood. 1966;28(3):398-415.

6. Colella G, Cannavale R, Pentenero M, Gandolfo S. Oral implants in radiated patients: a systematic review. Int J Oral Maxillofac Implants. 2007;22(4):616-622.

7. Korfage A, Schoen PJ, Raghoebar GM, Bouma J, Burlage FR, Roodenburg JL, Vissink A, Reintsema H. Five-year follow-up of oral functioning and quality of life in patients with oral cancer with implant-retained mandibular overdentures. Head Neck. 2011;33(6):831-839.

8. Chim H, Salgado CJ, Mardini S, Chen HC. Reconstruction of mandibular defects. Semin Plast Surg. 2010;24(2):188-197.

9. Claudy MP, Miguens SA Jr, Celeste RK, Camara Parente R, Hernandez PA, da Silva AN Jr. Time interval after radiotherapy and dental implant failure: systematic review of observational studies and meta-analysis. Clin Implant Dent Relat Res. 2015 Apr;17(2):402-11. doi: 10.1111/cid.12096. Epub 2013 Jun 7. PMID: 23742098.

10. Shirota T, Ohno K, Michi K, Tachikawa T. An experimental study of healing around hydroxylapatite implants installed with autogenous iliac bone grafts for jaw reconstruction. J Oral Maxillofac Surg. 1991;49(12):1310-1315.

11. Mortensen SP, Damsgaard R, Dawson EA, Secher NH, González-Alonso J. Restrictions in systemic and locomotor skeletal muscle perfusion, oxygen supply and VO2 during high-intensity whole-body exercise in humans. J Physiol. 2008;586(10):2621-2635.

12. Spiegelberg L, Djasim UM, van Neck HW, Wolvius EB, van der Wal KG. Hyperbaric oxygen therapy in the management of radiation-induced injury in the head and neck region: a review of the literature. J Oral Maxillofac Surg. 2010;68(8):1732-1739.

13. Marx RE, Kline SN. Principles and methods of osseous reconstruction. Int Adv Surg Oncol. 1983;6:167-228.

14. Larsen PE. Placement of dental implants in the irradiated mandible: a protocol involving adjunctive hyperbaric oxygen. J Oral Maxillofac Surg. 1997;55(9):967-971.

15. Granström G. Placement of dental implants in irradiated bone: the case for using hyperbaric oxygen. J Oral Maxillofac Surg. 2006;64(5):812-818.

16. Benites Condezo AF, Araujo RZ, Koga DH, Curi MM, Cardoso CL. Hyperbaric oxygen therapy for the placement of dental implants in irradiated patients: systematic review and meta-analysis. Br J Oral Maxillofac Surg. 2021 Jul;59(6):625-632. doi: 10.1016/j.bjoms.2020.08.050. Epub 2020 Aug 19. PMID: 33952404.

17. Shaw RJ, Butterworth CJ, Silcocks P, Tesfaye BT, Bickerstaff M, Jackson R, Kanatas A, Nixon P, McCaul J, Praveen P, Lowe T, Blanco-Guzman M, Forner L,

Brennan P, Fardy M, Parkin R, Smerdon G, Stephenson R, Cope T, Glover M. HOPON (Hyperbaric Oxygen for the Prevention of Osteoradionecrosis): A Randomized Controlled Trial of Hyperbaric Oxygen to Prevent Osteoradionecrosis of the Irradiated Mandible After Dentoalveolar Surgery. Int J Radiat Oncol Biol Phys. 2019 Jul 1;104(3):530-539. doi: 10.1016/j.ijrobp.2019.02.044. Epub 2019 Mar 7. PMID: 30851351.

18. Schoen PJ, Raghoebar GM, Bouma J, Reintsema H, Vissink A, Sterk W, Roodenburg JL. Rehabilitation of oral function in head and neck cancer patients after radiotherapy with implant-retained dentures: effects of hyperbaric oxygen therapy. Oral Oncol. 2007;43(4):379-388.

19. Coulthard P, Patel S, Grusovin GM, Worthington HV, Esposito M. Hyperbaric oxygen therapy for irradiated patients who require dental implants: a Cochrane review of randomised clinical trials. Eur J Oral Implantol. 2008;1(2):105-110.

20. Barret JP, Roodenburg JL. Functional rehabilitation in advanced intraoral cancer. Int J Surg Oncol (N Y). 2017 Feb;2(2):e10. doi: 10.1097/IJ9.0000000000000010. Epub 2017 Jan 10. PMID: 29177211; PMCID: PMC5673113.

FIGURES

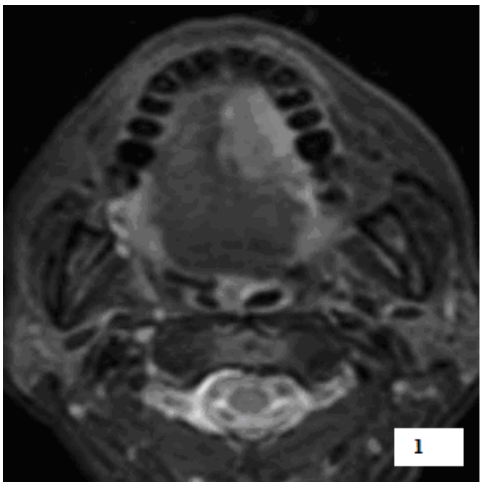

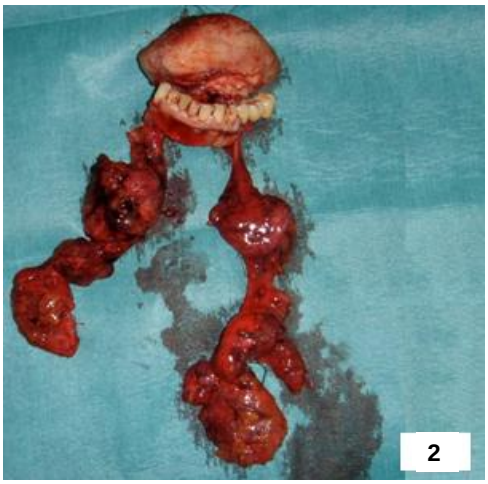

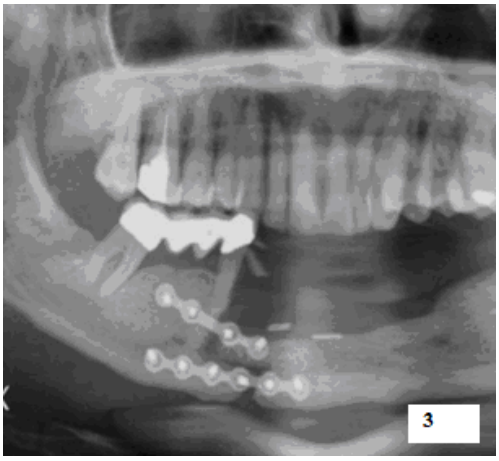

Figure Legends:

Fig 1: MR of the carcinoma showing the involvement of the whole left part of the tongue;

Fig. 2: resection monoblock including the hemitongue, the ipsilateral oral floor, the mandibular plug, and the laterocervical dissections;

Fig. 3: immediate post-operative period x-ray control;

Fig. 4: provisional prosthesis in the patient's mouth, with large cleaning spaces;

Fig. 5: final esthetical outcome.