Case report

Clinical and dermoscopic features of Winer's nodular solitary calcinosis

.

UNDER PEER REVIEW

ABSTRACT

Aims: Solitary nodular calcinosis of Winer is a rare and benign form of localized idiopathic cutaneous calcinosis. Its dermoscopic features may be useful for early diagnosis, but have never been described in the literature to our knowledge.

Case report : A 5-year-old child presented to our clinic with a 2 years history of a painless keratotic and warty nodule located in the helix of the right ear. A wart was suspected and treated without any improvement. Dermoscopy was performed and showed peripheral white deposits suggestive of Winer's calcinosis, motivating an excision whose histological examination confirmed the diagnosis.

Discussion : The subepidermal calcified nodule has been rarely described in the literature. It is not known to be associated with a disorder of phosphocalcium metabolism or other systemic diseases. Pathogenic hypotheses include calcification of preexisting skin structures, mast cell degranulation with secondary calcinosis, or prior trauma. Surgical excision with histopathological confirmation is necessary to show the dermal calcium deposits, which are usually amorphous and granular and may be surrounded by a lymphohistiocytic infiltrate or giant cells. Nevertheless, dermatoscopic evaluation can aid in rendering a timely diagnosis by showing these whitish dermal deposits.

Conclusion: The diagnosis of Winer's nodular calcinosis has always been based on histology, but the dermoscopy described here for the first time is so suggestive that it can be used to save time and exclude other differential diagnoses.

Keywords: Nodular calcinosis - Calcified subepidermal nodule - Winer - Child - Dermoscopy

1. INTRODUCTION

Cutaneous calcifications are characterized by dermal or hypodermal deposits of hydroxyapatite. Several types are distinguished according to the etiology: dystrophic, which is most often associated to autoimmune connective tissue diseases, idiopathic, metastatic occurring after calcium phosphate product exceeds 70, and iatrogenic which is the result of precipitation of calcium salts following the administration of a calcium or phosphate containing agent. In the first and second type, and in contrast to the last two, the phosphocalcic balance is normal [1, 2]. Winer's nodular solitary calcinosis, also known as subepidermal calcified nodule, is a rare form of localized idiopathic cutaneous calcinosis that occurs primarily in male children on the head and neck. Surgical excision with histopathological confirmation is necessary to detect the dermal deposits. Nevertheless, dermoscopy can lead to an early and easy diagnosis by showing these whitish dermal deposits prior to excision.

2. PRESENTATION OF THE CASE

A 5-year-old child with no medical history and no and no prior traumatic episode presented for 2 years a solitary painless keratotic and warty nodule, measuring 6 mm in length, located on the helix of the right ear (Figure 1). Dermoscopic images showed a keratinized center, whitish deposits in the periphery and some small linear vessels (Figure 2). The lesion had been treated initially as a wart, without any improvement.
Excisional biopsy was performed and histopathological evaluation showed an acanthosic epidermis with orthokeratotic hyperkeratosis and an amorphous dermal calcium deposits surrounded by a scarring fibrosis with a giant foreign body-like reaction (Figure 3). Phosphocalcic workup with vitamin D measurement ruled out metastatic calcification. The diagnosis of Winer's nodular calcinosis was made on dermoscopic, histological and biological criteria. No recurrence has been reported to date.

3. DISCUSSION

Calcinosis cutis is the accumulation of insoluble calcium salts in the skin. It is classified on the basis of its pathogenesis into dystrophic, metastatic, iatrogenic and idiopathic. Idiopathic calcinosis is asymptomatic, seen in healthy patients and involves Winer's nodular calcinosis or subepidermal calcified nodules, scrotal calcinosis and familial tumor calcinosis [3]. First described by Winer in 1952, the subepidermal calcified nodule is a rare and benign form of localized idiopathic calcinosis cutis, without phosphocalcic disorders or associated systemic disease [4]. Winer's calcinosis may be congenital or appear in early childhood with a male predominance. It appears as a single firm, asymptomatic, yellow-white or erythematous tumor, preferentially located on the head and neck. Ulcerations with discharge of chalky material may occur [5]. Less frequently, multiple nodules are observed [6].To our knowledge, its dermoscopy has not been previously reported in the literature. The differential diagnosis can be made, among others, with a wart, a squamous cell carcinoma, a pilomatricoma, a molluscum contagiosum or a sebaceous cyst [7,8]. Hence the interest of dermoscopy, that can rule out these different diagnoses by showing the dermal calcium deposits.
The pathogenesis of Winer's calcinosis is unclear. Some authors assume that it results from calcification of pre-existing skin structures such as syringomas, nevus or necrosis of subcutaneous fat. Others suggest mast cell degranulation with secondary calcinosis or even a previous trauma [9]. Histologically, dermal calcium deposits are usually amorphous and globular or granular, may be surrounded by a lymphohistiocytic or giant cell infiltrate and do not involve accessory glands [4]. Treatment with CO_2 laser has been successfully reported [10]. Nevertheless, surgical removal with anatomopathological examination remains the treatment of choice.

4. CONCLUSION

The subepidermal calcified nodule is a rare but specific subtype of idiopathic calcinosis, especially in children. Several etiological hypotheses can be raised in front of this picture but the dermoscopy can aid in rendering a timely diagnosis by showing the intradermal calcium deposits.

UNDER PEER REVIEW

CONSENT

All authors declare that written informed consent was obtained from the patient (for publication of this case report and accompanying images. A copy of the written consent is available for review by the Editorial office/Chief Editor/Editorial Board members of this journal.

ETHICAL APPROVAL

All authors hereby declare that all experiments have been examined and approved by the appropriate ethics committee and have therefore been performed in accordance with the ethical standards laid down in the 1964 Declaration of Helsinki

REFERENCES

1. Fabreguet I, Saurat JH, Rizzoli R, Ferrari S, Calcinose cutanée associée aux connectivites, Revue médicale suisse, 466 11 : 668-72, 2015

2. Le C, Bedocs P.M, Calcinosis Cutis, In: StatPearls [Internet]. Treasure Island (FL): StatPearls Publishing; 2023 Jan.2022 Jul 12.

3. Marín-Hernández E, Reyes-Salcedo C.A, Cárdenas-Conejo A, Peregrino-Bejarano L, Reyes-Cuayahuitl A, Rayo-Mares D, Siordia-Reyes G.A, Tumorous congenital calcinosis cutis associated with early childhood epileptic encephalopathy with a pathogenic FGF12 gene variant, Bol Med Hosp Infant Mex., 2020;77(6):331-336. doi: 10.24875/BMHIM.20000030.

4. In Su Ahn, Chung BY, Bong Lee H, et al. , A Case of a Subepidermal Calcified Nodule on the Sole without Trauma, Annals of dermatology, 2011 Sep;23 Suppl 1(Suppl 1):S116-8A, https://doi.org/10.5021/ad.2011.23.S1.S116

5. Sparsa A, Calcinoses, ossifications et lésions cartilagineuses cutanées, EMC, 98-730-A-10, 2007, https://doi.org/10.1016/S0246-0319(07)44805-1

6. KH Fernandez, DS Ward , Calcinosis cutis: etiology and patient evaluation, MA: UpToDate, 2018

7. P.Chang, Moreno-Coutiño G, Periocular dermatoses, International Journal of Women's Dermatology Volume 3, Issue 4, December 2017, Pages 206-218, https://doi.org/10.1016/j.ijwd.2017.08.001

8. EC Karadag, H Toy, Z Tosun, Winer's Nodular Calcinosis Mimicking Squamous Cell Carcinoma On The Ear, Turkish Journal of Plastic Surgery, 2017

9. A. Azon-Masollver, Ferrando J, Navarra E, Mascaro J M, Solitary Congenital Nodular Calcification of Winer Located on the Ear: Report of Two Cases, Pediatric Dermatology Vol. 6 No. 3 September 1989, https://doi.org/10.1111/j.1525-1470.1989.tb00815.x

10. Weig A, Roth G.M, Ferguson N.N, Subepidermal calcified nodule on the periungual finger successfully treated with ablative carbon dioxide laser, Pediatr Dermatol.2019 Mar;36(2):262-264. doi: 10.1111/pde.13742.

UNDER PEER REVIEW

FIGURES

REVIEW

Figure 1 : Nodule with keratotic surface, firm, yellowish-white in the helix of the right ear.

Figure 2 : Dermoscopic features including a central domed hyperkeratosis, whitish deposits in the periphery, and some small linear vessels.

UNDER PEER REVIEW

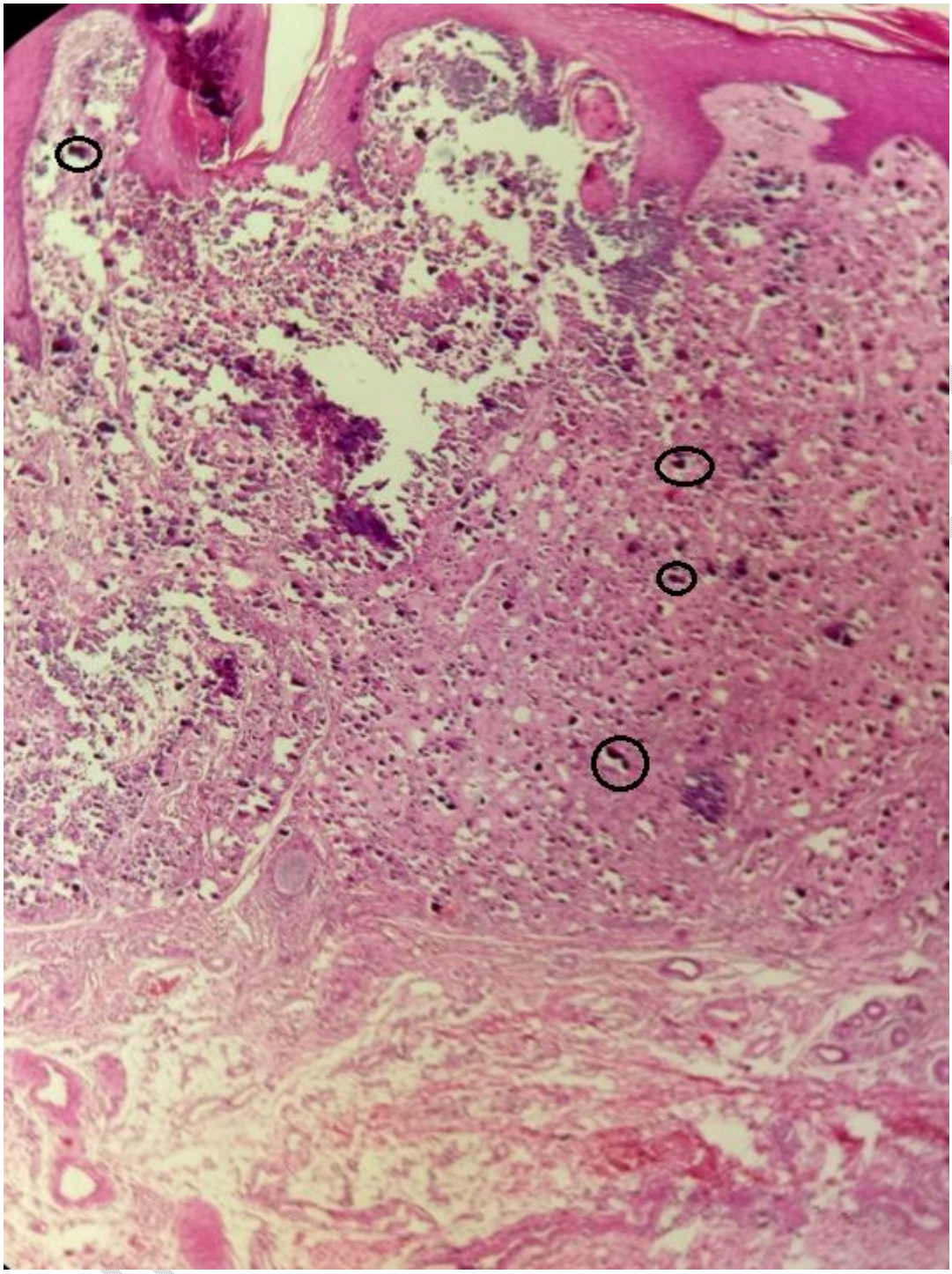

Figure 3 : Histological section showing amorphous dermal calcium deposits (HE stain)