

Original Research Article

Pathogenicity of *Aspergillus fumigatus* in experimental infection of different developmental stages of *Clarias gariepinus*

ABSTRACT

Aims: This study aimed to investigating the pathogenicity of *Aspergillus fumigatus* in the experimental infection of *Clarias gariepinus* fingerlings and juvenile catfish.

Experimental Procedure: *Aspergillus fumigatus* used for this study was isolated from the gills and liver of infected juveniles presented for microbial diagnostic examination, cultured on Sabouraud dextrose agar for 3 – 4 days, and identified at the Aquatic Animal and Wildlife Laboratory (AAWL), Department of Veterinary Medicine, University of Ibadan.

Methodology: One hundred and forty healthy eight-week old *Clarias gariepinus* fingerlings (average weight of 4g) and 140 healthy sixteen-week old juvenile (average weight of 10g) were purchased from a commercial fish farms in Ibadan. The fingerlings and juveniles were randomly divided into seven groups, each with 20 fish in five liters of water. The fungal suspension containing 3.2×10^6 spores/ml of *Aspergillus fumigatus* was used for the pathogenicity test. Six groups were infected by immersion in water containing fungal spores at the rates of 2ml/L and 5ml/L for fingerlings and juveniles respectively. The clinical signs, skin lesions and mortality were observed daily for 14 days.

Results: *Aspergillus fumigatus* isolated in this study has green spiked conidia; and the size of the conidia is 2.5µm. The conidia have a smooth surface and small spikes covering their surface.

Moreover, the mortality rate was significantly ($p = 0.40$) higher in infected fingerlings (80%) than juveniles (62%) at fourteen days post-infection. The gross lesions observed during

experimental infection of fingerlings and juveniles included exophthalmia, atrophied barbel, congested trunk kidney, hyperemia of **gill filaments**, and skin depigmentation. The histopathological organ changes caused by *Aspergillus fumigatus* were obvious in the liver and gills. Vacuolar degeneration of hepatocytes and necrosis of some melanomacrophage cells, in addition, severe erosion of the primary and secondary lamellae, were observed in infected juveniles.

Conclusion: *Aspergillus fumigatus* causes high mortality in fingerlings and juvenile of African Catfish (*Clarias gariepinus*)

Keywords: *Aspergillus fumigatus*, *Clarias gariepinus*, fingerlings, juvenile, pathogenicity

1.0 Introduction

Fungal infection in fish is a source of concern for fish farmers and aquaculturists. Many fungal pathogens that affect fish are opportunistic, producing infection following stress on fish as a result of poor environmental conditions or ongoing infection with another pathogen [1]. Disease-related economic losses are projected to rise due to intensification and development in aquaculture. This indicates the need to conduct extensive research into the pathogenicity of fungal disease in fish through experimental infections. Animal infection experiments have been extremely useful in determining the aetiology of various infections as well as investigating their pathogenicity and pathophysiology. Oomycetes, which are zoosporic fungi, have been reported as the main infectious pathogens in fish, and there are various conidial fungi related to fish infections [2].

Aspergillus and *Fusarium* are some of the genera involved in fish fungal infections.

Penicillium sp., *Aspergillus* sp., and *Alternaria* sp, were reported as pathogens of infected fishes [2]. Ornamental fish from freshwater were reported to be infected with fungal species such as *Aspergillus*, *Fusarium*, *Mucor*, *Penicillium*, and *Rhizopus* [2]. Freshwater fish Aspergillomycoses, which involved *Aspergillus niger* and *Aspergillus terreus*, were investigated as fish pathogens [3].

Moreover, the study of fish mycoses helps in the management, prevention, and spread of fish diseases in animals and humans. Meanwhile, there is a piece of scarce information on *Aspergillus fumigatus* infection in African catfish. Studies on *Aspergillus* sp as the causative agent of fish mycoses in freshwater fishes in Nigeria has not been thoroughly reported.

Therefore, this study aimed to investigate the pathogenicity of *Aspergillus fumigatus* in the experimental infection of *Clarias gariepinus* (*C. gariepinus*) fingerlings and juvenile catfish. The understanding of the pathophysiology of this disease enables aquaculturists and fish veterinarians to carry out proper prevention and disease control against *Aspergillus fumigatus* infection in African catfish.

2.0 Materials and Methods

2.1 Collection of Samples

The *Aspergillus fumigatus* used for this study was isolated from a case of infected *C. gariepinus* juvenile mortalities that were presented for bacterial, fungal isolation and identification at the Aquatic Animal and Wildlife Laboratory (AAWL), Department of Veterinary Medicine, University of Ibadan.

2.2 Fungal Isolation and Identification

The swabs from homogenized tissues of topically morbid juvenile *C. gariepinus* were streaked on Sabouraud dextrose agar (SDA) and incubated at 28-30 °C. The growth of the colony was observed in 3-4 days. For full growth of the colony, plates were kept for 8-10 days for incubation [4]. The isolated fungi were macroscopically examined for their morphological characteristics [5]. Slides were prepared from each colony by taking a small tuft of mycelium and staining it with Lactophenol cotton blue. The slides were observed under a microscope. Identification of fungi using the above procedure was reported [4].

2.3 Experimental Infection

One hundred and forty healthy eight-week old fingerlings with an average weight of 4g and 140 healthy sixteen-week old *C. gariepinus* juveniles with an average weight of 10g were collected from a commercial fish farm in Ibadan and transported under hygienic conditions to the Fish and Aquatic Animal Medicine Unit, Department of Veterinary Medicine, University of Ibadan.

The fingerlings were grouped into seven. The first group is controlled, while the remaining 6 groups were experimentally infected. The juveniles were also grouped in a similar and were acclimatized for 14 days. The microbial analysis and the aflatoxin analysis of the commercial feed samples fed to fingerlings and juveniles were carried out.

The identified *Aspergillus fumigatus* on Sabouraud Dextrose Agar (SDA) was recultured on SDA at 28±2°C to obtain a pure culture. A spore suspension taken gently from an eight-day old colony by sterile loop and transferred aseptically into a test tube containing sterile distilled water was prepared for inoculation. The fungal suspension was counted by haemocytometer, and the suspension was diluted by phosphate buffer solution to reach 3.2×10^6 spores/ml for *Aspergillus*

fumigatus used for the pathogenicity test which was based on the previous pilot study. Six groups were infected by immersion in water containing 3.2×10^6 spores/ml of the fungi at the rates of 2ml/L and 5ml/L as follows for fingerlings and juveniles based on previous pilot study. After three days of infection, half the water was replaced at the 24-hour intervals to further ensure good water quality [6]. pH, total Hardness, nitrite, ammonia, and dissolved oxygen concentration of the water were monitored and recorded at seven-day intervals to ensure tank water was not contaminated [6].

The experimentally-infected fishes were observed daily for 14 days. Clinical signs, organ lesions, and mortalities were monitored, meanwhile, organs such as skin, liver, and kidney were submitted for the histopathological procedure using H and E stains.

2.4 Statistical analysis

The water quality parameters in different tanks during experimental infection trials with fungal spores were determined and the analysis of variance (ANOVA) was used to determine the level of statistical significance. The analysis of variance (ANOVA) was also used to determine the level of significance in mortality rate during experimental infection, a p-value equal to 0.05 ($p = 0.05$) was considered significant.

3.0 Results and Discussion

Aspergillus fumigatus isolated in this study has green spiked conidia, and the size of conidia is $2.5\mu\text{m}$. The conidia have a smooth surface and small spikes covering their surface. The conidia were produced in column chains that are basipetal from green phalides $6 \text{ by } 2 \mu\text{m}$ (Figure 1).

The physicochemical findings such as Total hardness, ammonia, nitrite, and pH were not significantly different in control tank, infected fingerlings, and juvenile, meanwhile dissolved Oxygen was significantly ($p = 0.43$) higher in the control tank in comparison to infected

fingerlings and juvenile tanks (Table 1). Moreover, the mortality rate was significantly ($p = 0.40$) higher in infected fingerlings than in infected juvenile at day 7 and 14 respectively (Table 2).

The gross lesion observed during experimental infection of fingerlings and juveniles included exophthalmia, atrophied barbel, congested trunk kidney, hyperemia of the gills filament, and skin depigmentation (Figures 2 and 3).

The histopathological organ changes caused by *Aspergillus fumigatus* were obvious in the liver and gill. Vacuolar degeneration of hepatocytes and necrosis of some melanomacrophage cells (Figure 4), in addition, severe erosion of the primary and secondary lamellae was observed in infected juveniles (Figure 5).

This study reported the pathogenicity of *Aspergillus fumigatus* in cultured *Clarias gariepinus* fingerlings and juveniles. The gross lesion observed in this study was consistent with the findings of Iqbal & Mumtaz, [7], who reported epithelial desquamation which displayed erosion and finally led to ulceration in the infected area of the skin of *Channa punctatus* with *Aspergillus* sp. In the same vein, the external gross lesions of infected fishes in this study were also similar to the report of Chauhan et al., [8], who reported that the caudal region of fishes was the most infected area (53%) then head region (29%), fins (10%) and minimum infection was found in gills (8%). The mortality rate was significantly ($p = 0.43$) lower than the mortality rate observed in the study of Chauhan et al, [8] who reported 100% mortality in infected fishes with *Aspergillus fumigatus*, and this may be due to species difference.

Growth of the colony of *Aspergillus fumigatus* observed in this study showed maximum growth within 8 days duration of full colony growth, a similar growth pattern was previously reported with *Aspergillus sydowii* [9].

The histopathological organ changes observed in this study were comparable to reports of Iqbal et al, [10], who reported *Aspergillus* infection in the gills resulted in damage of secondary lamellae and this may be a source of respiratory problems.

Chauhan et al., [11] also indicated the loss of muscular cells, epidermal layer with complete necrotization of dermis and hypodermis in the infected *Channa maurilus* muscle and skin with *Aspergillus* sp, and these similar to the result of this study. The infected gills of fingerlings in this study showed severe lamellae atrophy, this is similar to the report of Rao [11] who observed atrophy of secondary gill lamellae and hypertrophy and hyperplasia of primary gill lamellae in infected fish with *Aspergillus* sp.

Studies on pathogenicity tests of *Aspergillus* sp. reported in the freshwater fishes are very rare. 3.2×10^6 spores/ml of the fungi at the rate of 2ml/L and 5ml/L for fingerlings and juveniles was found pathogenic to all the challenged fishes and death of most of the fishes within seven days. The findings are comparable with the reports of Chauhan et al., [8] who reported pathogenicity of three species of *Aspergillus* including *Aspergillus fumigatus* in nine different species of fish and death within ten days, likewise, Shristava [12] reported pathogenicity of *Aspergillus* on freshwater fishes and death within ten days. Refai *et al.*, [2] also confirmed *Aspergillus* as pathogenic fungi for fish with their histopathological findings. The present study is in agreement with this view and the pathogenic nature of *Aspergillus spp.* was confirmed by the re-isolation of fungi from the body of experimentally challenged fishes.

The presence of *Aspergillus* in the African catfish samples is of great significance because of food safety and quality. *Aspergillus* sp. are common in air and soil, and their presence in fish samples might contain metabolites produced by them, which may make fish consumption hazardous to human health. Similarly, Mitchell [13] mentioned that the potency of these

metabolites is not affected by cooking and may cause severe or fatal damage to the liver and kidneys of human.

5.0 Conclusion

Aspergillus fumigatus causes high mortality in fingerlings and juveniles of African Catfish (*Clarias gariepinus*). There were certain toxins present in given species of fungi that cause pathogenesis in fish leading to histopathological lesions, and varying degrees of destruction in the tissue resulting in the mortality of fish.

Ethical Approval

Ethical approval was obtained from the Ethical Committee, Faculty of Veterinary Medicine, University of Ibadan, Nigeria, ethical code number 02/2/21

REFERENCES

- 1) Fadaeifard F, Raissa M, Bahrami H, Rahim, Ei, Najafipoor A. Freshwater Fungi Isolated from Eggs and Brood stocks with an Emphasis on *Saprolegnia* in rainbow Trout Farms in West Iran. *Afri J Microbiol.* 2011;4(22) 3647-3651.
- 2) Refai MK, Laila A, Mohamed, Amany M, Kenawy, Shimaa EI-S.M.A. The assement of mycotic settlement of fresh water fishes in Egypt. *J of American Science.* 2010;6(11).
- 3) Olufemi BE, Roberts RJ. Induction of clinical aspergillomycosis by feeding contaminated diet to tilapia, *Oreochromis niloticus*. *J of Fish Dis.* 1986; 9, 123-128
- 4) Chauhan RLBH, Lone S, Beigh AH. Pathogenecity of three species of *Aspergillus* (*A. fumigatus*, *A. niger* & *A. sydowii*) on some fresh water fishes. *Life Sci Leaflets.* 2014;48, 65-72.
- 5) Atawodi JC, Yola IA, Kawo AH, Abdullahi BA. Fungi associated with african mudfish (*Clarias gariepinus*, Burchell 1822) in selected fish farms and dams in Zaria and its environs, Kaduna State, Nigeria. *Bayero J of Pure and Applied Sci.* 2017;10(1), 642-646.

- 6) Remilekun OA, Oladosu GA, Oladele OOl. Causal factors of mass mortality of hatchery reared *Clarias gariepinus* fry during exogenous feeding. *Int J Fish Aquat Stud*. 2021;9(1):235-239
- 7) Iqbal Z, Mumtaz R. Some fungal pathogens of an ornamental fish, Black Moor (*Carassius auratus* L.). *European J of Vet Med*. 2013;1, 1-10 ISSN 2051-297X
- 8) Chauhan RLBH, Lone S, Beigh AH. Pathogenicity of three species of *Aspergillus* (*A. fumigatus*, *A. niger* & *A. sydowii*) on some fresh water fishes. *Life Sci Leaflets*. 2014a;48, 65-72.
- 9) Alisa P, Garriet W, Smith, Kiho, Kim. Characterization of *Aspergillus sydowii* (Thom et Church), a fungal pathogen of Caribbean sea fan corals. *Hydrobiologia*. 2001;460: 105–111.
- 10) Iqbal Z, Sheikh U, Mughal R. Fungal infections in some economically important freshwater fishes. *Pak Vet J*. 2012a;32(3): 422-426.
- 11) Chauhan R, Ganaie SA, Lone SA. Studies on haematological and histological manifestations of *Channa marulius* (Ham.) found infected with fungi, *Aspergillus* sp. *Biolife*. 2014b; 2, 649-654.
- 12) Shrivastava AK. Record of *Aspergillus terreus* (Thorn.) Fungi as fish pathogen. *Indian J of fish* 1996;43, 2,203-204.
- 13) Mitchell TG. Medical mycology. In: Jawetz, Melnick and Adelberg's (Eds.). *Med Microbiol* 24th Edition McGraw Hill USA. 2007;621-625.



FIGURE 1 Image showing *Aspergillus fumigatus* on Sabouraud Dextrose Agar



FIGURE 2: Image of Infected juvenile showing atrophied barbel (A), exophthalmia (B), and Skin depigmentation (C)



FIGURE 3: Image of Infected fingerlings showing exophthalmia (A), skin discoloration (B), and atrophied barbel (C)

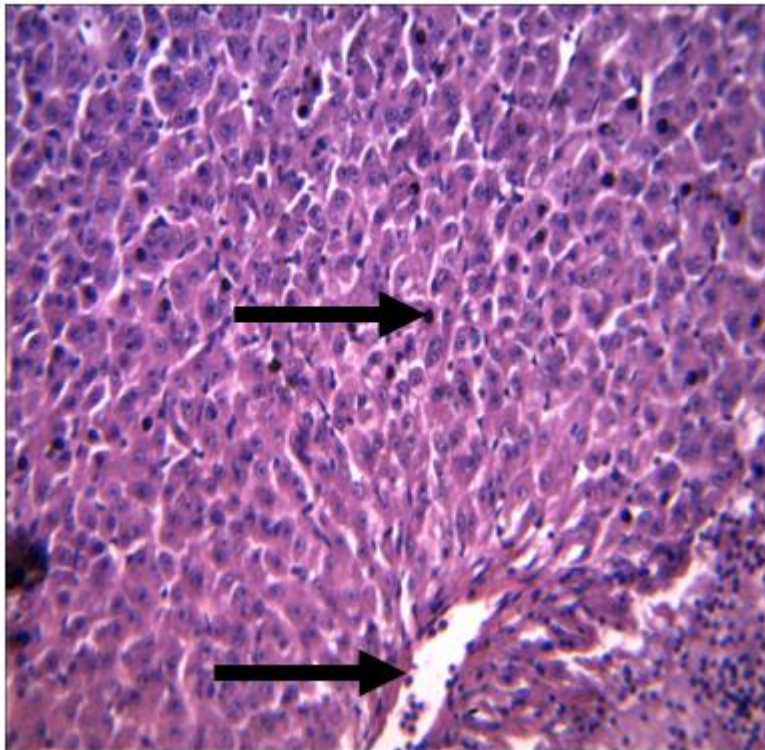


Figure 4: Vacuolar degeneration of hepatocytes and necrosis of some melanomacrophage cells (arrows) H & E X 400

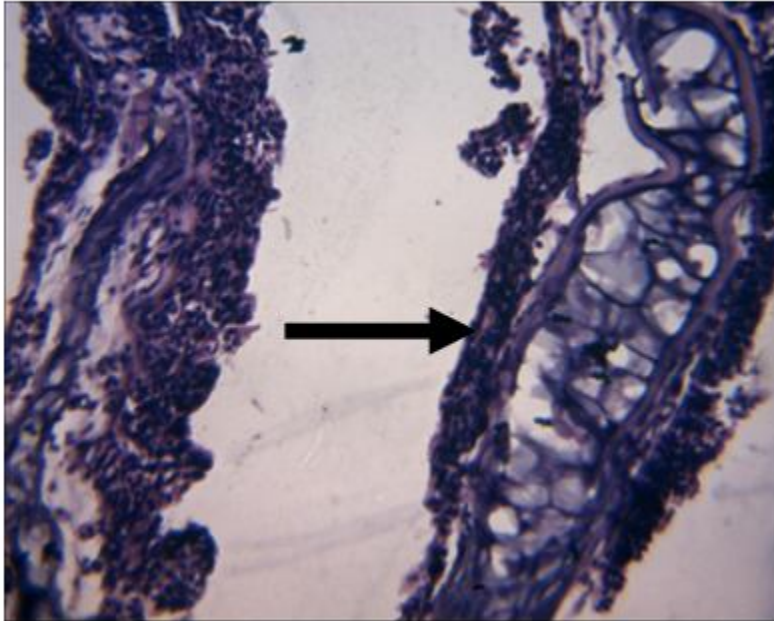


Figure 5: Severe erosion of primary and secondary lamellae (arrow)

UNDER REVIEW

Physicochemical Parameters	Control	Infected fingerlings	Infected Juvenile	Standard values for fish farming
pH	7.0±0.06	7.2±0.06	7.1±0.12	6.5 – 8.5
Total hardness (ppm)	85.0±8.9	71.0±9.3	70.4±7.2	50 – 150
Nitrite (ppm)	0.01±0.03	0.01±0.06	0.01±0.04	0.05 max
Ammonia (ppm)	0.79±0.04	0.7±0.02	0.69±0.01	2.0 max
Dissolved Oxygen (ppm)	7.0±1.20 ^a	4.5±1.44 ^b	4.0±1.73 ^c	5.0 min

TABLE 1 PHYSICO-CHEMICAL ANALYSIS OF WATER IN THE FISH TANKS DURING EXPERIMENTAL INFECTION

Values with different superscript along the row indicate significance (p = 0.43) - ANOVA

TABLE 2 MORTALITY RATE OF EXPERIMENTALLY INFECTED FISH WITH ASEPERGILLUS FUNMIGATUS

Experimental Groups	Day 7 (Percentage Mortality)	Day 14 (Percentage Mortality)
Control Fingerlings	0 ^a	0 ^a
Infected Fingerlings	60 ^b	80 ^b
Control Juvenile	0 ^a	0 ^a
Infected Juvenile	28 ^c	62 ^c

Values with different superscript along column indicate significance ($p = 0.40$) – ANOVA