

Original Research Article

Pathogenicity of *Aspergillus fumigatus* in experimental infection of different developmental stages of *Clarias gariepinus* (Burchell, 1822).

Comment [G1]: Delete as it title

ABSTRACT

Aims: This study was aimed to investigate pathogenicity of *Aspergillus fumigatus* used in experimental infection of *Clarias gariepinus* fingerlings and juvenile catfish.

Study Design: Isolation, identification and pathogenicity of fungal isolates was carried out in Aquatic Animal and Wildlife Laboratory (AAWL), Department of Veterinary Medicine, University of Ibadan.

Methodology: One hundred and forty healthy eight-weeks old *Clarias gariepinus* fingerlings (average weight of 4g) and 140 healthy 16 weeks old juvenile (average weight of 10g) were purchased from commercial fish farm in Ibadan. The fingerlings and juvenile were randomly divided into seven groups each of 20 fish in five liters of water. The fungal suspension 3.2×10^6 spores/ml of *Aspergillus fumigatus* was used for pathogenicity test. Six groups were infected by immersion in water containing fungal spores of the fungi at the rate of 2ml/L and 5ml/L for fingerlings and juvenile respectively. The clinical signs, skin lesions and mortality were observed daily for 14 days.

Results: *Aspergillus fumigatus* isolated in this study has green spiked conidia, the size of conidia is 2.5µm. The conidia have smooth surface and small spikes covering its surface. Moreover, mortality rate was significantly ($p = 0.40$) higher in infected fingerlings (80%) than juvenile (62%) at fourteen days post infection. The gross lesion observed during experimental infection of fingerlings and juveniles included exophthalmia, atrophied barbel, congested trunk kidney,

hyperemia of the filament of gill, and skin depigmentation. The histopathological organ changes caused by *Aspergillus fumigatus* were obvious in the liver and gill. Vacuolar degeneration of hepatocytes and necrosis of some melanomacrophage cells, in addition, severe erosion of the primary and secondary lamellae was observed in infected juvenile.

Comment [G2]: Gill filament

Conclusion: *Aspergillus fumigatus* causes high mortality in fingerlings and juvenile of African Catfish (*Clarias gariepinus*)

Key words: *Aspergillus fumigatus*, *Clarias gariepinus*, fingerlings, juvenile, pathogenicity

1.0 Introduction

Fungal infection in fish is a source of concern for fish farmers and culturists. Many fungal pathogens that affect fish are opportunistic, producing infection following stress on fish as a result of poor environmental conditions or ongoing infection with another pathogen [1]. Disease-related economic losses are projected to rise as due to intensification and development in aquaculture. This indicates the need to conduct extensive research into pathogenicity of fungal disease in fish through experimental infections. Animal infection experiments have been extremely useful in determining the aetiology of various infections as well as investigating their pathogenesis and pathophysiology. Oomycetes which are zoosporic fungi have been reported as main infectious pathogens in fish and there are various conidial fungi related to fish infections [2].

Aspergillus and *Fusarium* are some of the genera involved in fish fungal infections. *Penicillium* sp., *Aspergillus* sp., and *Alternaria* sp were reported as pathogens of infected fishes [2]. Ornamental fishes from fresh water were reported to be infected with fungal

species such as *Aspergillus*, *Fusarium*, *Mucor*, *Penicillium*, and *Rhizopus* [2]. Fresh water fish Aspergillomycoses which involved *Aspergillus niger*, and *Aspergillus terreus* were investigated as fish pathogens [3].

Moreover, the study of fish mycoses helps in management, prevention and spread of fish diseases in animal and human. Meanwhile, there is a scarce information on *Aspergillus fumigatus* infection in African catfish. *Aspergillus* as the cause of fish mycoses in freshwater fishes in Nigeria has not been thoroughly examined. Therefore, this study was aimed to investigate pathogenicity of *Aspergillus fumigatus* used in experimental infection of *Clarias gariepinus* (*C. gariepinus*) fingerlings and Juvenile catfish.

2.0 Materials and Methods

2.1 Collection of Samples

The *Aspergillus fumigatus* used for this study was isolated from case of infected *C. gariepinus* juvenile mortalities that were presented for bacterial, fungal isolation and identification at Aquatic Animal and Wildlife Laboratory (AAWL), Department of Veterinary Medicine, University of Ibadan.

2.2 Fungal Isolation and Identification

The swabs from homogenized tissues of topically moribund juvenile *C. gariepinus* were streaked on Sabouraud Dextrose Agar (SDA) incubated at 28-30 °C. Growth of colony was observed in 3-4 days. For full growth of colony, plates were kept for 8-10 days for incubation [4]. The isolated fungi were macroscopically examined for their morphological characteristics [5]. Slides were prepared from each colony by taking small tuft of mycelium and stained with Lacto-phenol

cotton blue. The slides were observed under microscope. Identification of fungi using the above procedure was reported [4].

2.3 Experimental Infection

One hundred and forty healthy eight-weeks old fingerlings with an average weight of 4g and 140 healthy 16 weeks old *C. gariepinus* juvenile with an average weight of 10g were collected commercial fish farm in Ibadan and transported transported under hygienic condition to the Fish and Aquatic Animal Medicine Unit, Department of Veterinary Medicine, University of Ibadan.

Comment [G3]: delete

The fingerlings and juvenile were randomly divided into seven groups each of 20 fish. Seven (7) Experimental tanks of five liters each were used for grouping the fishes. The fingerlings were labeled as F1 (control), F2, F3, F4, F5, F6 and F7 while juvenile were labelled J1 (control), J2, J3, J4, J5, J6 and J7 respectively. The microbial analysis and the aflatoxin analysis of the commercial feed samples fed to fingerlings and juvenile were carried out.

Pure cultures of identified fungi were prepared and maintained on Sabouraud Dextrose Agar (SDA) at $28\pm 2^{\circ}\text{C}$ and spore suspension was prepared for inoculation. The spores were taken gently from 8-10 days old colony by sterile loop and transferred aseptically in a test tube containing sterile distilled water. The fungal suspension was counted by haemocytometer and suspension was diluted by Phosphate buffer solution to reach 3.2×10^6 spores/ml for *Aspergillus fumigatus* used for pathogenicity test. Six groups were infected by immersion in water containing 3.2×10^6 spores/ml of the fungi at the rate of 2ml/L and 5ml/L as follows for fingerlings and juvenile respectively. After three days of infection, half of the water was replaced at 24-hour interval to further ensure good water quality [6]. The Total Hardness, Ammonia, Nitrite, pH and

Dissolved oxygen concentration of the water was monitored and recorded at 7 days interval during the course of this study [6].

The experimentally-infected fishes were observed daily for 14 days. Clinical signs, organ lesions, and mortalities were monitored, meanwhile organs such as skin, liver and kidney were submitted for histopathological procedure using H and E stain.

2.4 Statistical analysis

The water quality parameters in different tanks during experimental infection trial with fungal spores were determined and the analysis of variance (ANOVA) was used to determine the level of statistical significance. The analysis of variance (ANOVA) was also used to determine the level of significance in mortality rate during experimental infection, a 'p' value equal to 0.05 ($p = 0.05$) was considered as significance.

3.0 Results and Discussion

Aspergillus fumigatus isolated in this study has green spiked conidia, the size of conidia is 2.5 μ m. The conidia have smooth surface and small spikes covering its surface. The conidia were produced in column chains that are basipetal from green phalides 6 by 2 μ m (Figure 1).

The physicochemical findings such as Total hardness, ammonia, nitrite and pH were not significantly different in control tank, infected fingerlings and juvenile, meanwhile Dissolved Oxygen was significantly ($p = 0.43$) higher in control tank in comparison to infected fingerlings and juvenile tanks (Table 1). Moreover, mortality rate was significantly ($p = 0.40$) higher in infected fingerlings than infected juvenile at day 7 and 14 respectively (Table 2).

The gross lesion observed during experimental infection of fingerlings and juveniles included exophthalmia, atrophied barbel, congested trunk kidney, hyperemia of the gills filament, and skin depigmentation (Figure 2 and 3).

The histopathological organ changes caused by *Aspergillus fumigatus* were obvious in the liver and gill. Vacuolar degeneration of hepatocytes and necrosis of some melanomacrophage cells (Figure 4), in addition, severe erosion of the primary and secondary lamellae was observed in infected juvenile (Figure 5).

This study reported pathogenicity of *Aspergillus fumigatus* in cultured *Clarias gariepinus* fingerlings and juvenile. The findings of this study are consistent with the findings of Olufemi *et al.*, [7] who reported Aspergillomycoses in cultured Tilapia from Kenya and also reported *Aspergillus* as pathogen of cultured fishes. The gross lesion observed in this study was consistent with findings of Iqbal & Mumtaz, [8], who reported epithelial desquamation which displayed erosion finally led to ulceration in the infected area of skin of *Channa punctatus* with *Aspergillus* sp. In the same vein, the external gross lesions of infected fishes in this study were also similar to report of Chauhan *et al.*, [9], who reported that caudal region of fishes was most infected area (53%) then head region (29%), fins (10%) and minimum infection was found in gills (8%). The mortality rate significantly ($p = 0.43$) lower than mortality rate observed in the study of Chauhan *et al.*, [9] who reported 100% mortality in infected fishes with *Aspergillus fumigatus*, and this may be due to species difference.

Growth of colony of *Aspergillus fumigatus* observed in this study showed maximum growth within 10 days duration full colony growth, similar growth pattern was previously reported with *Aspergillus sydowii* [10].

Comment [G4]: this reference is not suitable as fungal growth in tilapia skin differ from clarias as tilapia have skin scales that differ in attachment and lesion appearance

The histopathological organ changes observed in this study was comparable to reports of of Iqbal et al, [11], who reported *Aspergillus* infection in gill resulted in damage of secondary lamellae and this may be source of respiratory problems.

Chauhan et al., [12] also indicated loss of muscular cells, epidermal layer with complete necrotization of dermis and hypodermis in the infected *Channa maurilus* muscle and skin with *Aspergillus* sp, and these similar to the result of this study. The infected gills of fingerlings in this study showed severe lamellae atrophy, this is similar to report of Rao [12] who observed atrophy of secondary gill lamellae and hypertrophy and hyperplasia of primary gill lamellae in infected fish with *Aspergillus* sp.

Studies on pathogenicity tests of *Aspergillus spp* in the tropical fishes are very rare. 3.2×10^6 spores/ml of the fungi at the rate of 2ml/L and 5ml/L for fingerlings and juvenile was found pathogenic to all the challenged fishes and death of most of the fishes within seven days .These findings are comparable with the reports of Chauhan et al., [9] who reported pathogenicity of three species of *Aspergillus* including *Aspergillus fumigatus* in nine different species of fishes and death within ten days, likewise Shristava [13] reported pathogenicity of *Aspergillus* on fresh water fishes and death within ten days. Refai *et al.*, [2] also confirmed *Aspergillus* as pathogenic fungi for fish with their histopathological findings. Present study is in agreement with this view and pathogenic nature of *Aspergillus spp*. was confirmed by re-isolation of fungi from body of experimentally challenged fishes.

The presence of *Aspergillus* in African catfish sample is of great significance in view of food safety and quality. *Aspergillus* sp. are common in air and soil, and their presence in fish samples might contain metabolites produced by them, that may make the fish consumption hazardous to

human health. Similarly, Mitchell [14] mentioned that the potency of these metabolites is not affected by cooking and may cause severe or fatal damage to the liver and kidney.

Comment [G5]: of human

5.0 Conclusion

Aspergillus fumigatus causes high mortality in fingerlings and juvenile of African Catfish (*Clarias gariepinus*). There were certain toxins present in given species of fungi which cause pathogenesis in fish leading to histopathological lesions, and varying degree of destruction in the tissue resulted into mortality of fish.

Ethical Approval

Ethical approval was obtained from the Ethical Committee, Faculty of Veterinary Medicine, University of Ibadan, Nigeria, ethical code number 02/2/21

REFERENCES

Comment [G6]: need recent references

- 1) Fadaeifard F, Raissa M, Bahrami H, Rahim, Ei, Najafipoor A. Freshwater Fungi Isolated from Eggs and Brood stocks with an Emphasis on *Saprolegnia* in rainbow Trout Farms in West Iran. *Afri J Microbiol.* 2011;4(22) 3647-3651.
- 2) Refai MK, Laila A, Mohamed, Amany M, Kenawy, Shima El-S.M.A. The assement of mycotic settlement of fresh water fishes in Egypt. *J of American Science.* 2010;6(11).
- 3) Olufemi BE, Roberts RJ. Induction of clinical aspergillomycosis by feeding contaminated diet to tilapia, *Oreochromis niloticus*. *J of Fish Dis.* 1986; 9, 123-128
- 4) Chauhan RLBH, Lone S, Beigh AH. Pathogenecity of three species of *Aspergillus* (*A. fumigatus*, *A. niger* & *A. sydowii*) on some fresh water fishes. *Life Sci Leaflets.* 2014;48, 65-72.
- 5) Atawodi JC, Yola IA, Kawo AH, Abdullahi BA. Fungi associated with african mudfish (*Clarias gariepinus*, Burchell 1822) in selected fish farms and dams in Zaria and its environs, Kaduna State, Nigeria. *Bayero J of Pure and Applied Sci.* 2017;10(1), 642-646.

- 6) Remilekun OA, Oladosu GA, Oladele OOI. Causal factors of mass mortality of hatchery reared *Clarias gariepinus* fry during exogenous feeding. *Int J Fish Aquat Stud*. 2021;9(1):235-239
- 7) Olufemi BE. The *Aspergilli* as pathogen of cultured fishes. In: *Recent Advances of Aquaculture*. 1985;193–218
- 8) Iqbal Z, Mumtaz R. Some fungal pathogens of an ornamental fish, Black Moor (*Carassius auratus* L.). *European J of Vet Med*. 2013;1, 1-10 ISSN 2051-297X
- 9) Chauhan RLBH, Lone S, Beigh AH. Pathogenicity of three species of *Aspergillus* (*A. fumigatus*, *A. niger* & *A. sydowii*) on some fresh water fishes. *Life Sci Leaflets*. 2014a;48, 65-72.
- 10) Alisa P, Garriet W, Smith, Kiho, Kim. Characterization of *Aspergillus sydowii* (Thom et Church), a fungal pathogen of Caribbean sea fan corals. *Hydrobiologia*. 2001;460: 105–111.
- 11) Iqbal Z, Sheikh U, Mughal R. Fungal infections in some economically important freshwater fishes. *Pak Vet J*. 2012a;32(3): 422-426.
- 12) Chauhan R, Ganaie SA, Lone SA. (2014b). Studies on haematological and histological manifestations of *Channa marulius* (Ham.) found infected with fungi, *Aspergillus* sp. *Biolife*. 2014b; 2, 649-654.
- 13) Shrivastava AK. Record of *Aspergillus terreus* (Thorn.) Fungi as fish pathogen. *Indian J of fish* 1996;43, 2,203-204.
- 14) Mitchell TG. Medical mycology. In: Jawetz, Melnick and Adelberg's (Eds.). *Med Microbiol* 24th Edition McGraw Hill USA. 2007;621-625.

Comment [G7]: delete



FIGURE 1 Image showing *Aspergillus fumigatus* on Sabouraud Dextrose Agar



FIGURE 2: Image of Infected juvenile showing atrophied barbel (A), bulgy eyes (B), and Skin depigmentation (C)

Comment [G8]: arrow is not on eye and bulging is not clear



FIGURE 3: Image of Infected fingerlings showing exophthalmia (A), skin discolouration (B), and atrophied barbel (C)

Comment [G9]: we need magnified and clear photo

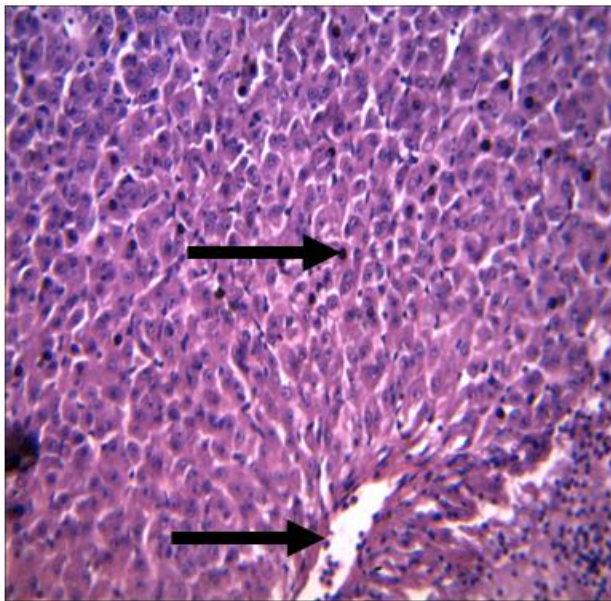


Figure 4: Vacuolar degeneration of hepatocytes and necrosis of some melanomacrophage cells (arrows) H & E X 400

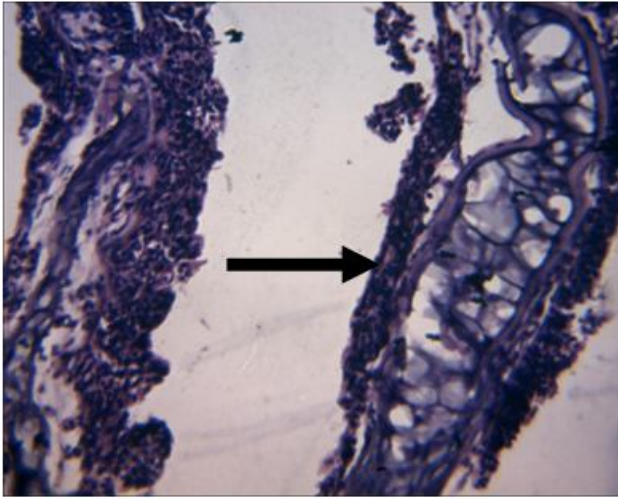


Figure 5: Severe erosion of primary and secondary lamellae (arrow)

UNDER REVIEW

Physicochemical Parameters	Control	Infected fingerlings	Infected Juvenile	Standard values for fish farming
pH	7.0±0.06	7.2±0.06	7.1±0.12	6.5 – 8.5
Total hardness (ppm)	85.0±8.9	71.0±9.3	70.4±7.2	50 – 150
Nitrite (ppm)	0.01±0.03	0.01±0.06	0.01±0.04	0.05 max
Ammonia (ppm)	0.79±0.04	0.7±0.02	0.69±0.01	2.0 max
Dissolved Oxygen (ppm)	7.0±1.20 ^a	4.5±1.44 ^b	4.0±1.73 ^c	5.0 min

TABLE 1 PHYSICO-CHEMICAL ANALYSIS OF WATER IN THE FISH TANKS DURING EXPERIMENTAL INFECTION

Values with different superscript along the row indicate significance ($p = 0.43$) - ANOVA

TABLE 2 MORTALITY RATE OF EXPERIMENTALLY INFECTED FISH WITH ASEPERGILLUS FUNMIGATUS

Experimental Groups	Day 7 (Percentage Mortality)	Day 14 (Percentage Mortality)
Control Fingerlings	0 ^a	0 ^a
Infected Fingerlings	60 ^b	80 ^b
Control Juvenile	0 ^a	0 ^a
Infected Juvenile	28 ^c	62 ^c

Values with different superscript along column indicate significance ($p = 0.40$) – ANOVA