Case study

ADULT COLOCOLIC INTUSUSSCEPTION SECONDARY TO LIPOMA – ENTEROTOMY OVER RESECTION – A DIFFERENT APPROACH

ABSTRACT

Intussusception occurs when a proximal segment of the gastrointestinal tract, called intussusceptum, telescopes into the lumen of an adjacent segment, also known as intussuscipiens. Intussusception is a serious and potentially life-threatening condition that requires immediate medical attention. In adults, it is often caused by a lead point, such as a tumor, polyp, or other abnormal growth in the gastrointestinal tract.

Diagnosis of intussusception in adults is often challenging due to the lack of specific symptoms and because it is a rare condition in adults.

In diagnosing this, a thorough history and clinical examination, as well as supplementary assistance with investigations, are all beneficial. A strong index of suspicion and a multidisciplinary approach are required for timely care. Current guidelines stipulate reduction and resection if necessary of small bowel adult intussusceptions, and resection without reduction of large bowel intussusceptions. With a review of the literature, we provide an interesting case that demonstrates the rarity and severity of this illness and provide a different

method than is otherwise promoted under literature for management of adult colocolic intussusceptions secondary to lipomas.

Key Words Adult colocolic intussusception · Colon · Lipoma · Computed tomography scanning · Colonoscopy · Literature review ·

INTRODUCTION

Adult intussusception is rare, representing only 1–5% and 5% of all bowel obstructions and intussusceptions, respectively. A definable lead point is common in 70–90% of adult intussusceptions, as opposed to paediatric intussusception, which is idiopathic in 90% of cases. The exact pathophysiology is not known, a plausible explanation being that if a lesion is present within the lumen, with the presence of food and peristaltic activity there is a narrowing above the stimulus and relaxation below, thus making the lead point telescope to the distal bowel [1]. Adult intussusception usually presents with subacute or chronic nonspecific symptoms. Therefore, the diagnosis is usually missed or made with a delay in the operating room. Most adult intussusceptions require surgical intervention with resection due to intraluminal lesions. However, there is controversy on whether to resect, the amount to be resected and if intussusceptions should be reduced, as there is a significant risk of malignancy regardless of anatomic site [1, 2]. The diagnosis and therapeutic management of factors causing intussusception in adults has recently been made more feasible with the availability of imaging modality of multislice contrast-enhanced computed tomography (CECT). We report a rare case of colonic lipoma presenting with intussusception diagnosed by CT scan and confirmed by histopathology, with a brief review of the literature.

Case Report

A 48 year old gentleman presented with a 1-month history of intermittent right upper quadrant pain radiating to the umbilicus after around 1 h of eating food. The pain was insidious in onset, dull-aching in character, gradually progressive, waxing and waning in intensity, aggravating after meals and with no significant relieving factors. He also had decreased appetite, without any significant weight loss over the past 6 months. Patient gave history of intermittent passage of reddish, mucous stools at least 4 times over the past 1 month. History of passage of 5-6 episodes of loose stools over past 7 days was also elicited.
He denied any chills, fevers, nausea or vomiting. Patient had no prior significant medical or surgical history, and no family history of colon cancer. Patient is addicted to chewing tobacco and smoking cigarettes occasionally.

At the time of presentation to the emergency room, his temperature was 98.1°F, blood pressure 118/78 mm Hg, pulse 70 beats per minute, respiratory rate 14 breaths per minute and oxygen saturation 99% while breathing room air.

On abdominal examination, he had appreciable bowel sounds with mild tenderness over the right sided flanks and lumbar region and no palpable abdominal mass.
Laboratory tests were within the normal range: blood cell count 6400/µl, hemoglobin 11.4 g/dl (mild anemia), with normal serum urea-creatinine and serum bilirubin levels.

CECT (Abdomen + Pelvis) was advised for this patient.

Abdominal CT scan showed crescentic bowel loops seen in midline outer transverse and inner ascending colon and hepatic flexure s/o intussusception for 15.16 cm length with lead point being well-defined mass lesion measuring 7*3.2 cm with central non-enhancing hypodensity (HU 70) s/o fat, with peripheral enhancing 4mm rind of soft tissue s/o capsule, lesion s/o lipoma. Proximal bowel loops were minimally dilated. Rest of the bowel loops were apparently normal.

Colonoscopy was performed to further evaluate the lead point of the intussusception, and at 70 cm from IC junction approx. 4.5 cm intussuscepted segment was noted with lead point being a lipomatous mass with pedicle at the hepatic flexure and ascending colon, and colonoscopic pneumatic reduction was achieved during this sitting, which was confirmed on serial USG.

Patient was kept under observation for any recurrence of pain or abdominal discomfort, and was re-evaluated when he complained of the same with USG, with USG suggestive of 4*3.5 cm well-defined hypoechoic lesion in epigastric region in large bowel loops s/o lipoma with involvement of mucosa and submucosa (likely transverse colon) with pedicle of 1.8 cm involvement, with e/o bowel within bowel appearance in right hypochondrium giving target sign on transverse scan with approx. length 2.2 cm likely s/o intussusception (colocolic).

Based on these findings and recurrent abdominal pain, patient was posted for exploratory laparotomy SOS procedure.

The patient's operative details were as follows –
Midline exploratory laparotomy incision was taken extending from xiphisterum to the umbilicus and abdomen was opened in layers.
IOE – Ascending colon intussuscepting into the Transverse colon over a length of approx. 13-15 cm.
Soft mobile intraluminal 6*4*2 cm mass acting as lead point noted inside the ascending colon.
Enterotomy was done over the antimesenteric border of ascending colon over a length of approx. 5 cm and the lead point confirmed to be a soft, mobile intraluminal mass of above mentioned dimensions with stalk of approx. 1.5-2 cm length extending into submucosal region.
Excision of this mass done and submucosa along with enterotomy site repaired in double layers.
The postoperative course was uneventful, and patient was discharged after 7 days in good general condition with no complaints.
Histopathological examination of the mass revealed mature adipose tissue with thin fibrocollagenous septae s/o 6.4*4*2.5 cm colonic lipoma.

DISCUSSION

Intussusception is an uncommon cause of intestinal obstruction in adults. Most lead points in the small bowel are benign lesions compared to the large bowel, 66 and 30%, respectively, with the most common malignant tumors in the colon being adenocarcinomas. Chronic abdominal pain is the most common clinical feature of adult intussusception. [1, 2, 4] The least common presenting sign on physical examination was palpable abdominal mass [8, 12]. Cases presenting with palpable abdominal mass (24-42%) necessitate caution as patient may

have bowel strangulation (presence of constitutional symptoms being the warning sign). The differentials for such a mass palpable only when patient exhibits symptoms are usually volvulus and intussusceptions (8, 12).
Diagnostic workup with abdominal X-rays in intussusception is mostly obsolete, though it may sometimes show signs of intestinal obstruction. The most sensitive study to diagnose intussusception is abdominal CT, which provides a diagnostic accuracy of 83%. CT scans show target or sausage sign on transverse view, and pseudokidney appearance on longitudinal view. Early intussusceptions show target sign with enveloped eccentric areas of low density, while late intussusceptions show layering due to longitudinal compression and ischemia of intussusception. [6, 7, 8]
Supportive evidence towards the favourable use of colonoscopy for diagnosis and biopsy is also on the rise.
Certain pre-operative risk factors have now been identified – namely, anaemia and site of bowel involved that are useful independent predictors of the nature of the lesion – benign or malignant. Presence of anaemia predisposes towards a malignant lesion, presumably due to bleeding from malignant lesions, while large bowel lesions are presumed malignant as most of the driving foci herein are of malignant aetiology. [8]

CONCLUSION –

Decision to undertake only resection of the mass and not right hemicolectomy as is desirable in such cases was based on the following points –
Strong preoperative radiological evidence pointing towards lipomatous character of lesion.
Prior colonoscopic evaluation demonstrating no suspicious lesions/polyps.
Presence of well-defined capsule over the mass.
Intraoperative soft freely mobile mass with no foci of hardness/calcifications palpable.
Intraoperative evidence of peripheral vascularity around stalk of the lesion and demonstration of no central vascular strands during dissection.
Intraoperative cut section of the mass demonstrating capsule, and lipomatous lobulated yellowish contents with no obvious calcifications/necrosis/altered morphology.

The diagnostic value of CT scan is invaluable in adult colocolic intussusceptions. Colonoscopy may be a useful tool for evaluating intussusception, particularly when symptoms of large bowel obstruction are present [2, 6]. Colonoscopy is also useful in assessing obstructive bowel lesions and evaluating for synchronous lesions that may be missed on CT scan. Care should be taken that colonoscope is not introduced into grossly dilated bowel lumen to avoid risk of perforation. Adult colonic intussusception generally responds unfavourably to pneumatic reduction with recurrences being more common. Surgery is the treatment of choice for colonic obstructing lesions and is usually done emergently.
Extent of resection of the bowel and whether to reduce the intussusception or not is still controversial. The current consensus is that exploratory laparotomy should be mandatory in adult intussusceptions. Small bowel intussusceptions are generally the result of benign pathologies, and can be resected, with trial of reduction undertaken under circumstances in which large lengths of the bowel are susceptible to reduction with 6-8 feet of the small bowel being safely resectable in a small bowel intussusception. Endoscopic reduction can be considered if a benign lesion has been identified by imaging or colonoscopy with/without histopathological confirmation through biopsy. If the colon is involved, it is safer to resect

and not reduce the intussusception as there is risk of transperitoneal seeding and venous embolization of underlying malignancy. [3] This idea has been challenged recently.
The argument proposed is that tumour cells are always flowing out of primary lesions, and the reduction of intussusception causes little damage to the intestinal mucosa. Preoperative reduction serves several functions, including avoidance of emergency surgery, allowing radical surgery for cancer, and reducing the extent of the intestinal resection. Careful radiologic or endoscopic evaluation can detect strangulated intussusception that is impossible to reduce preoperatively. These observations have resulted in a shift in the clinical paradigm for reducing intussusception and this shall likely become a standard approach because it offers greater benefits than traditional methods.

However, in a subset of cases, when a high margin of accuracy exists, coupled with colonoscopy and SOS frozen section of the mass or prior HPE reporting, total right hemicolectomy or similar high risk major surgeries may be avoided with simple resection of the mass by open or colonoscopic approach. Further confirmation of the diagnosis could be supported by preoperative HPE of the mass with polypectomy on confirmation of diagnosis, intraoperatively on frozen section analysis of the resected mass and postoperatively on immunohistochemistry. It is advisable for the patient to undergo follow-up colonoscopies on a 6 monthly basis for at least 3 years in such a scenario.

REPORTING CHECKLIST
The authors have completed the reporting checklist.

DATA SHARING STATEMENT
None needed

ETHICAL STATEMENT
-The authors are accountable for all aspects of the work in ensuring that questions related to the accuracy or integrity of any part of the work are appropriately investigated and resolved.
-A Written informed consent for publication was obtained.
-The study (Case report) conformed to the provisions of the Declaration of Helsinki (as revised in 2013).

References –

1. Azar T, Berger DL. Adult Intussusception. Annals of Surgery. 1997 Aug 1;226(2):134

2. Weilbaecher D, Bolin JA, Hearn D, Ogden W. Intussusception in adults. The American Journal of Surgery. 1971 May;121(5):531–5.

3. Wang, L.-T., Wu, C.-C., Yu, J.-C., Hsiao, C.-W., Hsu, C.-C., & Jao, S.-W. (2007). Clinical Entity and Treatment Strategies for Adult Intussusceptions: 20 Years' Experience. Diseases of the Colon & Rectum, 50(11), 1941–1949.

4. Eisen LK, Cunningham JD, Aufses AH. Intussusception in adults: Institutional Review. Journal of the American College of Surgeons. 1999 Apr;188(4):390–5

5. Wang N, Cui X-Y, Liu Y, Long J, Xu Y-H, Guo R-X, et al. Adult intussusception: a Retrospective Review of 41 Cases. World Journal of Gastroenterology. 2009 Jul 14;15(26):3303–8.

6. Gupta RK, Agrawal CS, Yadav R, Bajracharya A, Sah PL. Intussusception in adults: Institutional Review. International Journal of Surgery. 2011;9(1):91–5.

7. Goh BKP, Quah H-M, Chow PKH, Tan K-Y, Tay K-H, Eu K-W, et al. Predictive Factors of Malignancy in Adults with Intussusception. World Journal of Surgery. 2006 Jun 13;30(7):1300–4.

8. Gayer G, Apter S, Hofmann C, Nass S, Amitai M, Zissin R, et al. Intussusception in adults: CT diagnosis. Clinical Radiology. 1998 Jan;53(1):53–7.

9. Honjo H, Mike M, Kusanagi H, Kano N. Adult Intussusception: A Retrospective Review. World Journal of Surgery. 2014 Sep 6;39(1):134–8.

10. Nagorney DM, Sarr MG, McIlrath DC. Surgical Management of Intussusception in the Adult. Annals of Surgery. 1981 Feb;193(2):230–6.
11. Sarr MG. Postoperative Intussusception in the Adult. Archives of Surgery. 1981 Feb 1;116(2):144.

PHOTO GALLERY

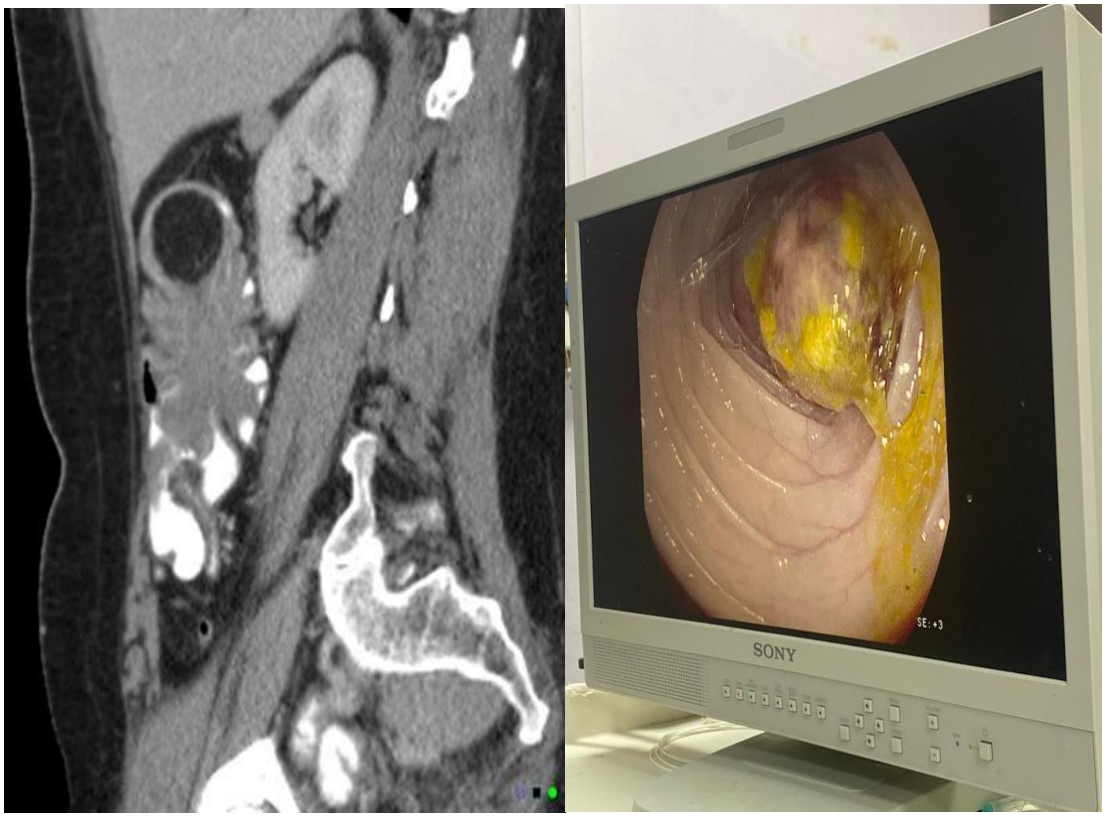

FIG (1) Colo-colic Intussusception secondary to lipoma
FIG (2) Colonic lipoma visulaised on colonoscopy

FIG (3) Intra-op evidence of lead point with stalk with no other evident pathology
FIG (4) Resected specimen with no evidence of haemorrhage or necrosis

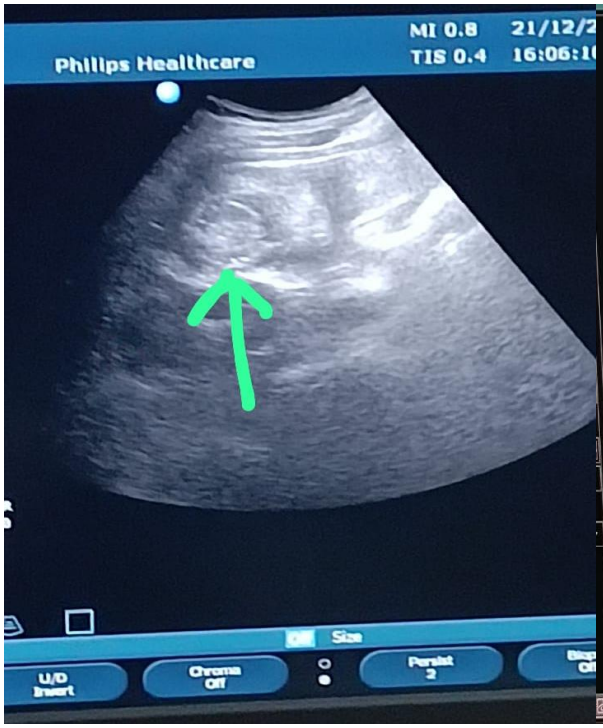

FIG (5) USG s/o Target Sign s/o intussusception
FIG (6) Abdominal erect X-ray s/o non-specific findings

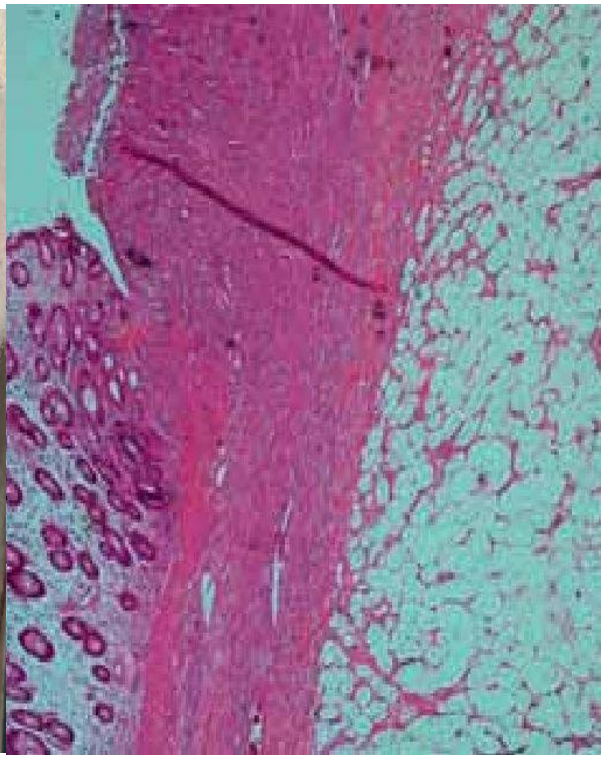

FIG (7) Cut section of lead point s/o lipoma with no evidence of necrosis or hemorrhage
FIG (8) Mcroscopic examination s/o benign lesion s/o lipoma

ABBREVIATIONS AND SYMBOLS

HB- Hemoglobin
CECT- Contrast Enhanced Computed Tomography
USG – Ultrasonography
AXR – Abdomen Xray Erect
FIG – Figure
HPE – Histopathological examination