

EVALUATION OF ANTEROPOSTERIOR LIP POSITION IN DIFFERENT SKELETAL MALOCCLUSIONS

ABSTRACT

Introduction: The horizontal position of upper and lower lips have been of great concern when planning a treatment plan of an orthodontic patient, because the purpose of orthodontic treatment is to establish an esthetic facial profile and not just a functional occlusion.

Objectives: The objective of this research was to determine anteroposterior lip position in three skeletal malocclusion groups and to analyze different soft tissue lines.

Material and Methodology: This study comprised of eighty one subjects and lateral cephalographs were taken in natural head position. Five reference lines—Sushner, Steiner, Burstone, Holdway, and Ricketts were drawn after radiographs were traced. The linear measurement between the lips and the five reference lines was recorded. For statistical analysis, SPSS 21 was used.

Results: Using five soft tissue reference lines, a significant difference between the anteroposterior position of the lips in various skeletal malocclusions was discovered.

Conclusion: The skeletal malocclusion pattern was shown to be related to the sagittal lip positions. For sagittal lip position analysis, Every group of skeletal malocclusions had a different preferred reference lines.

Key words: Soft tissues; Skeletal class; Reference lines; Lips; Sagittal.

INTRODUCTION

Evaluation of the facial profile view is an essential part of comprehensive orthodontic diagnosis.¹ For the purpose of evaluating the face profile before orthodontic and orthognathic treatment planning, a cephalometric analysis of a lateral cephalometric radiograph is required. Because the external characteristics of the face in soft tissues, such as the lips, chin, and nose, do not always follow the hard tissue skeletal structure owing to variations in thickness and pattern, it is important to investigate both soft and hard tissue.² These differences between the underlying soft and hard tissues might lead to an imbalance between the position of the underlying structures and face aesthetics, which could force the need for orthognathic surgery as a form of treatment.³

Hence, the consideration of aesthetic aspects and estimation of facial profile according to soft tissues have a major role in planning orthodontic treatment.⁴ It can be considered as among one of the limitations in orthodontic treatment and also an essential decisive factor to attain success or failure of treatment.⁵ Therefore, there is a strong need for soft tissue profile analysis to identify asymmetry that is reflected in the face and to predict how changing the disrupted dentoskeletal relationships would affect the soft tissue structures.⁶

The lower face helps in respiration, digestion and speech and it also has impact to a great extent to the attractiveness and psychological prosperity of an individual.⁷ In the lower third of the face, the positioning of the lips is quite important. These are the key determinants that evaluate the positioning of the lips, the skeletal aspects, the positioning of the incisor teeth, the morphology of the nose and chin, and the thickness of the lips.⁸ The decision of treatment is strongly influenced by the position of the lips. Consequently, an orthodontic treatment might change how the lips are positioned. According to the soft tissue paradigm, lip positions have recently become one of the most relevant soft tissue assessments because they affect tooth stability and face aesthetics.⁹

Lip prominence, incompetent lips, lip fullness, lip strain, nasiolabial angle, philtrum height and labiomental angles all have a significant impact on the treatment strategy. These traits influence the choice of treatment, moving borderline instances toward extraction or no-extraction.¹⁰ The size of nose and chin has also an impact on lip prominence, very short lower anterior face height can result in inappropriate lip positions. In such cases Orthognathic surgery is desirable than camouflage.¹¹ Considerably, orthodontists have brought an attention to the horizontal position of lips as the most significant feature for people to appear beautiful and appealing. The horizontal position of the upper and lower lips has been measured using a number of parameters.¹²

In a study conducted by Merina Joshi and Li Peng Wu, it was evaluated that lip position in different malocclusions is different as per their teeth and skeletal jaw relations.⁹

There are different cephalometric lines used to assess lip positions, such as Rickett's line 'E', Steiner's line 'S' Holdaway's line 'H', Burstone's line 'B' and Sushner's line 'S2'(fig1-5).¹⁵ Orthodontists often use these lines to analyze the lips for diagnosis and treatment planning.¹³ Nevertheless, each orthodontist has a preferred reference line for determining lip positions.¹⁴ In this study along with evaluating lip position, we will also find the distribution of these lines in different malocclusion groups.

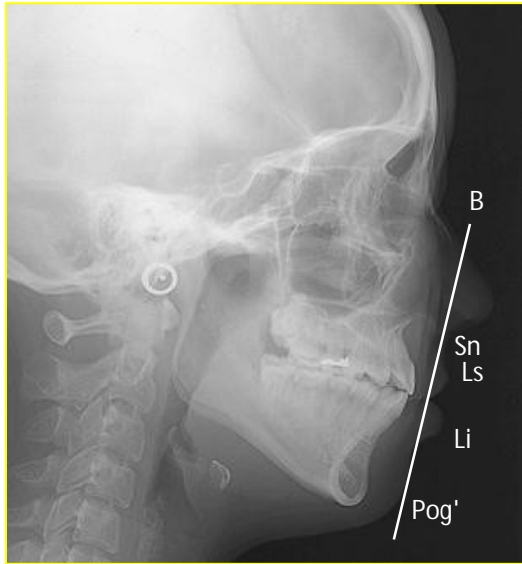


Figure 1: Steiner's S1 line.

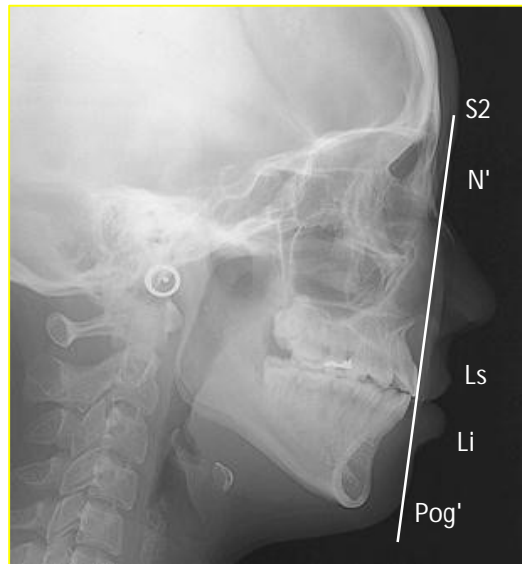


Figure 2: Rickett's E line.

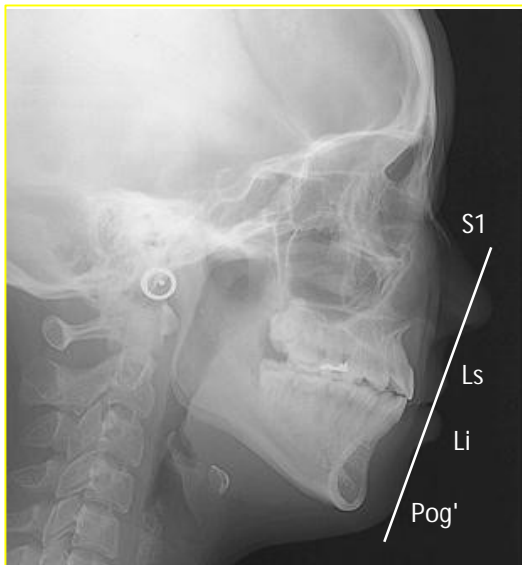

Figure 3: Burstone's B line.

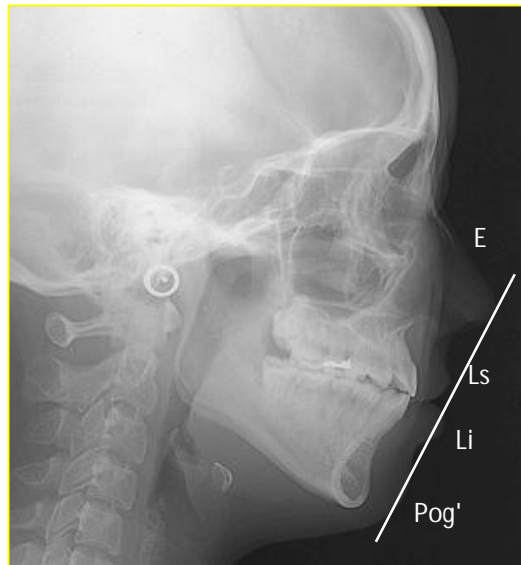


Figure 4: Sushner's S2 line.

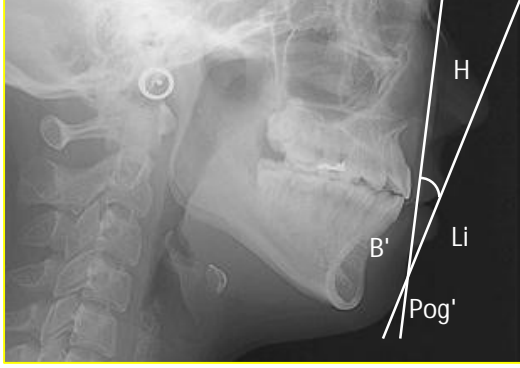


Figure 5: Holdway's H line.

MATERIALS AND METHOD

After receiving ethical permission from the hospital's Ethical Committee, this cross-sectional study was carried out in the department of orthodontics' outpatient clinic at the Liaquat University of Medical and Health Sciences' Institute of Dentistry in Jamshoro/Hyderabad. Eighty-one participants, both male and female, between the ages of 18 and 30, with a variety of skeletal malocclusions, were chosen. Patients with history of trauma in maxillofacial region, previous orthognathic surgery, previous orthodontic / prosthodontic treatment and with congenital anomalies like cleft lip and palate were excluded. Written consent was received from each subject registered for orthodontic treatment. Lateral cephalometric X-rays were taken using the established principles (1) Horizontal plane of a patient equivalent to the floor, teeth in the

central occlusion (2) comfortable position of lips (3) The X-ray reference is taken toward a distance of 150 cm as well as the target to a distance of 15 cm from the plane of film. Each radiograph was drawn on a standard 8 x 10-inch transparent acetate sheet which was positioned over through the typical illuminated observation box for tracing using pencil. Soft tissues and hard tissues structures were outlined on acetate papers. Patients were recorded in three skeletal malocclusion groups using ANB angle. Five soft tissue reference lines were drawn, **Steiner's line S1** (beginning the middle of the S-shaped curve, amid the tip of nose and subnasale towards pogonion soft tissue). **Rickett's line E** (tip of nose to pogonion of soft tissues), **Burstone's line B** (subnasale to soft tissue pogonion) **Holdways's line H** (soft tissue pogonion to upper lip). **Sushner's line S2** (soft tissue nasion to pogonion soft tissue. Linear distance between lips and these five reference lines was noted.

STATISTICS

Version 21.0 of the Statistical Package for Social Sciences was used to analyze the data (SPSS). Descriptive analysis of each variable was done. The means \pm standard deviations have been calculated for repeated measures including age, skeletal classes (ANB) and soft tissues (line S1, line E, line B, line H, line S2). Frequency as well as percentage have been determined for gender. The p value < 0.05 was known to be important.

RESULTS AND DISCUSSION

Table:1 Descriptive Statistics of E, S1, H, B and S2 Line for Upper Lip

	Mean	Range	Std	Minimum	Maximum
Rickett's E line	2.7407	13.50	2.81748	-11.00	2.50
Steiner's S line	1.1358	13	3.25482	-7.0	6.0
Burstone's B line	5.7778	10.00	2.40052	1.0	11.0
Sushner's S2 line	13.7407	20.00	4.82449	2.00	22.00

Table: 2 Descriptive Statistics of E, S1, H, B and S2 Line for Lower Lip

	Mean	Range	Sd	Minimum	Maximum
Rickett's E line	.0556	15.00	3.29678	-8.00	7.00
Steiner's S line	2.1111	14.00	3.31945	-4.00	10.00
Holdway's H line	1.9753	12.00	2.6971	-4.00	8.00
Burstone's B line	5.3827	11.00	3.1871	1.00	12.00
Sushner's S2 line	10.43211	17.50	4.385	.50	18.00

Table: 3 Skeletal Class I, II, and III Differences by Mean and Standard Deviation

	Skeletal Class I	Skeletal Class II	Skeletal Class III
UL to E line	2.5152 (± 2.07)	-1.611 (± 2.3)	-6.750 (± 2.3)
LL to E line	-.1364 (± 2.8)	1.1944 (± 3.11)	-2.833 (± 3.4)
UL to S1 line	1.6061 (± 3.20)	2.3056 (± 2.08)	-3.667 (± 1.77)
LL to S1 line	1.8788 (± 2.7)	3.027 (± 3.61)	.000 (± 2.89)
UL to S2 line	13.4848 (± 2.9)	16.6111 (± 3.6)	5.8333 (± 2.4)
LL to S2 line	9.8333 (± 3.7)	12.3333 (± 4.30)	6.3750 (± 3.05)
LL to H line	.8788 (± 2.3)	2.8889 (± 2.8)	2.2500 (± 2.05)
UL to B line	5.8485 (± 2.5)	6.2917 (2.03)	4.0417 (± 2.22)
LL to B line	5.0303 (± 2.9)	6.0000 (± 3.46)	4.5000 (± 2.81)

Table 1 and 2 shows descriptive statistics with mean and standard deviation of E line (UL 2.74 ± 2.8 and LL 0.55 ± 3.29), S1 line (UL 1.13 ± 3.25 and LL 2.11 ± 3.31), H line (LL 1.97 ± 2.69), B line (UL 5.77 ± 2.4 and LL 5.38 ± 3.18) and S2 line (UL 13.7 ± 4.82 and LL 10.43 ± 4.38). Table 3 shows statistically significant differences in class I, II and III.

In three distinct skeletal malocclusions, the horizontal lip positions in relation to the five reference lines were determined during this study. To better comprehend the relationship between gender and skeletal basis differences on the lips, which are important for face equilibrium, various approaches to analyze lip positions and thickness were applied.^{16,17} Soft tissues, as well as hard tissues influence the evaluation of orthodontic treatment success. Many authors prefer reference lines that do not include the tip of the nose because they eliminate the influence of the nose's size.^{18,19} Because the most of facial growth ceases typically between the ages of 16 and 17, the sample comprised adults aged 18 to 30.^{20,21} The people who had lateral cephalometric radiography for diagnosis were the ones who were selected as participants. Assessment centered on attractive profiles and acceptable occlusion is subjective and introduces biases. They however don't reflect the population's randomized representation. As a result, it's critical to examine these soft tissue reference lines in a variety of skeletal malocclusions types to see the most accurate.^{22,23}

Soft tissue analysis varies by demographic, according to Erbay et al every ethnicity has its specific distinct nose and chin features.^{24,25} Sushner established black population standards. Ricketts standards apply just to Caucasians, not to all ethnicities. Therefore, it would have been incorrect to use soft tissue criteria from one population while diagnosing and treating another species. The validity of these reference lines could have been tested among Jamshoro's adult population. The planning of orthodontic diagnosis and treatment would start with this

information. In this study five reference lines are selected in this investigation because they are the most commonly used during treatment and diagnosis. Upper lips in the skeletal class III group were found to be more retrusive than in the skeletal class I and class II groups, while lower lips were found to be more protrusive than in the skeletal class I and class II groups. In correlation to the skeletal class I and class III groups, all of the reference lines in the skeletal class II group indicated that the upper lips were the most protrusive and the lower lips were the most retrusive. There was a statistically considerable correlation between the three skeletal groups for the upper lip and the S2 line. H line showed statistically significant variances in all skeletal groups in the lower lip illustration. The S2 line can be used to decide the sagittal position of upper lip in various situations. H line is the preferred line for lower lip sagittal position. This might be as a result of the S2 line being close to the skeleton and being unaffected by the nose. Because upper lip position has a strong impact on the lower lip, H line is most ideal line to use when analyzing lower lip position. Statistically Due to a variety of variables, cephalometric measures of the face in terms of aesthetics can be complex and deceptive. Multiple investigations have found a significant relationship between soft and hard tissue characteristics. Facial symmetry and equilibrium are frequently affected or balanced in respect to the skeletal, soft tissue and dental aspects of the face.²⁴ Dental factors including the angle of the upper and lower anterior teeth in relation to the mandibular and palatal planes, respectively, have an effect on lip position.²⁶ Changes in the positioning of the upper lip in the horizontal position were significantly influenced by changes in the cervical point of the upper incisors or incisor retraction with translation. Since many of the vertical analysis considered in face examination either via the nose or chin, the size and morphology of the nose and chin would have a big influence on lip position.²⁷ The selection between the two major treatment modalities, extraction and non-

extraction, is heavily influenced by the patient's characteristics. When dealing with borderline cases, the debate becomes far more heated. In class I situations, crowding of upper and lower anterior teeth, lower lip to E line and overjet frequently have an impact on the extraction decision. These four fundamental orthodontic parameters may vary between groups.

CONCLUSION

- The upper and lower lips of the skeletal class I group are protrusive more than average in all reference lines.
- Comparing skeletal class I and III, skeletal class II has a more protruding top lip and retruding lower lip.
- Comparing skeletal class II and I, skeletal class III has the most protruding lower lip.
- In profile analysis, the S2 line is the preferred line for figuring out how the lips are positioned horizontally in skeletal class I and II, while the B line is the line of interest for figuring out how the lips are positioned anterioposteriorly in skeletal class III.

Ethical Approval:

As per international standard or university standard written ethical approval has been collected and preserved by the author(s).

Consent

As per international standard or university standard, patients' written consent has been collected and preserved by the author(s)

REFERENCES

1. Asad S, Awaisi ZH, Bokhari F. Patient's dento-facial motivations for orthodontic treatment: A questionnaire study. *Pakistan Orthodontic Journal*. 2011 Dec 31;3(2):53-6.
2. Jan A, Rehman H, Taifur N, Bangash AA. Correlation between nasolabial angle and maxillary incisor inclination. *Pak Armed Forces Med J*. 2015 Dec;65(0):236-39.
3. Hussein E, Al Khateeb S, Watted N, Aksoy A, Acar A, Mowais MA. Evaluation of facial soft tissue parameters for Palestinians using Holdaway analysis. *The Saudi dental journal*. 2011 Oct 1;23(4):191-5.
4. Rasool G, Hussain T, Hussain U, Shah AM. Comparisons of soft tissue chin thickness in adult patients with various mandibular divergence patterns. *Pak Ortho J*. 2016;8(1):53-57.
5. Rehan A, Iqbal R, Ayub A, Irshad A. Soft tissue analysis in class I and class II skeletal malocclusions in patients reporting to department of Orthodontics Khyber College of Dentistry Peshawar. *Pak Oral & Dent J*. 2014 Mar 1;34(1):87-90.
6. Joshi M, Wu LP, Maharjan S, Regmi MR. Sagittal lip positions in different skeletal malocclusions: a cephalometric analysis. *Prog Orthod*. 2015 Dec 1;16(1):8.
7. Kurkcuoglu A, Bozdog ZK, Oguz O. Evaluation of the Lips' Positions in Adolescent Class I Individuals According to Gender. *The Medical Bulletin of Şişli Etfal Hospital*, 50(2)2016:124-130.
8. Asad S, Kazmi F, Mumtaz M, Malik A, Baig RR. Assessment of Antero-posterior position of lips: E-Line-S-Line. *Pak Oral & Dent J*. 2011 Jun 1;31(1):84-87.
9. Rehan A, Iqbal R, Ayub A, Irshad A. Soft tissue analysis in class I and class II skeletal malocclusions in patients reporting to department of Orthodontics Khyber College of Dentistry Peshawar. *Pak Oral & Dent J*. 2014 Mar 1;34(1):87-90.

10. Bravo, L.A, et al., Comparison of the changes in facial profile after orthodontic treatment, with and without extractions. *British journal of orthodontics*, 1997. 24(1): p. 25-34.
11. Erdinc AE, Nanda RS, Dandajena TC. Profile changes of patients treated with and without premolar extractions. *American Journal of Orthodontics and Dentofacial Orthopedics*. 2007 Sep 1;132(3):324-31.
12. Berneburg M, Dietz K, Niederle C, Göz G. Changes in esthetic standards since 1940. *American Journal of Orthodontics and Dentofacial Orthopedics*. 2010 Apr 1;137(4):450-e1.
13. Rigsbee 3rd OH, Sperry TP, BeGole EA The influence of facial animation on smile characteristics. *The International Journal of adult Orthodontics and Orthognathic surgery*. 1988 Jan 1;3(4):233-9.
14. Saxby P.J. and Freer T.J. 1985. Dentoskeletal determinants of soft tissue morphology. *Angle Orthodontist*. 55: 2: 147 – 154.
15. Al-Saleem NR. Comparison of lip analyses in skeletal class I normal occlusion and class II division 1 Malocclusion. *Al-Rafidain Dental Journal*. 2013 Apr 1;13(2):192-201.
16. Hwang HS, Kim WS, McNamara Jr JA. Ethnic differences in the soft tissue profile of Korean and European-American adults with normal occlusions and well-balanced faces. *The Angle Orthodontist*. 2002 Feb;72(1):72-80.
17. Baccetti T, Franchi L, McNamara JA. Reproducibility of the CVM method: a reply. *American Journal of Orthodontics and Dentofacial Orthopedics*. 2010 Apr 1;137(4):446-7.
18. Holdaway RA. A soft-tissue cephalometric analysis and its use in orthodontic treatment planning. Part I. *American journal of orthodontics*. 1983 Jul 1;84(1):1-28.
19. Björk A. Prediction of mandibular growth rotation. *American journal of orthodontics*. 1969 Jun 1;55(6):585-99.

20. Hashim HA. A cephalometric study of soft tissue relationship among Saudi female dental students. Saudi Dent. J. 2003;15(1).
21. Lew KK, Ho KK, Keng SB, Ho KH. Soft-tissue cephalometric norms in Chinese adults with esthetic facial profiles. Journal of Oral and Maxillofacial Surgery. 1992 Nov 1;50(11):1184-9.
22. Chan GK. A cephalometric appraisal of the Chinese (Cantonese). American journal of orthodontics. 1972 Mar 1;61(3):279-85.
23. Bass NM. Measurement of the profile angle and the aesthetic analysis of the facial profile. Journal of orthodontics. 2014 Dec 16.
24. Erbay EF, Caniklioğlu CM, Erbay ŞK. Soft tissue profile in Anatolian Turkish adults: Part I. Evaluation of horizontal lip position using different soft tissue analyses. American Journal of Orthodontics and Dentofacial Orthopedics. 2002 Jan 1;121(1):57-64.
25. Ramos AL, Tatsuei Sakima M, dos Santos pinto A, Bowman SJ. Upper lip changes correlated to maxillary incisor retraction- a metallic implant study. The Angle Orthodontist. 2005 Jul;75(4):499-505.
26. Umale VV, Singh K, Azam A, Bhardwaj M, Kulshrestha R. Evaluation of horizontal lip position in adults with different skeletal patterns: A cephalometric study. Journal of Oral Health and Craniofacial Science. 2017 Mar 10;2:9-16.
27. Noviaranny IY, Hissam NK, Bakar PA. Holdaway Soft Tissue Cephalometric Standard for Malay Adults. Compendium of Oral Science. 2022 Sep 1;9(2):44-53.