

EVALUATION OF ANTIHYPERLIPIDEMIC ACTIVITY OF *CHOEROSPONDIAS AXILLARIS* IN RATS

ABSTRACT

Background:

Choerospondias axillaris CA, known as lapsi, is a plant with constituents having therapeutic properties. All plant parts including stem, bark, root, leaves, and fruit have medicinal virtues and have had a role in Ethno-medicine since ancient times.

Objective:

The present study was designed to investigate the antihyperlipidemic activity of dried powder of *Choerospondias axillaris* fruits in Wistar albino rats.

Methods:

The anti-hyperlipidemic effect of methanolic extract of the fruit of *Choerospondias axillaris* (CA) was tested in a high-fat diet-induced hyperlipidemic rat model. Here, chronic hyperlipidemia was induced by feeding a high-fat diet for 21 days to rats. During the experiment, the rat's body weight was monitored. At the end of the study, animals among whole groups have been sacrificed and biochemical parameters such as; serum Total Cholesterol, Triglycerides, Low-Density Lipoprotein Cholesterol (LDL-C), Very Low-Density Lipoprotein Cholesterol (VLDL-C), and increase of serum High-Density Lipoprotein Cholesterol (HDL-C) were analysed.

Results:

The observed extract of *Choerospondias axillaris* was proven to be safe in the toxicity findings. Treatment with methanolic extract of CA (200 and 400 mg/kg, p.o) significantly reduced the hyperlipidemia i.e., the decline in levels of serum Total Cholesterol, Triglycerides, Low-Density Lipoprotein Cholesterol (LDL-C), Very Low-Density Lipoprotein Cholesterol (VLDL-C), and High-Density Lipoprotein Cholesterol (HDL-C) when compared to vehicle control and standard drug Atorvastatin (10 mg/kg). The result indicates that methanolic extract of the whole plant of *Choerospondias axillaris* possessed significant antihyperlipidemic activity.

Conclusion:

After all the investigation it was found that oral administration of *Choerospondias axillaris* fruit extract at a low dose of 300mg/kg and a high dose of 600mg/kg against the high-fat diet-induced hyperlipidemia and it was found that a high dose was more effective as compared to low dose. The drug was able to suppress the raised parameters.

Keywords: High-fat diet, hyperlipidemia, *Choerospondias axillaris*, rats, Atorvastatin.

INTRODUCTION

“Hyperlipidemia is indicated by upraised serum levels of total cholesterol (TC), low-density lipoprotein (LDL), very low-density lipoprotein (VLDL), triglycerides and declined serum level of high-density lipoprotein (HDL)” [1]. “Hyperlipidemia is one of the greatest risk factors contributing to the prevalence and severity of atherosclerosis and subsequent coronary heart disease. The liver synthesizes two-thirds of the total cholesterol made in the body. The rate-limiting enzyme is 3-hydroxy-3-methyl glutaryl (HMG)-Co A reductase and provides feedback regulation by controlling the cholesterol concentrations in cells. Treatment of hyperlipidemia involves diet control, exercise, and the use of lipid-lowering diets and drugs” [2]. “The most commonly employed drugs for the treatment of hyperlipidemia include hydroxymethylglutarate Coenzyme A (HMG-CoA) reductase inhibitors, also called statins. Several other drugs employed as a remedy for hyperlipidemia involve bile acid sequestrants like colestipol; fibrates like clofibrate, and fenofibrate; cholesterol absorption inhibitors like ezetimibe and omega-3-fatty acids”. [3].

“Despite the availability of several drugs for the treatment of hyperlipidemia, antihyperlipidemic therapy is still deprived of efficiency and safety. For instance, there is a risk of severe muscle damage with statins, which are effective in lowering LDL” [4]. “Niacin, a good drug for lowering triglycerides, may cause hyperglycemia and may also cause liver damage” [5]. Adverse effects due to the use of fibrates often relate to the skeletal muscle, kidneys or liver. Thus, there is still a need for the development of efficient antihyperlipidemic agents. Plant products are frequently considered to be less toxic and free from side effects than synthetic ones. There are many plants reported to possess antihyperlipidemic activity in clinical studies like *Allium sativum*, *Nigella sativa* and *Plantago ovata*.

Plant information:

Choerospondias axillaris is a large, deciduous, edible native fruit tree of the Anacardiaceae family and is also known as hog plum. It is commonly known as lapsi in Nepal and India. Hog plum is a deciduous tree that can grow up to 30 meters tall, though is usually smaller. Native to

the hilly region in Nepal (850-1900 m), the tree has also been reported in India, China, Laos, Japan and east Asia. (review) Fruits are consumed fresh, pickled and processed for preparing a variety of sweet and sour, tasty food and candy^[6] Its fruits containing vitamin C, Phenol and flavonoid compounds are consumed to enhance immunity and neutralize free radicals formed in the body.^[7] Vitamin C is required to form collagen, growth, reproduction and immunity in many fishes. Ten compounds were isolated from the dry fruit of *C axillaris*.

Chemical constituents:

“Their structures were elucidated as dihydroquercetin, quercetin, protocatechuic acid, gallic acid, 3,3'-di-o-methylellagic acid, beta-sitosterol, daucosterol, stearic acid, tria contanoic acid and octacosanol by IR, EI-MS and NMR”.^[8]

Table 1: The results of TD-GC/MS of *Choerospondias axillaris*.^[9]

No.	Retention time (min)	Relative content (%)	Compound Name
1	9.275	0.64	1-(2- Butoxyethoxy)ethanol
2	11.254	1.9	Formamide, N,N-dibutyl-
3	12.086	2	2,2,4-Trimethyl-1,3-pentenediol Diisobutyrate
4	12.237	12.2	Ethanol, 2-(2-butoxyethoxy)-,
5	12.426	3.5	Propanoic acid, 2-methyl-, 3-
6	13.712	1.66	Dimethyl phthalate
7	14.544	1.35	2,4- Di-tert-butylphenol
8	15.211	2.08	Benzene, 1,2,3-trimethoxy-5-(2-
9	15.854	2.99	2,2,4-Trimethyl-1,3-pentenediol
10	16.068	2.79	Cedrol
11	17.556	0.76	Methyl tetradecanoate
12	19.61	100	1,2-Benzene dicarboxylic acid

Note: "--" this indicates that nothing is detected.

Fruits of *Choerospondias axillaris* have been reported to possess antioxidant, anti-inflammatory, cardiovascular and cytotoxic activities.^[10,11,12,13] But the effect of *Choerospondias axillaris* on hyperlipidemia has not been explored. *C. axillaris* consists of

constituents like quercetin, protocatechuic acid, gallic acid, beta-sitosterol and octacosanol that may have potent anti-hyperlipidemic properties. The present study was designed to investigate the Anti-hyperlipidemic activity of methanolic extract of fruits of *Choerospondias axillaris* on high-fat diet-induced hyperlipidemia in Wistar rats.

MATERIALS AND METHODS

Plant material

The fresh fruits of *Choerospondias axillaris* were collected from chapapani-12, Pokhara Nepal during October 2021, identified and authenticated by Professor Dr Hari Datta Bhattarai, Central Department of Botany, Tribhuvan University, Kathmandu Nepal.

Preparation of Extract

Dried fruits of the plant were powdered and subjected to batch extraction in the soxhlet apparatus. Methanol was used as a solvent for extraction. The powdered material of the fruit of *Choerospondias axillaris* was evenly packed in a Soxhlet extractor for extraction with solvent. The temperature was maintained on an electric heating mantle with thermostat control. The appearance of colourless solvent in the siphon tube was taken as the termination of extraction. The extract was then concentrated by distilling the solvent and the percentage yield was calculated. Henceforth the Methanolic extract of *Choerospondias axillaris* will be called CAM [14]

Test for phytochemical analysis

Conventional chemical tests were carried out for the extract of CAM to identify the presence of various chemical constituents. [15]

EXPERIMENTAL ANIMALS

Adult Wistar albino rats of either sex, weighing 110-150 g, were procured from Sri Venkateshwara Enterprises, Subramanyanagar, Bangalore- 560021. The animals were housed separately in groups of 6 per cage under standard environmental conditions of room temperature ($22^{\circ} \pm 2^{\circ}\text{C}$), relative humidity ($50\% \pm 5\%$) and 12 h light and dark cycle. The animals had free access to feed (commercial pellets that contain a balanced ration) and water. All the animals were acclimatized to the laboratory environment 5 days before the experiment. The experimental protocol was approved by Institutional Animals Ethics Committee and animal care was taken as per the guidelines of the Committee for Control and Supervision of Experiments on Animals (CPCSEA), Government of India. (Reg No. **KCP-IAEC/09/21-22/07/18/12/21**).

ANTI-HYPERLIPIDEMIC ACTIVITY

High Fat Diet-induced hyperlipidemic model ^[16]

Preparation of Feed

“Normal animal food pellets were crushed in mortar and pestle to crush into small pieces and then grinded into fine powder in a mixer grinder. The other ingredients i.e. cholesterol 2%, Cholic acid 1%, sucrose 40% and coconut oil 10% were added to the mixer grinder in increasing order of their quantity and mixed well. This dried powder was then mixed with the same quantity of water every time to make small balls of feed and later this was stored in self-sealing plastic covers in the refrigerator at 2°C to 8°C. The feed for the normal group was prepared similarly by grinding only the normal food pellets and then mixing them with water without the other excipients. This preparation of feed was done once in three days for all the animals. Thirty Wistar albino rats were randomly divided into five groups of six each”. ^[16] “The chronic experimental hyperlipidemia was produced by feeding the above-prepared food for 21 days. The rats are then given test plant extracts i.e. CAM (200 and 400 mg/kg, p.o) and Atorvastatin (10 mg/kg, p.o) once daily in the morning orally for 14 consecutive days. During these days, all the groups also received a fat diet in the same dose as given earlier. The hyperlipidemic control i.e. group II animals received the hyperlipidemic diet and the vehicle. The control group animals received the normal laboratory diet and vehicle”. ^[16]

Group 1: Normal Control Group – Vehicle and normal pellets were given for 21 days.
Group 2: Disease Control Group- High-fat diet, p.o. 21 days.
Group 3: Standard group - Atorvastatin (10mg/kg) for 14 days and fed with a high-fat diet for 21 days p.o.
Group 4: Methanolic extract of *Choerospondias axillaris* (200 mg/kg), p.o. and fed with a high-fat diet for 21 days. ^[17]
Group 5: Methanolic extract of *Choerospondias axillaris* (400 mg/kg), p.o. and fed with a high-fat diet for 21 days. ^[17]

“On day 15, blood was collected by retro-orbital sinus puncture, under mild ether anaesthesia. The blood was subjected to centrifugation for 15 min at 2500 rpm to obtain serum. The collected serum was analyzed for serum Total Cholesterol, Triglycerides, High-Density Lipoprotein Cholesterol, Low-Density Lipoprotein Cholesterol and Very Low-Density Lipoprotein Cholesterol” ^[18,19]

Statistical Analysis

The results are expressed as Mean \pm S.E.M from n=6 rats in each group. Data were analysed using statistical software Graph Pad Prism version 5. The significance of the difference among the groups was assessed using a one-way analysis of variance (ANOVA) followed by Tukey's test compared to Normal control (Untreated) Vs all groups with $p < 0.05$ were considered significant.

Result and discussion

Evaluation of In vivo Anti-hyperlipidemic Activity

The Control group received an equivalent volume of "vehicle" only, the Disease control group received a high-fat diet, the Standard group received Atorvastatin 10mg/kg body weight P.O. and the test drug, "*Choerospondias axillaris*" extract received a low dose of 200mg/kg and high dose 400mg/kg P.O. respectively.

The following parameters were observed post-treatment:

Body weight before (0 days) and after (21 days) of treatment.

Fig 1: Triglycerides level

Values are expressed as Mean \pm S.E.M (n=6)

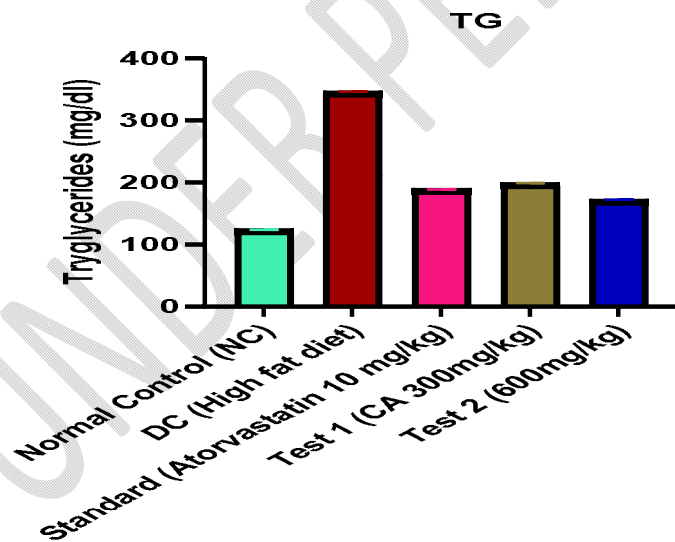


Table no 2: Statistics of Triglyceride level > Comparison between the groups: Tukey's Multiple Comparison Tests

Tukey's Multiple Comparison Test	Mean Diff.	Significant?	Summary
----------------------------------	------------	--------------	---------

		P<0.05?	
NC- Vehicle only vs. DC- (Atorvastatin 10mg/kg)	-222.5	Yes	****
NC vs Standard	-64.99	Yes	****
NC vs LD (CA 300 mg/kg)	-74.76	Yes	****
NC vs HD (CA 600 mg/kg)	-48.00	Yes	****
DC (Atorvastatin 10mg/kg) vs standard	157.5	Yes	****
DC (Atorvastatin 10mg/kg) vs LD (CA 300mg/kg)	147.8	Yes	****
DC (Atorvastatin 10mg/kg) vs HD (CA 600mg/kg)	174.5	Yes	****
Standard vs LD (CA 300mg/kg)	-9.766	Yes	****
Standard vs HD (CA 600mg/kg)	17.00	Yes	****
LD (CA 300mg/kg) vs HD (600MG/KG)	26.76	Yes	****

Fig 2: Total cholesterol level

Values are expressed as Mean \pm S.E.M (n=6)

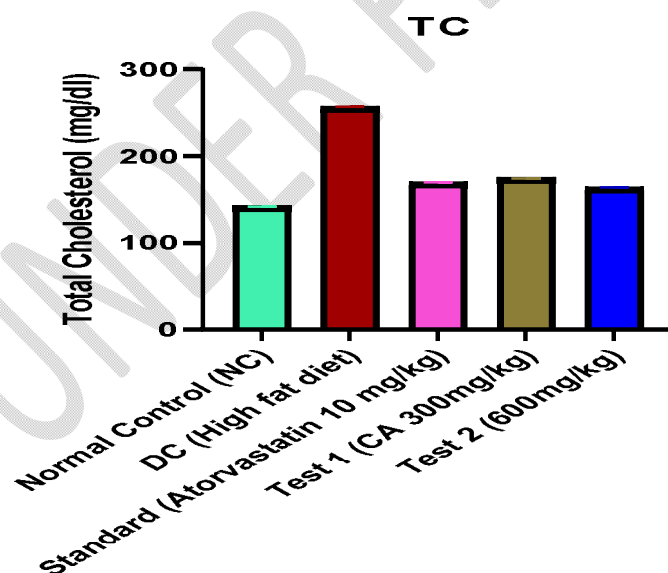


Table no 3: Statistics of Total cholesterol level > Comparison between the groups: Tukey's Multiple Comparison tests

Tukey's Multiple Comparison Test	Mean Diff.	Significant? P<0.05?	Summary
NC- Vehicle only vs. DC- (High-fat diet)	-114.7	Yes	****
NC vs Column C	-27.74	Yes	****
NC vs Test 1 (CA 300 mg/kg)	-32.51	Yes	****
NC vs Test 2 (CA 600 mg/kg)	-22.00	Yes	****
DC (High-fat diet) vs Column C	86.97	Yes	****
DC (High fat diet) vs Test 1(CA 300mg/kg)	82.20	Yes	****
DC (High fat diet) vs Test 2 (CA 600mg/kg)	92.71	Yes	****
Column C vs Test 1(CA 300mg/kg)	-4.766	Yes	****
Column C vs Test 2 (CA 600mg/kg)	5.742	Yes	****
Test 1 (CA 300mg/kg) vs Test 2 (600MG/KG)	10.51	Yes	****

Fig 3: Low-Density Lipoprotein level

Values are expressed as Mean \pm S.E.M (n=6)

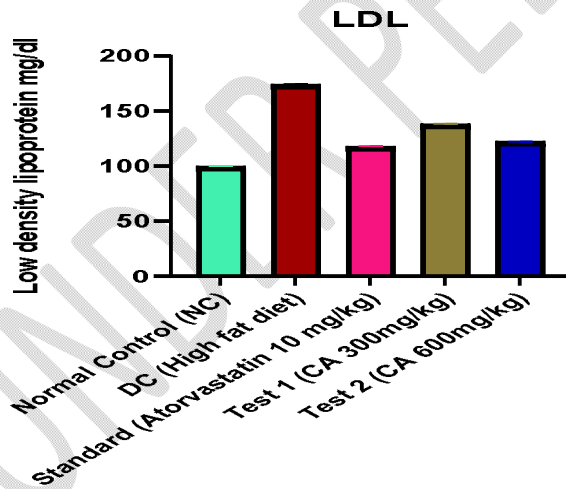


Table no 4: Statistics of LDL level > Comparison between the groups: Tukey's Multiple Comparison tests

Tukey's Multiple Comparison Test	Mean Diff.	Significant? P<0.05?	Summary
Normal Control (NC) vs DC (High-fat diet)	-74.30	Yes	****

Normal Control (NC) vs Standard Group	-18.00	Yes	****
Normal Control (NC) vs Test 1 (CA 300mg/kg)	-38.29	Yes	****
Normal Control (NC) vs Test 2 (CA 600mg/kg)	-22.23	Yes	****
DC (High-fat diet) vs Standard Group	56.30	Yes	****
DC (High fat diet) vs Test 1 (CA 300mg/kg)	36.02	Yes	****
DC (High fat diet) vs Test 2 (CA 600mg/kg)	52.07	Yes	****
Standard group vs Test 1 (CA 300mg/kg)	-20.28	Yes	****
Standard group vs Test 2 (CA 600mg/kg)	-4.226	Yes	***
Test 1 CA 300mg/kg) vs Test 2 (CA 600mg/kg)	16.06	Yes	****

Fig 4: High-Density Lipoprotein level

Values are expressed as Mean \pm S.E.M (n=6)

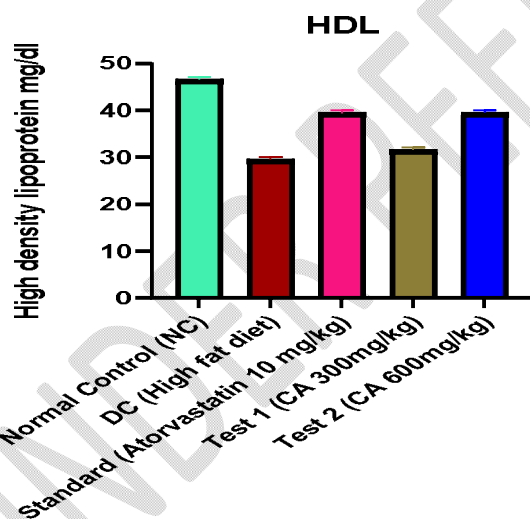


Table no 5: Statistics of HDL level > Comparison between the groups: Tukey's Multiple Comparison tests

Tukey's Multiple Comparison Test	Mean Diff.	Significant? P<0.05?	Summary
Normal Control (NC) vs DC (High-fat diet)	17.03	Yes	****

Normal Control (NC) vs Standard Group	7.090	Yes	****
Normal Control (NC) vs Test 1 (CA 300mg/kg)	14.92	Yes	****
Normal Control (NC) vs Test 2 (CA 600mg/kg)	6.988	Yes	****
DC (High-fat diet) vs Standard Group	-9.940	Yes	****
DC (High fat diet) vs Test 1 (CA 300mg/kg)	-2.108	No	ns
DC(High fat diet) vs Test 2 (CA 600mg/kg)	-10.04	Yes	****
Standard group vs Test 1 (CA 300mg/kg)	7.832	Yes	****
Standard group vs Test 2 (CA 600mg/kg)	-0.102	No	ns
Test 1 (CA 300mg/kg) vs Test 2 (CA 600mg/kg)	-7.934	Yes	****

Fig 5: Very Low-Density Lipoprotein level

Values are expressed as Mean \pm S.E.M (n=6)

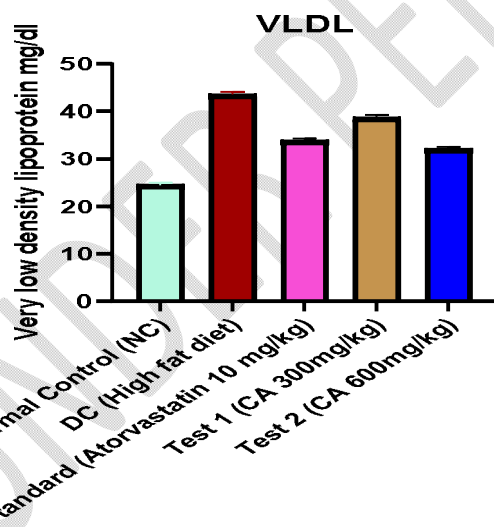


Table no 6: Statistics of VLDL level > Comparison between the groups: Tukey's Multiple Comparison tests

Tukey's Multiple Comparison Test	Mean Diff.	Significant? P<0.05?	Summary
Normal Control (NC) vs DC (High-fat diet)	-19.06	Yes	****

Normal Control (NC) vs Standard Group	-9.338	Yes	****
Normal Control (NC) vs Test 1 (CA 300mg/kg)	-14.26	Yes	****
Normal Control (NC) vs Test 2 (CA 600mg/kg)	-7.694	Yes	****
DC (High-fat diet) vs Standard Group	9.718	Yes	****
DC (High fat diet) vs Test 1 (CA 300mg/kg)	4.800	Yes	****
DC (High fat diet) vs Test 2 (CA 600mg/kg)	11.36	Yes	****
Standard group vs Test 1 (CA 300mg/kg)	-4.918	Yes	****
Standard group vs Test 2 (CA 600mg/kg)	1.644	No	ns
Test 1 (CA 300mg/kg) vs Test 2 (CA 600mg/kg)	6.562	Yes	****

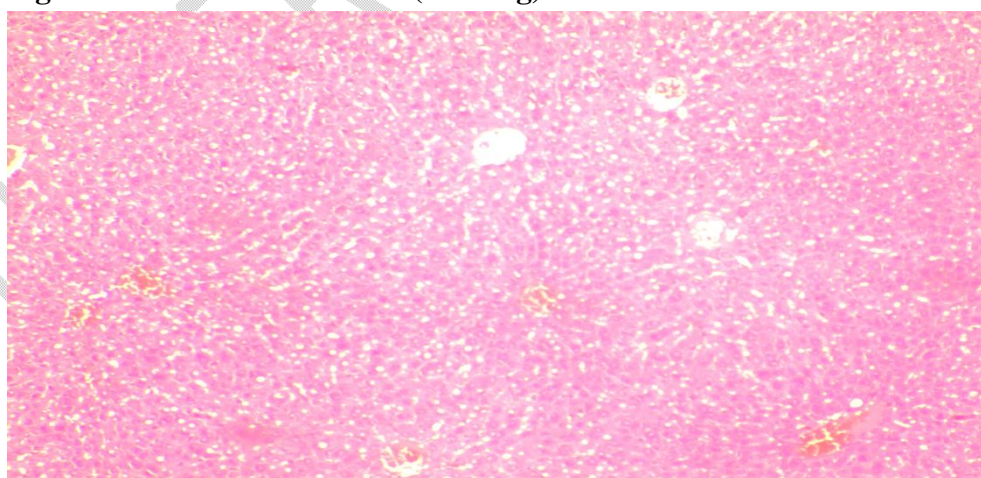
HISTOPATHOLOGICAL ANALYSIS

Score based on fatty changes in the animal groups treated with *Choerospondias axillaris* against HFD-induced atherosclerosis in rats.

Chart 1: Histopathological Score

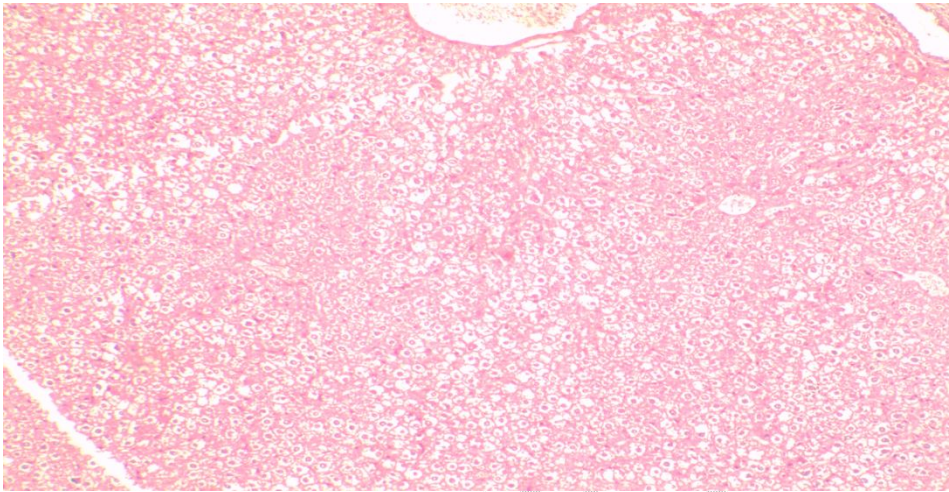
Groups	Histopathological Score
Group 1	0
Group 2	1
Group 3	2
Group 4	2
Group 5	1

Fig 6: Effect of normal saline (10ml/kg)



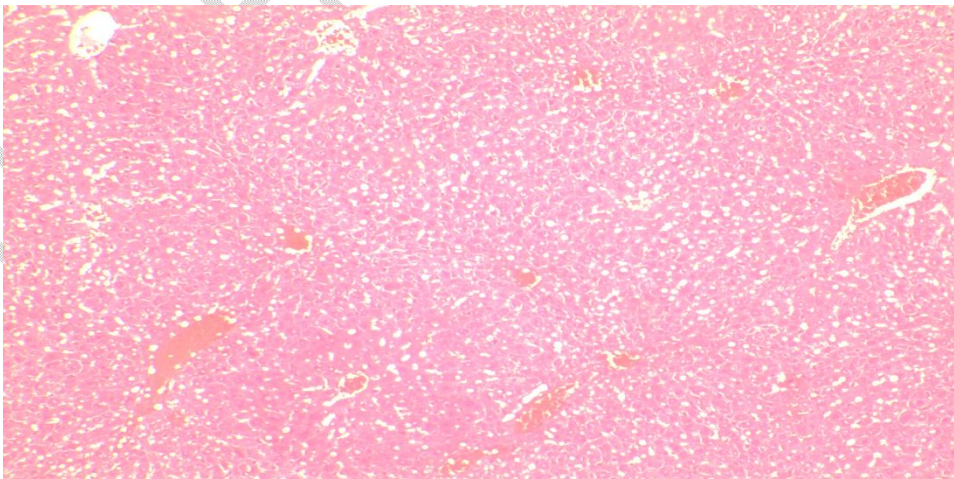
Liver showing normal architecture of hepatocytes arranged cord-like manner around the central vein with cytoplasm staining red and vesicular type of nucleus staining blue. The cytoplasm is eosinophilic and staining pink in colour.

Fig 7: Effect of a high-fat diet on the liver:



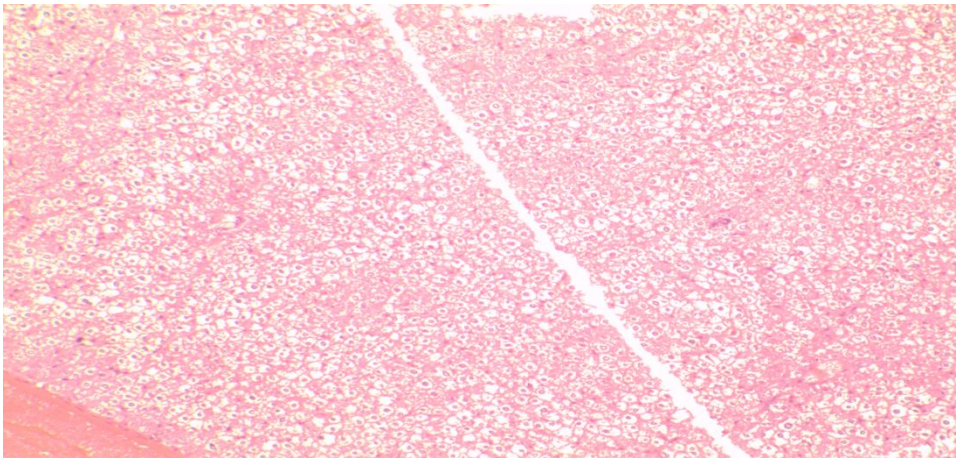
Liver showing mild vacuole degeneration of hepatocytes with unstained vacuoles inside, indicating a lack of cytoplasm with a compact core and focal inflammation of the portal. The normal architecture of hepatocytes is lost.

Fig 8: Effect of High fat diet + Atorvastatin (10mg/kg) on liver:



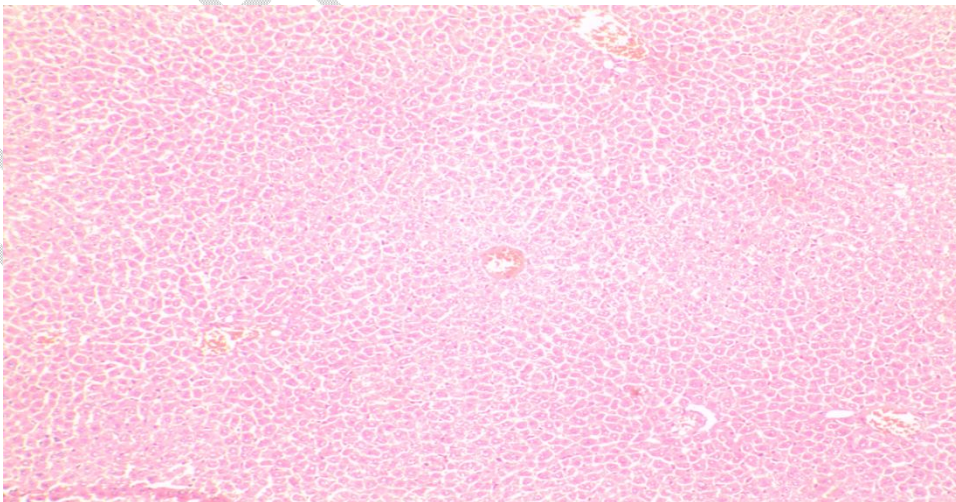
The liver shows the hepatocytes arranged in a cord-like fashion around the central vein with normal architecture. There were few macro vesicle fat vacuoles still present and congestion of blood vessels with infiltration of red blood cells in the sinusoidal spaces.

Fig 9: Effect of methanolic extract of *C axillaris* (200mg/kg) + High fat diet on the liver:



Normal liver architecture with a condensed nucleus, with minor artery degeneration. Hepatocytes are arranged in a cord-like fashion around the central vein. There is micro vesicle fat vacuoles were observed with the condensed nucleus.

Fig 10: Effect of methanolic extract of *C axillaris* (400mg/kg) + High fat diet on the liver:



Liver with the normal arrangement, vascular congestion and there is no necrosis or inflammation reported. The hepatocytes having vesicular nucleus and cytoplasm were

eosinophilic, staining pink in colour. Congestion of blood vessels with infiltration of red blood cells in the sinusoidal spaces indicates the regeneration of hepatocytes.

This study presents data on the anti-hyperlipidemic profiles of fruits of *C. axillaris*, which were shown to be comparable or sometimes much higher than those, suggesting it as the potential alternative source for anti-hyperlipidemic activities. Rats fed with a high-fat diet for 21 days induced significant hyperlipidemia, as indicated by the significant rise in serum levels of TC, TG, LDL-c, and VLDL and a decrease in serum levels of HDL-c. A high-fat diet relatively increased body weight and relative liver weight but did not significantly affect relative heart weight.

Hyperlipidemia is thought to increase cholesterol content, and this, in turn, leads to the generation of reactive oxygen species (ROS), an increase in lipid peroxidation and a decrease in the activity of reduced glutathione. It has been reported that overproduction of ROS can induce cellular damage via oxidation of critical cellular components such as membrane lipids, proteins, and DNA. The increased levels of total cholesterol in blood could induce arterial endothelial dysfunction, and vascular endothelial injury is the initial factor in hyperlipidemia. Therefore, lowering lipids and protecting vascular endothelium play significant roles in preventing hyperlipidemia.

A high-fat diet (HFD) enhanced hepatic oxidative damage due to hepatic stress, resulting from the burden of a high-fat diet or metabolism. In the present study, HFD significantly increased liver MDA (Malondialdehyde) levels and decreased GSH levels, indicating enhancement of oxidative stress. These findings are in agreement with the earlier report. Dried fruit extract of *C. axillaris* (400 mg/kg) significantly increased liver GSH levels and decreased MDA levels in HFD-induced hyperlipidemic rats, thus reducing oxidative stress.

The activity of HMG-CoA reductase was measured to pinpoint the precise mechanism of the dried fruit extract's potential antihyperlipidemic action. Two processes—cholesterol production, in which HMG-CoA reductase catalyzes the rate-limiting process, and cholesterol absorption of both dietary cholesterol and cholesterol eliminated from the liver through biliary secretion—maintain cholesterol homeostasis. The activity of HMG-CoA reductase is inversely correlated with the HMG-CoA/mevalonate ratio. According to the findings of the current investigation, HFD-induced hyperlipidemic rats' HMG-CoA reductase activity is markedly decreased by the dried fruit extract of *C. axillaris* (400 mg/kg).

Atherosclerosis plays a crucial role in the development of heart and vascular illnesses known to be a risk factor for hyperlipidemia. The main risk factor for atherosclerosis is an elevated blood cholesterol level, particularly LDL-c. The presence of foam cells, plaque, fatty infiltration, or lipids in the heart, coronaries, aorta, liver, and kidneys is indicated by an atherogenic index. The risk of oxidative injury to the aforementioned organs increases with the atherogenic index. *C.*

axillaris fruits (400 mg/kg) significantly decreased the atherogenic index in hyperlipidemic rats generated by HFD. As a result, it suggested that it might be able to stop hyperlipidemia.

Conclusion

This chapter describes the anti-hyperlipidemic activity of *Choerospondias axillaris* dried fruits extract in fat diet induced hyperlipidemia in rats model. The crude extract from the plant of *C axillaris* produced significant anti-hyperlipidemic activity. Different chemical constituents such as dihydroquercetin, quercetin, protocatechuic acid, gallic acid, 3,3'-di-o-methylellagic acid, beta-sitosterol, daucosterol, stearic acid, triacontanoic acid, octacosanol were present in the crude extract. Hence it can be exploited as an anti-hyperlipidemic therapeutic agent in existing therapy for the treatment of hyperlipidemia.

ETHICAL APPROVAL

This study had been ethically approved by the (Institutional Animal Ethical Committee) of Karnataka College of Pharmacy, Bangalore. Which conducted the meeting for M.pharm Students on the date (18/12/2021) before taking part in the study, the committee approved for use of the animals in the experiment and provided the registration number (Reg. Number: IAEC/ 09/21-22/07/18/12/21) to start the experiment on animals.

REFERENCES

1. G.D. Kolovou, K.K. Anagnostopoulou, and D.V. Cokkinos, "Pathophysiology of dislipidaemia in the metabolic syndrome" Postgraduate Medical Journal. 2005;81(956):358-366.

2. N.J. Stone, "Lipid management: current diet and drug treatment options," *The American Journal of Medicine*. 1996;101(4):40S-49S.
3. Y.Lin, S.S. Mousa, N. Elshourbagy, and S.A. Mousa. "Current status and future directions in lipid management: emphasizing low-density lipoproteins, high-density lipoproteins and triglycerides as target for therapy". *Vascular Health and Risk Management*. 2010;6(1):73-85.
4. M.Kobayashi, T. Kagawa, K.Narumi, S. Itagaki, T. Hirano, and K. Iseki, "Bicarbonate supplementation as a preventive way in statins-induced muscle damage. " *Journal of Pharmacy and Pharmaceutical Sciences*. 2008;11(1):1-8.
5. J.R. Guyton and H.E. Bays, "Safety considerations with niacin therapy". *The American Journal of Cardiology*. 2007;99(6):S22-S31.
6. Paudel KC, Pieber K, Klump R and Laimer M: Evaluation of Lapsi tree (*Choerospondias axillaris*) for fruit production in Nepal. *Bodenkultur*. 2003; 54(1):23-27.
7. Paudel K, Pieber K, Klumpp R, and Laimer M. Collection and evaluation of germplasm of lapsi (*Choerospondias axillaris*), B.L. Burt and A.W. Hill), an indigenous fruit tree of Nepal. *Plant Genetic Resources Newsletter*. 2002; 130(1):36-46.
8. Zhu Lian, Chengzhong Zhang, Chong Li, Yawei Zhou. [Studies on chemical constituents of *Choerospondias axillaris*]. *Zhong Yao Cai* 2003; 26(1):23-24.
9. Yue X, C Juntao, Yang Y, Liu Z, Wang T. Chemical components of *Choerospondias axillaris* wood by TD-GC/MS, Py-GC/MS, and TG. *Journal of King Saud University-Science*. 2020; 32(1):1142-1146.
10. Labh SN, Shakya SR, Kayasta BL. Extract of Medicinal lapsi *Choerospondias axillaris* (Roxb.) exhibit antioxidant activities during in vitro studies. *Journal of Pharmacognosy and Phytochemistry*. 2015; 4(3):194-197.
11. Mann S, Sharma A, Sarkar A, Kharb R. Evaluation of Anti-inflammatory effects of *Choerospondias axillaris* Fruits Methanolic Extract in Synoviocytes and CIA Rat Model. *Curr Pharm Biotechnol*. 2020; 21(7):596-604.
12. Yun-Seo Kl, Risinger AL, Petersen CL, Liang H, Grkovic TN, Barry R. O'Keefe, Mooberry SL* and Cichewicz RH*. Using the Cancer Dependency Map to Identify the Mechanism of Action of a Cytotoxic Alkenyl Derivative from the Fruit of *Choerospondias axillaris*. *J. Nat. Prod*. 2020; 83(3):584-592.

13. Lei CH, Jie HE, Gao YN, Xing YN. Preventive Effect of Total Flavones of *Choerospondias axillaries* on Ischemia/Reperfusion-Induced Myocardial Infarction-Related MAPK Signaling Pathway. *Cardiovascular Toxicology*. 2013;14(2):210-216.
14. Mukherjee PK. Quality control of herbal drugs, an approach to evaluation of Botanicals. 1st Ed. New Delhi: Business horizons. 2002;5(1):379-401.
15. Khandelwal KR. Practical Pharmacognosy. Techniques and experiments. Nirali Prakashan. 2008;1(11):149-53.
16. S.R Brahma and C.H Saileela. Anti-hyperlipidemic activity of methanolic extract of *Rhinacanthus Nasutus*. *International journal of research in pharmacy and chemistry*. 2013;3(3):708-11.
17. LIU Xin-yuan, YANG Yu-mei, HAN Feng, ZHANG Hao-nan, DU Jian-xi, HAO Xin-min. Immunological Effects of Total Flavones from Leaves of *Choerospondias axillaris* on Mice. *Chinese Herbal Medicines*. 2013; 5(2): 121-124.
18. Mukesh SS and MB. Antihyperlipidemic activity of *Salacia chinensis* root extracts in triton induced and atherogenic diet-induced hyperlipidemic rats. *Indian J Pharmacol*. 2012;44(1):88-92
19. Vilasinee H, Anocha U, Noppawan PM, Nuntavan B, Hitoshi S, Angkana H and Chuthamane S. Hypocholesterolemic and antioxidant effects of aqueous extracts from the dried calyx of *Hibiscus sabdariffa* L. in hypercholesterolemic rats. *J Ethnopharmacol*. 2006;103(2):252-260