

Management outcome of Multi-site keloids of multiple aetiologies in a young female Nigerian: A Case Report.

ABSTRACT

Background: Keloids are **exegerrated** cutaneous scars with a preponderance of fibrous tissue that may complicate wound healing in people that are predisposed to its development. **Its** management could be challenging with very high probability of recurrence following surgical excision alone. A case of multiple keloids involving both breasts and anterior chest wall of different aetiologies in a young adult female Nigerian without family history of keloid is being reported. She had extralesional **escisions** of the keloids with immediate external beam radiotherapy followed by serial triamcinolone injections of the surgical **sites**.

Conclusion: The triple therapy of surgical excision, post-excision radiation and corticosteriod injection offers an excellent outcome in terms of recurrence.

Key words: Multi-site Keloids, extralesional excision, radiation therapy, steriod injection.

1. INTRODUCTION

Wound is a breach in the integrity of an organ or structure. It may be sequel to trauma or surgical procedure and may be internal or external. Irrespective of the aetiology or location, it is invariably followed by healing. Wound healing may be by primary intention in which there is surgical intervention by means of closure or by secondary intervention ie no primary approximation of the wound edges. Wounds that invole the skin are of the external variety and whether they heal by primary or secondary intention the ultimate end point is formation of scar. The scar may be hair line; or slightly elevated but not getting bigger (hypertrophic scar); or moderately/highly **exegerrated**, itchy and expanding (Keloid). Many treatment modalities of surgery, external beam radiation, topically applied pressure, cryotherapy, silicone sheeting and drugs (steriod, antimiotics and antihypertensive) have been tried either as monotherapy or combo-therapy in the management of keloids with varying degree of success as measured by recurrence rate. The main draw back in keloid management is recurrence which is usually bigger and more disfiguring with considerable asthetic issues.

We managed a young adult female Nigerian with multiple keloids complicating surgies and infection with the combo-therapy of extralesional excisions, external beam radiation and steriod (triamnicolone acetionide injection). The presentation, management and outcome of the lesions are thus presented as a Case Report.

2. CASE REPORT

A, a 25 year old Nigerian female University graduate and an on-line foreign examinations (IELTS, SAT&GRE) **Tutor** and **Coach** was seen with a four year history of painless, itchy and slowly progressive multiple cutaneous growths over the anterior chest wall.

About four and a half years prior to presentation, she developed chicken pox (varicella) that eventually progressed to its final stage of crusts and scabs. These eventually healed with scars

Comment [CB1]: Please spell check. Is this word 'exaggerated'?

Comment [CB2]: Please put a space after a period.

Comment [CB3]: Spell check. Is this 'excisions'?

Comment [CB4]: A 'period' is required at the end of sentence.

Comment [CB5]: Please put a space after a period. Please do this throughout the document.

Comment [CB6]: Spelling check, please

Comment [CB7]: Don't capitalize tutor

Comment [CB8]: Don't capitalize 'coach'

that were itchy and slowly increasing in size. This viral infection lasted about two weeks and upon full recovery, she had excisional biopsies of lumps from both breasts sequel to a diagnosis of fibroadenomata. The post excisional scars were noted to be increasing in size both in circumference and height. To the best of her knowledge nobody in her family lineage ever had exegerated post woud scar. Examination revealed multiple well circumscribed oval to roundish elevated, smooth surfaced, firm, slightly hyperpigmented and non-tender lesions over the anterior chest wall and both breasts. Both nipples were normal and no palpable axillary lymph nodes. The lesions are designated as follows:- R1- right periareolar measuring 15 x 6 cm; R2- right parasternal at the level of the 4th intercoastal space ; R3-right midclavicular line, 4th intercoastal space ; R4- right midaxillary line, 5th intercoastal space and R5- posterior surface of the right breast at the level of the 8th intercoastal space (Figure 1). The dimensions of R2- R5 ranged from 3/4 x 2/3 cm. A clinical diagnosis of multi sites keloids of different aetiologies was made.

She was scheduled for triple therapy consisting of excision, adjuvant triamcinolone acetone injection and immediate external beam radiotherapy.

She subsequently had extralesional excisions of the keloids. All the associated fibrous tissues were completely excised leaving healthy wound beds (Fig 2). After closure of the wounds, the edges were immediately injected with three ampoules (40mg/ml) of triamcinolone acetone (Fig 3). About six hours post-surgery, she had the first of two fractions of external beam radiation to the anterior chest wall surgical sites with the second fraction administered four days later. A total of 10 Gy was delivered from Cobalt 60 machine to the depth of 0.5 cm and well tolerated. The sutures of all the five surgical sites were removed 14 days post-operation. Wound healing observed to be progressing satisfactory with flat and well apposed edges. No area of induration or discharge noticed (Figure 4).

Four weeks after the surgery, the operative sites were re-evaluated and the wound scars were observed to be flat and healthy, consequently, they were injected with the second dose of triamcinolone acetone and 160 mg (40 mg/ml) was administered (fig 5).

Eight weeks post surgery (ie four weeks after the 2nd injection), the scars were reevaluted and noticed to be satisfactory and they were injected with the third dose of triamcinolone (160 mg).

At another review twelve weeks post operation, the R1 and R2 scars remained hair-line and flat hence were not injected while R3,4 and 5 were injected with 80 mg of triamcinolone.

At six months post surgery, the scars remained flat, soft, not extending beyond the initial incisions and devoid of stretch marks (Fig 6).

Comment [CB9]: Spell check

Comment [CB10]: Spell check. Please correct spellings everywhere in the document

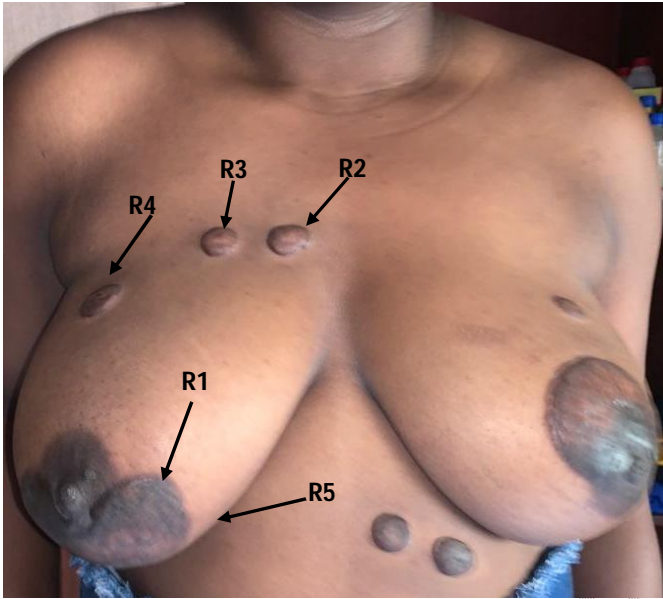


Fig 1 Anterior chest wall. Note the distribution of the scars (Keloids)
R1- Right breast periareolar. R2- Right parasternal
R3- Right midclavicular. R4- Right axillary& R5- Posterior surface of the right breast.

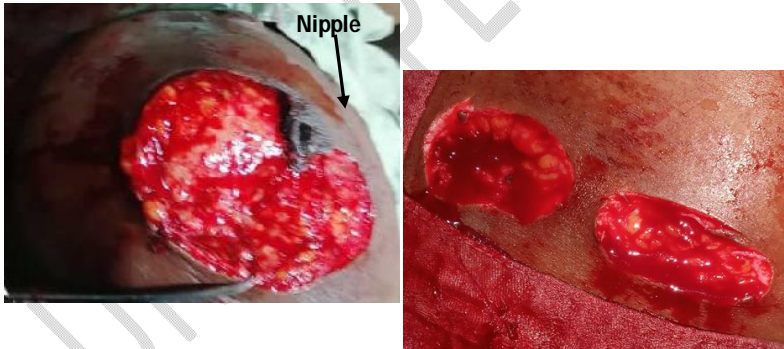


Fig 2: R1A- Post excision of Keloid R1. R2 & 3 A- Post excision of Keloids R2 & R3

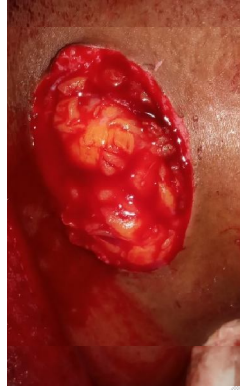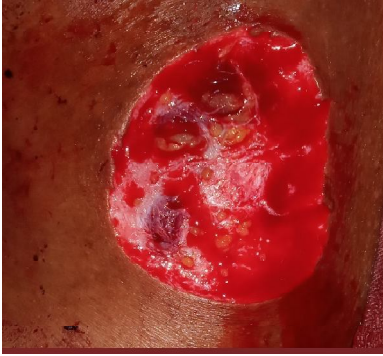


Fig 3: R4A- Post excision of Keloid R4.R5A- Post excision of Keloid R5

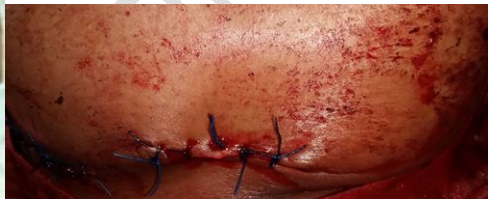
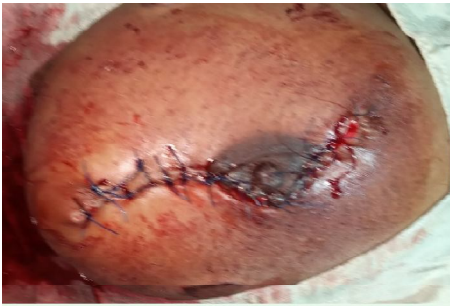
Fig4: R1B-Post wound closure of R1. **Fig 5:** R2-4B-Post wound closure of R2,3 &4

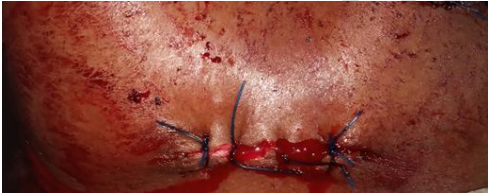

Fig 6: R5B—Post wound closure of R5

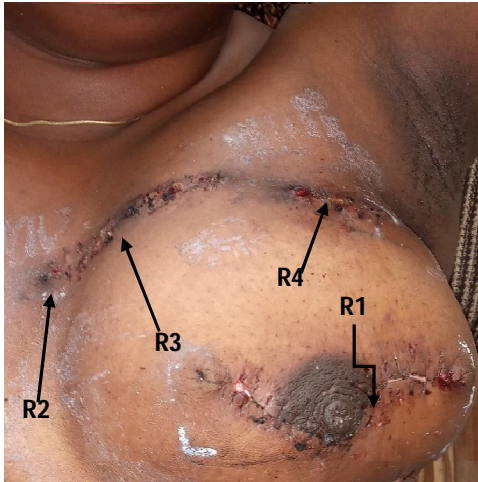


Fig 7: Post removal of sutures from the five sites on 14 days post-surgery.

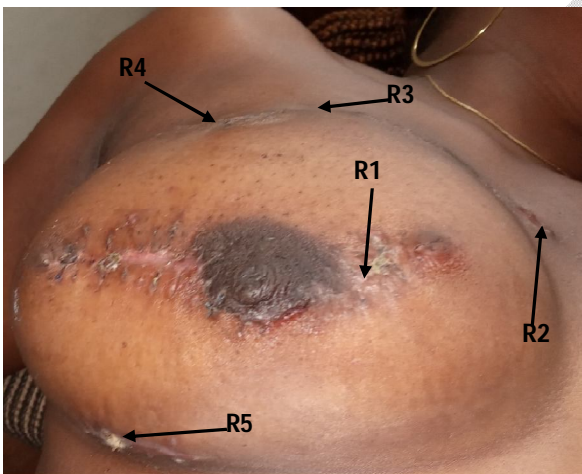


Fig 8: Four weeks (28 days) post excision. Second dose of triamcinolone administered.

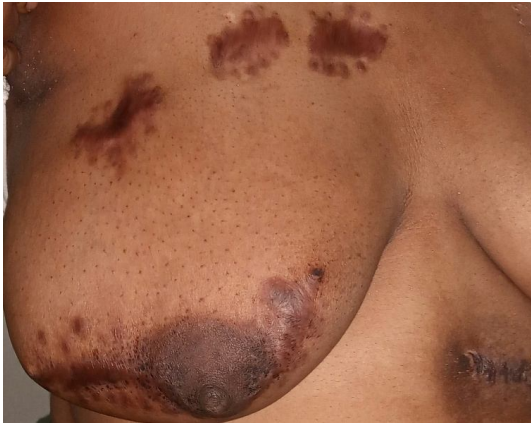

Fig 9: Six months post-surgery

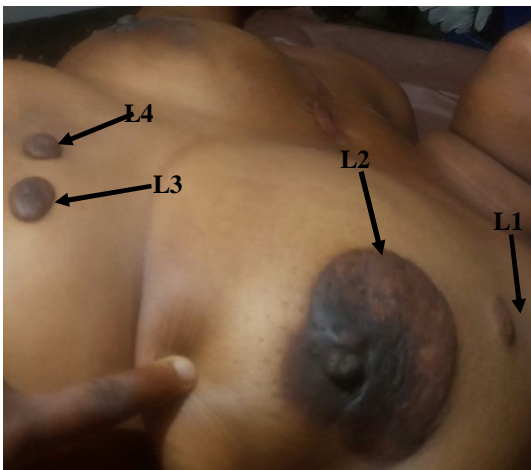


Fig 10. The Left breast keloids; L1-Upper left breast, **L2-** Left breast periareolar, **L3-**Left upper abdomen **L4-** Upper left paramedian

There were four keloid scars on the left namely:- **L1-** situated on the upper outer quadrant of the left breast with a size of 3 x 2 cm;**L2-**periareolar of the left breast 8 x 4 cm;**L3-**left upper quadrant of the abdomen 3x 2 cm and **L4-** upper left paramedian 2.5x 2.5 cm. Extraslesional excisions of all of them were done eight weeks after those of the right. Immediate adjuvant external beam radiation of 10 Gy in two fractions was delivered to the four closed wounds. The injection of the wounds with triamcinolone acetonide was delayed for four days to minimize post-operative stress. All of them healed satisfactorily.

3.DISCUSSION

Keloid scars are amongst the not uncommon complications of wound healing either after primary intention or approximation of the wound edges (secondary intention). Their pathophysiology is

believed to be due to an altered balance between fibroblast proliferation and apoptosis with endothelial dysfunction [1-4]. They are characterized by increased collagen deposition and growth beyond the wound site and also infiltrate the contiguous normal skin. Their propensity to arise from non-trauma wound, lack of involution with associated itching (pruritus) and post-excision recurrence tendency differentiate them from hypertrophic scars [5,6]. Keloids are commoner in people younger than 30 years and peak at the second decade of life. Also, females with elevated hormone levels (puberty and pregnancy) have increased risk [7]. Keloids may also be hereditary with Blacks, Hispanics and Asians being at a greater risk than Caucasians [8-10]. Skin wounds with delayed healing, burns, open biopsy procedures, acne, chickenpox, BCG vaccination, ear piercing increase the chances of keloid formation. Parts of the body with increased predilection for keloids include ear lobes, sternal area, cheeks, shoulder and upper limbs.

Although the index case did not give family history of keloids, her risk factors were racial (Negroid), post viral infection and previous breast biopsies. A genomic study in her may reveal the presence of the gene abnormality responsible for keloid formation.

Based on gross appearance, keloids can be classified as: (A) *Fresh nodular* type, this is characterized by continuous growth, (B) *Superficial spreading* type- has a butterfly appearance and characteristically found over the sternal area, (C) *Mature* type- not growing and (D) *Transitional* type- does not fit into any of the types or has features of two or more types [11].

Microscopically (Histology), keloids exhibit broad, irregular hyalinized collagen bundles with an increased type I/III collagen ratio, decreased fibillin-1 and decorin expression, increased extracellular matrix, preponderance of fibroblasts with paucity of inflammatory cells in the dermis [11]. Certain molecules such as transforming growth factor β and fibronectin are believed to be responsible for the exaggerated collagen synthesis that occurs in keloid formation [12]

Treatment strategies

Various treatment options and protocols have been developed and advocated for the management of keloids. The gold standard of management outcome is the occurrence and frequency of recurrence which is the main problem in keloid management. The consensus is that surgical excision alone is not sufficient to either prevent or reduce drastically recurrence, it has to be combined with other treatment modalities. Intralesional excision has not been found to be advantageous over extralesional excision and available studies reported higher recurrence rates thus extralesional excision in combination with another one or two modalities is being advocated [1,11]. External beam radiation therapy administered within twenty four hours of excision has been observed to give excellent results with very low recurrent rates. In fact, this combination modality was used to successfully managed a non-healing **hemangiomatous** ulcer of the index finger in an adult male Nigerian without any evidence of recurrence even after more than two years of follow up [13]. Radiotherapy suppresses fibroblast activity and angiogenesis thus decreasing inflammation and formation of dysfunctional blood vessels [1]. The main drawback is the paucity of Radiotherapy facilities and services in Africa.

Drugs that have been used as lesional injectables include corticosteroids, 5-fluorouracil, bleomycin, and verapamil, they all have variable response and recurrence rates [6]. The commonest corticosteroid in use either as monotherapy or adjuvant in the management of keloid is Triamcinolone acetonide. It suppresses the inflammatory response associated with wound healing through the following pathways-; reduction in collagen and glycosaminoglycan synthesis, inhibition of fibroblast growth and TGF- β 1 expression, and enhancement of collagen degradation

Comment [CB11]: Please spellcheck

[14].The triple regimen of excision, radiotherapy and triamcinolone has been found to be very effective in terms of recurrence.

Recurrence tendency

The tendency of keloid to recur after surgical excision or following resolution sequel to triamcinolone injection can not be predicted with absolute (100%) accuracy. However certain clinical features may increase the accuracy of recurrence predictability. A history of non-increase in size and soft consistency on palpation portends extremely low chance of recurrence. While keloids that are reported as still growing with firm or hard consistency have high probability of recurrence. Several studies have reported different recurrent rates with some as low as 9% and others as higher as 100% [6,11]. Surgical excision alone has the highest recurrence rate and its combination with other management options gives low recurrence rate.

4.CONCLUSION

Our patient, that is the case being reported had nine (9) keloid scars of different aetiologies and managed with triple regime of extralesional excision, external beam radiotherapy and cyclical triamcinolone acetonide injections. She had been followed up for about one year without any evidence of recurrence.

This case report further strengthens the efficacy of the triple regime therapy of surgical excision, external beam radiotherapy and cyclical triamcinolone injection in the management of keloid scars. We hereby recommend the triple regimen (where Radiotherapy facilities and services are available) as the standard treatment for keloids.

CONSENT

At the outset of management, informed consent of the patient (index case) was sought and obtained. She also approved of the publication of this case report.

REFERENCES

1. Goutos I. Intralesional excision as a surgical strategy to manage keloid scars: what's the evidence? *Scars Burn Heal.* 2019; 5:1-9.
2. Luo S, Benathan M, Raffoul Wet al. Abnormal balance between proliferation and apoptotic cell death in fibroblasts derived from keloid lesions. *Plast Reconstr Surg* 2001; 107: 87–96.
3. Huang C, Liu L, You Z et al. Endothelial dysfunction and mechanobiology in pathological cutaneous scarring: lessons learned from soft tissue fibrosis. *Br J Dermatol* 2017; 177(5): 1248–1255.
4. Ogawa R. Keloid and hypertrophic scars are the result of chronic inflammation in the reticular dermis. *Int J Mol Sci* 2017; 18: E606.
5. Fermo L, Bellomo N, Lumenta DB. Assessment of surgical strategies for addressing keloids: An optimization problem. *Computers & Mathematics with Applications.* 2011;62(6): 2417-2423
6. Juckett G, Hartman-Adams H. Management of keloids and hypertrophic scars. *American Family Physician.* 2009;80(3):253-260.
7. Berman B, Perez OA, Konda S, et al.; A review of the biologic effects, clinical efficacy, and safety of silicone elastomer sheeting for hypertrophic and keloid scar treatment and management. *Dermatol Surg.* 2007;33(11):1291-1303.
8. Omo-Dare P. Genetic studies on keloid. *J Natl Med Assoc.* 1975;67(6):428-432.

9. Brissett AE, Sherris DA. Scar contractures, hypertrophic scars, and keloids. *Facial Plast Surg.* 2001;17(4):263-272.
10. Butler PD, Longaker MT, Yang GP. Current progress in keloid research and treatment. *J Am Coll Surg.* 2008;206(4):731-741.
11. Lemperle G, Scherle J, Kitoga KE, Sachs C, Dimmler A. Keloids: Which types can be excised without risk of recurrence? A new clinical classification. *Plast Reconstr Surg Glob Open* 2020; 8:1-9.
12. Andrews JP, Marttala J, Macarak E, et al. Keloids: the paradigm of skin fibrosis—pathomechanisms and treatment. *Matrix Biol.* 2016; 51:37-46.
13. Ajani RS, Adenipekun AA. External beam radiotherapy as an adjuvant in the management of recurrent digital hemangioma tumor: A case report. *Journal of Cancer and Tumor International.* 2021;11(3): 1-6.
14. Ren Y, Zhou X, Wei Z, et al. Efficacy and safety of triamcinolone acetonide alone and in combination with 5-fluorouracil for treating hypertrophic scars and keloids: a systemic review and meta-analysis. *International Wound Journal.* 2017;14:480-487.