

Original Research Article

HYSTEROSALPINGOGRAPHIC INDICATIONS AND FINDINGS AMONG WOMEN PRESENTING TO RADIOLOGY DEPARTMENT OF RIVERS STATE UNIVERSITY TEACHING HOSPITAL

ABSTRACT

Background: Hysterosalpingography (HSG) is one of the imaging modality used in evaluating females presenting with complaints of infertility. Infertility is not just the issue of the couples alone both the extended family is involved in the typical African environment, therefore it is essential to identify possible causes and proffer solutions where possible.

Aim: This study is aimed at documenting the indications and findings among women presenting for hysterosalpingographic studies in the Radiology Department of Rivers State University teaching Hospital (RSUTH).

Setting and Design: A retrospective study, was conducted at the Radiology and the Obstetrics and Gynaecology Departments of a tertiary health care facility.

Materials and Methods: Assessment of all consecutive patients who had Hysterosalpingography (HSG) done based on the indications from 1st January, 2020 to 31st May, 2022 in the Radiology Department of RSUTH. Biodata and indications for the study were obtained from the request forms and the HSG findings were also obtained from results pool.

Statistical Analysis: Data were analyzed using SPSS 21.0 version. The level of statistical significance was set at $p < 0.05$.

Results: A total of 305 women data were analyzed. The age of the study group was between 21 to 48 years with a mean age of 35.21 ± 5.48 years. Majority of the age group was 31-35 years ($n=96$, 31.5%). Secondary infertility ($n=216$, 70.8%) was the most common indication for HSG. Normal HSG was seen in 84 (27.5%) of the patients and others had one pathology or the other. Commonest uterine pathology is uterine fibroids ($n=100$, 32.8%) and bilateral tubal occlusion ($n=47$, 20.8%) is the most frequent tubal pathology. There was a significant association between age and tubal occlusion ($P=0.007$).

Conclusion: HSG is still a valuable tool for investigating women in gynaecological clinics. Tubal occlusion is the prevailing pathology from this study and secondary infertility is the most common indication for HSG.

Keywords: Indications, Women, Hysterosalpingography, Fallopian Tubes, Uterus, Contrast Material

INTRODUCTION

Hysterosalpingography (HSG) is an imaging modality in Radio-diagnosis which uses ionizing radiation to assess the cervical canal, the uterine cavity and the fallopian tubes with the aid of a radio opaque material injection through the cervical canal. [1,2] This investigation is usually done within days 7-12 of the menstrual cycle (day 1 is the onset of the menstrual bleeding or flow). Fallopian tube assessment can be done also by using laparoscopic chromopertubation, this investigation cannot evaluate the cervical canal and the uterine cavity, thereby making HSG to still have a role in the evaluation of women presenting with infertility in both resource rich and poor regions of the world. Contrast sonography (HYCOSY) is an alternative approach that is been considered and gaining popularity. [3] It is an ultrasound based method which uses contrast and it is then injected into the fallopian tubes through the cervical canal. Note that if HSG is properly done under fluoroscopy with no abnormality seen, hysteroscopy is not required because it will yield same results. [1] However, if too little a contrast material is injected an inconclusive study can occur and excess injection of contrast material could make interpretation of result difficult. [4] HSG, is first and foremost diagnostic but can occasionally prove to be therapeutic. [5] Pregnancy and active pelvic infection are contraindication to HSG and possible complications are pain, pelvic infection, bleeds and vasovagal attacks. [6] It is worthy of note that there are other imaging modalities in assessment of women presenting with infertility. Transvaginal ultrasound scan is a first line of choice and can be complimented by saline or contrast. Highly sensitive for polyps but less accurate with tubal issues. Magnetic resonance imaging (MRI) is useful for congenital mullerian ducts anomalies and limited for tubal evaluations.

There is a lot of infertility cases referred from the Gynaecology clinic to Radiology unit of RSUTH for HSG and there has not been any study done to assess the findings. The aim of this study was to document the indication and findings among women presenting for hysterosalpingographic studies in Radiology Department of RSUTH.

Infertility is a global health challenge with prevalence of 10-15% of couples who experience infertility. [7] while in the United Kingdom and United States it is documented as 6% and 10% respectively. [8] The frequency of infertility in Africa, is particularly high especially in the Sub-Saharan region ranging from 20 to 60% of couples. [9] This increase in prevalence has been credited to unsafe abortion, sexually transmitted disease as well as puerperal pelvic sepsis. [10] Community-based studies in some parts of Nigeria reported rates of infertility to be as high as 45%. [11] Previous study has shown that 15% of all women during their reproductive age experiences either primary or secondary infertility. Many factors are implicated in women presenting with infertility ranging from disorders of the fallopian tubes, uterus, cervix and ovaries, but tubal factor is the most culpable culprit accounting for 35-40% of cases. [12]

MATERIALS AND METHODS:

The study was conducted at the Radiology and the Obstetrics and Gynaecology Departments of RSUTH, South-South Nigeria. All consecutive patients who presented for hysterosalpingography for diverse reasons between 1st January, 2020 and 31st May, 2022 were included in the study. Those whose request forms could not be found were excluded from the study. The Biodata, indications for the investigation and the HSG findings were obtained

Ethical approval is not needed in this kind of study

Sample size calculation: Using the formula for cross-sectional design [13] a sample size of 305 was obtained based on the 0.05 significant level, a proportion of 71.7% HSG abnormality of blocked tubes from a study in South-South region of Nigeria, [14] and precision level of 5%, a sample size of 305 was approximately obtained.

Data analysis: Data obtained from the study proforma was entered into Microsoft Excel, and then exported to IBM Statistical Package for Social Sciences (SPSS) version 21 for statistical analysis. Descriptive statistics employed means, standard deviation, median and ranges for numerical data, and absolute frequencies and percentages for categorical data. Fisher's Exact was employed for comparison between proportions. Comparisons of mean ages between respondents with and without abnormalities were performed using independent t-test to determine significant differences. One-way Analysis of Variance (ANOVA) was used to determine significant differences in the mean ages across HSG indications. Statistical significance was set at 0.05.

Hysterosalpingographic technique:

The HSG examination was done by trained Radiologist in the Radiology department of RSUTH who also interpreted the results afterwards. Patients are booked for this procedure and it is conducted within day 7-12 of the menstrual cycle (day 1 is the start of the flow). This step was necessary to avoid accidental flush or ionization of an embryo as well as to obtain optimal images for better interpretation. Contraindications to this test are pregnancy, pelvic inflammatory disease, bleeding and severe allergy to iodine-based contrast agents.

Verbal informed consent was obtained from the clients after the procedure and its attendants complications explained to the patients.

All procedures were done under fluoroscopy. Control image was obtained in supine position for evaluation of factors, radio opaque lesions and for proper positioning. The patient was placed in lithotomy position, using aseptic technique, the cervix was visualized with the aid of a speculum and the anterior lip held with the vosellum forceps. A matching size of Everal Williams's uterine cannula was inserted into the endocervical canal after sounding of the uterus by a uterine sound. Occasionally difficulty with cannulation is encountered and patient is referred to the referring Gynecologist to dilate and cannulate patient. The uterus was pulled into position by applying a gentle traction on the vosellum, 15-20ml of water-soluble contrast medium (urographin 76% of sodium amidotrizorate+meglumine amidotrizorate) was injected slowly into the uterine cavity. The uterine cavity and the patency of the fallopian tubes were assessed by direct image intensification. Spot films were taken at each stage of the study. A delay film was also taken to check for clearance of contrast from pelvic cavity, especially if hydrosalpinx was noted. All images were checked and findings were documented.

RESULTS

Table 1: Age distribution of the women in the study

Age category	Frequency	Percentage
21 – 25 years	13	4.3
26 – 30 years	48	15.7
31 – 35 years	96	31.5
36 – 40 years	94	30.8
41– 45 years	50	16.4
> 45years	4	1.3
Total	305	100.0

Table 2: Indications for HSG among the women in the study

Variables	Frequency	Percentage
Infertility		
Secondary infertility	216	70.8
Primary infertility	10	3.3
Uterine fibroids		
Asherman's syndrome	13	4.3
Abnormal menstruation		
Routine	1	0.3
Total	305	100.0

A total of 305 patients who presented for HSG in radiology department of RSUTH were involved in this study. The age range was between 21-48years, with a mean age of 35.21±5.48years. Majority of the women fell within the 31-35years age range (n=96, 31.5%) as shown in table 1.

Two hundred and sixteen (70.8%) patients had HSG due to secondary infertility and just ten (3.3%) from primary infertility. Other indications for HSG are uterine fibroids (fifty-seven,

18.7%), Asherman's syndrome (thirteen, 4.3%), abnormal menstruation (eight, 2.6%) and the least indication is routine (one, 0.3%).

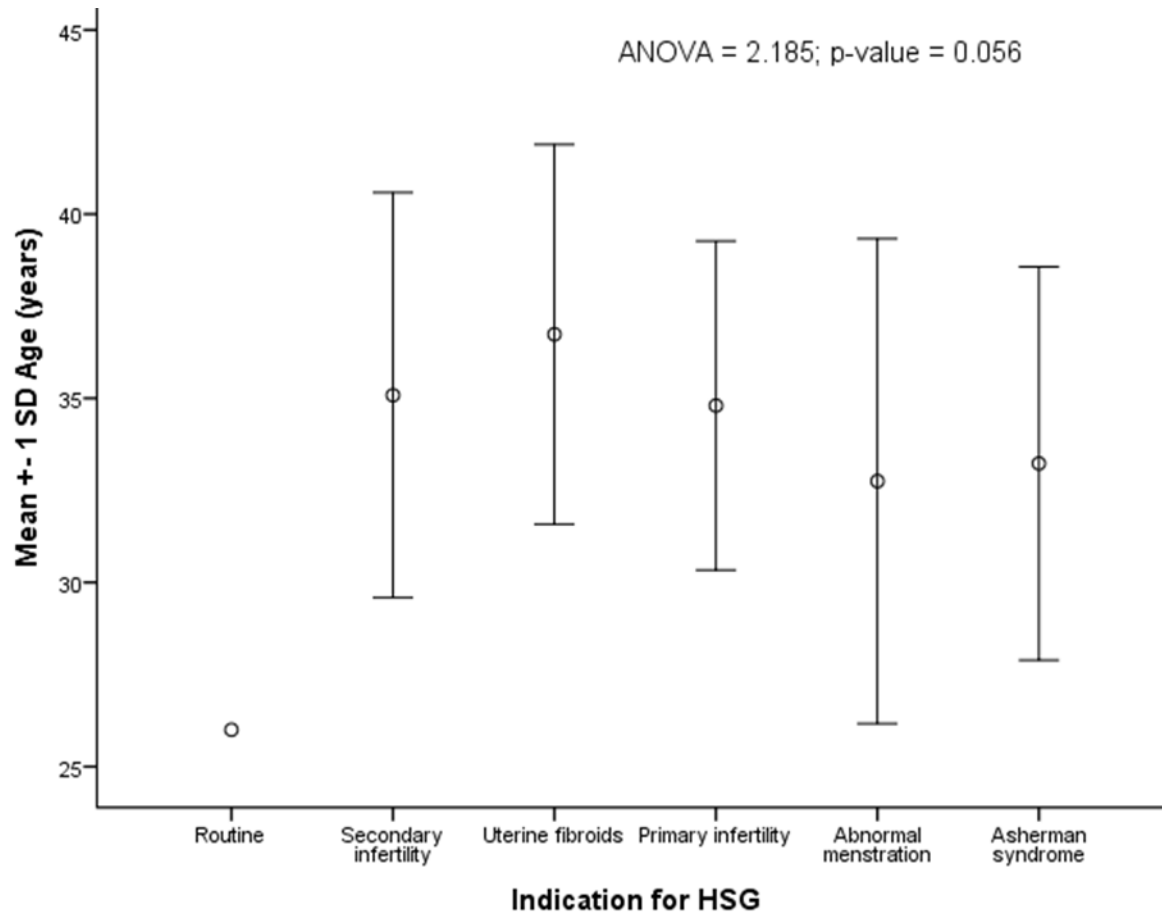


Figure 1: Error bar showing the mean ages of the respondents according to HSG indication

Figure 1 shows the mean age for each indication for HSG. The mean age for secondary infertility was 35.08 ± 5.500 years while primary infertility was 34.80 ± 4.467 years. The mean age for uterine fibroids was 36.74 ± 5.153 years, Asherman's syndrome was 33.23 ± 5.341 years, abnormal menstruation was $32.75 \pm 6.585 \pm 5.341$ years and routine was 26.00 years. This is not statistically significant with $P\text{-value}=0.056$.

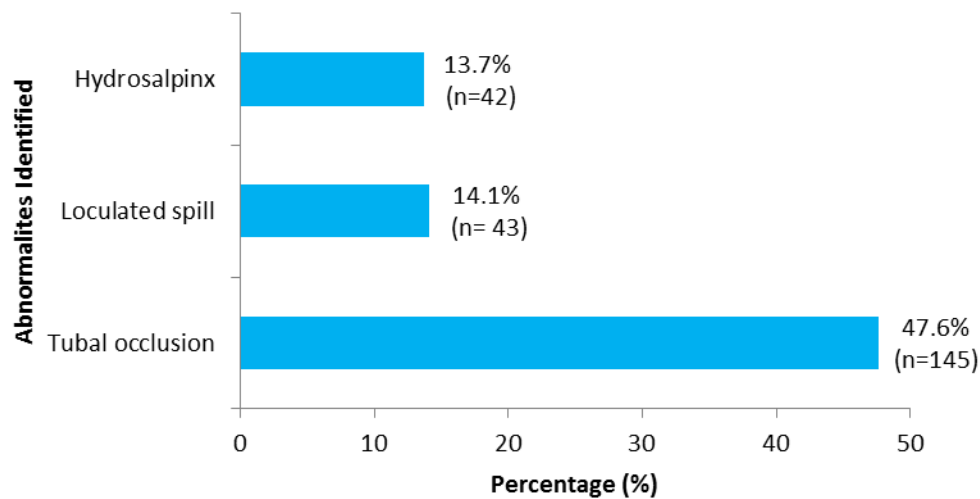


Figure 2: Fallopian tube abnormalities identified among the study population

The most common tubal abnormality was tubal occlusion (n=145, 47.6%) followed by loculated spill (n=43, 14.1%), then hydrosalpinx (n=42, 13.7%), as revealed in figure 2.

Table 3: Hysterosalpingogram findings from HSG among the women in the study

Variables	Frequency	Percentage
Tubal pathologies		
Bilateral tubal occlusion	47	20.8
Left tubal occlusion	25	11.1
Right tubal occlusion	21	9.3
Left hydrosalpinx	15	6.6
Bilateral hydrosalpinges	8	3.5
Right hydrosalpinx	7	3.1
Bilateral loculated spill	12	5.3
Left loculated spill	11	4.9
Right loculated spill	8	3.5
Right beaded tube	1	0.3
Left beaded tube	1	0.3
Uterine findings		
Uterine fibroid/myoma/smooth filling defects	100	32.8
Normal Hysterosalpingography	84	27.5
Uterine synechiae/Asherman's syndrome	46	15.1
Arcuate uterus	2	0.9
Unicornuate uterus	1	0.3
Adenomyosis	1	0.3

Table 3, showed that normal HSG was (n=84, 27.5%), the commonest uterine abnormality found were uterine fibroids (n=100, 32.8%) followed by uterine synechiae (n=46, 15.1%), arcuate uterus (n=2, 0.9%), unicornuate uterus and adenomyosis (n=1, 0.3% each).

Table 4: Comparison of mean age of study population by HSG findings

Variables	Number (%)	Mean Age \pm SD (years)
Synechia		
Yes	46 (15.1)	34.87 \pm 5.365
No	259 (84.9)	35.27 \pm 5.512
<i>t = -0.461; p-value = 0.645</i>		
Smooth filling defects		
Yes	88 (28.9)	35.77 \pm 5.053
No	217 (71.1)	34.99 \pm 5.643
<i>t = 1.136; p-value = 0.257</i>		
<hr/>		
SD – Standard deviation	**Independent t test	

Table 4 shows that there is no statistical significance with the mean age and uterine pathology.

Table 5: Comparison of age category against tubal occlusion among the study population

Variables	Tubal occlusion				Total
	Right alone	Left alone	Both	None	
	n (%)	n (%)	n (%)	n (%)	n (%)
Age category					
≤ 35 years	11 (7.0)	20 (12.7)	30 (19.1)	96 (61.1)	157 (100.0)
>35 years	20(13.5)	18 (12.2)	46 (31.1)	64 (43.2)	148 (100.0)
Total	31 (10.2)	38 (12.5)	76 (24.9)	160 (52.5)	305 (100.0)

*Chi- Square = 12.232; p-value = 0.007**

Table 5 shows that the age category and tubal occlusion are statistically significant and it is the prevalent tubal pathology which plays a key role in the ability of women to conceive naturally.

Table 6: Comparison of age category against infertility among the study population

Variables	Infertility			
	Primary	Secondary	Others	Total
	n (%)	n (%)	n (%)	n (%)
Age category				
≤ 35 years	6 (3.8)	111 (70.7)	40 (25.5)	157 (100.0)
>35 years	4 (2.7)	105 (70.9)	39 (26.4)	148 (100.0)
Total	10 (3.3)	216 (70.8)	79 (25.9)	305 (100.0)

Chi-Square = 0.314; p-value = 0.855

Table 6 is comparing the age category with infertility and other indications for HSG, which is of no statistical significance.

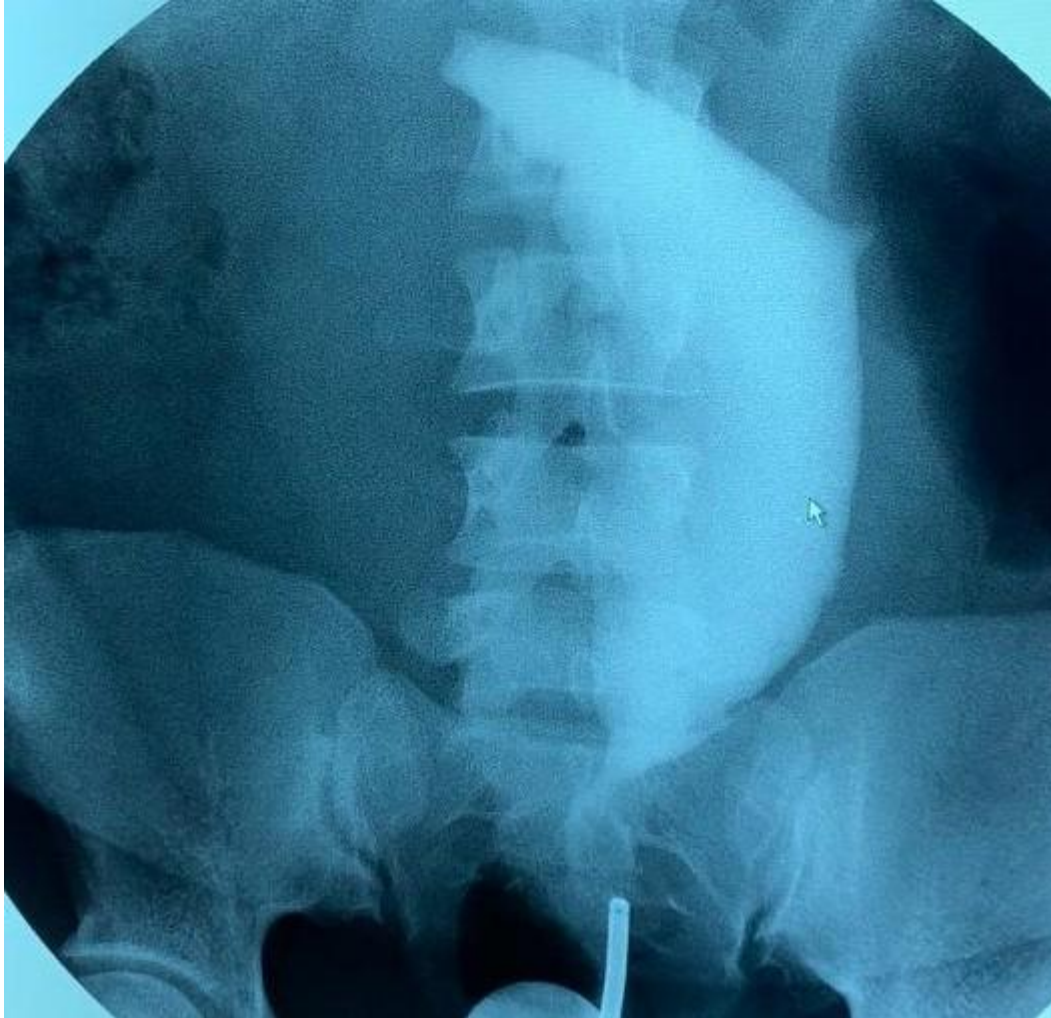

Figure 3: shows that the uterine cavity is capacious, reveals an abnormal shape and is displaced leftward in the abdominal and pelvic cavity. It shows smooth convex filling defects along its right margins. Both fallopian tubes are not demonstrated.

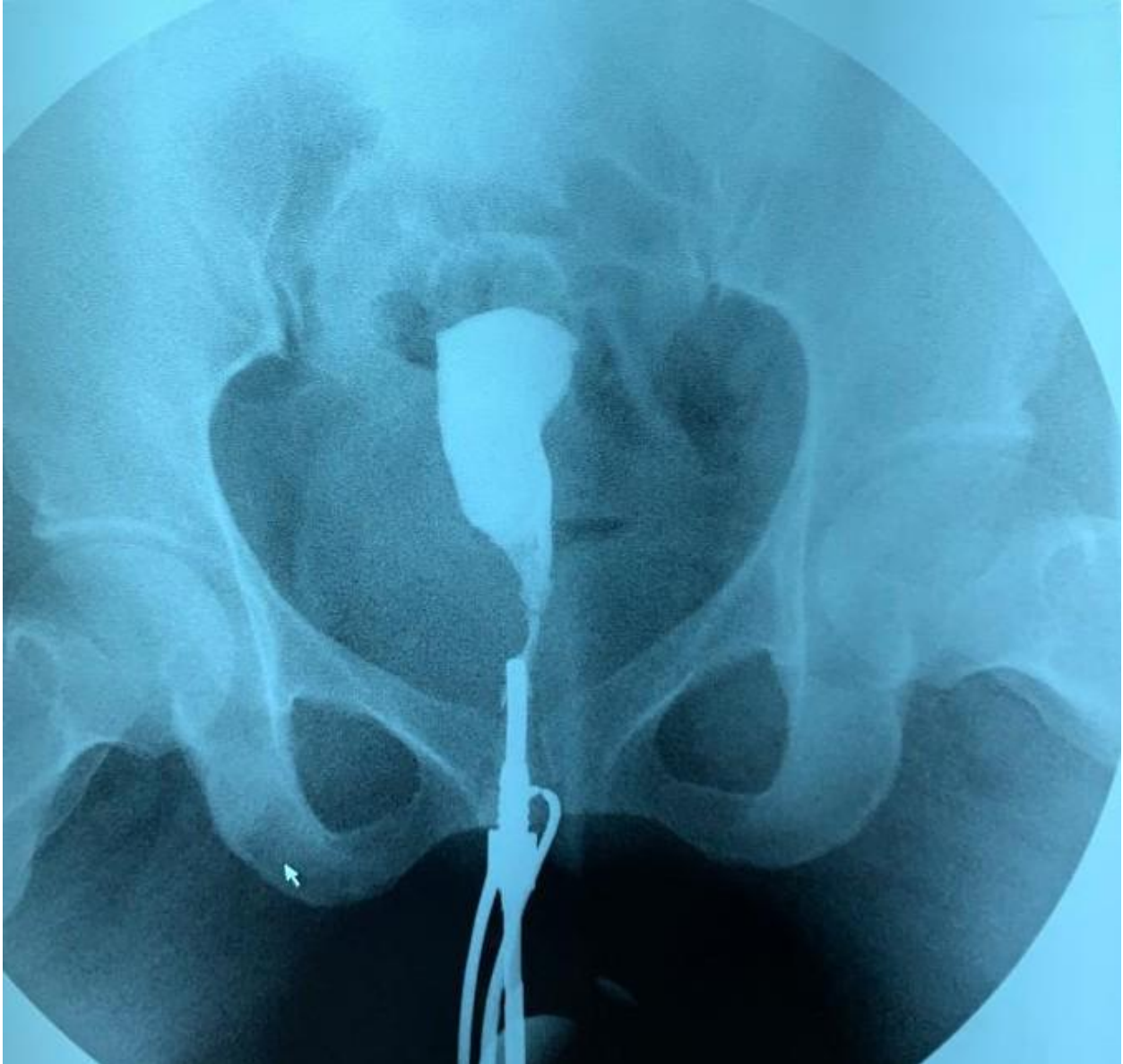


Figure 4: showed that the contrast opacified uterine cavity is mildly elongated with smooth extrinsic filling defects in its right inferior and left mid regions. The cavity is enlarged and central in location. The cornus are rounded up bilaterally and both fallopian tubes are not demonstrated.

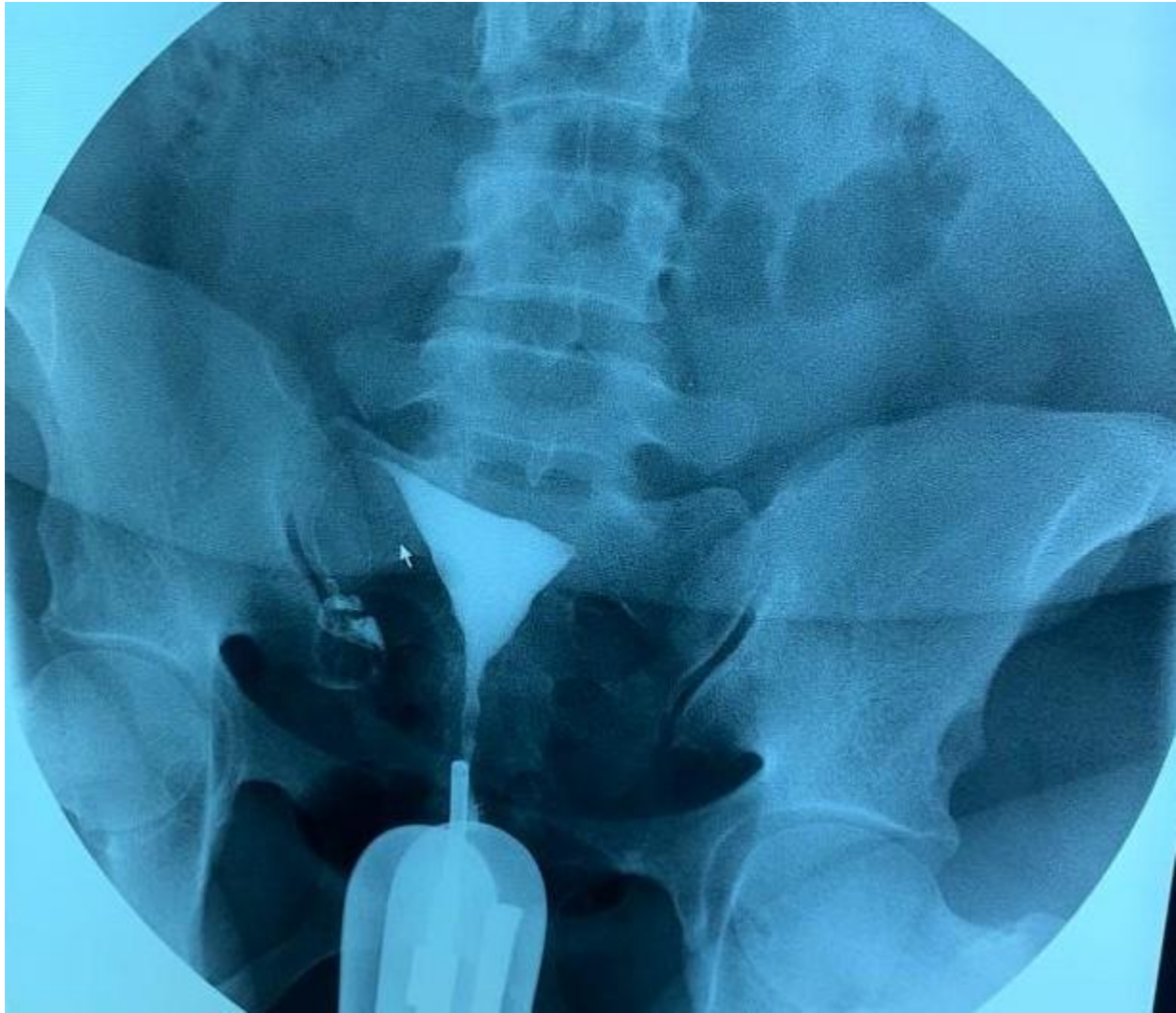

Figure 5: shows that the contrast opacified uterine cavity is triangular in shape, normal in outline, size and position. The right fallopian tube is demonstrated with free intraperitoneal spill noted, however the left uterine horn is rounded up and the left fallopian tube is not demonstrated.

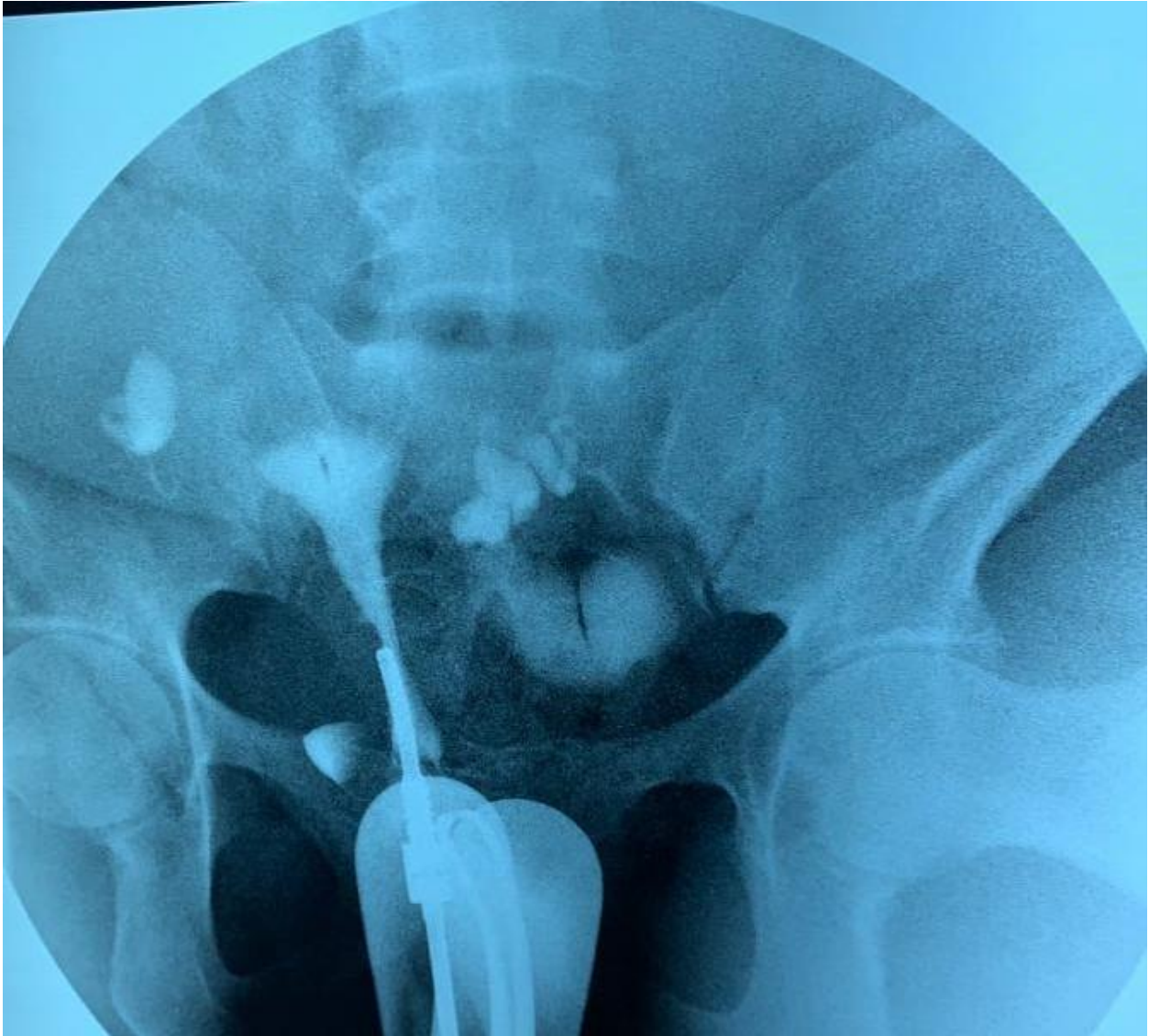


Figure 6: shows a contrast opacified uterine cavity that is triangular in shape, normal in outline, size and position. Bilateral dilated tortuous fallopian tubes (bilateral hydrosalpinges) worst on the right are seen.

DISCUSSION

It is worthy of note that there are other cutting-edge investigations available for the evaluation of women within the reproductive age, however, HSG is readily available, readable and less expensive compared to others in less affluent environs.

This study reveals a mean age of 35.21 ± 5.48 years and also showed that the highest age range of women presenting for HSG is 31-35 years. This can be explained by the intense desire of women in this age group to bear children after obtaining formal education and career building. [15] This finding agrees with previous studies done. [14, 16-19]

In this study, secondary infertility (n=216, 70.8%) is commoner than primary infertility (n=10, 3.3%). Similar findings were made by other investigators. [14, 18, 20-26] In contrast to our findings, others observed that primary infertility is a more frequent indication for HSG than secondary infertility. [17,27] This difference may be due to difference in methodology. [17] Okafor et al [17] also documented high incidence of cervical and uterine synechiae in primary infertility patients, making the history they volunteered questionable.

From this current study 27.5% of the women had normal HSG findings. This observation corroborates with other studies [14,17-18,25] but disagrees with Nwankwo et al [28] which recorded higher frequency of 44.2%. This is most likely due to absence of the use of fluoroscopy for the study period.

Uterine abnormality is high in this study (49.4%) which is closely related to the 47% reported in a Nnewi study and 50.8% reported in a Port Harcourt study. [17-18] It however differs from a previous study conducted in the same locality, by Nwankwo et al, [28] which documented a

lower percentage of uterine abnormality (26.8%). This is probably due to the reason mentioned earlier.

Uterine fibroids are the most common uterine cavity abnormality (32.8%). This finding supports that of Okafor et al [17] who documented 61.1%. It also agrees with previous studies as the commonest uterine cavity abnormality with the following percentages 21.1%, 17.6%, 20.9%, 13.5% and 20% but the percentages were lower [14,18-19,29-30] respectively.

On the other hand, uterine synechiae is of lower occurrence (15.1%) and is in concordance with others which reported low prevalence of uterine synechiae in comparison to uterine fibroids [14,18-19] but disagrees with Bukar M et al [21] who documented higher percentage for uterine synechiae, which they credited to infections and excessive uterine curettage.

In this study three cases of congenital uterine abnormalities were noted of which two (0.9%) cases were arcuate uterus and the other, a case (0.3%) of unicornuate uterus. This is close to values documented in other studies: one (0.4%) [18], three (0.9%) [16], two (0.8%) [31], three (0.9%) [14] respectively but lower than: 4 (3.0%) [19] and 10 (3.6%) [21] respectively. However, no congenital uterine abnormality was seen in the study carried out by Okafor et al. [17] This has shown that Nigeria falls within the infertility belt wherein the causes are mostly acquired than congenital.

Also in this study only one (0.3%) case of adenomyosis was encountered which is similar to the two (1.3%) and four (1.1%) reported by Aduayi et al [19] and Kiridi et al [14] respectively.

With regards to tubal pathologies, bilateral tubal occlusion is the most common (47, 20.8%), this is in keeping with some other studies. [14,18-19,32-35] These values are higher than that previously reported in Port Harcourt (4%). [28] Concerning unilateral tubal occlusion, left tubal

occlusion (25, 11.1%) is commoner than right tubal occlusion (21, 9.3%) in the index study. This is in concordance with other studies. [14,19,33] In contrast to these findings, other studies [16-18,30,32] showed that right tubal occlusion is more common and a hypothesis of post-surgical complication was given as a possible explanation.

The next common tubal pathology encountered is hydrosalpinx, which is mainly unilateral and left sided, with a higher frequency (15, 6.6%) compared to the right (7, 3.1%). This was in tandem with some studies [21,34,36] and is in disagreement with other previous studies [14,18-19] that noted right predominance and bilaterality of hydrosalpinges. [16,28,31] Adetiloye et al [30] documented that the increased incidence on the right is due to appendectomy and its attendant complications. Also previous unsafe abortion, pelvic inflammatory disease and puerperal sepsis constitute bulk sources of infection of the female reproductive tract. Thus, primary prevention and early treatment of infection is important in reducing the high occurrence rate of tubal infertility. [16]

Loculated spill was observed in 43 (14.1%) of cases in this study which indicates peritubal adhesions. This is closely related to Udobi et al [32] (13%, n=58) and Eze et al [33] (12.40%). Studies done by Aduayi et al [19] reported (17.9%) and Absasiattai et al [35] reported (30.7%); these values are higher than that noted in this study. While Krirdi et al [14] and Danfulani et al [16] documented 4.5% and 0.3% in separate studies respectively. These values are lower than that seen in this study.

There was significant association between bilateral or unilateral tubal occlusion and age ($P=0.007$). In contrast to our study, Udobi et al [32] documented that there was no association with age and tubal occlusion be it bilateral or unilateral. Note that our findings supports an

earlier study done by Aduayi et al [19]. It has been documented that tubal factor occurs more in women of older age than younger age [36] however, there is no relationship between age and infertility as well as other indications for HSG in this study.

Beaded tubes were also seen in this study one each on either side (n=1, 0.3%), which is highly suggestive of salpingitis isthmica nodosa and was also reported by others [19,31] however Kiridi et al [14] reported four cases.

UNDER PEER REVIEW

CONCLUSION

In conclusion, the most common indication for HSG in our facility is secondary infertility. Uterine fibroid is the prevalent uterine cavity abnormality and bilateral tubal occlusion is the commonest of the tubal pathology. Its worthy of note that only tubal occlusion had significant association with age. HSG is an indispensable investigation in gynaecological cases especially in low income climes, thus its continuous use should be advocated.

REFERENCES

1. Theodore A, Baramki MD. Modern trends in hystersalpingography. *Fertil Steril* 2005;83 (6) 1595-1606.
2. Bacevac J, Ganovic R. Diagnostic value of hysterosalpingography in examination of fallopian tubes in infertile women. *Srpski archive za celokupno lekarstvo*. 2001;129 (9-10) 243-6.
3. Kdous M. Hysterosaipingography in the assessment of tubal patency. *La Tunisie medicale* 2006;84(8):520-5.
4. Siegler A. Hysterosalpingography. In Wallach E and Zacur H (eds). *Reproductive medicine and surgery*, Mosby Baltimore (1986).
5. Schwabe MG, Shapiro SS, Haning RV. Jr. hysterosalpingography with oil contrast medium enhances fertility in patients with infertility of unknown etiology; *Fertil Steril*;1983;40:604-606.

6. Sala E, Allison S, Ascher SM, Hricak H. Imaging in Gynecology. In: Adams A and Dixon A.K(eds). Grainger and Allison`s Diagnostic Radiology. A textbook of Medical Imaging Volume 2. 5th Edition. Churchill Livingstone, Elsevier London, UK. 2008;1217-1241.
7. Evers JL, Collins JA. Assessment of efficacy of varicocele repair for male subfertility: a systemic review Lancet 2003;361: 1849-52. Evers JL, Collins JA. Assessment of efficacy of varicocele repair for male subfertility: a systemic review Lancet 2003;361: 1849-52.
8. Okonofua FE. Infertility in the Sub-Saharan Africa. Okonofua F, Odunsi K (eds). Contemporary Obstetrics and Gynaecology for developing countries. WHARC Benin city, Nigeria. 2003;128-156
9. Ogunniyi SO, Makinde OO, Dare FO. Abortion related deaths in Ile-Ife, Nigeria. Afr J Med Sci 1999; 19:271-4.
10. Idrisa A Infertility. In Kwaawukume EY, Emuveyan EE, editors. Comprehensive Gynaecology in the Tropics. Accra Graphics packaging;2005.333-43.
11. Adetoro OO, Ebomoyi EW. Prevalence of infertility in a rural Nigerian community. Afr J Med Sci 1991; 20:23-7.
12. Reis MM, Soares SR, Cancado ML, Camargos AF. Hysterosalpingo-contrast Sonography(Hycosy) with SH U 454 (Echorist) for assessment of tubal patency. Hum Reprod 1998;13: 3049-52.
13. Kirkwood BR, Sterne JAC. Calculation of required sample size. Essential Medical Statistics. 2nd Ed. United Kingdom: Blackwell Science. 2003;420-1.

14. Kiridi EK, Oriji PC, Ugwoegbu JU, Abasi IJ. Hysterosalpingography Findings among Women Presenting for Infertility Evaluation in Bayelsa State, South-South Nigeria. *J Adv Med Res.* 2022;34(5):7-17 DOI: 10.9734/JAMMR/2022/v341531292
15. Balen VF. Interpreting infertility, social science research on childlessness in a global perspective . Amsterdam. *Afr J Reprod Health* 2000; 4:120-2.
16. Danfulani M, Mohammed MS, Ahmed SS, Haruna YG. Hysterosalpingographic findings in women with infertility in Sokoto North-Western Nigeria. *Afr J Med Health Sci* 2014;13:19-23. DOI: 10.4103/2384-5589.139438
17. Okafor CO, Okafor CI, Okpala OC, Umeh E. The pattern of hysterosalpingographic findings in women being investigated for infertility in Nnewi, Nigeria. *Niger J Clin Pract* 2010;13: 264-7.
18. Onwuchekwa CR, Oriji VK. Hysterosalpingographic(HSG) pattern of infertility in women of reproductive age. *J Hum Reprod Sci* 2017; 10:178-84. DOI:10.4103/jhrs.JHRS_121_16
19. Aduayi OS, Akanbi GO, Akintayo AA, Aduayi VA. Hysterosalpingography findings among women presenting for gynaecological imaging in Ado-Ekiti, South Western Nigeria. *Int J Rreprod Contracept Obstet Gynecol* 2016; 5:1906-11. DOI: 10.18203/2320-1770ijrcog20161688.
20. Imo AO, Adeoye IS. Radiological assessment of the uterus and fallopian tubes in infertile women at Abakaliki, Nigeria. *Niger J Clin Pract* 2008; 11:211-51.
21. Bukar M, Mustapha Z, Tahir A. Hysterosalpingographic findings in infertile women: A seven year review. *Niger J Clin Pract* 2011; 14:168-70. DOI: 10.4103/1119-3077.84008.

22. Bello TO. Tubal abnormalities on hysterosalpingography in primary and secondary infertility. *West Afr J Med* 2006;25:130-3.
23. Obejide AO, Ladigo OA, Otolorin FO, Makamagola JD. Infertility in Nigerian women. A study of related physiological factors. *J Obst Gynaecol East Cent Afr* 1986:613.
24. Kiguli-Malwade E, Byanyima RK. Structural findings at hysterosalpingography in patients with infertility at two private clinics in Kampala, Uganda. *Afr Health Sci* 1994;4:178-81.
25. Elsie KM, Rosemary KB. Structural finding at hysterosalpingography in patients with infertility at private clinic in Kampala Uganda. *Afr Health Sci* 2004; 4:178-81.
26. Kitila T. Infertility investigation, sociodemographic characteristics and dropouts of infertile women at family guidance association in Ethiopia. *Ethiop Health Dev* 2000; 14:127-34.
27. Daniel A, Yewebdar N. Evaluation of the fallopian tubes in infertile women by hysterosalpingography in Tikur Anibessa Hospital, Addis Ababa, Ethiopia. *Int J Nurs Midwifery* 2011; 3:178-81.
28. Nwankwo NC, Akani CI. Pattern of hysterosalpingographic findings in infertility in Port Harcourt. *West Afr J Radiol* 2005; 12:15-19.
29. Mgbor SO. Pattern of hysterosalpingographic findings in gynaecological patients in Enugu. *Niger Med J* 2006; 47:14-6.
30. Adetiloye V. Hysterosalpingography in investigation of infertility: experience with 248 patients. *West Afr J Med*.1992;12(4):191-6.

31. Akinola RA, Akintola OI, Fabamwo AO. Pattern of genital tract abnormalities on hysterosalpingography in infertile patients in Ikeja, Nigeria. *Niger Postgrad Med J* 2009; 16:31-4.
32. Udobi SI, Aronu ME. Hysterosalpingographic findings in women with infertility in Awka, Anambra State, South-East Nigeria. *Niger J Surg Sci* 2017; 27:47-50. DOI: 10.4103/njss.njss_3_18.
33. Eze CU, Ohagwu CC, Abonyi LC, Njoku J, Iruhe N, Igbinedion FO. A spectrum of . hysterosalpingographic findings in infertile women in Benin City Nigeria. *J Reprod infertile* 2013; 4:13-8. DOI: 10.5829/idosi.jri.2013.4.2.7692.
34. Makwe CC, Ugwu AO, Sunmonu OH, Yesuf-Awesu SA, Ani-Ugwu NK, Olumakinwa OE. Hysterosalpingography findings of female partners of infertile couple attending fertility clinic at Lagos University Teaching Hospital. *Pan Afr Med J*.2021;40;223. DOI:10.11604/pamj.2021.40.223.29890.
35. Philips CH, Benson CB, Ginsburg ES, Frates MC. Comparison of uterine and tubal pathology identified by Transvaginal sonography, Hysterosalpingography, and hysteroscopy in female patients with infertility. *Fertil Res Pract*. 2015; 1:20. DOI:10.1186/s40738-015-0012-3
36. Maheshwari A, Hamilton M, Bhattacharya S. Effect of female age on diagnostic categories of infertility. *Hum Reprod Oxf Engl* 2008;23(3):538-42. DOI: 10.1093/humrep/dem431.

Author`s contribution:

VNA: Concept, design, manuscript preparation, data analysis, editing and review. N-EEI and GJA: editing and review. All authors read and approved the final manuscript.

UNDER PEER REVIEW