

# Magnetic Resonance Imaging in Trigeminal Neuralgia

## Abstract:

### Background:

Trigeminal neuralgia (TN) is still a serious neurologic condition that causes significant facial pain that is unilateral and is distributed across the trigeminal nerve. Magnetic resonance imaging (MRI) is an excellent imaging technique for determining the aetiology of TN, despite the fact that there are no particular clinical tests for its diagnosis. 3D FIESTA MRI helps to improve diagnostic precision and identify neurovascular compression when used in conjunction with conventional MRI. MRI is used to rule out alternative causes of TN, such as cerebellopontine angle lesions, demyelinating diseases, and inflammatory conditions, in addition to neurovascular compression.

**Aim of the work:** The objective of this study was to assess the utility of MRI in the diagnosis of TN and its various causes.

**Patients and Methods:** In this prospective study, 30 patients (14 men and 16 women), with an average age of 49.6 years, were referred to Tanta University Hospital's Radiodiagnosis and Medical Imaging Department from outpatient neurosurgery and/or dental clinics.

**Results:** The commonest affected side was the left side (46.7%) followed by the right one (40%), while bilateral affection was seen in (13.3%) of cases. According to aetiological factor, TN was secondary to underlying pathology in 24 cases (80%), while idiopathic TN with no underlying pathology was found in 6 cases (20%). Neurovascular compression and neoplastic lesions had the higher incidence. The most affected segment of the trigeminal nerve was the cisternal segment that was involved in 15 cases out of 24 cases with abnormal MRI findings.

**Conclusion:** Many CPA lesions may cause TN such as schwannomas and meningiomas. Demyelinating disease as multiple sclerosis were reported in our study to cause also TN. MRI showed that it has significant diagnostic role denoting brain lesions in patients with TN as it has a diagnostic accuracy 62.5%, sensitivity 60% and specificity 100% ( $P < 0.001$ ).

**Keywords:** Magnetic Resonance Imaging, Trigeminal Neuralgia

## Introduction:

Neuropathic face pain is a symptom of trigeminal neuralgia (TN). It is the most prevalent type of face neuropathic pain in the elderly and affects women more frequently than men (1).

TN is classified as either "classical TN," "secondary TN," or "idiopathic TN" in the third edition of the International Classification of Headache Disorders (ICHD-3). Classic TN covers vascular compression-related illnesses, whereas secondary TN includes TN brought on by an underlying condition such multiple sclerosis (MS) or a tumour on the trigeminal nerve. When there is no evident cause, TN is referred to as idiopathic TN (2).

TN is characterised clinically by paroxysmal, stereotyped bouts of frequently severe, acute, superficial, or stabbing pain in the region of one or more trigeminal nerve branches. The TN pain usually comes in paroxysms and is at its worst right when it starts. Painful facial muscular spasms can be observed. Many people describe the pain as electric, shocking, or stabbing. It often lasts one to several seconds, although it can also happen repeatedly.

Between pain paroxysms, some people with chronic TN may experience ongoing dull discomfort. TN generally does not cause patients to wake up at night, unlike some other facial pain syndromes. TN is usually one-sided. Sometimes the pain is bilateral (3).

The trigeminal neural distribution's typical pain paroxysms serve as the foundation for the diagnosis of TN. Once the clinical suspicion of TN has been established, a search for secondary reasons should be made (4).

Neuroimaging is advised for all patients with suspected TN to help differentiate between classic TN and secondary TN as well as idiopathic TN. Both CT and MRI can be

used for neuroimaging of the brain, however MRI with and without contrast is often favoured due to its better resolution, which makes it possible to image the trigeminal nerve and minor nearby lesions (5).

Different kinds of TN are predicted to exhibit a wide range of MRI results. The superior cerebellar artery creates the vascular loop that compresses one of the trigeminal nerve branches in classic TN, as seen on MRI (using high-resolution T2WI thin slices sequences and MRA). If available, high-resolution MRI with thin slices along the trigeminal nerve's route and significant T2 weighting (for example, a constructive interference in steady state [CISS] fusion study) is the preferable imaging technique. Additionally, vascular compression may be detected via magnetic resonance angiography (MRA) (6). When in secondary TN, MRI will show the primary neurologic condition that is the source of the neuralgia.

A tumour at the cerebellopontine angle or MS (the preferred sequences are FLAIR and T2WI, but delayed post contrast study may give advantage of detecting active disease) is the primary cause of TN in 15% of patients. MRI with contrast is mandatory in the diagnosis of space-occupying lesions and delineation of their extensions and effects. The majority of tumours that cause TN are benign, and they often compress the root close to where it enters the pons. There is speculation that the compression causes paroxysmal ectopic discharges and localised demyelination. Axonal degeneration is more likely to be caused by malignant tumours infiltrating the nerve. Malignant tumours may induce trigeminal pain, however it often differs from pain bouts like those in TN (7).

Finally, in idiopathic TN, MRI brain scans will be normal (in all sequences) with no abnormalities found along the trigeminal course; however, MRI scans are necessary to rule out the possibility of secondary TN (8).

### **Patients and Methods**

This prospective study involved 30 patients (14 males and 16 females), their mean age was (49.6) years old who were referred from out clinics (neurosurgery and/or dental clinics) to Radiodiagnosis and Medical Imaging Department at Tanta University Hospital.

**Patient demographics:** Age, gender, and complaint were all acquired from the patients as part of their complete medical histories.

#### **Inclusion criteria:**

Patients with paroxysmal facial pain with or without other neurological symptoms or signs

#### **Exclusion criteria:**

1. Dental and psychological causes.
2. Patients who have a cardiac pacemaker.
3. Patients who have a metallic foreign body in their eye.
4. Patients with movement disorder that cannot be controlled.
5. Patients who have a hypersensitivity to the contrast or renal impairment.
6. Patients with claustrophobia.

#### **Each patient underwent the following:**

1. Clinical assessment
2. Neurological examination
3. MRI examination
  - MRI sequences:
  - 3D FIESTA
  - T1WI
  - T2WI
  - FLAIR images
  - T1 C+ (Gd)
  - Diffusion weighted images (DWI)

**Image assessments:**

- Evaluation of the trigeminal-pontine angle in individuals with idiopathic TN
- Measuring the trigeminal nerve's cisternal length and the cross-sectional area of the CPA cistern bilaterally in individuals with primary TN.
- Smaller CPA cisterns and short cisternal trigeminal nerves impact the pathogenesis of essential TN by facilitating the neurovascular conflict, particularly in younger individuals, smaller CPA cisterns and short cisternal trigeminal nerves have an impact on the aetiology of essential TN by promoting the neurovascular conflict.
- Following evaluation of neurovascular compression of the trigeminal nerve on the side of pain as well as the opposite side in TN patients:

**Statistical analysis:**

- Data were shown as a mean or a number.
- When comparing the mean of a continuous variable between two groups, the Student t-test was used to compare the distribution of the variable.
- When comparing the mean of a variable across more than two groups, the ANOVA test was used to compare normally distributed continuous variables.
- The appropriate Chi square test or Fisher's exact test was used to compare categorical variables.
- For all the evaluated criteria obtained by MRI, statistical analysis included calculation of sensitivity, specificity, accuracy, Positive Predictive Value (PPV), and Negative Predictive Value (NPV).
- P-value less than 0.05 were taken into account statistically.

**Result:**

This is a prospective study, consists of 30 cases who presented clinically with T.N, Males represent 46.7% and females represent 53.3% of the study group. Age study ranges from 5 to 65 years with mean  $46.23 \pm 13.63$  years. We found that the most affected decade (30 - > 40 yrs.) and females more affected than males (16 / 30 patients) (table 1).

Table 1: Age and sex distribution of the study group (n=30)

Age(yrs.)	SEX		Total No.	%
	Male	Female		
0 - < 10	-	1	1	3.33
10 - < 20	-	-	0	0
20 - < 30	2	-	2	6.67
30 - < 40	1	7	8	26.67
40 - < 50	3	2	5	16.67
50 - < 60	3	4	7	23.33
60 - < 70	5	2	7	23.33
Total	14	16	30	100

This table showed that left sided TN was more common (46.7%) in comparison to righted sided ones (40%) and bilateral TN was present only in 4 cases (13.3%) (table 2).

Table 2: Lateralization of TN in 30 patients of our study

Lateralization	N	%
Left	14	46.7
Right	12	40
Bilateral	4	13.3
<i>Total</i>	30	100

All 30 cases of our study underwent MR examination. Out of 30 included patients who presented with TN. 9 cases showed tumors (30%), 7 patients showed vascular causes (23.3%), 6 cases were idiopathic (20%) and 4 with MS (13.3%), and last 4 one with pontine-infarction as shown in table 3.

Table 3: MR aetiological classifications of 30 cases of our study

Aetiology of diagnosis	N	%	Chi square	P.value
Multiple sclerosis	4	13.3	3	0.5578
Post Stroke	4	13.3		
Tumor	9	30		
Vascular	7	23.4		
Idiopathic	6	20		
<b>Total</b>	<b>30</b>	<b>100</b>		

The 30 patients who included in this study and presented by TN were classified through MR examination into; three categories according to the aetiology of TN; into: Classical TN (vascular compression) in 6 patients. Secondary TN in 18 patients (9 with tumors, 4 with MS, 4 with pontine-infarction and 1 patient with cavernous hemangioma). Idiopathic in 6 cases as shown in table 4. We found that secondary type were the most common cause (18/30) 60%.

Table 4: MR aetiological classifications of 30 patients with TN

Type of TN	No. of cases	%
I. Classical type (vascular compression)	6	(6/ 30) 20%
II. Secondary type	18	(18/ 30) 60%
▪ Tumors	9	
▪ MS	4	
▪ Infarction	4	
▪ Vascular malformation	1	
III. Idiopathic type	6	(6/ 30) 20%
<b>Total NO.</b>	<b>30</b>	<b>100%</b>

The secondary type of TN was the most common type (18/30) 60%;(9 with tumors, 4 with MS, 4 with pontine-infarction and 1 patient with cavernous hemangioma). Benign tumors were the most common cause of TN (secondary type); (8/18) (44.44%) and Schwannoma were the most common (5 cases) (3 with Trigeminal Schwannoma and 2 with Acoustic Schwannoma) (table 5).

Table 5: TN classifications of secondary type according to aetiology

Lesion	N	%
Tumors:		
- Benign	8	(9/18) 50%
• Trigeminal Schwannoma	3	
• Acoustic Schwannoma	2	
• Epidermoid Cyst	1	
• Meningioma	2	
- Malignant	1	
• Glioma	1	
Pontine-Infarction	4	(4/18) 22.22%
Cavernous Hemangioma	1	(1/18) 5.56%
Multiple Sclerosis	4	(4/18) 22.22%
<b>Total</b>	<b>18</b>	<b>100</b>

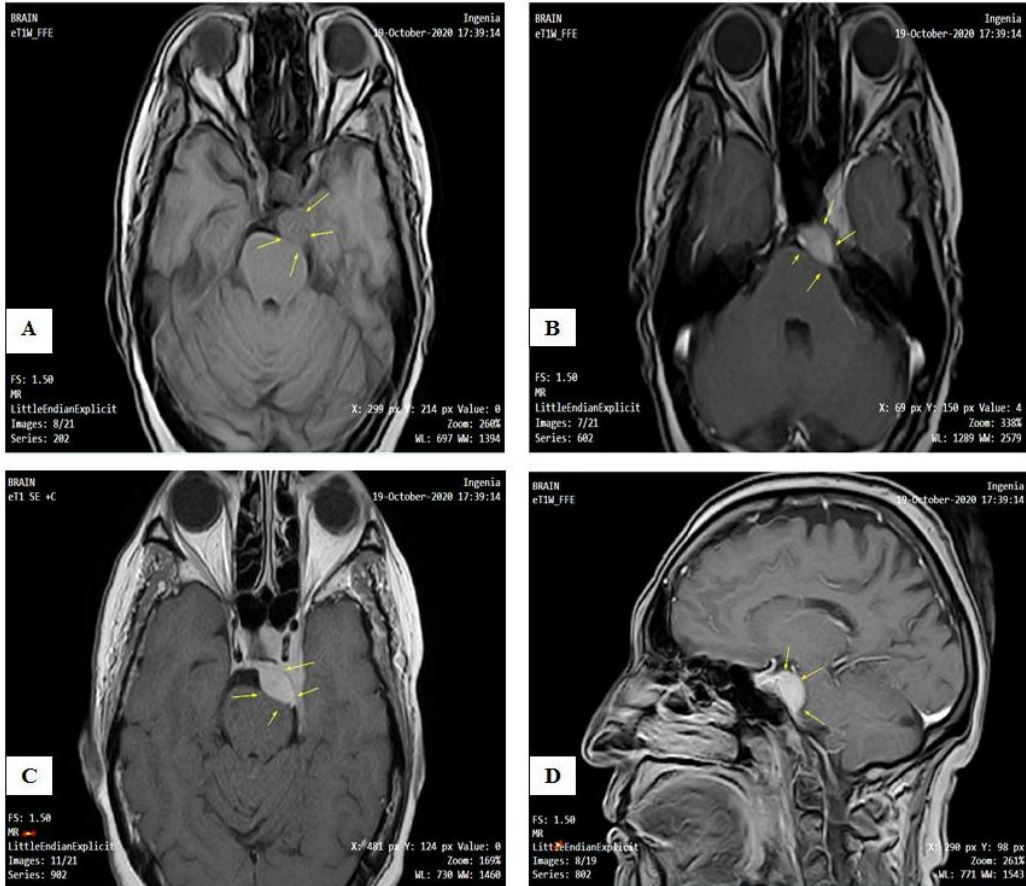


Fig. 1: Female patient 64 years old, presented by left sided trigeminal neuralgia. MRI brain revealed: (A) axial T1WI, (B)axial FLAIR WI and (C & D) axial and sagittal T1 WI post contrast revealed a small well defined extra axial petrous apex space occupying lesion (Mass) seen in the left prepontine cistern and supra-sellar cistern measures about 2.1x1cm exhibits intermediate T1 and T2 signal intensities with intense homogeneous contrast enhancement with enhancing dural tail along the dorsum sellae. It exerts mild mass effect in the form of mild compression of the left side of the pons. It is more to be consistent with extra axial SOL (left petrous apex meningioma).

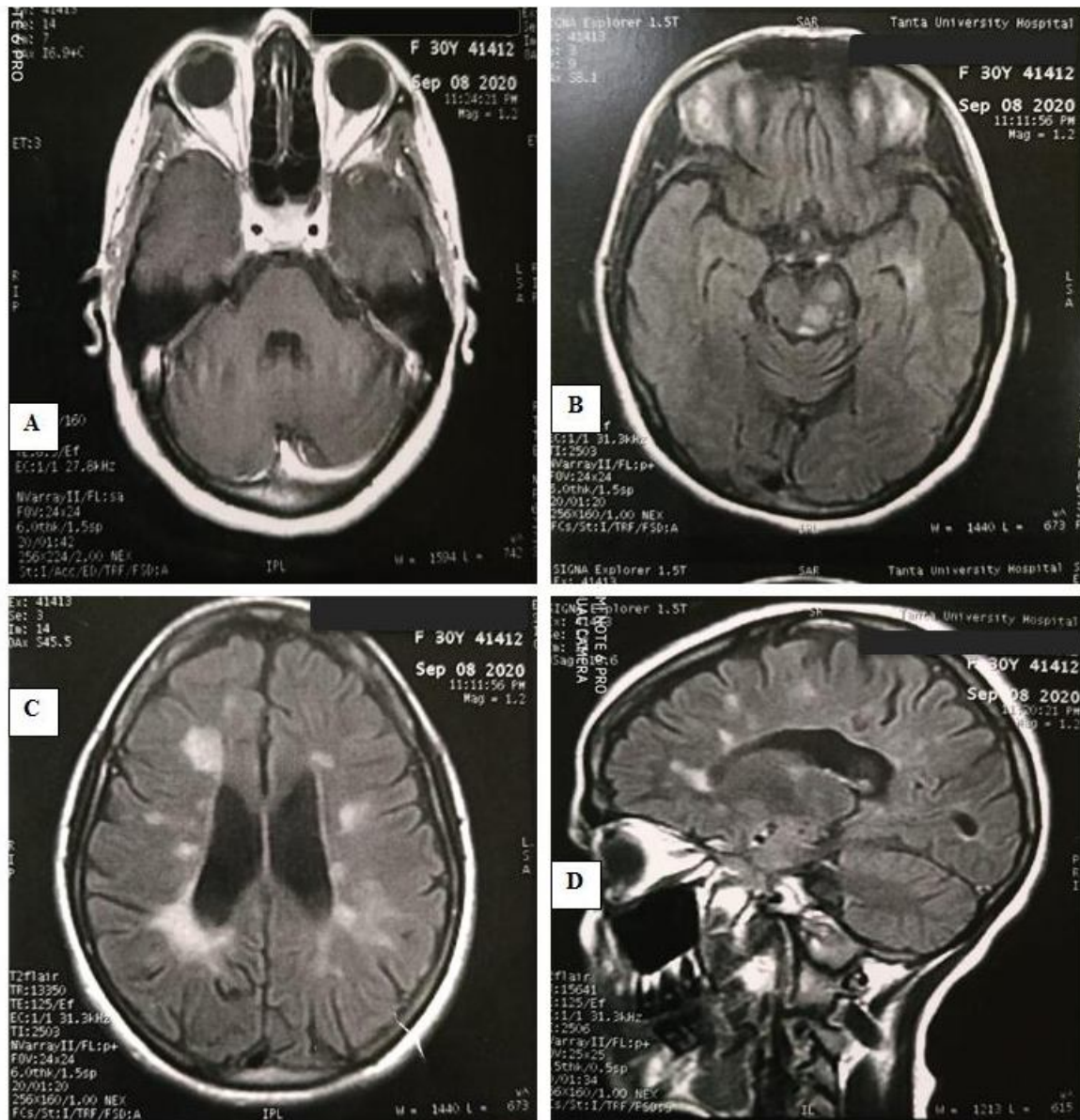


Fig. 2: Female patient 30 years old, presented by left sided trigeminal neuralgia. MRI brain revealed: (A) axial T1WI, (B,C,D) axial & sagittal FLAIR images revealed multiple variable sized patches of altered signal intensity in the form of bright T2 & FLAIR signal seen in white matter on both deep temporo-parietal region & both centrum semiovale oriented perpendicular to corpus callosum and calloso-septal space (downs fingers), left side of midbrain. Multiple sclerotic plaques in a known case of MS.

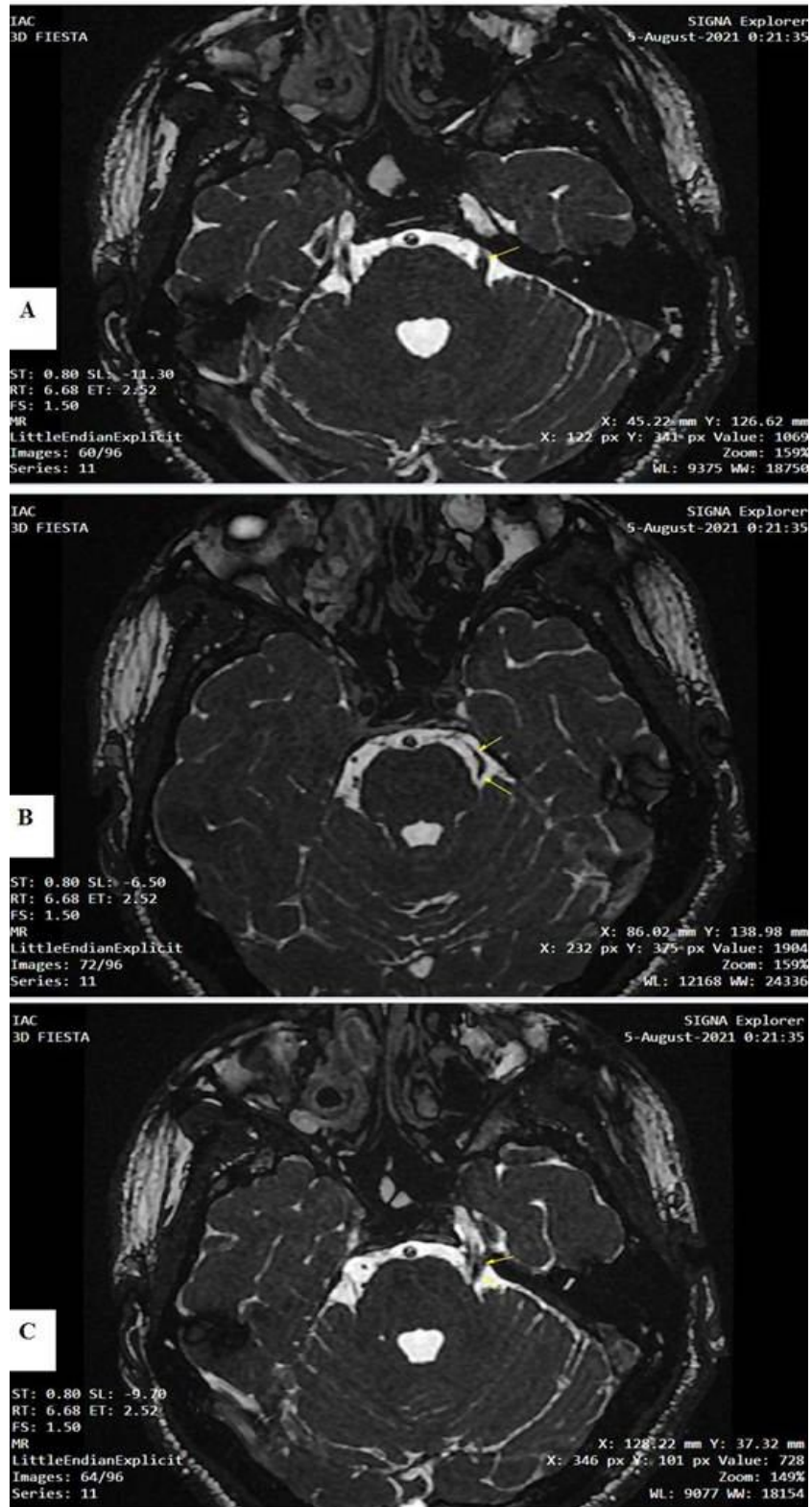


Fig. (3): Male patient 23 years old, presented by left sided trigeminal neuralgia. MRI brain revealed: (A,B,C) axial FIESTA images revealed a vascular loop, the left cerebellar artery, mildly deforming the root entry zone (REZ) of the cisternal segment of the left CN V. The finding consistent with left side vascular loop grade II.

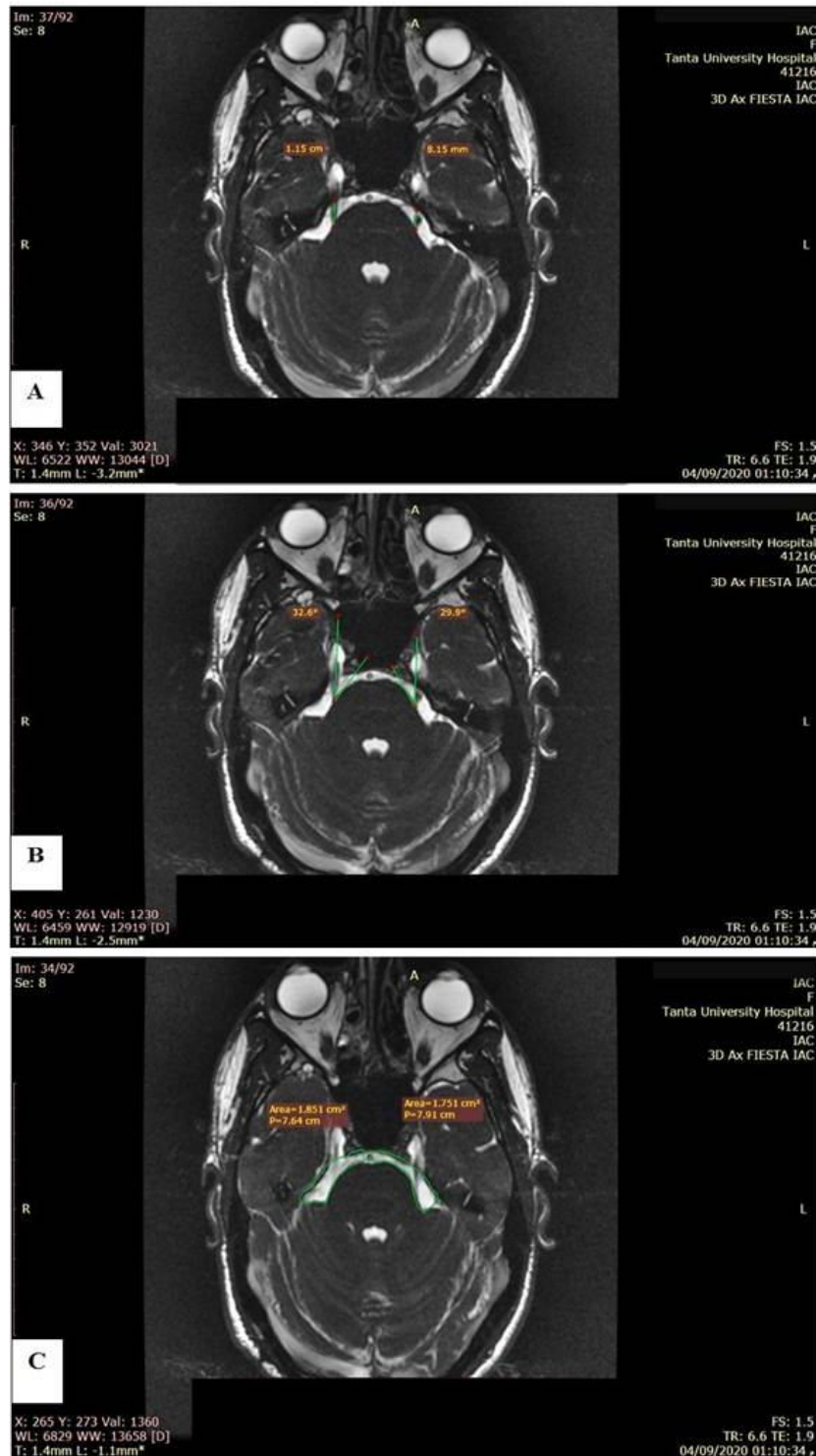


Fig. (4): Male patient 49 years old, presented by left sided trigeminal neuralgia. MRI brain revealed: (A, B & C) Axial FIESTA images revealed length of cisternal part of trigeminal nerve, trigeminal pontine angle and cross sectional area of CPA cistern respectively. Length of cisternal part of right trigeminal nerve (10mm) & length of cisternal part of left trigeminal nerve (8.15mm). Right trigeminal pontine angle measures about  $32.6^\circ$  & left trigeminal pontine angle measures about  $29.9^\circ$ . Cross sectional area of right CPA cistern measures about  $1.85 \text{ cm}^2$  and left cross sectional area of CPA cistern measures about  $1.75 \text{ cm}^2$ . All measures of the left side are less than those in right side. (Idiopathic case of left side trigeminal neuralgia).

## **Discussion and conclusion :**

The largest cranial nerve, the trigeminal nerve, is divided into five segments: the brainstem, the cisternal, Meckel's cave, the cavernous sinus, and the peripheral portions. It is widely dispersed throughout the face and is in charge of the face's primary sensory supply. TN can be caused by a variety of benign and malignant neoplasm tumours (9). Clinicians have conducted a variety of studies to categorise atypical facial aches in order to give a framework with which to establish an accurate diagnosis and to adequately advise on treatment options and prognosis (9).

One of the most unpleasant types of facial discomfort is TN. It is characterised by transient electric shock-like pains that are localised to one or more trigeminal nerve divisions and are abrupt in their onset and termination. History and clinical examination can diagnose TN, but radiographic imaging analysis is required to detect any cerebral pathology (10).

Since clinical signs of TN frequently make it difficult to pinpoint the exact location of lesions, MRI is beneficial for visualising the trigeminal nerve's entire course and detecting abnormalities (11).

Our study's goal was to evaluate the value of magnetic resonance imaging in the identification of TN's intracranial origin.

This prospective study recruited 30 patients (14 men and 16 women) with paroxysmal face pain and/or other neurological symptoms or signs who were referred to Tanta University Hospital's Radiodiagnosis and Medical Imaging Department from outpatient clinics (neurosurgery and/or dental clinics).

TN was present in the research participants for a variety of reason.

Their average age was 46.23 13.63 years, with ages ranging from 5 to 65.

In a study by Geneidi et al. (2016) (12), 45 patients (28 males and 17 females) with trigeminal pain with or without other associated neurologic symptoms and signs were included. The aim of the study was to assess trigeminal pain cases by MRI to assess the underlying pathology and to correlate the imaging findings with the clinical data. The study found that the mean age was lower. At the time the study was presented, the average age was 37.57 11.8 years. Our recent study found that left-sided trigeminal affection predominated, appearing in 14 patients (or roughly 46.7% of cases), while right-sided trigeminal affection was noted in 12 patients (or roughly 40% of cases), and bilateral trigeminal affection was noted in 4 patients (or roughly 13.3% of cases).

A 24 patients (80%) in our current study were caused by secondary diseases. To study and categorize brain magnetic resonance imaging findings in patients aged >18 years who presented with clinical symptoms of TN, Rangaswamy et al. (2016) (13) included the clinical records and imaging studies of 75 patients who presented to the Department of Radio-diagnosis. They identified a percentage of cases (76%) that were due to various diseases that was almost identical.

Furthermore, 50 patients in the age range of 30-65 years who visited the outpatient Department with trigeminal pain were included in a study by Swetha et al. (2018) (14) that was published in the journal Pain. To compare MRI results with clinical information, a specialized trigeminal nerve protocol was used during brain imaging. According to the study, 28 patients (56%) had an underlying pathology.

Out of 24 patients in our study who had secondary TN, 9 cases (30%), 6 cases (20%), and 4 cases (13.3%) had tumours or vascular loops.

According to a study by Liu et al. (2013) (15), which included 16 TN patients and 6 healthy controls, the trigeminal nerve's microstructural tissue changes in patients with unilateral TN were examined. The study used a 3.0 T system and three-dimension time-of-flight magnetic resonance angiography to image the trigeminal nerve. According to their findings, the afflicted

trigeminal nerve's primary pathological foundation is demyelination without severe axonal destruction.

In addition, Swetha et al (2018) .'s research (14) According to the study, 6 (12%) patients had pain from a prior trigeminal injury, while 9 (18%) patients had tumours, 12 (24%) patients had vascular anomalies, including anatomical variants, vascular loops, and vascular malformations.

The reason for our study's substantially greater ratio of TN secondary to CPA lesions compared to previous studies may be due to the fact that the physicians at our centre immediately referred any case with accompanying symptoms on the same side of TN for imaging.

Out of the 30 patients in our study, 8 cases had CPA lesions, and they were as follows: Acoustic schwannomas in three cases, trigeminal schwannomas in two cases, meningiomas in two cases, and an epidermoid cyst in one case.

Rangaswamy et al. (2016) (13) described two cases of trigeminal schwannomas, two cases of vestibular schwannomas, one case of epidermoid cyst, and one case of arachnoid cyst, and this was somewhat comparable to those cases.

Also reported as a frequent MRI finding in patients with trigeminal pain associated with MS were demyelinating plaques of multiple sclerosis involving intra-pontine trigeminal nuclei (16).

Out of the 30 individuals in the current investigation, four (13.3%) had MS plaques in the pons; two of these cases had isolated unilateral TN and one had bilateral TN.

### **Recommendation:**

To identify any idiopathic cases of TN in all cases reported to be normal by MRI, a FIESTA sequence must be run on the following measurements:

1. Trigeminal pontine angle.
2. Length of cisternal part of Trigeminal nerve.
3. Cross sectional area of CPA cistern.

### **Limitations:**

There were a few drawbacks to this study, including the small number of cases, the lack of a post-operative correlation of neurovascular compression, and the lack of a post-operative follow-up of pain relief in surgical patients. Idiopathic TN cases were frequently taken into consideration by clinicians, and they frequently began conservative treatment without referring patients for imaging.

### **Ethical Approval and Consent**

- The study was accepted by the Research Ethics Committee of Faculty of Medicine Tanta University before starting the field work.
- An informed consent was signed by all the patients.
- Explanation of the study aim in a simple manner to be understood by the common people.
- The patient had the right to get a copy from the informed consent.
- No harmful maneuvers were performed or used.
- All data were considered confidential and did not used outside this study without patient's approval.
- All patients were notified with the results of imaging.
- Patients had the right to withdraw from the study at any time without giving any reason and were excluded from the study.
- The patient did not pay for any investigations in the research.

## References:

1. **Arnold M (2018):** Headache classification committee of the international headache society (IHS) the international classification of headache disorders. *Cephalalgia*; 38(1):1-211.
2. **Cruccu G, Finnerup NB, Jensen TS, et al. (2016):** Trigeminal neuralgia: new classification and diagnostic grading for practice and research. *Neurology*; 87(2):220-8.
3. **Haanpää M, Attal N, Backonja M, et al. (2011):** NeuPSIG guidelines on neuropathic pain assessment. *PAIN®*;152(1):14-27.
4. **Lamburu G and Matharu MS (2014):** SUNCT, SUNA and trigeminal neuralgia: different disorders or variants of the same disorder? *Current Opinion in Neurology*; 27(3):325-31.
5. **Lin KH, Chen YT, Fuh JL, et al. (2016):** Increased risk of trigeminal neuralgia in patients with migraine: A nationwide population-based study. *Cephalalgia*; 36(13):1218-27.
6. **van Kleef M, van Genderen WE, Narouze S, et al. (2009):** Trigeminal neuralgia. *Pain Pract*; 9(4):252-9.
7. **Panczykowski DM, Frederickson AM, Hughes MA, et al. (2016):** A blinded, case-control trial assessing the value of steady state free precession magnetic resonance imaging in the diagnosis of trigeminal neuralgia. *World Neurosurgery*; 89:427-33.
8. **Truini A, Barbanti P, Pozzilli C, et al. (2013):** A mechanism-based classification of pain in multiple sclerosis. *Journal of Neurology*; 260(2):351-67.
9. **Donia MM, Gamaleldin OA, Abdo AM, et al. (2017):** Intracranial neoplastic lesions of the trigeminal nerve: How MRI can help. *Egypt J Radiol Nucl Med*; 48(4):1035-41.
10. **Eller JL, Raslan AM and Burchiel KJ (2005):** Trigeminal neuralgia: definition and classification. *Neurosurg Focus*; 18(5):E3.
11. **Chen ST, Yang JT, Yeh MY, et al. (2016):** Using Diffusion Tensor Imaging to Evaluate Microafter Radiofrequency Rhizotomy of Trigeminal Nerves in Patients with Trigeminal Neuralgia. *PLoS ONE*; 11(12):e0167584.
12. **Geneidi EAS, Ali HI, Abdel Ghany WA, et al. (2016):** Trigeminal pain: Potential role of MRI. *The Egyptian Journal of Radiology and Nuclear Medicine*; 47(4):1549-55.
13. **Rangaswamy VK, Srinivas MR, Basavalingu D, et al. (2016):** The Role of Magnetic Resonance Imaging in the Evaluation of Trigeminal Neuralgia. *Int J Anat Radiol Surg*; 5(2):24-9.
14. **Swetha S, Kejriwal GS and Madhavi C (2018):** Role of Magnetic Resonance Imaging in Evaluating Various Causes of Trigeminal Neuralgia. *Int J Sci Res*; 7(6):127-30.
15. **Liu Y, Li J, Butzkueven H, et al. (2013)** Microstructural abnormalities in the trigeminal nerves of patients with trigeminal neuralgia revealed by multiple diffusion metrics. *Eur J Radiol*; 82(5):783-6.
16. **Anderson VC, Berryhill PC, Sandquist MA, et al. (2006):** High resolution three-dimensional magnetic resonance imaging in the evaluation of neurovascular compression in patients with trigeminal neuralgia. A double-blind pilot study. *Neurosurgery*; 58:666–673.