

Deep vein thrombosis and Phlegmasia cerulea dolens of the Lower limbs: An unusual presentation and an unknown etiology.

ABSTRACT

Deep vein thrombosis is the most frequent Venous thromboembolic event seen among individuals with hematological diseases which is associated with high morbidity and mortality. and it is associated with various risk factors. It mainly affects the deep veins of the lower extremities and the pelvic. Phlegmasia dolens is an uncommon skin condition associated with or caused by acute deep vein thrombosis and presents in three clinical subtypes such as phlegmasia alba dolens, phlegmasia cerulea dolens, and venous gangrene.

We report a 29-year-old obese female patient who was admitted via the accident and emergency section of the hospital with a history of sudden onset of pain in both lower limbs, colicky abdominal pain, 4 episodes of passage of loose stool, and 8 episodes of non-projectile, non-bilious vomiting. Compressive ultrasonography revealed evidence of occlusion of both external iliac veins and the biopsy of the skin showed the presence of neutrophilic vesicles in the epidermis suggestive of phlegmasia cerulea dolens.

In conclusion, phlegmasia cerulea dolens is a rare clinical skin condition that must be kept in mind by clinicians, especially in patients with a history suggestive of venous thrombosis.

Keywords: Anticoagulant therapy, phlegmasia alba dolens, phlegmasia cerulea dolens, deep vein thrombosis.

1. INTRODUCTION

Thrombosis is the formation of an abnormal mass or blood clot from the constituent of blood within the vascular system often leading to total or partial obstruction to blood flow. When it involves the deep veins in the body, it is called Deep Vein Thrombosis (DVT) [1]. It is commonly seen in the veins of the lower limbs, pelvic, and occasionally in the upper limbs [1]. A timely and accurate diagnosis of DVT is very important to avoid potential acute complications, mainly in the pulmonary circulation such as pulmonary embolism, and pulmonary hypertension, a chronic complication such as post phlebitis syndrome [2]. DVT occurs at an annual incidence of about 1 per 1,000 adults. The incident of DVT increases with increase in age and are slightly higher in men than women in older age. Risk factors for DVT, other than age, include

hospitalization, prolonged immobility, trauma, malignancies, pregnancy, and the puerperium, hormone use, obesity, and inherited and acquired disorders of hyper coagulation [2].

The cutaneous manifestations of DVT are generally nonspecific, but the identification of an abnormal skin finding should warrant a further workup for possible underlying thrombophilic disorders [3]. The skin disorders associated with DVT include purpura fulminans, livedo reticularis, livedo vasculopathy, anetoderma, chronic venous ulcers [3], and very rarely phlegmasia cerulea dolens [4], and phlegmasia alba dolens [5]. Phlegmasia cerulea dolens (PCD) is an uncommon but potentially life-threatening complication of acute DVT characterized by marked swelling of the extremities with pain and cyanosis, which in turn may lead to arterial ischemia and ultimately cause gangrene with high amputation and mortality rates [6]. It is most commonly seen in the upper limbs [6] but rarely in the lower limbs [7].

2. CASE SUMMARY

A patient aged 29 years, without any history of chronic medical conditions, presented with a history of sudden onset of pain in both lower limbs, colicky abdominal pain, 4 episodes of passage of loose stool, and 8 episodes of non-projectile, non-bilious vomiting, evolving in the context of fever which subsided with use of antipyretics. The physical examination found a febrile patient (Temperature was 38.9⁰C), conscious, alert, and in painful distress. Multiple, hyperemic, bullous skin lesions of varying sizes sparing the soles of the feet were noted in both lower limbs with edema up to thighs bilaterally with differential warmth. (Figure 1)

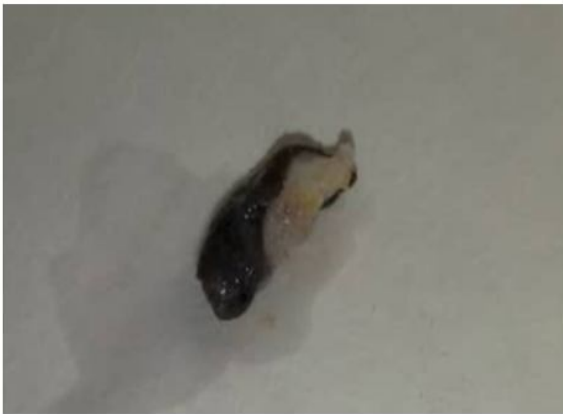

Figure 1 shows multiple hyperemic fluid filled skin lesions of varying sizes on both lower limbs.

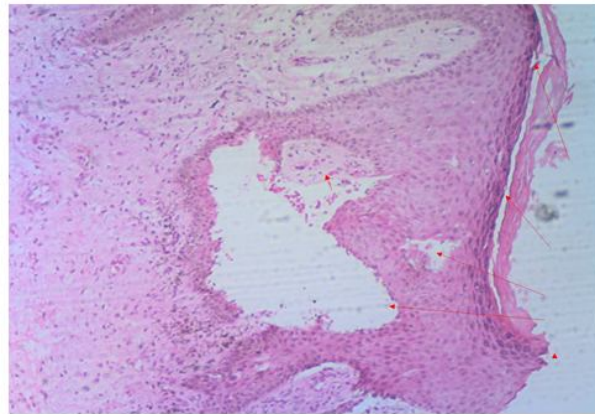
Respiratory rate was 18cycles per min. oxygen saturation was 98% in room air. The pulse rate was 88 beats per min with a blood pressure of 125/72mmHg. Cardiopulmonary auscultation was unremarkable. The abdomen was full, moves with respiration, with tenderness in the right iliac region. The liver, spleen, and kidneys were not palpably enlarged, there were no demonstrable

ascites. CNS examination was essentially normal. The biological workup showed a Full Blood Count that revealed a total White Cell count of $7.45 \times 10^9/L$, with neutrophilic dominance, packed cell volume of 35.2%, and thrombocytopenia at $161,000 \times 10^9/L$.

Bilateral venous and arterial Doppler of both lower limbs showed plasticity to respiration, aliasing, phasic flow, and non-compressible external Iliac veins bilaterally, highly suggestive of acute deep vein thrombosis of both lower limbs with the involvement of the external iliac veins. The peripheral blood film revealed essentially normochromic normocytic Red Blood cells (RBCs); and Left shift neutrophils with toxic granules. Blister aspirate culture did not yield significant growth after 48 hours. Erythrocyte Sedimentation rate was $>100\text{mm}/\text{hour}$. Electrolytes and Urea levels were essentially normal. However, High-Density Cholesterol (HDL) of $0.5\text{mmol}/L$ was markedly reduced. The electrocardiogram was essentially normal. The d-Dimer level was $4020 \text{ ng}/\text{ml FEU}$ (reference range $< 500\text{ng}/\text{ml FEU}$) and the prothrombin time was 16 seconds with an International Normalized Ratio (INR) of 1.0. Retroviral, Hepatitis B, and C screens were all non-reactive. Pregnancy test was negative. An abdomino-pelvic ultrasound scan revealed the presence of a huge uterine leiomyoma above the cervical opening. A skin biopsy was done while on admission revealed the infiltration of the epidermis by neutrophils and the presence of multiple vesicles with a diagnosis of Phlegmasia cerulea dolens. (Figure 2)



2(a)



2(b)

Figure 2: (a) shows the gross appearance of the skin biopsy sample. (b) Shows skin biopsy in medium magnification with H& E staining revealing neutrophilic infiltration of the epidermis and multiple vesicles (red arrows).

An assessment of bilateral Deep Vein Thrombosis involving external iliac veins complicated by bullous skin eruptions (Phlegmasia cerulea dolens) was made. The patient was rehydrated with saline, antibiotic treatment with intravenous Ceftriaxone and metronidazole for 2 weeks, a therapeutic dose of enoxaparin was administered at 80mg 12 hourly subcutaneously with 5 mg of warfarin nocte, and an oral analgesic was also administered for pain in the lower limbs. The fever resolved within 3 days, pain in both lower limbs improved after 6 days, and the skin lesion busted and attenuated noticed after 12 days on admission. The repeat INR on the 12th day of admission was 2.3. The patient was discharged home on the 15th day of admission on 15md Rivaroxaban bd. The patient was seen in the clinic a week after discharge, she is well and alive. The skin lesions were dry and showed evidence of healing.

3. DISCUSSION

Phlegmasia cerulea dolens (PCD) is a fulminant skin condition associated with acute massive venous thrombosis most commonly of the lower limb [8, 9]. Though uncommon, it may lead to venous gangrene if left untreated with the required urgency [8]. Phlegmasia cerulea dolens is associated with high limb amputation and mortality rates [9]. Gregoire in 1938 described it as a clinical triad of limb swelling, acute ischemic pain, and skin discoloration which he named phlegmasia cerulea dolens, which often leads to venous congestion and massive fluid sequestration in the skin and may lead to shock and possibly causing death [10]. The annual incidence of PCD is unknown because it is very uncommon and difficult to identify [8]. Risk factors include malignancy, obesity, connective tissue disorders, anti-phospholipid syndrome, thrombocytopenia, hypercoagulable states such as antithrombin III, protein C and protein S deficiency, pregnancy, and femoral vein catheterization [7, 9, 10].

The diagnosis of PCD is mainly clinical and supported by the demonstration of venous occlusion by compressive ultrasonography (CUS) which remains the standard for the diagnosis of venous thrombosis [10]. To date, no diagnostic criteria have been developed to aid in the early identification and diagnosis of PCD. Different treatment modalities have been used in the past to reduce morbidity and mortality in patients, and these include the early initiation of anticoagulation, followed by surgical thrombectomy and sometimes fasciotomy [11, 12, 13].

Our index case was a difficult clinical presentation of venous thrombosis which required early diagnosis and institution of anticoagulant to prevent tissue damage. Early recognition of PCD and collaboration with the clinical hematologist and the radiology team were critical in making an early diagnosis and the preservation of the limb and the patient's life, as seen in the reported case. However, additional studies are required to compare the efficacy of the use of anticoagulation therapy employed in our index case with other treatment modalities such as fasciotomy, and thrombectomy.

4. CONCLUSION

DVT is a potentially dangerous clinical condition that can lead to preventable morbidity and mortality. When associated with Phlegmasia cerulea dolens, can lead to higher mortality and high limb amputation rates. The main goal of therapy for venous thrombosis is to prevent the extension of the thrombus, its embolization to the lungs (acute PE), recurrence of thrombotic events, and the development of complications such as was seen in this index patient.

CONSENT

In accordance with international standards, the patient's consent has been collected and preserved by the authors.

ETHICAL APPROVAL

In accordance with international standards, verbal and written informed consent were collected and preserved by the authors.

REFERENCES

1. Cushman M. Epidemiology and risk factors for venous thrombosis. *Semin Hematol.* 2007 Apr;44(2):62-9. doi: 10.1053/j.seminhematol.2007.02.004.
2. Kesieme E, Kesieme C, Jebbin N, Irekpita E, Dongo A. Deep vein thrombosis: a clinical review. *J Blood Med.* 2011 Apr;2:59-69. doi: 10.2147/JBM.S19009.
3. Thornsberry LA, LoSicco KI, English JC 3rd. The skin and hypercoagulable states. *J Am Acad Dermatol.* 2013 Sep;69(3):450-62. doi: 10.1016/j.jaad.2013.01.043.
4. Kou CJ, Batzlaff C, Bezzant ML, Sjulín T. Phlegmasia Cerulea Dolens: A Life-Threatening Manifestation of Deep Vein Thrombosis. *Cureus* 2020 Jun;12(6): e8587. doi:10.7759/cureus.8587
5. Saskin H. A rare Clinical form of deep vein thrombosis; Phlegmasia alba dolens. *Damar Cerrahi Dergisi* 2018 Jan;26(3):111-115. <https://doi.org/10.9739/uvcd.2014-42998>
6. Chaochankit W, Akaraborworn O. Phlegmasia cerulean dolens with compartment syndrome. *Ann Vasc Dis.* 2018, 11:355-357. doi: 10.3400/avd.cr.18-00030.
7. Abdul W, Hickey B, Wilson C. Lower extremity compartment syndrome in the setting of iliofemoral deep vein thrombosis, Phlegmasia cerulean dolens and factor VII deficiency. *BMJ Case Reports.* 2016, 2016:bcr2016215078. doi:10.1136/bcr-2016-215078.
8. Gardner-Medwin JMM, Dolezalova P, Cummins C, Southwood TR. Incidence of Henoch-Schönlein purpura, Kawasaki disease, and rare vasculitides in children of different ethnic origins. *Lancet*, 2002; 360(9341): 1197–202
9. Wood KE, Reedy JS, Pozniak MA, et al. Phlegmasia cerulea dolens with compartment syndrome: a complication of femoral vein catheterisation. *Crit Care Med* 2000;28:1626–30.

10. Den Boer SL, Pasmans SGMA, Wulffraat NM. Bullous lesions in Henoch Schönlein Purpura as indication to start systemic prednisone. *Acta Paediatr Oslo Nor* 1992, 2010; 99(5): 781–83
11. Abdul W, Hickey B, Wilson C: Lower extremity compartment syndrome in the setting of iliofemoral deep vein thrombosis, phlegmasia cerulea dolens and factor VII deficiency. *BMJ Case Reports*. 2016, 2016:bcr2016215078. 10.1136/bcr-2016-215078.
12. Veltchev LM, Kalniev MA, Todorov TA. Phlegmasia cerulean dolens- risk factors and prevention . *J IMAB*. 2009, 15:89-91.
13. Maiti A, Das A, Smith DT: Phlegmasia cerulea dolens. *Postgrad Med J*. 2016, 92:690. 10.1136/postgramedi-2016-134185.

UNDER PEER REVIEW