

## **Original Research Article**

### **OCULAR MANIFESTATIONS AND SOCIO-DEMOGRAPHIC FACTORS AMONG ADULTS ON HIGHLY ACTIVE ANTIRETROVIRAL THERAPY (HAART) IN ENUGU, NIGERIA**

#### **ABSTRACT**

**OBJECTIVE:** To determine the socio-demographic association, frequency and types of ocular manifestations of HIV/AIDS in adult HIV positive patients in Enugu.

**METHODS:** This was a cross-sectional descriptive study of 331 randomly selected, consenting adult HIV positive patients on Highly Active Anti-Retroviral Therapy (HAART) at the retroviral disease clinic of UNTH Enugu, Nigeria. Approval for the study was obtained from the institutional human research and ethical committee of the hospital. Data was obtained using an interviewer administered semi-structured questionnaire. Data analysis was with SPSS version 21. Their demographic data, frequency and pattern of ocular manifestations were presented in frequency and percentages. A p value of < 0.05 was used to define statistical significance at 95% confidence interval.

**RESULTS:** The hospital prevalence of HIV related ocular manifestations was 18.4%. HIV microangiopathy was the commonest (18.8%). Posterior segment ocular manifestations were the commonest (37.7%) observed class of HIV ocular manifestations. Of those with HIV related ocular manifestations, only 33.3% had a previous history of eye problem. There was no statistically significant association between the socio-demographic variables and the ocular findings.

**CONCLUSION:** Pharmacotherapy has altered the overall clinical course of HIV/AIDS. However, HIV related ocular manifestations are still common, No association was found between the demographic variables of the population and the ocular findings.

**KEYWORDS:** Ocular manifestations, HIV/AIDS, Enugu Nigeria, HAART

#### **INTRODUCTION**

Acquired immunodeficiency syndrome (AIDS) is a multisystem disease characterized by decreased body immunity with the onset of a number of opportunistic infections and tumors.<sup>1,2</sup> The etiology is human immunodeficiency virus (HIV), a retrovirus with elective tropism for the T-helper lymphocytes (CD4+) transmitted through blood and bodily fluids<sup>1,2</sup> via unsafe sex, parenteral route, and perinatal route.<sup>3,4</sup> Since the first case of acquired immunodeficiency

syndrome (AIDS) was diagnosed in 1981, the cases of human immunodeficiency virus (HIV) infection have been increasing worldwide.<sup>5,6</sup> The first cases of HIV/AIDS in Nigeria were reported in Lagos and Enugu in 1986 among commercial sex workers.<sup>7</sup> The ocular manifestations of HIV/AIDS, first reported by Holland et al,<sup>8</sup> may be the primary presentation of the disease<sup>9,10</sup> and can range from a simple blepharitis to blindness.<sup>11</sup>

These ocular manifestations can be classified pathologically or anatomically.<sup>12,13</sup> Pathologically, the categories include non-infectious retinopathy, opportunistic infections, unusual neoplasm and neuro-ophthalmic manifestations. Anatomically, the categories include orbital manifestations, adnexal manifestations, anterior segment manifestations, posterior segment manifestations and neuro-ophthalmic manifestations.

Publications on ocular lesions found in HIV and AIDS are focused on the developed countries, whereas about 90% of people living with HIV/AIDS are in the developing countries.<sup>14</sup> In addition, the spectrum and prevalence of ocular diseases in HIV-infected patients in developing countries differ from those in developed countries where most of the studies have been done.<sup>14,15</sup> Cytomegalovirus retinitis seems to be more prevalent in the developed countries, unlike in developing countries where herpes zoster ophthalmicus is more prevalent.<sup>16</sup>

The pattern of ocular manifestations also varies between the pre-HAART and HAART era. In the pre HAART era, the major battle was with opportunistic ocular infections, however with the introduction of HAART, conditions such as immune recovery uveitis (IRU) emerged.<sup>17,18</sup> This study is aimed at determining the ocular manifestations of HIV/AIDS and associated socioeconomic factors in [Adults on HAART in Enugu state] with a view to providing a database and making recommendations for improved ocular health for these patients.

Comment [DEU1]: Change the font and size to conform with the text

## MATERIALS AND METHODS

This was a descriptive cross-sectional study of HIV positive [adults on HAART] in Enugu state which is one of the 36 States of Nigeria. It is bounded on the north by Kogi and Benue States, on the east by Ebonyi State, on the west by Anambra State and on the south by Abia State. During the data collection period, about 120 to 150 patients were seen daily at the antiretroviral therapy (ART) clinic of the University of Nigeria Teaching Hospital, Enugu, which was the point of data collection. A systematic random sampling technique was used to select the participants. A total of 331 participants responded.

Comment [DEU2]: Different font and size

Consenting adult ( $\geq 18$  years) HIV positive patients were included in the study. Patients who due to impaired mental and/or physical state could not be examined or were pregnant were excluded. [Anterior and posterior segment examinations were conducted using ophthalmic equipment/accessories such as slit lamp biomicroscope, +90D lens. Pretested structured interviewer based questionnaires were used for data collection. The demographic data of the participants, frequency and pattern of ocular manifestations were recorded and presented in frequency and percentages. Data analysis was with Statistical Package for Social Sciences (SPSS) version 21. Chi square and Fisher's Exact test was used to test for association and a p value of  $< 0.05$  was considered significant. The tenets of the Helsinki declaration and the National code of Health research ethics of Nigeria were adhered to and ethical approval was

Comment [DEU3]: Different font and size

obtained from Health Research Ethics Committee (HREC) of the University of Nigeria Teaching Hospital, (UNTH) Ituku-Ozalla, Enugu, Nigeria, before the commencement of the study.

## RESULTS

Out of 331 patients who participated in the study, 252 (76.1%) were females. The male to female ratio was 1: 3.2. Participants were aged between 22 and 81years with a mean of  $43.6 \pm 9.9$  years. A total of 61 participants (18.4%) had ocular manifestation.

**Table 1: Relationship between socio-demographic factors and HIV Related Ocular Manifestations (HROM) (N=331)**

Socio demographics		Manifestation of HROM		Chi-square trend (Linear linear test)	P-value test by
		Absent	Present		
Age	< 25	2(0.7)	0(0.0)	0.637	0.524
	25-34	37(13.7)	7(11.5)		
	35-44	125(46.3)	24(39.3)		
	45-54	78(28.9)	18(29.5)		
	55-64	19 (7.0)	5(8.2)		
	≥65	9(3.3)	7(11.5)		
Educational Status	None	9 (3.3)	5(8.2)	0.57	0.620

	Primary	73(27.0)	16(26.2)		
	Secondary	106(39.3)	20 (32.8)		
	Tertiary	82 (30.4)	20 (32.8)		
				<b>Chi-square</b>	<b>P-</b>
				<b>Fisher's Exact</b>	<b>value</b>
Sex	Male	59 (21.9)	20 (32.8)	3.3	0.071
	Female	211 (78.1)	41(67.2)		
Marital Status	Single	50 (18.5)	13(21.3)		
	Married	122(45.2)	30 (49.2)	1.6	0.801
	Divorced	8(3.0)	2(3.3)		
	Separated	3(1.1)	0(0.0)		
	Widowed	87 (32.2)	16(26.2)		
Occupation	Civil Servant	62(23.0)	14(23.0)		
	Trader	95(35.2)	20(32.3)		
	farmer/Agricultural worker	29 (10.7)	8(13.1)	12.8	0.234

Artisan	35 (13.0)	14 (23.0)
Unemployed	32(11.9)	3(4.9)
Driver/ cyclist	4(1.5)	0(0.0)
Military/ Paramilitary	2(0.7)	0 (0.0)
Health worker	3(1.1)	0(0.0)
Self employed	7(2.6)	1(1.6)
Clergy	1(0.4)	0(0.0)
Student	0(0.0)	1(1.6)

Table 1 shows the relationship between socio-demographic factors and ocular manifestations of HIV. The mean age of those with ocular manifestations was  $45.0 \pm 11.6$  years. A majority (80.3%) of those with ocular manifestations were within the age range of 25–54 years. Females constituted 41 (67.2%) of those with ocular manifestations and [DoO17] most (30) of whom were married (49.2%). There was no statistically significant difference between these factors and the ocular findings. The mean  $CD4^+$  count for all participant was  $575.0 \pm 512.56$  cell/ $\mu$ l, while that of those with HROM  $315.2 \pm 290.76$  cells/ $\mu$ l. All (100%) those with  $CD4^+$  count  $<100$  cells/ $\mu$ l had HROM. Also, the mean duration of HAART for all participants was  $92.13 \pm 54.56$  months for which about 68% had been inconsistent with treatment at some point in the therapy.

The frequency and classes of ocular manifestations are shown in tables 2 and fig. 3 below respectively.

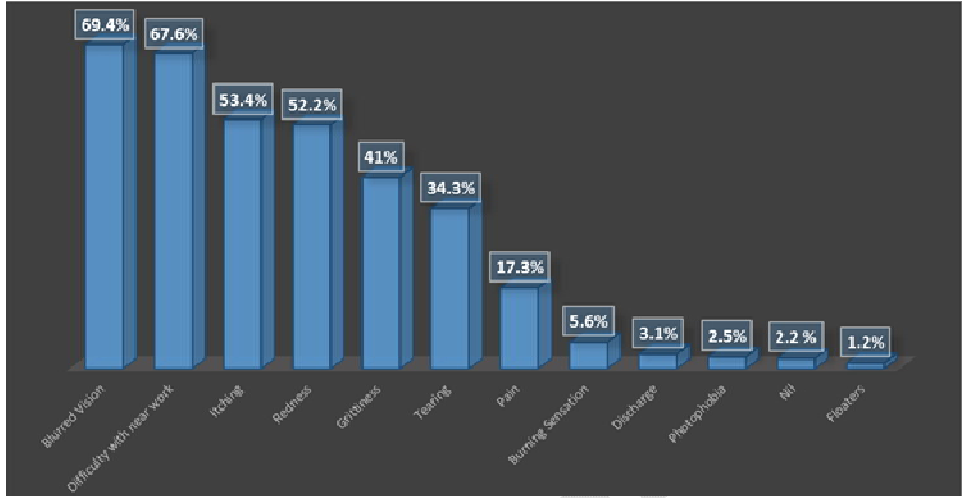


Figure 1: Current ocular compliant/ symptoms among participants

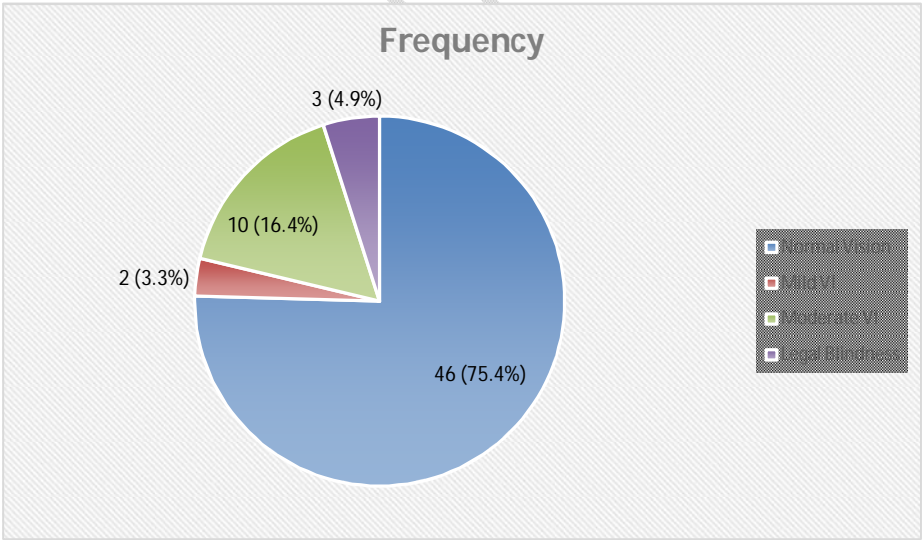


Figure 2: Visual status of 61 participants with ocular manifestations. (Key VI = Visual impairment)

Blurred vision, difficulty with near work and itching were the most common presenting complaints (fig. 1) Also, participants noted to be blind had presenting visual acuity  $\leq 3/60$  i.e. 1.30 LogMAR. None had severe visual impairment (presenting visual acuity  $\leq 6/60 \geq 3/60$  i.e. 1.01 – 1.30 LogMAR). The prevalence of visual impairment (VI) and blindness of 19.7% and 4.9% respectively was observed. (fig. 2) Of the 3 (4.9%) noted to be blind, 2 had optic atrophy while the other had CMVR.

**Table 2: Frequency of ocular manifestations of HIV among the participants**

<b>HIV Related Ocular Manifestations</b>	<b>Frequency</b>	<b>Percentage</b>
<b>Adnexal Manifestations</b>		
Conjunctival microvasculopathy	10	14.5
Active Herpes zoster ophthalmicus	4	5.8
Squamous cell carcinoma	3	4.4
Molluscum contagiosum	1	1.5
<b>Anterior Segment Manifestations</b>		
Keratoconjunctivitis sicca	10	14.5
Anterior Uveitis	6	8.7

Keratitis 2 2.9

**Posterior Segment Manifestations**

HIV microangiopathy 13 18.8

Immune recovery uveitis 6 8.7

Toxoplasma retinitis 4 5.8

Cytomegalovirus retinitis 3 4.4

**Neuro-ophthalmic Manifestations**

Optic atrophy 3 4.4

Gaze palsy 2 2.9

Pupillary abnormality 2 2.9

**Table 3: Showing classes of ocular manifestations of HIV among participants**

<b>Types of HIV Related Ocular Manifestations</b>	<b>Frequency</b>	<b>Percentage (%)</b>
ADNEXEAL	18	26.1
ANT. SEGMENT	18	26.1
POST SEGMENT	26	37.7
NEUROPHthalmic	7	10.1
ORBITAL	0	0.0

The most common diagnosis among the participants were HIV microangiopathy (18.8%), conjunctivalmicrovasculopathy and keratoconjunctivitis sicca (14.5%). The most common class of ocular manifestation was posterior segment ocular manifestation (37.7%) while the least was neuro ophthalmic (10.1%). Most of the participants (97.9%) had an ocular symptom at time of interview and a few (32.6%) had previous history of ocular symptoms prior to HIV diagnosis. All those without any current ocular symptoms also had no HIV related ocular manifestation. However, there was no statistically significant association between reported symptoms and HIV related ocular manifestations ( $p > 0.05$ ).

## DISCUSSION

The prevalence of ocular manifestation in this study was low compared with the report of other studies.<sup>19-22</sup> This low prevalence of ocular manifestations may be due to the fact that all the participants recruited were on HAART and most (63.1%) had been on HAART for more than 5 years. Also, most of the study participants (85.5%) were at HIV clinical stages I and II. Higher prevalence reported by some researchers<sup>19-22</sup> was attributed to most of the patients being at WHO clinical stages III and IV<sup>20,21</sup> as well as having low CD4+ cell count of less than 200 cells/ $\mu$ l.<sup>22</sup> Other researchers have on the other hand noted lower prevalence of ocular manifestation, which was attributed to good medication coverage.<sup>2,23</sup> A study in Brazil reported that no ocular manifestation of HIV was noted among the study participants and this was attributed to small sample size (42 participants) and the fact that all but one of those studied were on HAART.<sup>24</sup>

The prevalence of blindness and visual impairment in this study was low compared to an earlier report [DoO31] by Adeniyi in Makurdi where legal blindness and VI were 15% and 45% respectively in the study population.<sup>5</sup> An adducible reason to this was the fact the majority were yet to commence HAART unlike this where all respondents were on therapy with about 2/3<sup>rd</sup> of the study population on HAART for about 5 years. Blurred vision and difficulty reading were the most prevalent presenting symptoms. This is not surprising, considering the mean age of the study population who are within the presbyopic range and the fact that about 1/5<sup>th</sup> of the participants had some degree of visual impairment. Also, blurring of vision was the most common symptom as shown by Adeniyi<sup>5</sup>, however over 30% of the population in the study were less than 30 years.

Listo et al<sup>25</sup> in their study reported that about 26% and 26.5% of the HIV related ocular manifestations, were found in the adnexa and anterior segment respectively. This may be attributed to more than half of their study participants being on HAART and at earlier stages of the disease (stages I and II). However, Bekelet et al<sup>26</sup> in another report showed that adnexal manifestations constituted only 12.8% while 12.3% were in the anterior segment. This difference may be because a majority of their study participants were not on HAART compared to ours who were all on therapy. Anterior segment ocular manifestations are said to occur at a higher CD4+

cell level compared with posterior segment manifestations.<sup>10,27</sup> Conjunctival microvasculopathy was observed as the commonest adnexal presentation in this study. This agrees [DoO37] with existing literature where it was reported in about 80% of presentations.<sup>28</sup> However, studies in Nigeria have shown herpes zoster ophthalmicus to be a common presentation among HIV positive patients sometimes preceding the diagnosis of HIV/AIDS.<sup>29,30</sup> Also in keeping suggestions by Feroze and Wang above.<sup>28</sup>

Posterior segment manifestations were the most common class of ocular manifestation [DoO40] reported in this study and this is consistent with earlier reports Makurdi and Nepal.<sup>5,31</sup> Posterior segment manifestations are said to occur more in patients with CD4+ cell level lower than 200 cells/ $\mu$ l.<sup>10,27</sup> In this study however, all the participants were on HAART and most had CD4 count > 200 cells/ $\mu$ l. Similar to the proposal by other researchers,<sup>26,32</sup> HAART is commenced at lower levels of CD4+ count and the patients possibly could have developed the ocular manifestations before the commencement of HAART; also the newly reconstituted CD4+ cells may not be associated with the functional maturity to offer the required protection to the patients. These observations may explain the higher prevalence of posterior segment manifestations with seemingly high CD4+ cell levels in this study. HIV microangiopathy has been noted to occur more at later stages of HIV infection.<sup>6</sup> This may account for the lower prevalence of HIV microangiopathy reported in this study compared to the study by Azonobi et al<sup>33</sup> since most of the patients in their study were at later stage of HIV infection compared to the participants in this study.

With the advent of HAART, a new entity, immune reconstitution inflammatory syndrome, part of which is immune recovery uveitis, has been introduced into the spectrum of ocular features associated with HIV/AIDS. Sudharshan et al<sup>22</sup> observed that 17.4% of those with HIV related ocular manifestations had immune recovery uveitis and 36.2% had cytomegalovirus retinitis; these are higher than the findings of this study. Gogriet et al<sup>10</sup> observed that only 5% of those with HIV related ocular manifestations had immune recovery uveitis and 12.5% had cytomegalovirus retinitis. The prevalence of cytomegalovirus retinitis observed in this study falls within the range (0.2% to 4.8%) reported by other researchers in Nigeria.<sup>33-35</sup> Immune recovery uveitis, though mainly associated with cytomegalovirus retinitis has been documented to occur in association with other opportunistic infections.<sup>22</sup>

Previous studies have reported neuro-ophthalmic features as a rare manifestation of HIV/AIDS.<sup>18,20,21,36</sup> The 10.2% obtained from those study though the least among the different groups of ocular manifestations, it is not a negligible proportion. The orbit has been documented to be rarely involved in HIV disease.<sup>31</sup> Studies by other researchers also show that no orbital manifestation was observed just like was observed in this study.<sup>11,37</sup>

Omolaseet et al<sup>38</sup> in Nigeria also noted that 12.5% of their participants had a history of eye problems.

## CONCLUSION

The frequency of HROM in this population was comparatively low with a 1:2 M: F ratio. There was also no statistical association with any socio-demographic variable. The clinical profile (stage of disease, CD4<sup>+</sup> count) and use of HAART were important factors noted in this study. As part of comprehensive care, it is necessary to ensure that PLWHA get ophthalmic examinations irrespective of their demographic and HAART status. To achieve this, it is important to integrate eye care services into the existing retroviral disease care.

## REFERENCES

1. Loo, A V P; Sujaya, S; Peyman, M; Florence, S; Subrayan V. Retinal manifestations of patients with human immunodeficiency virus, a multiethnic study in Malaysia. *Int J Ophthalmol.* 2011;4(6):641–3.
2. Rutayisire DL, Saiba SE. Ocular manifestations related to HIV / AIDS at Kigali University Teaching Hospital. *Rwanda Med Journal.* 2010;68(4):47–51.
3. Purushottam J, Thakur A, Choudhary M, Sharma S, Shah DN. Ocular Manifestations in HIV Positive and AIDS Patients in Nepal. *Int J Clin Med.* 2012;3:14–21.
4. Alam, M; Akbar, S; Khan, A; Iqbal M. Ocular manifestations in HIV positive patients attending Khyber Teaching Hospital Peshawar. *SAARC J TUBER LUNG DIS HIV/AIDS;* 2011;VIII(2):31–6.
5. Adeniyi OS. Ocular manifestations of HIV infection/AIDS in Makurdi– Nigeria. *African J Med Sci.* 2011;4(1):1–10.
6. Jabs DA. Ocular manifestations of HIV infection. *N Engl J Med.* 1998;339(4):236–44.
7. Kehinde, A V; Samaila, E; Eni RN. Ocular aids: experience at the Guinness Ophthalmic unit, Kaduna, Nigeria. *Niger J Surg Res.* 2005;7(3 – 4):305–8.
8. Holland GN, Pepose JS, Pettit TH, Gottlieb MS, Yee RD FR. Acquired immune deficiency syndrome. *Ophthalmology.* 1983;90(8):859–73.
9. Sahu, D K Namperumalsamy, P Walimbe, P Rajalakshmi C. Ocular manifestations of HIV infection/AIDS in South Indian patients. *Indian J Ophthalmol.* 1999;47(2):79–85.
10. Gogri PY, Misra SL, Kothari RN, Bhandari AJ, Gidwani H V. Ophthalmic Manifestations of HIV Patients in a Rural Area of Western Maharashtra, India. *IntSch Res Not.* 2014;2014:1–9.
11. Acharya, P K; Venugopal KC, Karimsab DPBS. Ocular Manifestations in Patients with HIV Infection/AIDS who were Referred from the ART Centre, Hassan, Karnataka, India. *J Clin Diagnostic Res.* 2012;6(10):1756–60.

12. Bhatia RS. Ophthalmic Manifestations of AIDS. *JACM*. 2002;3(1):85–8.
13. Govender P, Hansraj R, Visser L. Ocular manifestations of HIV / AIDS: A literature review ( Part 1 ). *S AfrOptom*. 2010;69(4):193–9.
14. Lewallen S. HIV/AIDS: What is the Impact on Prevention of Blindness Programmes? *Community Eye Heal J*. 2003;16(47):33–4.
15. Emina MO, Odjimogho SE. Ocular problems in HIV and AIDS patients in Nigeria. *Optom Vis Sci*. 2010;87(12):979–84.
16. Lewallen S, Kumwenda J, Maher D, Harries AD. Retinal findings in Malawian patients with AIDS. *Br J Ophthalmol*. 1994;78(10):757–9.
17. Heiden, David; Holland, Gary N; Jabs, Douglas A; Thorne JE. HIV and the eye. *Eyenet*. 2014;37–41.
18. Amare B, Admassu F, Assefa Y, Moges B, Ali J, Kassu A. Pattern of Ocular Manifestation of HIV/ AIDS among Patients on HAART in ART Clinic of Gondar University Hospital, Northwest Ethiopia. *J ClinExpOphthalmol*. 2011;02(11):1–5.
19. Arruda, R F; Muccioli CBJR. Ophthalmological findings in HIV-infected in the post-HAART era and comparison with the number of patients evaluated in the pre-HAART period. *J Brazilian Med Assoc*. 2004;50(2):1–10.
20. Assefa Y, Yohannes AG, Melese A. Ocular Manifestations of HIV / AIDS patients in Gondar University Hospital , north west Ethiopia. *Ethiop J Health Dev*. 2006;20(3):166–9.
21. Sahoo S. HIV- and AIDS-related ocular manifestations in Tanzanian patients. *Malaysian J Med Sci*. 2010;17(1):12–6.
22. Sudharshan S, Kaleemunnisha S, Banu AA, Shrikrishna S, George AE, Babu BR, et al. Ocular lesions in 1 , 000 consecutive HIV-positive patients in India: a long-term study. *J Ophthalmic Inflamm Infect*. 2013;3(2):1–7.
23. Abdollahi A, Heidari-Bateni G, Zarei R, Kheirandish P, Malekmadani M, Mohraz M, et al. Clinical spectrum of 15 patients with HIV-related ocular involvement in Tehran. *Int J Ophthalmol*. 2010;3(4):331–6.
24. Vargas, M A; Lourdes Veronese Rao, M; Castro Figueiredo, J F; Souza N V. Ophthalmological conditions of patients with acquired immunodeficiency syndrome with long follow up time. *J Brazilian Med Assoc*. 2006;1–10.
25. Listo B, Kollmann K, Kimani K, C O. Ocular manifestations of HIV/AIDS at Moi Teaching and Referral Hospital (AMPATH Clinic). *East African J Ophthalmol*. 2009;27–34.

26. Bekele S, Gelaw Y, Tessema F. Ocular manifestation of HIV/AIDS and correlation with CD4+ cells count among adult HIV/AIDS patients in Jimma town, Ethiopia: a cross sectional study. *BMC Ophthalmol.* 2013;13(20):1–6.
27. Kim YS, Sun HJ, Kim TH, Kang KD, Lee SJ. Ocular Manifestations of Acquired Immunodeficiency Syndrome. *Korean J Ophthalmol.* 2015;29(4):241–8.
28. Feroze KB, Wang J. Ocular Manifestations of HIVIn: StatPearls [Internet]. Treasure Island (FL): StatPearls Publishing; 2021
29. Nwosu NN. HIV/AIDS in ophthalmic patients: The Guinness Eye Centre Onitsha experience. *Niger Postgr Med J.* 2008;15(1):24-7.
30. Umeh RE. Herpes zoster ophthalmicus and HIV infection in Nigeria. *Int J STD AIDS.* 1998;9(8):476–9.
31. Duane TD, Tasman W, Jaeger EA. *Duane's ophthalmology.* 2011.
32. Kim, S J; Park SJ, Yu, H G; Kim NJ, Jang, H C; Oh M. Ocular manifestations of acquired immunodeficiency syndrome in Korea. *J Korean Med Sci.* 2012;27(5):542–6.
33. Azonobi IR, Udoye E, Tebepah T, Opubiri IR. Ocular manifestation of HIV / AIDS infection among patients receiving highly active Antiretroviral therapy ( HAART ) in a tertiary eye care centre. *J AIDS HIV Res.* 2013;5(9):322–7.
34. Adepoju, F G;Olawumi, H O; Adekoya BJ. HIV SeropositivityAnd Related Eye Diseases In UITH Ilorin. *Niger Postgrad Med J.* 2007;14(2):163–5.
35. Osahon, A.I Onunu AN. Ocular disorders in patients infected with the human immunodeficiency virus at the University of Benin Teaching Hospital, Benin City, Nigeria. *Niger J ClinPract.* 2007;10(4):283–6.
36. Sharew G, Azage M. Predictors of HIV / AIDS Related Ocular Manifestations among HIV / AIDS Patients in FelegeHiwot Referral Hospital, Northwest Ethiopia. *J Ophthalmol.* 2015;2015:1–8.
37. Cochereau I, Mlika-cabanne N, Godinaud P, Niyongabo T, Poste B, Ngayiragije A. AIDS related eye disease in Burundi , Africa. *Br J Ophthalmol.* 1999;83:339–42.
38. Omolase C, Komolafe O, Ayodeji O, Omolase B, Akinwalere AK, Majekodunmi MY. Ocular manifestations in HIV-AIDS patients in a Nigerian community. *South African FamPract.* 2012;54(5):455–8.