

Evaluation Of Preputial and Buccal Mucosal Grafts in Two-Stage Repair of Severe Proximal Hypospadias.

Abstract (Arial, Bold, 11 Font, Left Aligned, Caps)

Aims: to evaluate the results of staged surgical repair of proximal forms of hypospadias according to Bracka's method using preputial or buccal grafts in the department of urology, Tanta university hospital between January 2019, and January 2022.

Study design: prospective comparative randomized study

Place and duration of study: urology department, Tanta university hospital, between January 2019 and January 2022.

Methodology: fifty male patients with severe proximal hypospadias associated with moderate to severe chordee and or poor urethral plate underwent two-stage repair with buccal mucosal or preputial graft in the department of urology, Tanta university hospital between January 2019, and January 2022 cosmetic and functional outcomes were assessed.

Results: native meatus was at proximal penile in 1, penoscrotal in 13, scrotal in 19, and perineal in 17 cases. 25 patients underwent staged hypospadias repair using preputial graft in the 1st stage and 25 patients underwent staged hypospadias repair using buccal mucosal graft. The mean age of the patients at the 1st stage was 9.5 and 8.7 months in the preputial and buccal mucosal groups respectively. The graft take was successful except only in 5 patients needed graft redo after the 1st stage. Success rate was 54.5% with preputial group and was 62% in buccal mucosal group.

Conclusions: two-stage repair with Bracka's technique is safe and feasible for repair of primary cases of severe proximal hypospadias. Both preputial and buccal mucosal grafts are reliable and suitable urethral substitutes in staged hypospadias repair with comparable results and complications rate.

Keywords: *hypospadias · proximal · severe chordee · graft ·*

1. Introduction.

Hypospadias is a congenital anomaly of the anterior urethra of males where the urethral opening presents in the under surface of the penis.⁽¹⁾Hypospadias may be associated with abnormal ventral curvature of the penile shaft which is called chordee that leads to functional and cosmetic impairment.⁽²⁾

Hypospadias is usually classified according to the location of the urethral meatus: distal hypospadias, middle (penile) hypospadias and proximal hypospadias.⁽³⁾

Indication for hypospadias surgery includes the need for the correction of penile deviation, ectopic urethral meatus, and penoscrotal transposition. The ideal result of surgery is construction of a good calibre urethra with a slit-like urethral meatus at the tip of the glans and a straight penis.⁽⁴⁾

The surgical techniques used to repair hypospadias are almost as diverse with hundreds of described methods. Given the large number of patient and operative factors that may influence outcomes. This is especially true for proximal hypospadias where, regardless of whether a single or multistage surgery is used, complication rates range from 8% to 70%.⁽⁵⁾

Over the years, so many techniques have evolved and these range from a one stage technique, where correction of chordee and creation of neo-urethra is done simultaneously to a two-stage operation, where creation of the new urethra is performed as a second stage procedure after an earlier operation for chordee correction.⁽⁶⁾

Single stage technique has a limitation in dealing with the full spectrum of hypospadias. By contrast, the two-stage method deals with everything from coronal hypospadias, through to the most severe proximal cases, even if circumcised or having already been the victim of multiple failed repairs.⁽⁷⁾

Originally, Bracka's method described usage of preputial skin graft, and only in cases of its absence buccal mucosa. The application of preputial skin graft is less traumatic in comparison with buccal mucosa, which requires a second site surgery during the first stage.⁽⁸⁾

Our objective in this study was to analyse the results of staged surgical repair of proximal forms of hypospadias according to Bracka's method to compare the outcomes and complications of treatment using preputial versus buccal grafts.

Our hypothesis was that buccal mucosa is the optimal tissue for use in the Bracka's method urethroplasty. As its availability give us the chance for correction of severe forms of hypospadias with long urethral defect without difficulties in penile skin and glans closure.

2. Material and methods / experimental details / methodology

2.1 study design:

This is a prospective comparative randomized study performed on patients with severe proximal hypospadias who underwent staged repair in the period between January 2019, and January 2022.

2.2 study population:

50 patients with severe hypospadias were randomized by simple randomization using computer-generated random numbers which randomly assign the patients in the two groups.

Group P: 25 patients underwent staged hypospadias repair using preputial graft in the 1st stage.

Group B: 25 patients underwent staged hypospadias repair using buccal mucosal graft in the 1st stage.

2.3 statistics:

Data were fed to the computer and analysed using IBM SPSS software package version 20.0. Qualitative data were described using number and percent. The Kolmogorov-Smirnov test was used to verify the normality of distribution. Quantitative data were described using range (minimum and maximum), mean, standard deviation and median. Significance of the obtained results was judged at the 5% level.

2.4 surgical technique:

A. First-stage repair

Optical loupes were used (2.5 X) for magnification. Initial skin incision was done extending in a u-shaped fashion around the hypospadias meatus and 5mm from the corona. Degloving of the penile skin was done dorsally down to the

penopubic angle, then we shift ventrally to the plane between the corpus spongiosum around the plate and the skin dartos to completely deglove the penis. (Figure 1).

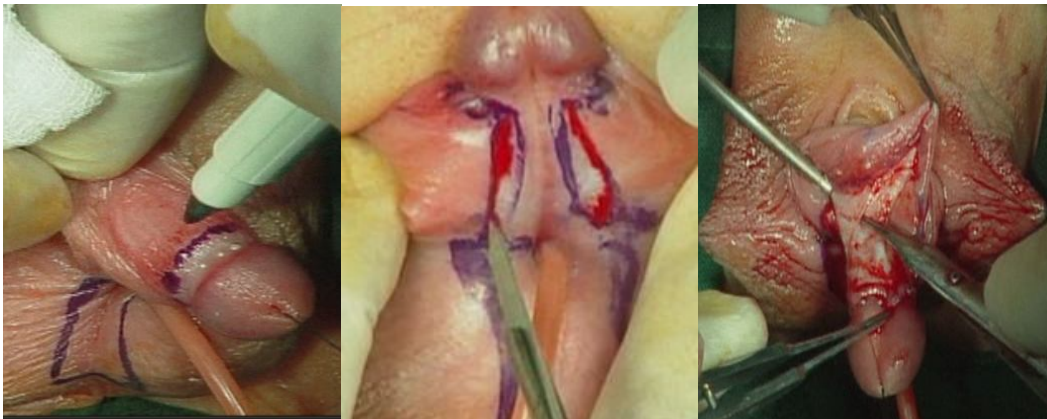


Figure (1): Marking, incision of the skin and degloving of the penis.

B. Penile curvature management

Initial artificial erection by test to assess the degree of associated penile curvature after complete degloving by inserting a 23-gauge butterfly needle into the corpus cavernosum with a tourniquet and injecting saline solution. The degree was then

evaluated using a metal protractor or a mobile application after taking photo for the erected penis called **Angulus**. If the curvature was more than 30 degrees, the urethral plate was excised at the coronal level and fibrous bands of the buck's fascia and aberrant corpus spongiosum that contribute to chordee were dissected off the corpora cavernosa. If the penis was straight, grafting was then fixed. But if it was still ventral bent, a single or multiple superficial transverse ventral corporotomies were done coupled with a dorsal plication (DP) 4/0 PDS stitch when needed. (Figure 2).

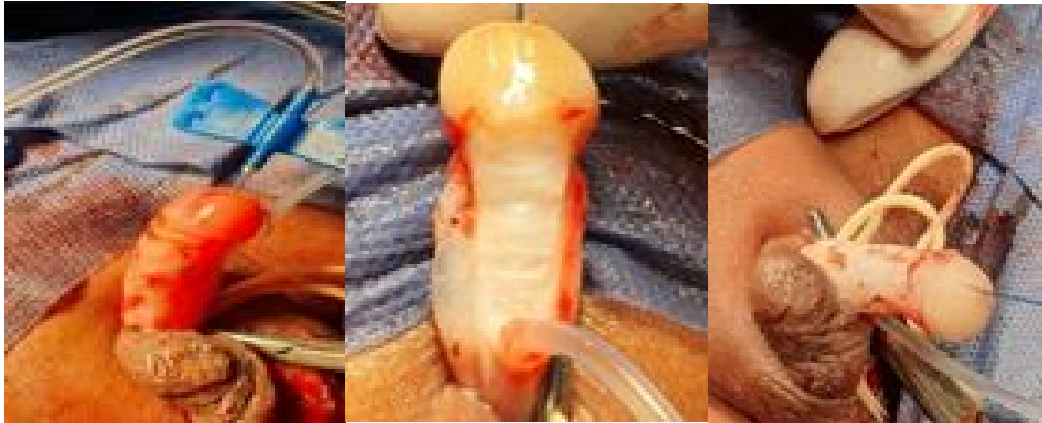


Figure (2): Urethral plate transection, ventral corporotomies and dorsal plication of tunica albuginea.

C. Correction of concomitant scrotal anomalies

Penoscrotal transposition of the scrotum was corrected by two incisions at the junction between the scrotum and the penile skin base to get the scrotum into position and reapproximating of scrotal flaps inferior to the penis. (Figure 3) bifid scrotum was also corrected by excision of the midline shiny skin between both hemi-scrotums and the midline anastomosis between the two hemi-scrotums in the midline.

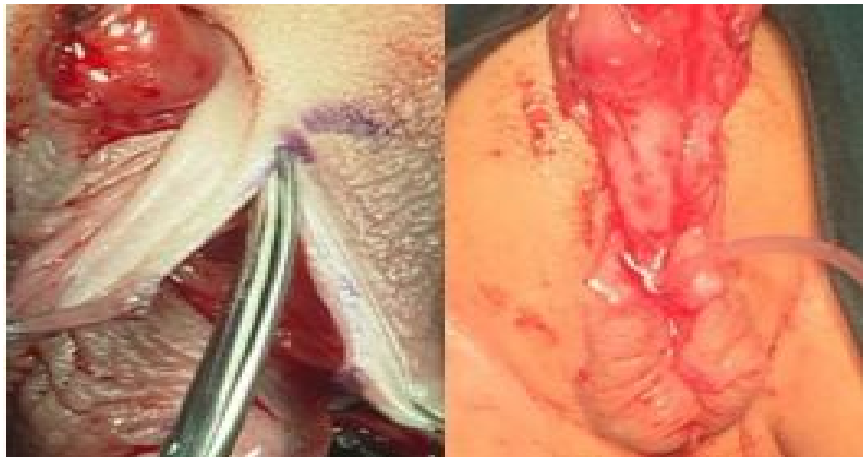

Figure (3): Scrotoplasty for penoscrotal transposition.

D. Glans preparation

The glans is incised longitudinally in the midline to create large glanular wings with the spongiosum widely opened to accommodate the graft.

E. Preputial graft harvesting.

Two traction sutures were placed at the corners of the preputial hood to facilitate harvesting of the graft. Incision was made after marking the inner aspect of the prepuce as the required size to cover the formed defect on the ventral surface of penis. then dissected by fine scissors while holding the stay sutures.

F. Buccal mucosal graft harvesting.

The external and inner mucosal surfaces of the lower lip or the inner cheek were painted and draped, then two traction sutures were placed at the lower lip margins. A 10 ml of 1:100,000 epinephrine solution was infiltrated along the edge of the lower lip graft to facilitate haemostasis and dissection. The graft was dissected in the plane between the mucosa and the muscle. The donor site was accurately examined, and bleeding was controlled with bipolar electrocautery, then it was left open for reepithelization to decrease the risk of oral tightness.

G. Graft application

The graft (preputial or buccal) was accurately secured to the ventral aspect of the corpora using a 6/0 Vicryl suture. The edges were sewn first, and then multiple quilting stitches were placed through the graft in multiple parallel rows to reduce the potential risk of hematoma and graft loss (Figures 4,5). A firm 'tie-over' dressing was applied holding the graft in place and preventing any hematoma from collecting underneath.

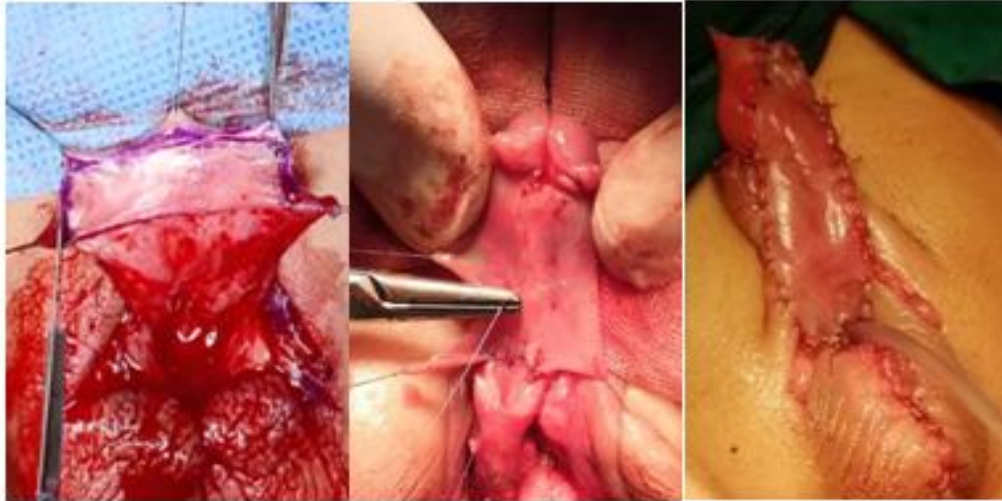

Figure (4): Preputial graft harvesting and fixation.

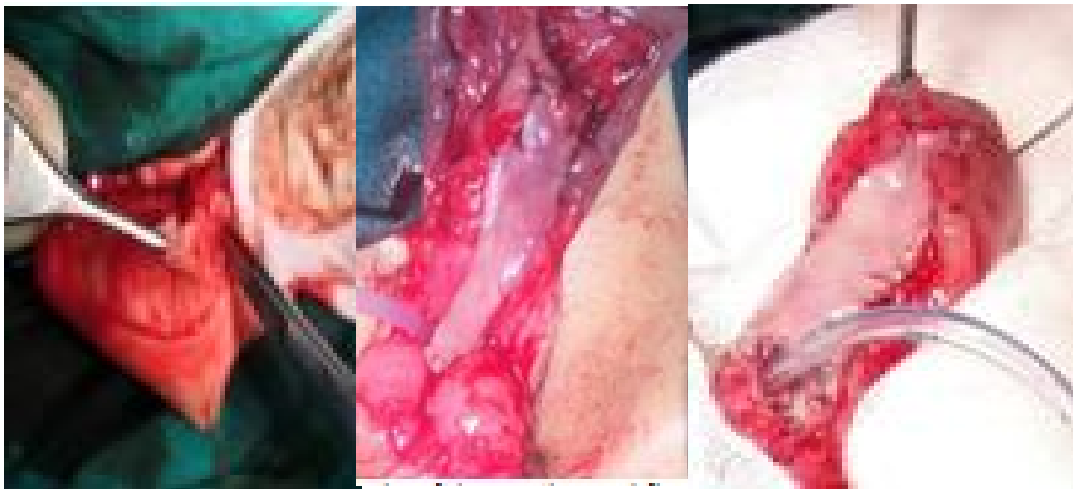

Figure (5): Buccal mucosal graft harvesting and fixation.

H. Postoperative care of the 1st stage.

The urethral catheter and the 'tie-over' dressing were removed together on the 7th day postoperative, and the graft was checked for take or necrosis. Betamethasone 0.1% ointment was administered twice daily for 3 months to improve the quality of the healing and reduce fibrosis. The good graft take should be smooth and the glans cleft sharply delineated, allowing for accurate planning of the new meatus and urethra. For buccal group, Cold fomentation was applied to the lower lip for 24 h to reduce pain and the risk of hematoma

formation. The oral cavity was checked regularly for the presence of oedema, bleeding, infection, numbness, or tightness.

I. Second-stage repair

A u-shaped incision was designed around the catheter to ensure sufficient width in the constructed urethra and meatus. The u-shaped graft was then dissected along buck's fascia down to a level proximal to the urethral meatus, ensuring as much preservation of lateral vascularity. The isolated graft strip was tubularized comfortably around 6 french nelaton catheter with two layers using a 7/0 vicryl suture. (Figures 6,7)

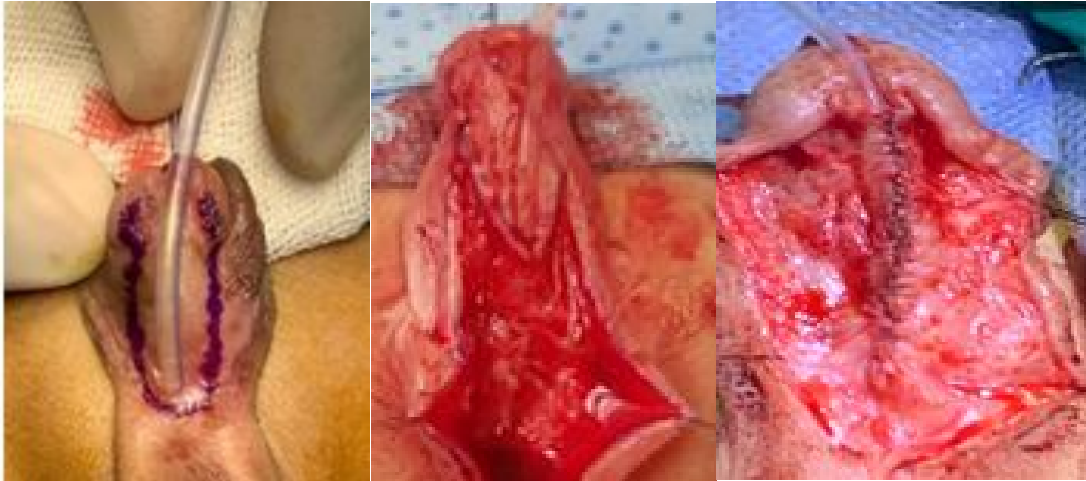

Figure (6): Preputial graft tubularization in two layers of sutures.

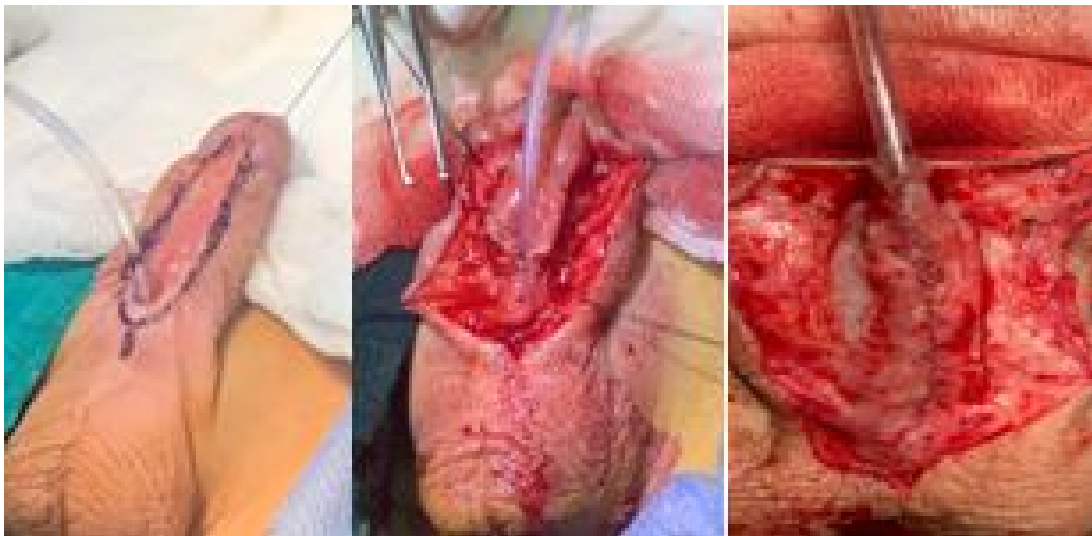

Figure (7): Buccal graft tubularization in two layers of sutures.

A second layer of tunica vaginalis flap is then secured over the neourethra. The glans was repaired with 6/0 vicryl vertical mattress sutures and the skin was repaired with 6/0 vicryl. A Coban dressing was applied and left for 5 days, and a draining catheter was used for 7–10 days in double diaper technique. (Figure 8)

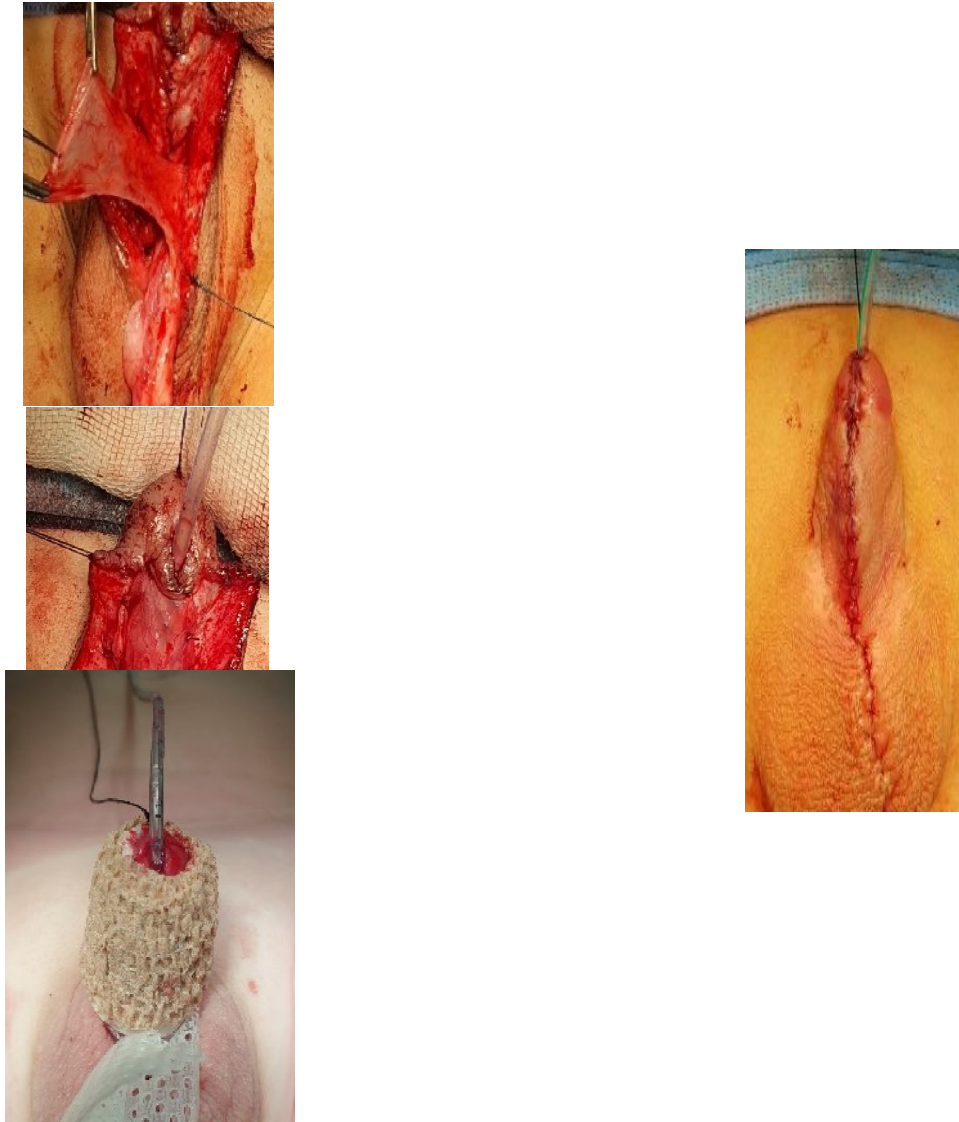


Figure (8): Tunica vaginalis flap wrapping and skin closure

Follow up visits were scheduled weekly for the 1st month, monthly for 3 months, 3 months, and 6 months postoperatively for success or presence of early or late complications. The success of the primary outcome was determined by achieving normal like meatus at the tip of the glans without meatal stenosis, fistula or diverticulum with straight penis and minimal skin scarring. Secondary outcome was functional evaluation of the voiding pattern and urine stream and ultrasound measured residual urine (PVR), for all patients at last clinic visit at least 6 months after second stage. The paediatric penile perception score (PPPS) as a tool for assessment after hypospadias repair. (Figure 9.10)

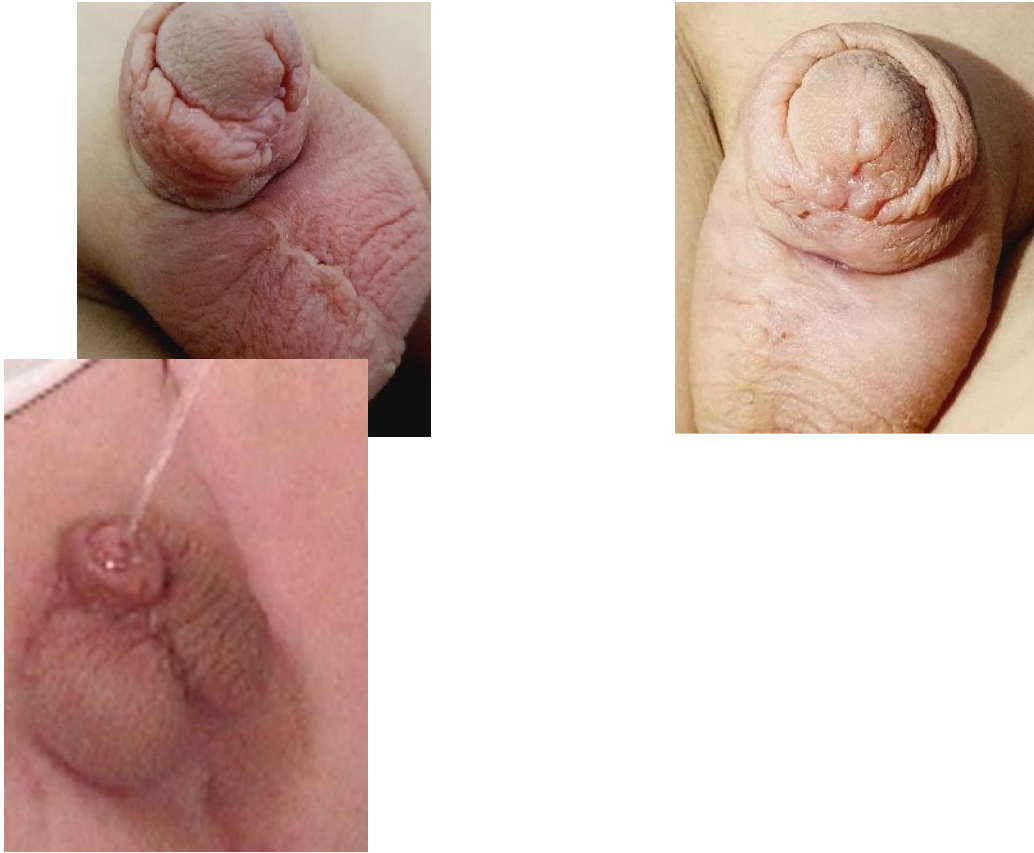

Figure (9): Follow up of some cases with preputial graft six months postoperative.

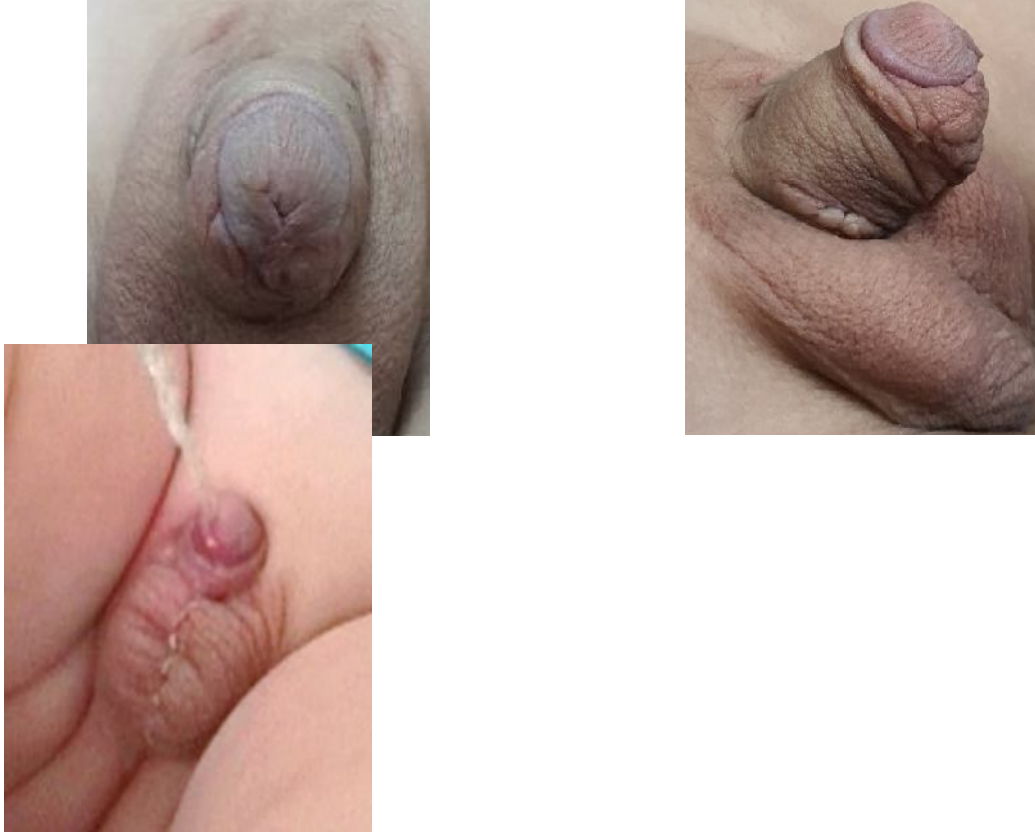

Figure (10): Follow up of some cases with buccal graft six months postoperative.

2. Results

The sample size was calculated to detect a mean difference 40% in percent of urethral fistula occurrence between the study groups. A total number of 44 patients at least were needed to have a study power of 80%, an alpha error of 0.05 and proportion of the experimental to the control group 1:1.

From January 2019, and January 2022, we operated on 50 children with primary proximal hypospadias, 25 (group P) patients were treated by two stage repair with preputial graft in the 1st stage and 25 (group B) patients were treated by two stage repair with buccal mucosal graft in the 1st stage.

The age of patients in group P ranged from 6.5 to 15 months with mean age 9.5 ± 2.21 months. In group B the age of patients ranged from 6 to 13 months with mean age 8.7 ± 2.71 months. The external urethral meatus was perineal in 7, scrotal in 11 and penoscrotal in 7 patients in group P while it was perineal in 10, scrotal in 8, penoscrotal in 6 and proximal penile in 1 patient in group B.

Congenital penile curvature was severe (>30 degree) in all patients after complete degloving and extended bulbar dissection. This curvature was corrected completely after urethral plate transection in only 3 patients in group P and in 2 patients in group B.

Single transverse ventral corporotomy opposing the area of maximum bent was needed in 8 cases in group P and in 7 patients in group B after complete penile degloving and transection of the urethral plate.

Multiple transverse ventral corporotomies was done to correct the ventral curvature of 10 patients in group P and in 11 patients in group B. Combination of multiple ventral corporotomies and dorsal midline plication was used to correct the ventral curvature (VC) in 4 patients in group P and in 5 patients in group B.

Graft necrosis occurred in one patient in group P and in two patients in group B. Mild fibrosis with no need for graft redo was found in 4 patients in group P and in 6 patients in group B. Severe graft fibrosis occurred equally in only one patient in each group. Overall, the graft was taken successfully in 92% of patients and 88% of patients in group P and group B respectively. Only 5 cases needed graft redo and revision of the 1st stage (2 in group P and 3 in group B).

All patients (100%) in group B suffered from oral manifestations related to the buccal mucosal graft site in the form of lower lip oedema, oral pain. All these manifestations were mild and were treated medically by analgesics and anti-oedematous drugs and improved gradually with follow up. Mouth tightness or numbness or permanent scar didn't happen in any patient.

Second-stage repair was completed in 43 patients after exclusion of the 5 patients that needed regrafting after failure of the 1st stage and 2 patients that missed the follow-up and did not come to our hospital for the 2nd stage, 22 patients in group P and 21 patients in group B.

The overall complications rates were comparable in both groups, with total number of complications 10(45.5%) in group P and 8(38%) in group B with initial success rate (54.5 %) in the preputial group and (62%) in the buccal group. Simple surgical intervention in the form of meatotomy, simple fistulectomy or visual internal urethrotomy was done in the remaining 6 complications raising the success rate to (69.2%) in group P and (76.2%) in group B. (Table 1,2,3)

Table (1): Comparison between the two studied groups according to early post-operative complications of the 2nd stage.

| Complications | Type of the used graft | | Test of significance | p |
|---------------|------------------------|---------------|----------------------|-------|
| | Preputial (n=22) | Buccal (n=21) | | |
| Penile oedema | 13(59%) | 14(66.6%) | χ^2 0.237 | 0.626 |

| | | | | |
|---------------------------|----------|----------|--------------------|-------|
| Wound infection | 4(18.2%) | 5(23.8%) | FE 0.407 | 0.608 |
| Wound dehiscence | | | | |
| Glans dehiscence | 2(9%) | 1(4.8%) | FE 0.311 | 1.000 |
| Partial wound dehiscence | 1(4.5%) | 1(4.8%) | | |
| Complete wound dehiscence | 1(4.5%) | 0(0.0%) | | |

χ^2 : Chi-square test

FE: Fischer Exact test

Complications were encountered in the form of fistula that occurred in totally 9 cases, 4 patients in group P and 5 cases in group B, glans dehiscence was found in two patients in group P and in one patient in group B. Partial wound dehiscence was noticed in one patient in group P and another case in group B while complete wound dehiscence occurred in only one patient in in group P with no cases found in group B. Meatal stenosis was occurred in 3 patients in group P and in 2 patients in group B.

Urethral stricture was also reported in 5 patients, 2 in group P and 3 in group B. Two cases of stricture urethra managed successfully by endoscopic dilatation (VIU) and the other 3 cases was obliterated urethral stricture and redo urethroplasty was planned for the treatment of these patients. Diverticulation of the urethra was found only in one patient in group P and was treated by diverticulectomy. No cases of urethral diverticulum occurred in group B.

Table (2): Comparison between the two studied groups according to the late post-operative complications of the 2nd stage.

| Late Complications | Type of the used graft | Test of | p |
|--------------------|------------------------|---------|---|
|--------------------|------------------------|---------|---|

| | Preputial (n=22) | Buccal (n=21) | significance | |
|------------------------------|-----------------------------|--------------------------|---------------------|-------|
| Urethral fistula | 4(18.2%) | 5(23.8%) | FE 1.423 | 0.284 |
| Meatal stenosis | 3(13.7%) | 2(9.5%) | FE 0.178 | 1.000 |
| Urethral stricture | 2(9%) | 3(14.3%) | FE 0.407 | 0.608 |
| Urethral diverticulum | 1(4.5%) | 0(0.0%) | FE 0.978 | 1.000 |

FE: Fischer Exact test

Table (3): Comparison between the two studied groups according to the success and complications rate of the 2nd stage.

| | Type of the used graft | | Test of significance | p |
|---|-------------------------------|--------------------------|---------------------------------|----------|
| | Preputial (n=22) | Buccal (n=21) | | |
| All late complications | 10 (45.5%) | 8 (38%) | χ^2 0.044 | 0.206 |
| Major complications | 7 (31.8%) | 5 (23.8%) | | |
| Simple complications | 3 (13.6%) | 3 (14.3%) | | |
| Over all 12 cases (27.9%) had major late complications | | | | |

χ^2 : Chi-square test

Functional assessment of patients was done by measurement the amount of post voiding residual (PVR) of urine by ultrasound at the outpatient clinic 6 months after the 2nd stage. The mean amount of PVR ranged from 0 to 33 ml with mean 9.5 ± 7.3 ml in group P and ranged from 0 to 22 ml with mean 8.5 ± 6.1 ml in group B. The mean (SD) over all PPPS was 6.9 ± 1.73 in preputial group and 7.1 ± 2.21 in buccal group. (Table 4)

Table (4): Comparison between the two studied groups according to paediatric penile perception score (PPPS).

| Score | Type of the used graft | | Test of significance | p |
|---|------------------------|---------------|----------------------|-------|
| | Preputial (n=23) | Buccal (n=22) | | |
| Meatus shape Mean ± SD. | 1.6 ± 0.66 | 1.7 ± 0.70 | U 218.000 | 0.330 |
| Range | 0 - 2 | 0 - 3 | | |
| Glans shape Mean ± SD. | 1.7 ± 0.56 | 1.9 ± 0.64 | U 217.000 | 0.291 |
| Range | 0 - 2 | 0 - 3 | | |
| Penile skin shape Mean ± SD. | 1.8 ± 0.49 | 1.6 ± 0.73 | U 213.500 | 0.296 |
| Range | 1 - 3 | 0 - 3 | | |
| General appearance Mean ± SD. | 1.8 ± 0.65 | 1.9 ± 0.81 | U 237.500 | 0.689 |
| Range | 0 - 3 | 0 - 3 | | |
| Total score Mean ± SD. | 6.9 ± 1.73 | 7.1 ± 2.21 | U 230.000 | 0.587 |
| Range | 1 - 9 | 2 - 11 | | |

U: Mann Whitney U test

Table (5): Comparison between the two studied groups according to the amount of postvoiding residual of urine (PVR).

| Postvoiding residual of | Type of the used graft | | Test of significance | p |
|-------------------------|------------------------|--------|----------------------|---|
| | Preputial | Buccal | | |
| | | | | |

| urine (ml). | (n=22) | (n=21) | | |
|-------------|-----------|-----------|---------------------|-------|
| Mean ± SD. | 9.5 ± 7.3 | 8.5 ± 6.1 | U 243.000 | 0.506 |
| Range | 0 - 33 | 0 - 22 | | |

Mann Whitney U test

3. Discussion

From 2019 to 2022, we operated on 50 boys presenting with severe proximal hypospadias. The staged repair technique was applied in all cases and two surgeons operated on all children following the same surgical steps and assisted by the paediatric urology team in Tanta university hospital.

In our study the mean (SD) age of patients was 9.5 ± 2.21 months with preputial graft group and 8.7 ± 2.71 months with buccal mucosal graft group at the time of the first stage as advised for the ideal age for repair in the literature.

Erin r. Mcnamara and his colleagues in their retrospective study over 20 years on 134 patients underwent staged repair of sever hypospadias, reported median age of 8.8 months [IQR 6.3– 11.7] at the time of the 1st stage.⁽⁹⁾ The median age of cases at the 1st stage was 12 months with Badawy H et al, 2020.⁽¹⁰⁾

Our findings were similar to the reported data regarding the degree of penile curvature and correction techniques as Ventral curvature in the included patients was sever more than 30 degrees in all cases after complete degloving and extended bulbar dissection.

Degloving and urethral plate transection were sufficient to correct the curvature in 5(10%) of patients, 3 patients in preputial group and 2 boys in buccal mucosal graft group, VC was corrected by single ventral corporotomy with urethral plate transection in 15(30%), 8 cases in group P and in 7 patients in group B, multiple ventral corporotomies were needed with the plate transection in 21(42%), 10 cases in from group P and in 11 cases in group B and a combination of multiple ventral corporotomies and dorsal midline plication was used to correct the ventral curvature in 9(18%) of patients, 4 cases in group P and in 5 patients in group B.

Snodgrass et al⁽¹¹⁾ reported in his study on total 70 boys with proximal hypospadias that no VC after degloving in 13 (19%), VC was less than 30 degrees and corrected by dorsal plication in 22 cases (31%), and 35 (50%) had VC more than 30-degree were repaired by transection of the urethral plate.

Al-Adl et al⁽¹²⁾ found that after penile degloving and transecting the up, straightening was achieved in 25 out of 38 cases (65.8%), while in 13 cases, transverse ventral corporotomies were needed in 10 cases (26.3%) while in three cases (7.9%) additional DP was done.

The graft take was successful in 23(92%) of cases in preputial graft group and 22(88%) of cases with buccal mucosal graft. Collectively only five patients needed redo 1st stage (3

graft necrosis and 2 graft severe fibrosis). Our results were like the reported data of Badawy H et al ⁽¹⁰⁾, they found 39(90.7%) patients with graft take, and 4(9.3%) cases required revision of the first stage. Also graft take was successful in 90% of proximal hypospadias cases underwent primary repair using BMG in the first stage as described by Shandilya and his colleagues. ⁽¹³⁾

Alice Faure et al ⁽¹⁴⁾ in their report on forty-four boys who underwent two-stage repair for proximal primary hypospadias. Free grafts of inner preputial skin were used in 41 patients (93%), and buccal mucosa grafts were used in three (6.8%). The grafts took successfully after the first stage in 41 (93.8%) patients. Three graft contractures (6%) were noted: all were inner preputial graft, and all required a second grafting procedure before tubularization.

Jan Fichtner et al ⁽¹⁵⁾ described the use of buccal mucosa as only graft in a total of 132 patients who underwent staged hypospadias repair, successful graft take was present in nearly all cases with only 2 graft contractures were found in need for re-grafting.

Snodgrass and Elmore ⁽¹⁶⁾ reported graft contracture in 12% of hypospadias staged repair cases. Modified Bracka procedure was performed by Barroso Jr et al ⁽¹⁷⁾ in 9 children with previous failed hypospadias repair and one primary scrotal hypospadias. Significant contraction of the graft was not seen in any patient.

Regarding the oral complications in our study, we found only minor complications like lower lip oedema and oral pain in all patients (100%) with buccal mucosal graft group that resolved gradually 2 weeks postoperative. No mouth tightness or scar was reported in any patient. The buccal mucosal harvesting site was left open for gradual healing and epithelialization as described by Manasherova d et al. ⁽⁸⁾

Zhao et al ⁽¹⁸⁾ and Manasherova d et al ⁽⁸⁾ performed two-stage repair of hypospadias using a buccal mucosa graft with no reported complications related to the buccal mucosa harvest site. The donor site was closed primarily with interrupted sutures in all cases with Zhaom et al ⁽¹⁸⁾ and was left open for re-epithelialization with Manasherova d et al. ⁽⁸⁾

The second stage was completed in 43 patients, 21 boys were operated using BMG to substitute the urethral plate in the first stage and 22 patients were done using the preputial mucosal graft.

Associated complications in our study after the second stage urethroplasty was found in 45.5% in preputial group and 38% in buccal mucosal group. Our reported complications rate was high as we included all occurred minor and major complications but, some of our reported early complications were expected to improve and were managed conservatively or simple surgical intervention like meatotomy or fistulectomy and serial dilatation of the stenotic urethral meatus with no need for reoperations.

Our outcomes are similar to those in the existing literature with Snodgrass et al ⁽¹⁹⁾, Faure et al ⁽¹⁴⁾ and Badawy H et al ⁽¹⁰⁾ by 38%,38.4% and 43.2% respectively, which was considerably higher than that reported by Bracka ⁽⁷⁾, Manasherova d et al ⁽⁸⁾ and Zheng D et al ⁽²⁰⁾ by 23.5%,28% and 33% respectively.

In our study, urethra-cutaneous fistula was seen in 18.2% with preputial graft group and 23.8% in buccal graft group, which was comparable to the reported rate of fistula in grafted two stage technique. Zheng et al ⁽²⁰⁾, Manasherova D et al ⁽⁸⁾ and Badawy H et al ⁽¹⁰⁾ have reported 20.5%, 20% and 21.6% fistula rate in their respective studies with Bracka-staged repair using preputial graft.

Manasherova D et al ⁽⁸⁾, Faure A et al ⁽¹⁴⁾, and Zheng D et al ⁽²⁰⁾ have reported 14%, 18% , 9% and 13% fistula rate in their respective studies with two-stage repair of proximal hypospadias using buccal mucosal graft.

In our study, urethral stricture was seen in 9% in preputial graft group and 14.3% in buccal mucosal group. Our outcome with using the preputial graft was similar to that of A Bracka (7%) ⁽⁷⁾ and considerably lower than reported in the series examined by Leslie et al (16%) ⁽²¹⁾. In the buccal graft group ,the urethral stricture happened in similar rate to Leslie et al (16%) report but, higher than reported by A Bracka (7%) ⁽⁷⁾.

Urethral diverticulum which is ballooning of the neourethra is a documented drawback of the two-stage repair. It may occur as an independent complication or as a secondary consequence of meatal stenosis. It is more common with Byar's two-stage repair, the reported incidence of diverticula formation ranges from 0 to 14%. ⁽²²⁾

Leslie et al ⁽²¹⁾, Wani, S. A. et al ⁽²²⁾, Faure A et al ⁽¹⁴⁾, Badawy H et al ⁽¹⁰⁾ and Manasherova D et al ⁽⁸⁾ reported that no diverticulum was observed with their patients who underwent staged hypospadias repair using preputial or buccal mucosal grafts except only one case (2.2%) was reported by Faure A et al ⁽¹⁴⁾ in his series of two stage hypospadias repair with buccal mucosal graft.

Our findings were comparable to the published data, as urethral diverticulum on top of meatal stenosis occurred during follow up in our study only in one patient (4.5%) with preputial graft group, and no cases were found with buccal mucosal group.

4. Conclusions

Two-stage repair with Bracka's technique using preputial or buccal mucosal graft is safe and feasible for repair of primary cases of sever proximal hypospadias with good surgical outcomes.

Since no significant difference between buccal and preputial grafts, we recommend use of preputial graft in the first stage when available in primary cases of two stage repair.

Our limitations in this study are the low number of patients in each group and short term follow up, so we are planning to extend our study to include large number patients with long term follow up for better evaluation of the functional and cosmetic outcomes.

Ethical Approval and Consent

This study was approved after the review by the research ethics committee in Tanta university (ethical committee approval number 32487/07/18) and written consent was taken from the patients' caregivers.

ACKNOWLEDGEMENTS

None.

COMPETING INTERESTS

All authors declared no conflict of interest.

AUTHORS' CONTRIBUTIONS

Mohammed Elmaadawy designed the study, performed the statistical analysis, wrote the protocol, and wrote the first draft of the manuscript. Osama Elgamal and mohamed Adel Omar managed the analyses of the study. Samir El-gamal revised and edited the final version of the manuscript. All authors read and approved the final manuscript.

REFERENCES

1. **Barbaro M, Wedell A, Nordenström A.** Disorders of sex development. *Seminars in fetal & neonatal medicine.* 2011;16(2):119-27.
2. **Kluth D, Fiegel HC, Geyer C, Metzger R.** Embryology of the distal urethra and external genitals. *Seminars in pediatric surgery.* 2011;20(3):176-87.
3. **Keays MA, Dave S.** Current hypospadias management: Diagnosis, surgical management, and long-term patient-centred outcomes. *Canadian Urological Association journal = Journal de l'Association des urologues du Canada.* 2017;11(1-2Suppl1):S48-s53.
4. **Springer A, Tekgul S, Subramaniam R.** An Update of Current Practice in Hypospadias Surgery. *European Urology Supplements.* 2017;16(1):8-15.
5. **Canning DA. Re:** single- vs. multi-stage repair of proximal hypospadias: the dilemma continues. *J Urol.* 2014;191(6):1873.
6. **Bracka A.** Hypospadias repair: the two-stage alternative. *British journal of urology.* 1995;76 Suppl 3:31-41.
7. **Bracka A.** A versatile two-stage hypospadias repair. *British journal of plastic surgery.* 1995;48(6):345-52.
8. **Manasherova D, Kozyrev G, Nikolaev V, Abdullaev F, Abdulkarimov G, Kushnir B, et al.** Bracka's Method of Proximal Hypospadias Repair: Preputial Skin or Buccal Mucosa? *Urology.* 2020;138:138-43.
9. **McNamara ER, Schaeffer AJ, Logvinenko T, Seager C, Rosoklija I, Nelson CP, et al.** Management of Proximal Hypospadias with 2-Stage Repair: 20-Year Experience. *J Urol.* 2015;194(4):1080-5.

10. **Badawy H, Dawood W, Soliman AS, Fahmy A, Mahfouz W, Moussa A, et al.** Staged repair of proximal hypospadias: Reporting outcome of staged tubularized autograft repair (STAG). *Journal of pediatric surgery*. 2020;55(12):2710-6.

11. **Snodgrass W, Prieto J.** Straightening ventral curvature while preserving the urethral plate in proximal hypospadias repair. *J Urol*. 2009;182(4 Suppl):1720-5.

12. **Al-Adl AM, Abdel Aal AM, El-Karamany TM, Noureldin YA.** Two-stage repair of proximal hypospadias with moderate to severe chordee using inner preputial skin graft: prospective evaluation of functional and cosmetic outcomes. *World journal of urology*. 2020;38(11):2873-9.
13. **Shandilya G, Kureel SN, Gupta A, Singh GP, Pandey A, Rawat JD, et al.** Bracka Urethroplasty with Buccal Mucosa Graft: Ergonomic Management of Penile Skin Dartos in the First Stage to Facilitate Second-stage Neourethral Coverage. *Journal of Indian Association of Pediatric Surgeons*. 2021;26(1):11-5.
14. **Faure A, Bouty A, Nyo YL, O'Brien M, Heloury Y.** Two-stage graft urethroplasty for proximal and complicated hypospadias in children: A retrospective study. *Journal of pediatric urology*. 2016;12(5):286.e1-.e7.
15. **Fichtner J, Filipas D, Fisch M, Hohenfellner R, Thüroff JW.** Long-term followup of buccal mucosa onlay graft for hypospadias repair: analysis of complications. *J Urol*. 2004;172(5 Pt 1):1970-2.
16. **Snodgrass W, Elmore J.** Initial experience with staged buccal graft (Bracka) hypospadias reoperations. *J Urol*. 2004;172(4 Pt 2):1720-4.
17. **Barroso U, Jr., Macedo A, Jr.** Initial experience with 'inverted U' staged buccal mucosa graft (bracka) for hypospadias repair. *Journal of pediatric urology*. 2009;5(2):90-2.
18. **Zhao M, Li Y, Tang Y, Chen W, Yang Z, Li Q, et al.** Two-stage repair with buccal mucosa for severe and complicated hypospadias in adults. *International journal of urology : official journal of the Japanese Urological Association*. 2011;18(2):155-61.
19. **Snodgrass WT, Bush N, Cost N.** Algorithm for comprehensive approach to hypospadias reoperation using 3 techniques. *J Urol*. 2009;182(6):2885-91.

20. **Zheng D, Fu S, Li W, Xie M, Guo J, Yao H, et al.** The hypospadias classification affected the surgical outcomes of staged oral mucosa graft urethroplasty in hypospadias reoperation: An observational study. *Medicine*. 2017;96(47):e8238.

21. **Leslie B, Lorenzo AJ, Figueroa V, Moore K, Farhat WA, Bägli DJ, et al.** Critical outcome analysis of staged buccal mucosa graft urethroplasty for prior failed hypospadias repair in children. *J Urol*. 2011;185(3):1077-82.

22. **Wani SA, Baba AA, Mufti GN, Rashid KA, Bhat NA, Buch M, et al.** Bracka verses Byar's two-stage repair in proximal hypospadias associated with severe chordee: a randomized comparative study. *Pediatric surgery international*. 2020;36(8):965-70.