

Original Research Article

Foreign bodies of Airway: Our experience at a tertiary care center in Gujarat, India

Abstract

Background: Foreign bodies of airway are a common cause of mortality in pediatric age group. The management of these requires multi-departmental approach. In our study we share our experience of foreign body management over a period of 3 years at a tertiary care center in Gujarat.

Aims: 1) erasethe number To study incidence, age and gender distribution of foreign bodies in airway; To establish the methods for managing foreign bodies of airway, to study the complications of foreign bodies.

Methods and management: A prospective study was performed in the department of Otorhinolaryngology in GG. Hospital, Jamnagar, from the year 2018 to 2021. Data was collected for patients with foreign body aspiration.

Results: The most common age group being between 1-2 years of age (48.27%). The mean age in our study was 25.6 months. There was a slight male predilection of 51.72% (n=30), and 48.27% (n= 28) being females. Choking and paroxysmal coughing were the most common symptoms, seen in 68.96% and 77.58% of the patients respectively. Right main bronchus was more commonly affected, 51.72% cases. Peanuts were the most commonly encountered foreign bodies, 58.62%. Laryngeal spasm was the commonest intra operative complication. Post operatively pneumonia was the commonest complication, treated with antibiotics and steroids.

Conclusion: Foreign bodies in the airway are associated with a significantly higher morbidity and mortality. The difficulty in removal of the foreign bodies depends on their location and type, the instruments and the anesthesia available. It continues to pose a challenge even for experienced endoscopists, however, a pre-operative CT scan is extremely helpful.

Introduction:

Choking remains a common cause of mortality in pediatric age group.[1]Foreign bodies of airway have always posed a challenge for otorhinolaryngologists. These challenges have to do with the age of the patients, who usually belong to pediatric group, as well as the challenge of handling the airway itself.

Foreign bodies in the airways are associated with a significantly higher morbidity and mortality, compared to other ENT foreign bodies. The difficulty in removal of the foreign body depends on the location, the availability of instruments and the mode of anesthesia. In our study we discuss the clinical presentation, diagnosis and management protocols as well as the complications of the foreign bodies of bronchus encountered at a tertiary care center in Gujarat.

Aims:

- 1) To collect systematic and accurate information regarding the comparative incidence, age and gender distribution of foreign bodies in airway.
- 2) To establish the methods for managing foreign bodies, with least possible complications and maximum efficacy.
- 3) To study the incidence of immediate complications of foreign body related injuries, and methods of their management.

Methods and materials:

A prospective study of 58 patients was performed in the department of Otorhinolaryngology in GG. Hospital, Jamnagar, from the year 2018 to 2021.

The study group includes patients presenting with the foreign body lodgment in the airway in emergency OPD, and patients referred from the department of pediatrics with suspicion of foreign body aspiration. All of the included patients underwent rigid bronchoscopy. The data was collected from hospital records, and pro-forma containing detailed history and examination was filled out. Each patient was followed from admission up till 1 week after discharge.

Inclusion criteria:

- 1) Patients presenting to the ENT OPD with history or signs and symptom of foreign body ingestion
- 2) Patients referred from other departments with foreign body aspiration

Exclusion criteria:

- 1) patients unwilling for surgical intervention or patients referred to higher centers for management.

Observations and results:

The most of the patients were below 3 years of age. the most common age group being between 1-2 years of age (48.27%). The mean age in our study was 25.6 months, the minimum age being 10 months and the oldest being 5-year-old.

Table number 1. Demography of the study

Age group	Number of patients	Percentage
Below 1 year	6	10.34%
1-2 years	28	48.27%
2-3 years	14	24.13%
Above 3 years	10	17.24%
Total	58	100%

These results are similar to the case series from the Nagoya city university hospital,[2] where the common age group involved was also between 1-2 years of age. Numerous other studies have also found the commonly affected to be below 3 years of age.[3][4][5]

There was a slight male predilection of 51.72% (n=30), with 48.27% (n= 28)being females. Whereas the Dale G. Johnson[9] study showed that males (67.88%) were more commonly affected than females (32.13%).

Duration of lodgment was noted on the basis of history of foreign body ingestion or the duration of symptoms. Patients usually present within 24 hours of foreign body aspiration, with 27.58% presenting within the first 8 hours. 10.34% presented within 1-5 days, 10.34% presented within 5-10 days, 17.24% within 10-30 days and 3.44% between 1-6 months. The mean duration of lodgment was 196.4 hours, with the minimum duration being 2 hours and maximum duration being 6 months. The standard deviation was 595.6 hours.

Table number 2. Total duration and number of cases

Duration	Number of cases	Percentage
2-8 hrs	16	27.58%
8-24 hrs	18	31.03%
1-5 days	6	10.34%
5-10 days	6	10.34%
10-30 days	10	17.24%
1-6 months	2	3.44%
>6 months	-	0
Total	58	100%

The above table shows the duration of foreign body aspiration. It is based on the history given by the patients or parents and guardians. The current study had 14 cases without any definitive history of foreign body ingestion. These patients presented with complaint of acute onset cough, respiratory distress or decreased air entry on examination. Some patients presented with chronic respiratory illness, but the clinical and radiological examination pointed towards the possibility of foreign body aspiration. 2 patients in our study had been suffering from persistent dry cough, intermittent episodes of fever and eventual emancipation. An HRCT of the chest showed the possibility of foreign body in the left main bronchus. Following this a bronchoscopy was performed and pieces of food particles were found in both cases.

In the Cohen et al series 50% of the cases were treated within 24 hrs. and 74% by 10 days.[6] 26% of the cases were treated between 10 days and 1 month. The rest more than 1 month. Studies by C. Jackson et al[7] and Harboyan G. et al[8] advised a diagnostic bronchoscopy in pediatric cases with chronic respiratory disease in children, especially in chronic obstructive lung diseases, as these patients have a remote possibility of foreign body aspiration without a definitive history. A bronchoscopy in these patients may also be useful for clearance of mucous plugs and retained secretions.

Patient's presentation:

Patients presenting directly to an Otorhinolaryngologist, or from the pediatric department, or primary or secondary health centers, represents the awareness among other doctor, and patients regarding foreign body aspiration. In present series, 44.82% of the cases were referred by Pediatrician, 34.48% of the cases were referred from the peripheral centers and 17.24% of the cases presented directly to the ENT department.

Symptoms:

The most common presentation was coughing (77.58%), choking (68.96%), dyspnea (68.96%), excessive crying (62.06%), vomiting (39.65%), throat pain (10.34%), unconsciousness and convulsions (3.44%) each were the main presenting symptoms. 75.86% of the patients had history of foreign body ingestion.

Table number 3 List of symptoms and cases

Symptoms	Number of cases	Percentage
History of foreign body ingestion	44	75.86%
Paroxysmal Cough	45	77.58%
Choking	40	68.96%
Vomiting	23	39.65%
Dyspnea	40	68.96%
Excessive Crying	36	62.06%
Throat pain	6	10.34%
Unconsciousness	2	3.44%
Convulsions	2	3.44%

Physical examination:

Decreased air entry in right was the most common finding (51.72%), followed by decreases air entry in left lung (37.93%), Indrawing in subcostal, intercostal and supraclavicular region (34.48%), Cyanosis (27.58%), Stridor (6.89%), Subcutaneous emphysema (3.44%). subcutaneous emphysema was seen in 2 patients due to ingestion of a metallic pin.

Table number 4. List of signs and cases

Signs	Number of cases	Percentage
Cyanosis	16	27.58%
Indrawing in subcostal, intercostal and supraclavicular region	20	34.48%

Decreased air entry in left upper/middle/lower zones	42	37.93%
Decreased air entry in right upper/middle/lower zones	30	51.72%
Bilateral decreased air entry	4	6.89%
Stridor	4	6.89%
Subcutaneous emphysema	2	3.44%

In the Dale G. Johnson series,[9] coughing, choking, wheezing was present in about 95% of the cases. However, in this study, choking is present in 68.96% of the cases and coughing in 58.62% of the cases.

Nature of foreign body:

Peanuts (58.62%) were the most commonly found foreign bodies, followed by Other nuts/seeds(20.68%), Food particles (6.89%), Metal object (6.89%) and Plastic object (6.89%).

Various studies found food particles to be more common in developing countries [2] and toy part to be common in developed countries,[3][4] to be the most commonly aspirated foreign bodies.

Diagnosis:

The radiological examination is the most valuable diagnostic tool. Chest radiographs and computed tomography were the modalities of choice.

Radio opaque foreign bodies are visible on chest X-rays are, also for the changes made by a possible foreign body in the lung parenchyma and the mediastinum can be seen. Most of these changes are due to trachea-bronchial obstruction.

Obstructive emphysema, atelectasis and pneumonia are the commonest findings on a plain chest radiograph.

Obstructive emphysema shows the following characteristics on a radiograph:

- 1) Mediastinal shift to the normal side.
- 2) Translucency of the lung is increased on the affected side
- 3) The intercostal spaces are widened on the affected side
- 4) The diaphragm is depressed on the affected side, due to limitation in the movement of the diaphragm.

Obstructive collapse has the following findings on a radiograph:

- 1) Dense shadow on the invaded side.
- 2) The diaphragm is shifted upwards due to absence of movement.
- 3) Narrowing of the intercostal spaces on affected side.
- 4) Mediastinal shift to the same side.
- 5) Emphysematous features on the normal side.

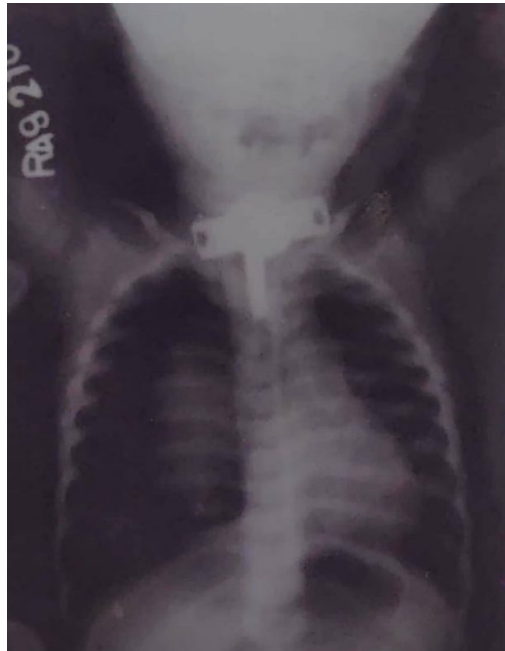

Figure 1 left lung collapse and right lung hyper-inflation in atracheostomised patient

Table number 5 Plain chest radiograph findings

Plain chest radiograph findings	Number of cases	Percentage
Obstructive emphysema	32	55.17%
Atelectasis	6	10.34%
Lobar collapse	4	6.89%
Pneumonia	6	10.34%
Radio opaque foreign bodies	2	3.44%
Normal radiograph	6	10.34%
Radiography not obtained	2	3.44%

The radiographic findings for patients with foreign body in airway found Obstructive emphysema as the most common finding in the Dale G. Johnson series [9] as well, followed by atelectasis, lobar collapse and pneumonia.

Computed tomography:

Rigid bronchoscopy is considered the gold standard for diagnosing foreign body aspiration however, it is still an extremely challenging procedure, requiring an experienced endoscopist and anesthetic team. Despite of this a rigid bronchoscopy is associated with a significant morbidity and mortality.

In an attempt to avoid unnecessary rigid bronchoscopies; In the present series, a Computed tomography of neck and thorax was performed for most of the patients with suspicion of foreign body ingestion. Only following a positive finding, rigid bronchoscopy was performed. Foreign body was found in all of these cases.

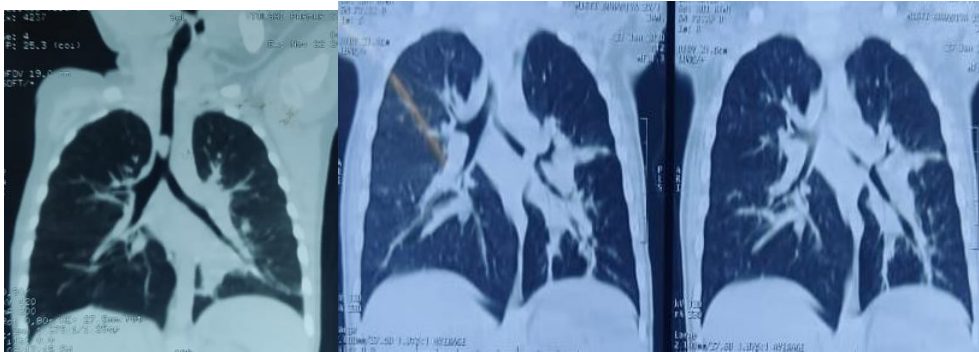


Figure 2 foreign body in trachea Figure 3 foreign body in left bronchus

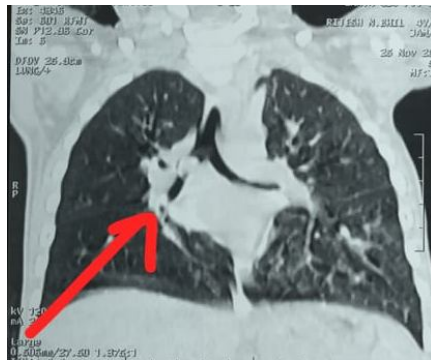


Figure 4 foreign body in right bronchus

A retrospective study by Pitiot V,[10] concluded that, it is advisable to perform a neck and thoracic CT before opting for a rigid bronchoscopy, as this significantly reduces the associated morbidity and mortality.

Site of lodgment of foreign body:

The most common site of lodgment was the right bronchus (51.72%), followed by the left bronchus (37.93%) and then the trachea (6.89%). In Dale G. Johnson series[9] 55% of the patients had foreign body lodgment in the right bronchus, 44% in the left bronchus and 1% had foreign body lodgment in both the bronchi. The same finding was seen in other studies as well.[3][4][5][11][12][13]

The angle of deviation of the right bronchus from the axis of trachea is less as compared to the left main bronchus, and the diameter of the right main bronchus is greater than the left main bronchus are the reasons for predominance of foreign body lodgment in the right bronchus.

Management: Rigid bronchoscopy:

All the cases except one were managed with rigid bronchoscopy with foreign body removal. The 1 case which could not be treated, presented with a metallic pin ingestion associated with

subcutaneous emphysema over neck and chest, and pneumothorax. The patient was referred to a pediatric surgeon for further management. This accounts for 0.3% of the patients.

In the Dale G. Johnson series,[9] only one patient was referred for thoracotomy. In this case the patient had a straight pin lodged in the distal bronchi, and 2 consecutive attempts at removing the foreign body were unsuccessful.

Tracheostomy and bronchoscopy:

Only 1 patient underwent tracheostomy in the current study group, which was performed intra-operatively. It was performed as repeated attempts at the removal of foreign body (groundnut) resulted in a subcutaneous emphysema. In cases with a large foreign body, if there is impaction in the sub-glottis, just below at the vocal cords a tracheostomy may be required.

Complications:

Laryngospasm and cardiopulmonary arrest was seen in 3.44% patients each. Subcutaneous emphysema in 1.72% patients and post operative pneumonia in 6.89% patients. In the Dale G. Johnson series[9] with 548 laryngospasm, bronchospasm, cardiopulmonary arrest and pneumo-mediastinum were seen in 0.18% of the patients each; pneumonia was seen in 1.09% of the patients. Postoperative pneumonia was the commonest complication, managed by antibiotics and steroids. Mortality of 3.44% (n=2) occurred in our study both occurred due to intra-operative cardiopulmonary arrest. The Dale G. Johnson series [9] showed no mortality.

Discussion:

Foreign bodies aspirated into airway can result in respiratory distress is an otolaryngological emergency and requires a great amount of experience and expertise to manage. The presentation can be acute with respiratory distress or chronic with pneumonia, failure to thrive and emaciation.

Aspiration of foreign bodies is mostly encountered in paediatric age group; one study found the mean age to be 24 months and 98% of the patients below 5 years of age.[11] The national safety council of America found the rate of fatal choking in children <5 years of age to be 0.43 per 100,000 population.[3] The following factors are thought to be contributory:

1. Children below 1 year of age being given beans or nuts to eat. This often results in foreign body aspiration due to lack of proper dentition and hence the inability to chew.
2. Children putting inedible substances in mouth, in absence of proper vigilance by the guardians.
3. Children playing while eating.

The presentation of foreign body aspiration largely depends on the nature (organic or inorganic), size and shape of the foreign body. A foreign body which is large enough to cause complete obstruction of the airway can lead to sudden death, whereas a hard and sharp foreign body damages the airway directly.[1] However choking and cough were the most common presentation, as has been noted in multiple studies [3][4], this coupled with a positive history and abnormal physical examination warrants bronchoscopy.

In all cases of suspected foreign aspiration an HRCT of the thorax was performed, and is found to be extremely helpful in identifying the location and type of foreign body. This goes a long way in anticipating the difficulties that would be encountered during bronchoscopy. The density of the

foreign body which is measured by Hounsfield unit, gives us an estimate about the nature of the foreign body. Foreign bodies of higher densities are harder and come out in a single piece. However lower density foreign bodies are likely to be more fragile and have to be removed piecemeal. Another advantage is the estimate of the size of the foreign body, it is especially useful to ensure that the foreign body has been removed completely. If a size smaller than mentioned in the scans is removed, it is imperative to carry out a check bronchoscopy, to ensure that all the pieces have been removed.

A plain chest X-ray can be used as a preliminary investigation, however in 10.34% of the patients at our study, it was found to be normal. A series found as many as 45% patients with normal chest X-rays. [4] Many centres have been using a chest radiograph as the only radiological investigation, and bronchoscopy is performed based on x ray findings. Chest X-rays are used post operatively for monitoring improvement in the lung fields.

Rigid bronchoscopes are preferred over flexible bronchoscopes for foreign body extraction, as these provide a number of advantages; these include larger lumen for instrument manipulation, ability to remove larger foreign bodies, simultaneous ventilation, and real view of the airway. Flexible bronchoscopes find better application for diagnostic rather than therapeutic purposes. In our study all the foreign bodies were extracted with a rigid bronchoscope.

A review report found the incidence of complications to be equal in both high- and low-income countries, and these occur in a considerable number of cases (10% and 20%) respectively.[14][15] The rate of complications increases with increase in duration of foreign body lodgment. However, the clinical findings may not be evident if the patient is being treated with antibiotics and steroids. [3]

Conclusions:

To summarize, in our study, the most common age group affected was between 1-2 years of age. most of the patients presented within the first 24 hours of foreign body ingestion. However, cases as old as 6 months have also been encountered in the current series. Peanuts were the most commonly encountered foreign bodies, 58.62%, which implicates that hard food items like seeds or nuts should be given to children cautiously. Also toys with small detachable parts should be avoided. Choking and paroxysmal coughing were the most common symptoms, seen in 68.96% and 77.58% of the patients respectively along with unilaterally decreased air entry which was seen in approximately 87% of the patients. These findings form a ground for suspecting foreign body aspiration and should prompt a formal bronchoscopy.[3][4] Most common finding on a plain chest radiograph is obstructive emphysema. Computerized tomography has excellent sensitivity in diagnosing foreign body aspiration, and also gives clues about the type of foreign body, as it is highly recommended to perform a pre-operative scan in centers where it is free available. Rigid bronchoscopy remains the treatment option of choice. The overall management requires a multi-departmental effort.

Funding: No funding was received to conduct the above study

Compliance with ethical Standards

Conflict of interest: The authors declare no conflict of interest and do not have any potential financial conflict of interest related to or could influence this work.

Ethical Approval: The research protocol was accented by the institution ethics committee of the said institution and did not raise any ethics related concerns.

References:

- 1) Shilpa V. Hegde, Peter K.T. Hui, Edward Y. Lee, Tracheobronchial Foreign Bodies in Children: Imaging Assessment, Seminars in Ultrasound, CT and MRI, Volume 36, Issue 1,2015
- 2) Yamamoto S, Suzuki K, Itaya T, Yamamoto E, Baba S. Foreign bodies in the airway: eighteen-year retrospective study. *ActaOtolaryngol Suppl.* 1996; 525:6-8. PMID: 8908261.
- 3) Cramer N, Jabbour N, Tavarez MM, et al. Foreign Body Aspiration. [Updated 2022 May 2]. In: StatPearls [Internet]. Treasure Island (FL): StatPearls Publishing; 2022 Jan-.
- 4) Even L, Heno N, Talmon Y, Samet E, Zonis Z, Kugelman A. Diagnostic evaluation of foreign body aspiration in children: a prospective study. *J Pediatr Surg.* 2005 Jul;40(7):1122-7. doi: 10.1016/j.jpedsurg.2005.03.049. Erratum in: *J Pediatr Surg.* 2005 Nov;40(11):1815. Lea, Even [corrected to Even Lea]; Nawaf, Heno [corrected to Heno, Nawaf]; Yoav, Talmon [corrected to Talmon, Yoav]; Elvin, Samet [corrected to Samet, Elvin]; Ze'ev, Zonis [corrected to Zonis, Ze'ev]; Amir, Kugelman [corrected to Kugelman, Amir]. PMID: 16034756.
- 5) Committee on Injury, Violence, and Poison Prevention. Prevention of choking among children. *Pediatrics.* 2010 Mar;125(3):601-7. doi: 10.1542/peds.2009-2862. Epub 2010 Feb 22. PMID: 20176668.
- 6) 1980: Cohen SR, Herbert WI, Lewis GB, Jr, et al: Foreign bodies in the airway. Five year retrospective study with special reference to management *Ann. OtolRhinolLaryngol* 89: 437-442, 1980.
- 7) Jackson, C. and Jackson, C.L. (1936), Diseases of the air and food passages of foreign body origin. *The Laryngoscope*, 46: 814-814. <https://doi.org/10.1288/00005537-193610000-00008>.
- 8) Harboyan, G., &Nassif, R. (1970). Tracheobronchial foreign bodies—a review of 14 years' experience. *The Journal of Laryngology & Otology*, 84(4), 403-412. doi:10.1017/S0022215100072017.
- 9) Bronchoscopic removal of aspirated foreign bodies in children by Richard E. Black, Dale G. Johnson, Michael E. Matlak, *Journal of Pediatric Surgery*, Elsevier, May 1994.
- 10) Pitiot V, Grall M, Ploin D, Truy E, AyariKhalfallah S. The use of CT-scan in foreign body aspiration in children: A 6 years' experience. *International Journal of Pediatric Otorhinolaryngology.* 2017 Nov; 102:169-173. DOI: 10.1016/j.ijporl.2017.08.036.
- 11) Chiu CY, Wong KS, Lai SH, Hsia SH, Wu CT. Factors predicting early diagnosis of foreign body aspiration in children. *PediatrEmerg Care.* 2005 Mar;21(3):161-4. PMID: 15744193. Chiu CY, Wong KS, Lai SH, Hsia SH, Wu CT. Factors predicting early diagnosis of foreign body aspiration in children. *PediatrEmerg Care.* 2005 Mar;21(3):161-4. PMID: 15744193.
- 12) Chapin MM, Rochette LM, Annest JL, Haileyesus T, Conner KA, Smith GA. Nonfatal choking on food among children 14 years or younger in the United States, 2001-2009. *Pediatrics.* 2013 Aug;132(2):275-81. doi: 10.1542/peds.2013-0260. Epub 2013 Jul 29. PMID: 23897916.
- 13) Cleveland RH. Symmetry of bronchial angles in children. *Radiology.* 1979 Oct;133(1):89-93. doi: 10.1148/133.1.89. PMID: 472318

- 14) Foltran F, Ballali S, Rodriguez H, Sebastian van As AB, Passali D, Gulati A, Gregori D. Inhaled foreign bodies in children: a global perspective on their epidemiological, clinical, and preventive aspects. *PediatrPulmonol.* 2013 Apr;48(4):344-51. doi: 10.1002/ppul.22701. Epub 2012 Nov 20. PMID: 23169545.
- 15) Hayes NM, Chidekel A. Pediatric choking. *Del Med J.* 2004 Sep;76(9):335-40. PMID: 15510972.

UNDER PEER REVIEW