

## **Case study**

### **Rare Case of Gastric Arteriovenous Malformation with Persistent Anemia in a Patient with Recurrent Arteriovenous Malformation Widespread in Gastrointestinal Tract**

#### **Abstract:**

Arteriovenous malformation (AVM) is an abnormal entanglement of blood vessels. AVMs in the gastrointestinal (GI) tract is a rare condition and are often found incidentally during GI bleeding investigations. We present a case of a 57-year-old patient with chronic anemia who was diagnosed with AVM of the GI tract by colonoscopy treated with argon based laser therapy. Pt re-developed arteriovenous malformation in duodenum and ileum which are considered as unusual locations of this clinical entity. We also discussed pathogenesis, diagnosis, and reviewed available treatment options for GI AVMs.

Keywords : Arterio venous Malformation ,Anemia,Colonoscopy

#### **Introduction:**

Arteriovenous malformation (AVM) is an abnormal web or tangle of blood vessels consisting of feeding arteries and draining veins without endothelial hyperplasia. Though AVM is rare affecting 1 out of 100,000 with no sexual or ethnic predilection, it is a significant cause of morbidity for those who are affected [1]. While Central AVM affecting the head-neck region is the commonest, it can happen anywhere in the body (Peripheral AVM) e.g. over the trunk, or on other visceral organs [2,3]. AVM is thought to occur due to the failure in apoptosis of embryonic AV shunts. Molecular studies have shown aberrant signaling processes regulating proliferation and differentiation, maturation, adhesion of vascular cells, and apoptosis [4]. AVM in the gastrointestinal tract is a potential source of bleeding, and almost always requires surgical intervention [5,6].

#### **Case presentation:**

A 57 year old male has a past medical history of severe recurrent anemia, lumbar radiculopathy was brought to ED due to dizziness, progressive lower GI bleed, abdomen pain and weakness for a week. Patient reported that he has been feeling fatigued and light headed on and off for the past few months. He denied any fall or loss of consciousness.

He denied any fever, vomiting, recent travel or sick contacts.

Per the patient, he had a similar presentation every six months, for the past 6-8 yrs. The last EGD and colonoscopy was done 2 years ago showing multiple AVMs in jejunum and ileum with

a capsule endoscopy and 2 colonoscopies in the 2 prior contiguous years with coagulation of AVMs, every time with similar presentation.

On review of systems he was positive for malaise, fatigue, shortness of breath on exertion, low back pain and occasional lightheadedness. On arrival vitals were stable, with a blood pressure of 119/63, pulse of 80, temperature of 36.7C, respiratory rate of 18, and SpO2 of 100%.

On physical Examination patient was icteric, pale conjunctiva, bilateral non-tender mobile cervical and inguinal lymph nodes measuring 1-2 cm, a round sessile non tender lipoma of 8\*8 cm on the left scapula. An abdominal examination revealed tenderness in the epigastrium and palpable neurofibromas under the skin. On Respiratory examination no crepts or rales appreciated. On Cardiovascular examination faint systolic murmur in the mitral area  
Appropriate labs done at the time of admission are shown in tables 1:

Test	Ref Range and Units	Values
WBC	4.5-11.0 10x3/uL	6.1
Neutrophil %	40.0-70.0 %	59.4%
Lymphocytes %	22.0-48.0 %	15%
Monocytes %	2.0-14.0 %	7.8%
<b>Eosinophil %</b>	<b>0.5-5.0 %</b>	16.1%
<b>Basophil %</b>	<b>0.0-2.0 %</b>	0.3%
Hb	11.0-15.0 g/dL	3.4
Hct	39-53%	12.4%
Retic count absolute	0.02 - 0.1 10x6/uL	0.0405
Retic percent auto	1-2%	2.34%
Ferritin	17.90 - 464.00 ng/mL	12.70

Iron	49.0 - 181.0 ug/dL	60.0
TIBC	240.00 - 450.00 ug/dL	356.73
Iron saturation	%	17
Transferrin	206.00 - 381.00 mg/dL	254.81
BUN	7.0-18.7 mg/dL	10.7
Creatinine	0.57-1.11 mg/dL	0.84
Na	136-145 mmol/L	136
K	3.5-5.1 mmol/L	4.5
CO2	22-29 mmol/L	19
Total Bilirubin	0.2-1.2 mg/dL	0.8
ALT	10-55 U/L	28
AST	5-34 U/L	67
ALP	40-150 U/L	87.9
Albumin	3.5-5.2 g/dL	3.5
Phosphorous	2.3-4.7 mg/dl	3.3
Ca	8.4-10.2 mg/dL	8.7
BNP	10-100 pg/ml	103.3
Lactate	0.50-1.90 mmol/L	

PT	10-13 s	13.1
INR	1	1.2
Procalcitonin	0.00-0.08 ng/ml	
HIV-1,2		Non-reactive
SARS-Cov-2 PCR	Not detected	Not detected

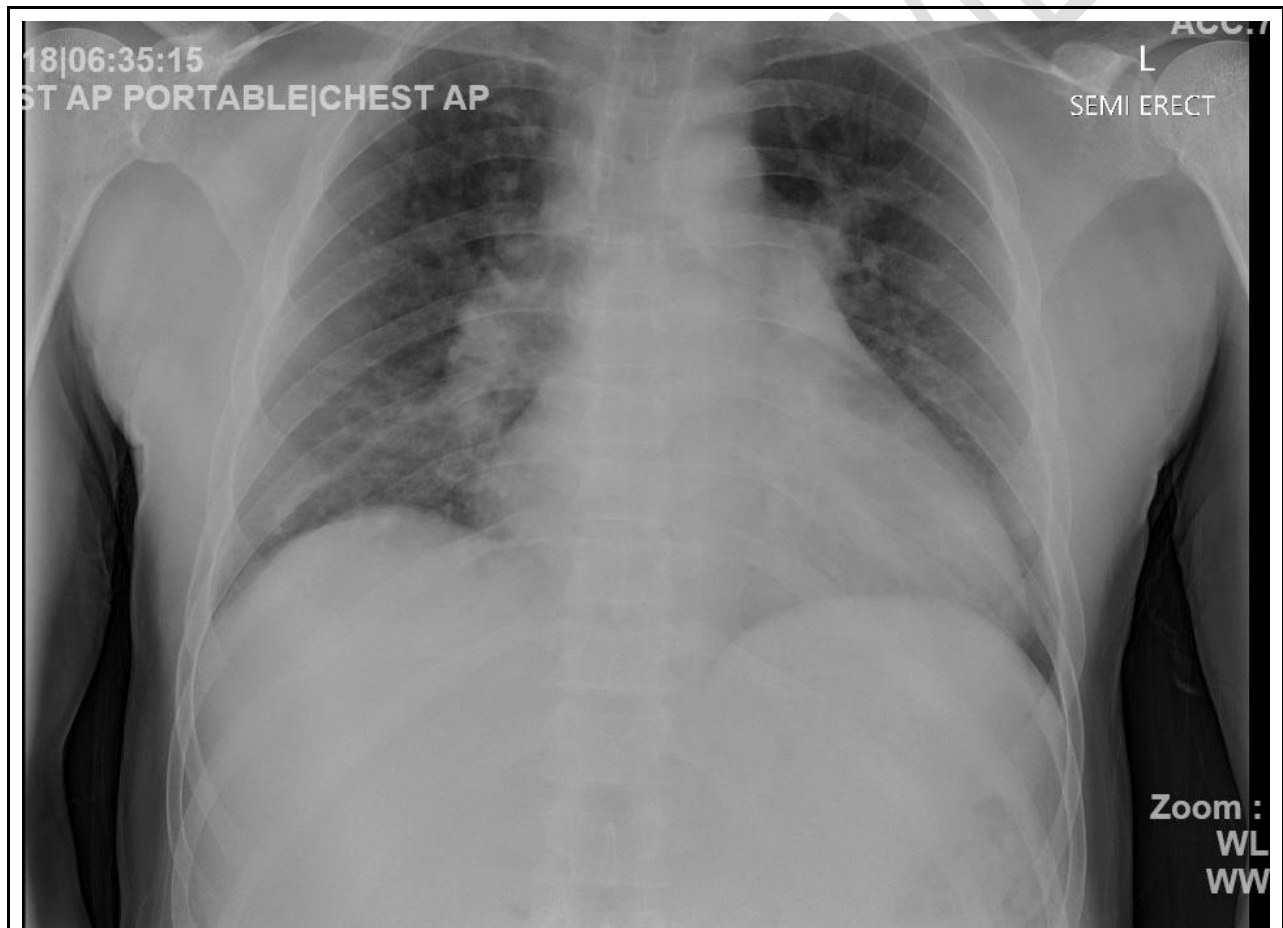


Figure 1 :Chest X ray - Perihilar and bilateral lower lobe atelectasis and/or Consolidations and prominent cardiac silhouette

RAST|Chest 3.0 B70f LUNG

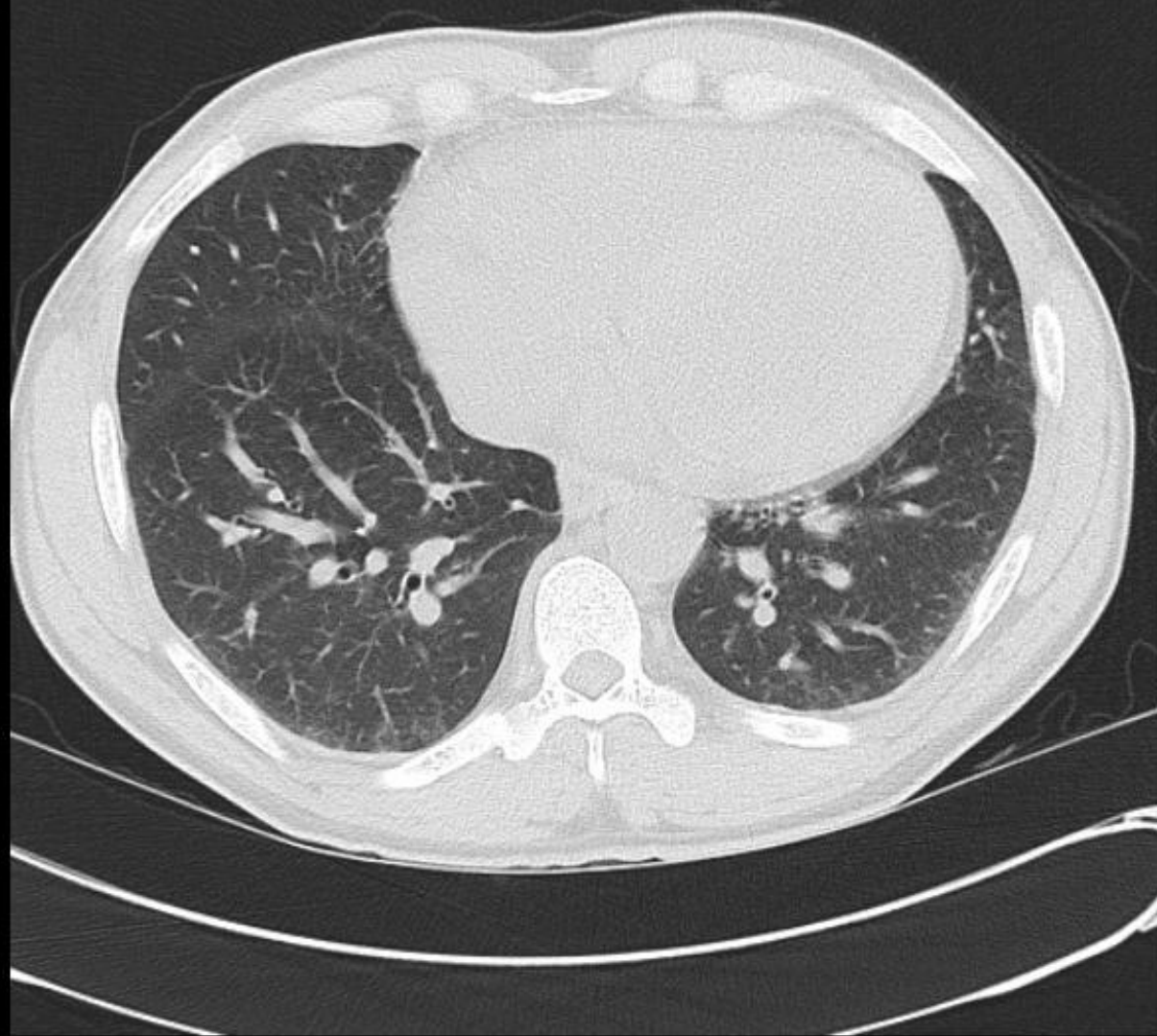


Figure 2 : CT Chest was insignificant.

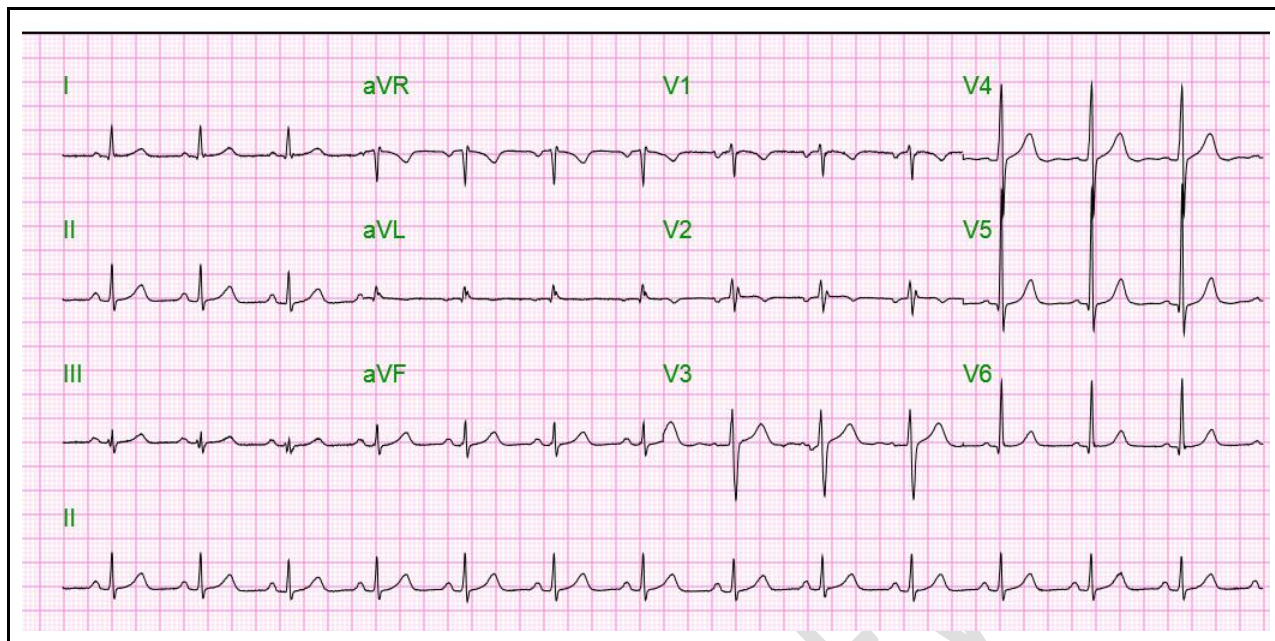


Figure 3: Echocardiogram image

Stool guaiac test is positive and patient had 2 episodes of frank per rectal bleed with bowel movement, after admission. Nuclear GI bleed scan with Tc-99M labeled RBC showed aberrant accumulation of radiotracer within the lower included portion of the stomach, probably the stomach antrum, representing the site of bleeding.

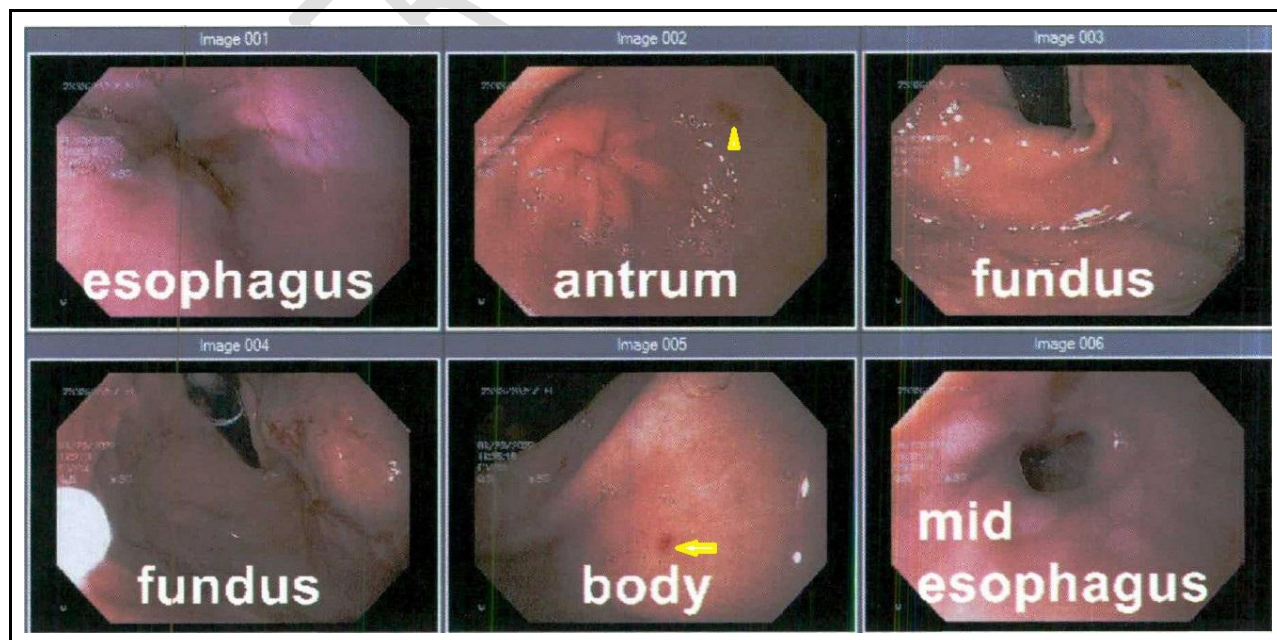
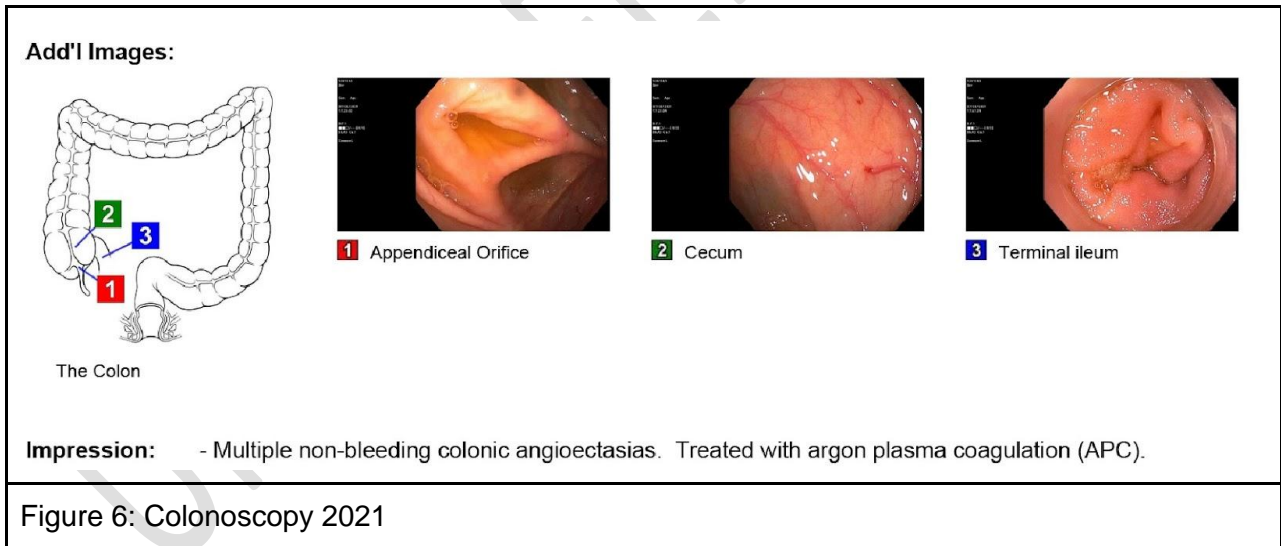
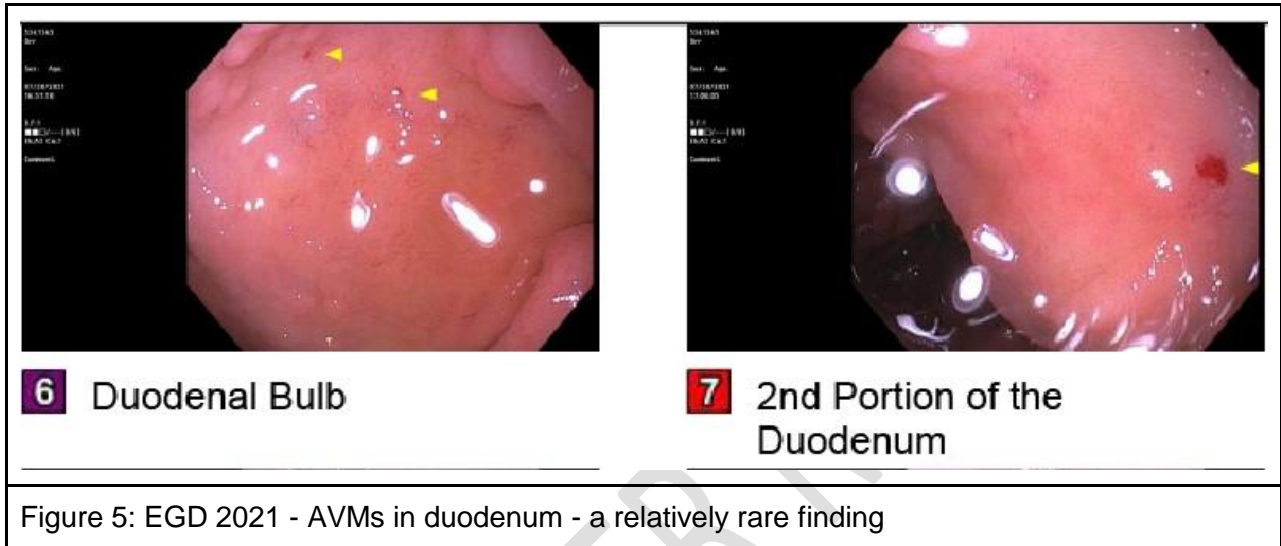


Figure 4: EGD during the current hospitalization - two 6 mm sized oozing AVMs in the stomach which have been treated with epinephrine injection followed by Argon Plasma Coagulation (APC).

As stated above, the patient had AVMs detected and treated with APC in the past:



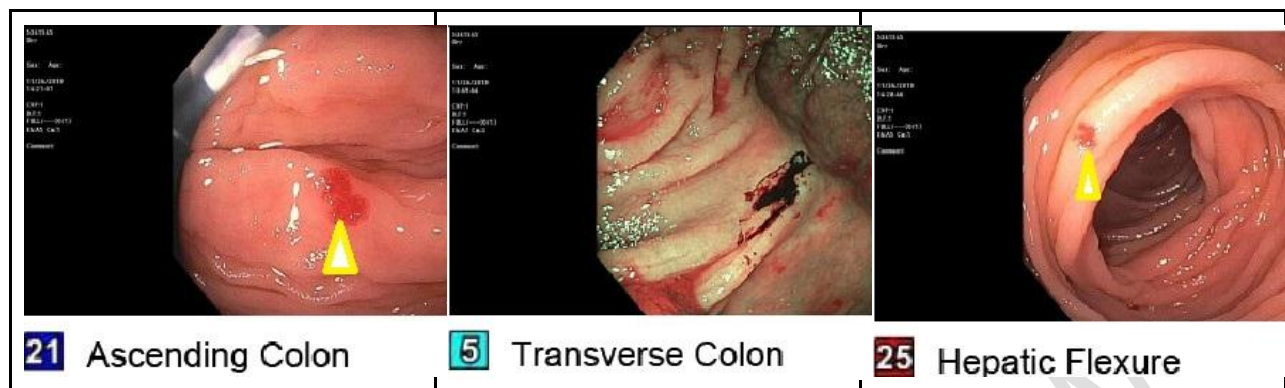


Figure 7: Colonoscopy 2019.

Capsule endoscopy in 2018 showed multiple AVMs in jejunum and ileum.

### Case description :

Anaemia, a public health concern that affects about 25% of worldwide population and the prevalence is more in developing countries [7]. Iron deficiency anaemia (IDA), which is the most frequent cause of anaemia, impacts about 5–12% of non-pregnant women and 1–5% of men with IDA [8]. In post-menopausal women and adult men, the most common cause of IDA is blood loss from gastrointestinal tract (GIT), and the diagnosis and the interpretation of IDA have been made clearly on account of accessibility of widespread testing in crucial population [8].

Although gastrointestinal tract bleeding requires more specific and, in some cases, invasive investigations as there are serious consequences underlying GIT bleeding which may be occult and overt in certain cases [9][10]. Overt gastrointestinal bleeding may be defined as gross bleeding which may present in a patient as gross haematemesis (vomiting blood) and/or melena (black, tarry stool) or obvious haematochezia (passing fresh blood per rectum, usually in or with stool) [9].

Bleeding from the colon is often mild which resolves spontaneously in most of the patient. Nevertheless, bleeding from small bowel lesion can be occult yet serious in some circumstances presenting as severe anaemia due to fatal haemorrhage [11]. One of the causes of major GIT bleeding is demonstrated as vascular lesion which is neoplastic lesions like haemangioma or tumour and non-neoplastic abnormalities including arteriovenous malformation (AVM), although AVM is a quite uncommon cause of GI bleeding [11].

Gastric antral vascular ectasia (GAVE) which is also known as 'Watermelon Stomach' and angiodysplasia, the two most common forms of gastrointestinal vascular ectasia, present as chronic gastrointestinal blood loss that leads to chronic anaemia with life threatening consequences [12]. Angiodysplasias (AD) are characteristically 2-10 mm in size, discrete, marginally elevated or smooth, bright red lesion whereas GAVE is seen endoscopically as linear, friable, red streaks radiating from pylorus [13]. Both of these conditions associated with tendency with chronic gastrointestinal bleeding occur in

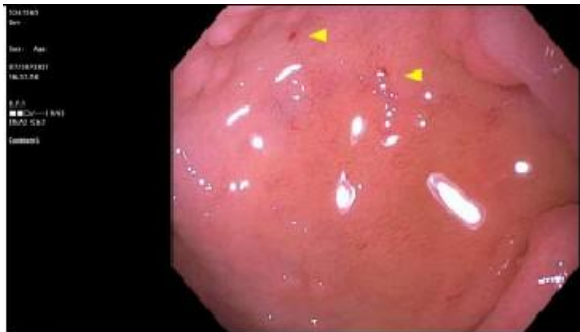patients with underlying conditions such as, Von Willebrand disease, hereditary haemorrhagic telangiectasia (HHT), aortic stenosis, uraemia or end stage renal disease, cirrhosis of liver, systemic sclerosis and a variety of autoimmune disease [13].

AVM is identified as a congenital interconnection of anomalous arteries and veins with thick hypertrophic walls, seen in mostly younger populations, whereas AD has thin-walled submucosal vessels that are enlarged, mostly multiple, often lined by endothelium only and occurs in elderly people, mainly in the right colon [12][13]. Although the pathogenesis of AVM is not well understood, there are some proposed hypotheses regarding the pathogenesis of it. One theory acknowledges that vascular degeneration which is promoted by a reduced amount of oxygenation of GI mucosa as a result of atherosclerosis of the supplying blood vessels while another considerable hypothesis suggests AVM can be caused by increased venous pressure [13]. According to previous studies, patients with AVM are clinically silent or asymptomatic until the presenting events including hematemesis, fresh bleeding per rectum, melena, fatigue, unexplained iron deficiency and grave symptoms of anaemia occur and the diagnosis of patients with AVM are also first made during the first and significant haemorrhagic events [8]. Diagnosis of AVM is usually made by endoscopy, though patients with gastrointestinal bleeding are screened first to diagnose the type of anaemia which usually presents as low haemoglobin level, low transferrin saturation, low total iron binding capacity (TIBC) and low serum iron level. Bone marrow biopsy is also done occasionally to confirm the cause of underlying mechanism of anemia [8].

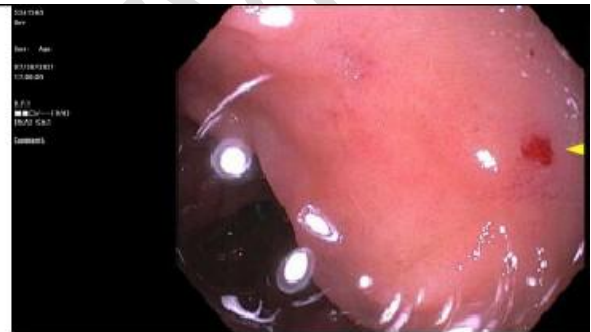To evaluate both upper and lower GI bleeding effectively, esophagogastroduodenoscopy, colonoscopy, small bowel series, abdominal computed tomography (CT), red blood cell (RBC) scan, capsule endoscopy are performed [9], [14]. Capsule endoscopy is effective to diagnose occult GIT bleeding of small intestine. Bleeding focus is described in case of ulcer as lesion with active stage above Forrest II b (adherent clot) whereas in lesion other than ulcer, bleeding focus is defined as oozing, spurting or the presence of adherent clot by doing endoscopic examination [9]. Sometimes surgery and angiographic procedures are also needed to determine the diagnosis of AVM [13].

Management of patients of AVM with chronic anaemia is focused mostly on severity of presentation of anaemia and presence of active bleeding signs as melena, haematochezia or hematemesis [15]. All patients with overt GI bleeding are treated with pure red blood cell (PRBC), platelet and whole blood transfusion [9], [14]. Endoscopic procedures which include Thermal Destruction, Argon Plasma Coagulation are found effective in treatment of widespread AVM with active bleeding. Bipolar Coagulation, Endoscopic Laser, Endoscopic Cryotherapy are other treatment modalities of patients with bleeding in malformed blood vessels in AVM and hereditary haemorrhagic telangiectasia (HHT), although transcatheter angiography and embolization are also done alternatively [10]. Argon plasma coagulation (APC) being the most common and successful treatment option, is done due to its low cost, simplicity of use, lower rate of post procedural complications [13].

Besides widespread use of endoscopic practices, certain pharmacological agents are also needed to treat chronic GIT bleeding and to lessen and prevent the recurrence of bleeding. Hormonal preparations such as oral estrogenic and progesterone preparations and Tranexamic acid have been demonstrated to lessen the necessity of transfusion and reduce the chance of GI bleeding after giving the patients Bevacizumab, an anti-angiogenic medication [15]. Other medications such as Octreotide have been used effectively to manage the active bleeding in GIT [10]. Certain drugs like Thalidomide, Danazol, Recombinant coagulation factors have also been used in a very limited scale and are under active study [10].



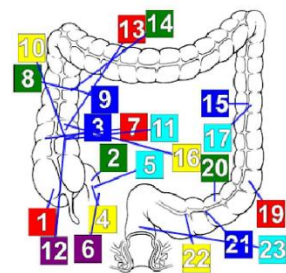
**6** Duodenal Bulb



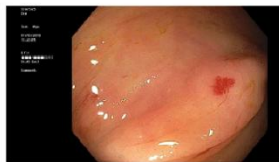**7** 2nd Portion of the Duodenum

Colonoscopy 2018:

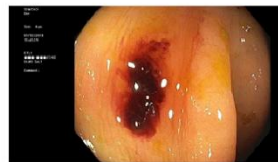Add'l Images:



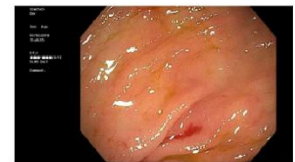The Colon



**3** Ascending Colon : Angiodysplasia



**7** Ascending Colon : Blood clot



**8** Ascending Colon : Angiodysplasia

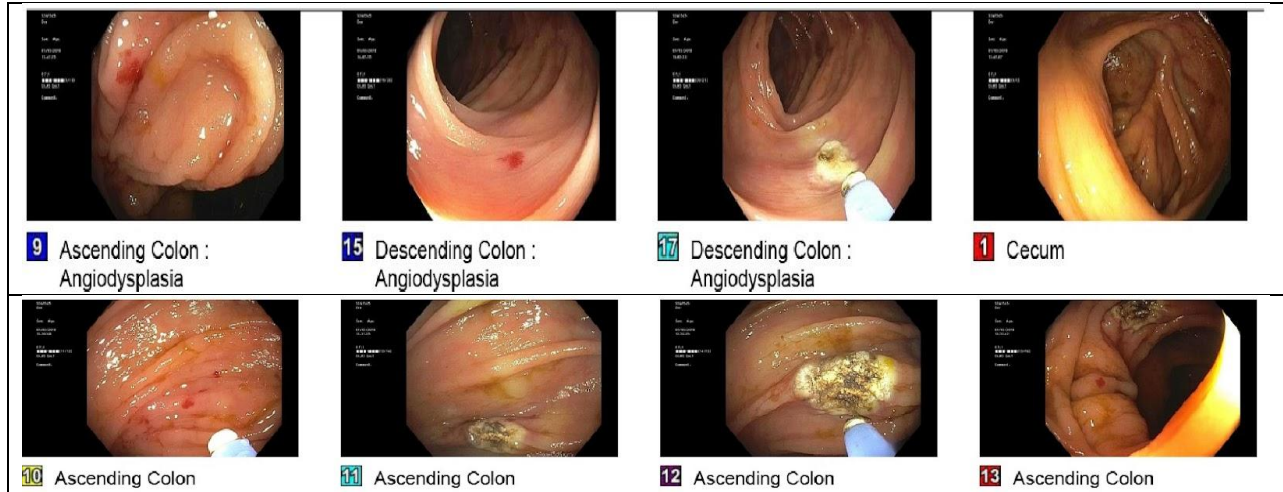


Figure 8: EGD during the current hospitalization - two 6 mm sized oozing AVMs in the stomach which have been treated with epinephrine injection followed by Argon Plasma Coagulation (APC).

As stated above, the patient had AVMs detected and treated with APC in the past:

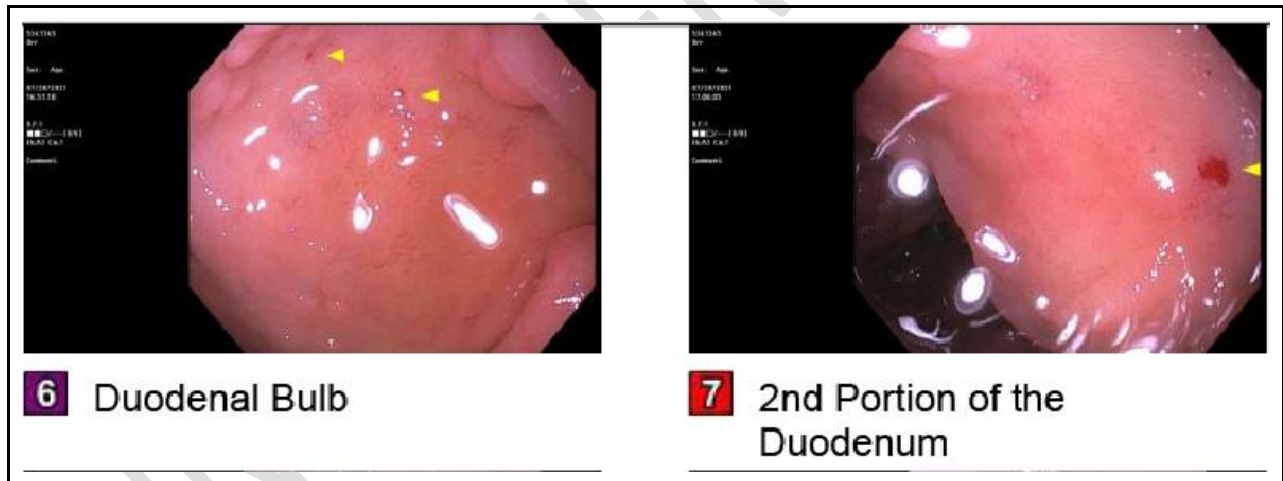


Figure 9: EGD 2021 - AVMs in duodenum - a relatively rare finding

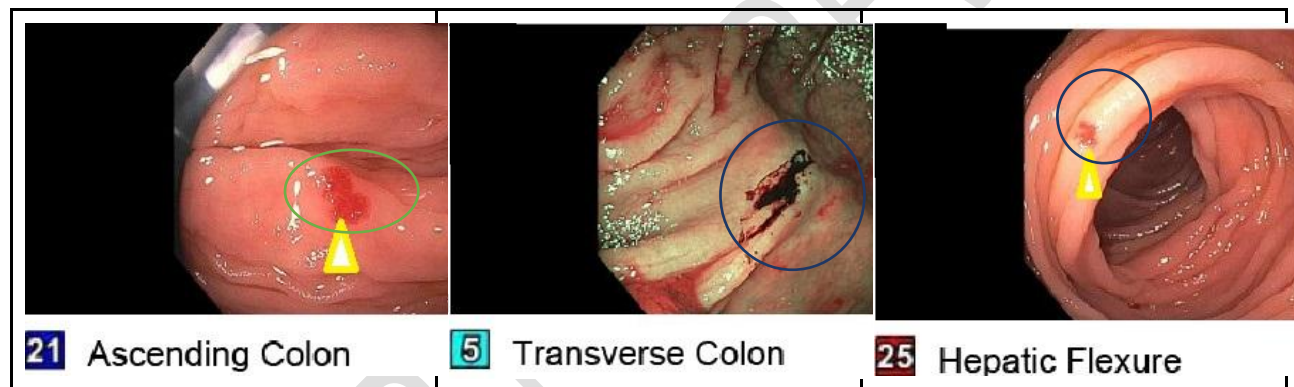
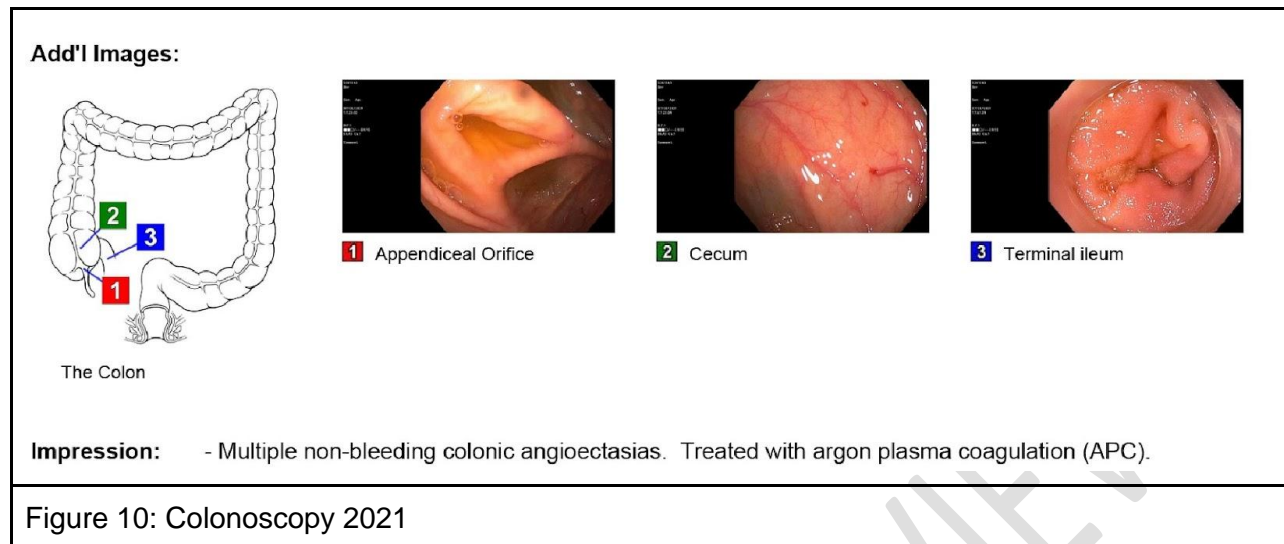


Figure 11: Colonoscopy 2019.

Capsule endoscopy in 2018 showed multiple AVMs in jejunum and ileum.

Anemia, a public health concern that affects about 25% of worldwide population and the prevalence is more in developing countries [7]. Iron deficiency anemia (IDA), which is the most frequent cause of anemia, impacts about 5–12% of non-pregnant women and 1–5% of men with IDA [8]. In post-menopausal women and adult men, the most common cause of IDA is blood loss from gastrointestinal tract (GIT), and the diagnosis and the interpretation of IDA have been made clearly on account of accessibility of widespread testing in crucial population [8].

Although gastrointestinal tract bleeding requires more specific and, in some cases, invasive investigations as there are serious consequences underlying GIT bleeding which may be occult and overt in certain cases [9][10]. Overt gastrointestinal bleeding may be defined as gross bleeding which may present in a patient as gross hematemesis (vomiting blood) and/or melena (black, tarry stool) or obvious hematochezia (passing fresh blood per rectum, usually in or with stool) [9].

Bleeding from the colon is often mild which resolves spontaneously in most of the patient. Nevertheless, bleeding from small bowel lesion can be occult yet serious in some circumstances presenting as severe anemia due to fatal hemorrhage [11]. One of the causes of major GIT bleeding is demonstrated as vascular lesion which is neoplastic lesions like hemangioma or tumor and non-neoplastic abnormalities including arteriovenous malformation (AVM), although AVM is a quite uncommon cause of GI bleeding [11].

Gastric antral vascular ectasia (GAVE) which is also known as 'Watermelon Stomach' and angiodysplasia, the two most common forms of gastrointestinal vascular ectasia, present as chronic gastrointestinal blood loss that leads to chronic anaemia with life threatening consequences [12]. Angiodysplasias (AD) are characteristically 2-10 mm in size, discrete, marginally elevated or smooth, bright red lesion whereas GAVE is seen endoscopically as linear, friable, red streaks radiating from pylorus [13]. Both conditions associated with tendency with chronic gastrointestinal bleeding occur in patients with underlying conditions such as, Von Willebrand disease, hereditary hemorrhagic telangiectasia (HHT), aortic stenosis, uraemia or end stage renal disease, cirrhosis of liver, systemic sclerosis and a variety of autoimmune disease [13].

AVM is identified as a congenital interconnection of anomalous arteries and veins with thick hypertrophic walls, seen in mostly younger populations, whereas AD has thin-walled submucosal vessels that are enlarged, mostly multiple, often lined by endothelium only and occurs in elderly people, mainly in the right colon [12][13]. Although the pathogenesis of AVM is not well understood, there are some proposed hypotheses regarding the pathogenesis of it. One theory acknowledges that vascular degeneration which is promoted by a reduced amount of oxygenation of GI mucosa as a result of atherosclerosis of the supplying blood vessels while another considerable hypothesis suggests AVM can be caused by increased venous pressure [13]. According to previous studies, patients with AVM are clinically silent or asymptomatic until the presenting events including hematemesis, fresh bleeding per rectum, melena, fatigue, unexplained iron deficiency and grave symptoms of anaemia occur and the diagnosis of patients with AVM are also first made during the first and significant haemorrhagic events [8]. Diagnosis of AVM is usually made by endoscopy, though patients with gastrointestinal bleeding are screened first to diagnose the type of anaemia which usually presents as low haemoglobin level, low transferrin saturation, low total iron binding capacity (TIBC) and low serum iron level. Bone marrow biopsy is also done occasionally to confirm the cause of underlying mechanism of anemia [8].

To evaluate both upper and lower GI bleeding effectively, esophagogastroduodenoscopy, colonoscopy, small bowel series, abdominal computed tomography (CT), red blood cell (RBC) scan, capsule endoscopy are performed [9], [14]. Capsule endoscopy is effective to diagnose occult GIT bleeding of small intestine. Bleeding focus is described in case of ulcer as lesion with active stage above Forrest II b (adherent clot) whereas in lesion other than ulcer, bleeding focus is defined as oozing, spurting or the presence of adherent clot by doing endoscopic examination [9]. Sometimes surgery and angiographic procedures are also needed to determine the diagnosis of AVM [13].

Management of patients of AVM with chronic anemia is focused mostly on severity of presentation of anemia and presence of active bleeding signs as melena, haematochezia or hematemesis [15]. All patients with overt GI bleeding are treated with pure red blood cell (PRBC), platelet and whole blood transfusion [9], [14]. Endoscopic procedures which include Thermal Destruction, Argon Plasma Coagulation are found effective in treatment of widespread AVM with active bleeding. Bipolar Coagulation, Endoscopic Laser, Endoscopic Cryotherapy are other treatment modalities of patients with bleeding in malformed blood vessels in AVM and hereditary hemorrhagic telangiectasia (HHT), although transcatheter angiography and embolization are also done alternatively [10]. Argon plasma coagulation (APC) being the most common and successful treatment option, is done due to its low cost, simplicity of use, lower rate of post procedural complications [13].

Besides widespread use of endoscopic practices, certain pharmacological agents are also needed to treat chronic GIT bleeding and to lessen and prevent the recurrence of bleeding. Hormonal preparations such as oral estrogenic and progesterone preparations and Tranexamic acid have been demonstrated to lessen the necessity of transfusion and reduce the chance of GI bleeding after giving the patients Bevacizumab, an anti-angiogenic medication [15]. Other medications such as Octreotide have been used effectively to manage the active bleeding in GIT [10]. Certain drugs like Thalidomide, Danazol, Recombinant coagulation factors have also been used in a very limited scale and are under active study [10].

### **Conclusion:**

Given to minimal data is available till date on gastric AVM, To determine most efficacious approach to treat AVM, classifying endoscopic findings could be a very useful. This fact demands further reporting of AVM to gather possible diverse findings and outcome of gastric AVM. In conclusion, herein we presented a case of rare gastric arteriovenous malformation which is uncommon in practice and needs a proper guideline to treat on the basis of extensivity.

### **Reference**

1. Tasnádi G: Epidemiology and etiology of congenital vascular malformations. *Semin Vasc Surg.* 1993, 6:200–3.
2. Gawecki F, Strangeways T, Amin A, et al.: Exercise capacity reflects airflow limitation rather than hypoxaemia in patients with pulmonary arteriovenous malformations. *QJM.* 2019, 112:335–42. 10.1093/qjmed/hcz023
3. Miyasako Y, Kuwai T, Ishaq S: Case of a small intestinal arteriovenous malformation diagnosed by double-balloon enteroscopy preoperatively. *Dig Endosc.* 2019, 31:e68–9. 10.1111/den.13357

4. Cohen MM: Vasculogenesis, angiogenesis, hemangiomas, and vascular malformations. *Am J Med Genet.* 2002, 108:265–74. 10.1002/ajmg.10260
5. Ng SC, Thomas-Gibson S, Harbin LJ, Gupta A, Gould SWT, Jacyna M: Gastric arteriovenous malformation: a rare cause of upper GI bleed. *Gastrointestinal Endoscopy.* 2009, 69:155–6. 10.1016/j.gie.2008.07.013
6. Moretó M, Figa M, Ojembarrena E, Zaballa M: Vascular malformations of the stomach and duodenum: an endoscopic classification. *Endoscopy.* 1986, 18:227–9. 10.1055/s-2007-1018385
7. Cotter, J., Baldaia, C., Ferreira, M., Macedo, G., & Pedroto, I. (2020). Diagnosis and treatment of iron-deficiency anemia in gastrointestinal bleeding: A systematic review. *World Journal Of Gastroenterology*, 26(45), 7242-7257. doi: 10.3748/wjg.v26.i45.7242
8. Serefhanoglu, S., Buyukasik, Y., Emmungil, H., Sayinalp, N., Haznedaroglu, I., & Goker, H. et al. (2011). Identification of clinical and simple laboratory variables predicting responsible gastrointestinal lesions in patients with iron deficiency anemia. *International Journal Of Medical Sciences*, 8(1), 30-38. doi: 10.7150/ijms.8.30
9. Park, Y., Lee, J., Cho, B., Min, W., Cheung, D., & Kim, J. et al. (2009). Incidence and Etiology of Overt Gastrointestinal Bleeding in Adult Patients with Aplastic Anemia. *Digestive Diseases And Sciences*, 55(1), 73-81. doi: 10.1007/s10620-008-0702-3
10. Fujii, T., Morita, H., Sutoh, T., Takada, T., Tsutsumi, S., & Kuwano, H. (2014). Arteriovenous Malformation Detected by Small Bowel Endoscopy. *Case Reports In Gastroenterology*, 8(3), 324-328. doi: 10.1159/000367591
11. Lee, J., Hwang, S., Kim, J., Kang, J., Kang, G., & Park, K. et al. (2016). Multiple Polypoid Angiodysplasia with Obscure Overt Bleeding. *Clinical Endoscopy*, 49(1), 91-96. doi: 10.5946/ce.2016.49.1.91
12. Chiu, Y., Lu, L., Wu, K., Tam, W., Hu, M., & Tai, W. et al. (2012). Comparison of argon plasma coagulation in management of upper gastrointestinal angiodysplasia and gastric antral vascular ectasia hemorrhage. *BMC Gastroenterology*, 12(1). doi: 10.1186/1471-230x-12-67
13. Kathi, P., Tama, M., Kundumadam, S., Gulati, D., & Ehrinpreis, M. (2018). Esophageal arteriovenous malformation, a rare cause of significant upper gastrointestinal bleeding: Case report and review of literature. *Intractable & Rare Diseases Research*, 7(3), 196-199. doi: 10.5582/irdr.2018.01068
14. Park, Y., Lee, J., Cho, B., Min, W., Cheung, D., & Kim, J. et al. (2009). Incidence and Etiology of Overt Gastrointestinal Bleeding in Adult Patients with Aplastic Anemia. *Digestive Diseases And Sciences*, 55(1), 73-81. doi: 10.1007/s10620-008-0702-3

15. Tortora, A., Riccioni, M., Gaetani, E., Ojetti, V., Holleran, G., & Gasbarrini, A. (2019). Rendu-Osler-Weber disease: a gastroenterologist's perspective. *Orphanet Journal Of Rare Diseases*, 14(1). doi: 10.1186/s13023-019-1107-4

UNDER PEER REVIEW