

### Actinomycetoma: An unusual case and literature review

#### ABSTRACT

In the current era of modern medicine, neglected tropical disorders though rare, still remain a cause of significant morbidity in the sufferers. Actinomycetoma is one such disease commonly seen in the rural population of the tropical countries. Due to the presence of other infectious diseases with similar presentation and low yield on cultures, there may be a delay in correct diagnosis and treatment in resource poor settings. We present a 35 year old male patient who came with complaints of raised lesions over his neck. He had been treated with antitubercular drugs for the same, despite which the lesions had persisted. Based on clues from histopathological and clinical features, we diagnosed him with Actinomycetoma. He was started on the welsch regimen and he showed excellent response. This case becomes a rare vignette due to the uncommon site of presentation of mycetoma.

**Conclusion:** Neglected tropical diseases are not to be neglected. Relevant investigations have to be done to rule out their possibility, especially in tropical countries where they are still a burden.

*Keywords: Mycetoma, Actinomyetoma, Nocardia, Neglected tropical diseases.*

#### 1. INTRODUCTION

Mycetoma, translating to fungal **tumor** in Greek is a chronic granulomatous infection of the dermis and subcutaneous tissue, rarely extending to the muscles and bone.<sup>1</sup>

The description of this disease dates back to ancient times and it was Dr John Gill who first described this entity as **maduro** foot in "the Indian army medical reports", 1842.<sup>2</sup>

Mycetoma is endemic in the tropical and subtropical countries.

It can present in two forms: -Actinomycetoma which is caused by bacteria, predominant in the and central America and Eumycetoma caused by fungi, which is more common in Africa.<sup>3</sup>

Adult males in the 3rd - 5th decades are commonly affected, especially those involved in agriculture or farming activities, as these organisms are commonly found in the soil from where direct inoculation can occur.<sup>4</sup>

The foot is the most common site affected, followed by the hands, trunk and scalp.<sup>5</sup>

Painless swelling, discharging sinuses and presence of granules comprise the triad characteristic of mycetoma.<sup>5</sup>

Mycetoma involving the head and neck region is a rare occurrence with previous studies quoting incidences ranging between 0.9 to 3%.<sup>6,7</sup>

Herein, we report a case of Gill's fungal tumor presenting at a very rare site- the Neck.

## **2. PRESENTATION OF CASE**

A 35 year old male patient, hailing from Chikmagalur, South India presented to us with complaints of multiple raised lesions over the back of his neck since 3 years.

The lesions were painless, but were associated with discharging sinuses. These lesions had initially been diagnosed as acne keloidal is nuchae treated by a dermatologist and treated for the same. However, the lesions did not improve.

Simultaneously, He suffered a significant weight loss of about 25 kgs over a period of one and a half years, which was accompanied by fever with evening rise of temperature and localized swelling over the neck.

He was suspected to have cutaneous tuberculosis and an MRI was done after consultation with a neurologist.

The MRI revealed an infiltrative process, osteomyelitis and a small right occipital lobe abscess.

Patient was then started on anti- tubercular drugs, which he had consumed for about 18 months, despite which the had lesions persisted.

The patient was a known diabetic on medications since 4 years and had been disabled by polio when he was young.

He does not give any history of trauma to the neck prior to the onset the lesions.

On clinical examination, a diffuse boggy swelling was noted over the nape of the neck with multiple skin colored firm papules and nodules with few active sinuses overlying it. There were few areas of scar tissue and puckering noted as well.(fig1a and 1b).

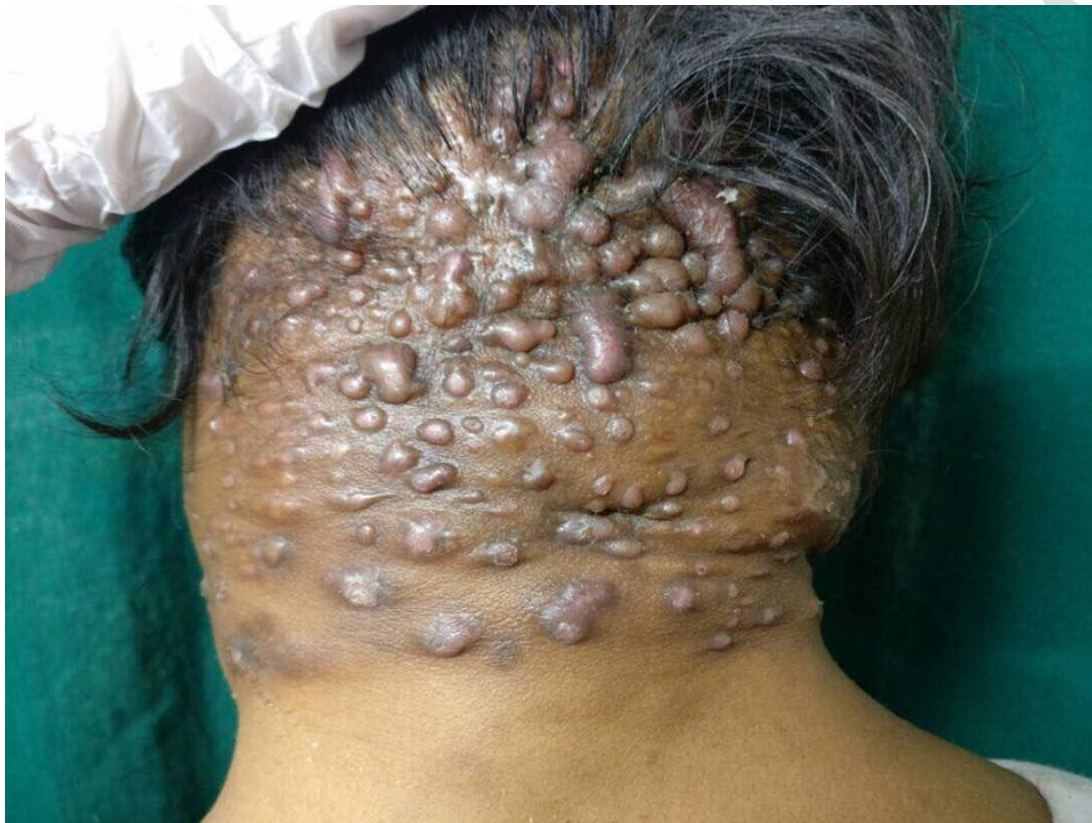

Fig 1a -showing multiple skin colored papules and nodules over the nape of the neck

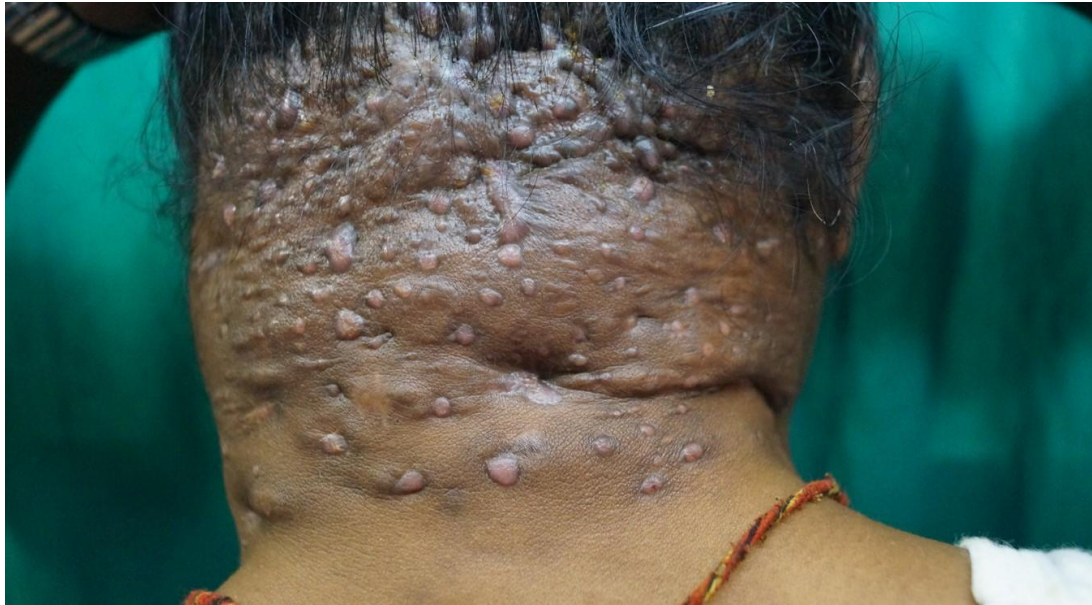

Fig 1b- papules and nodules with areas of puckering noted over the posterior aspect of neck

Preliminary blood investigations showed anemia and a raised ESR. Koh mount and swab for culture were sent, which did not yield any diagnostic clues.

Further, skin biopsy was done which showed the presence of large grains in the dermis with the classical eosinophilic radiating spicules- the Splendored Hoeffli phenomenon. (fig 2a and 2b)

The colonies were seen to be surrounded by histiocytes, occasional multinucleated giant cells and dense suppurative inflammation forming granuloma.(fig 3)

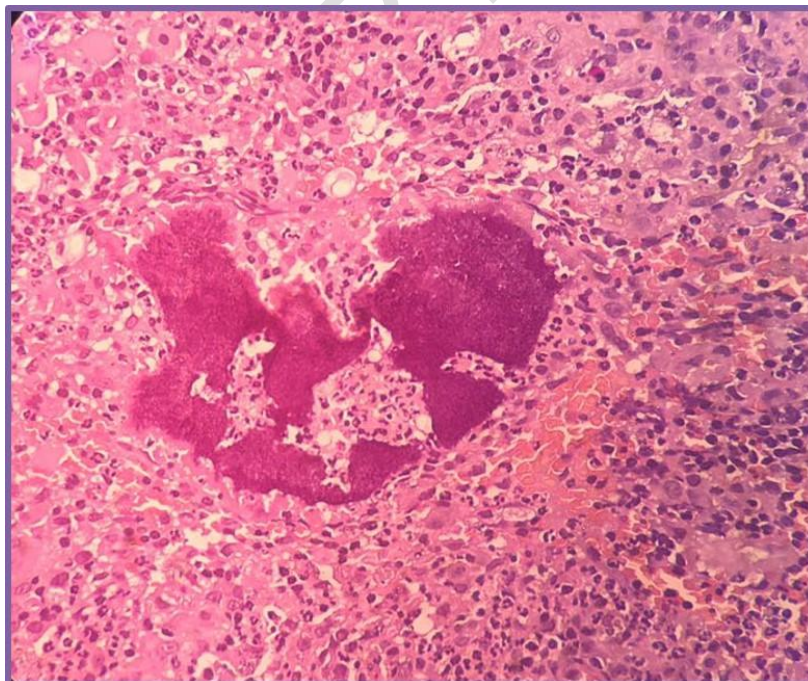


Fig 2a – histopathological examination showing large grains in the dermis with the

classical eosinophilic radiating spicules- the Splendored Hoeppli, in turn surrounded by inflammatory cells forming a granuloma

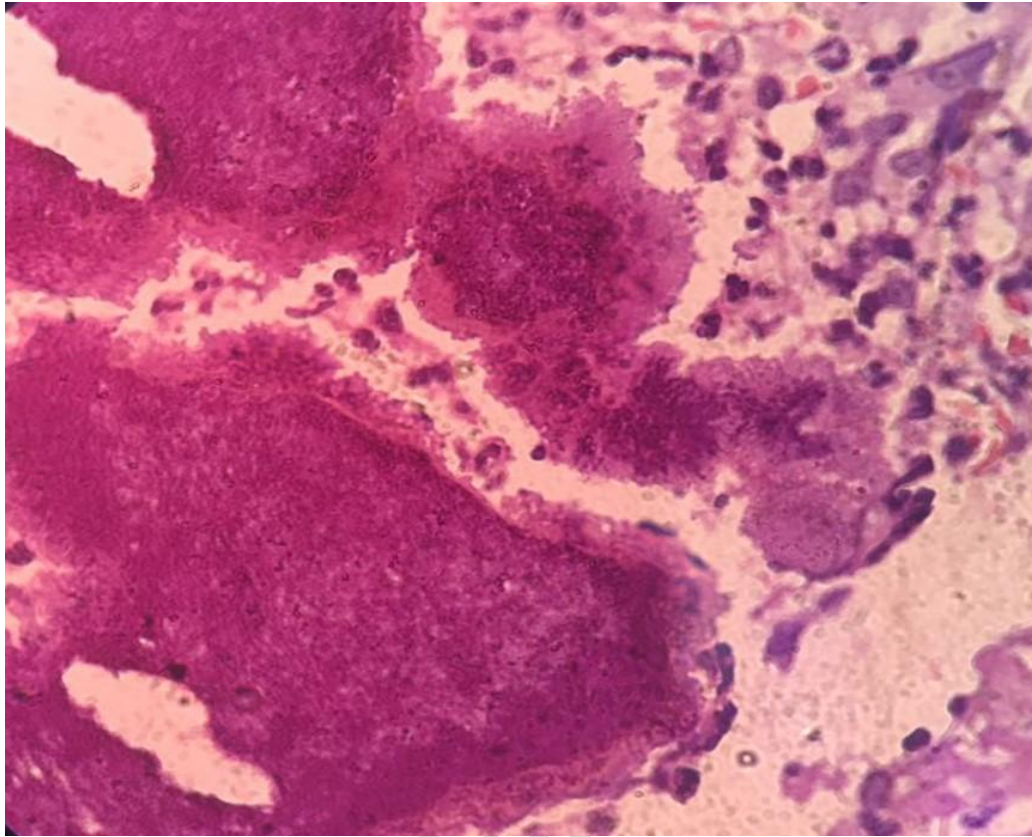


Fig 2b- zoomed in view of the Splendored Hoeppli phenomenon

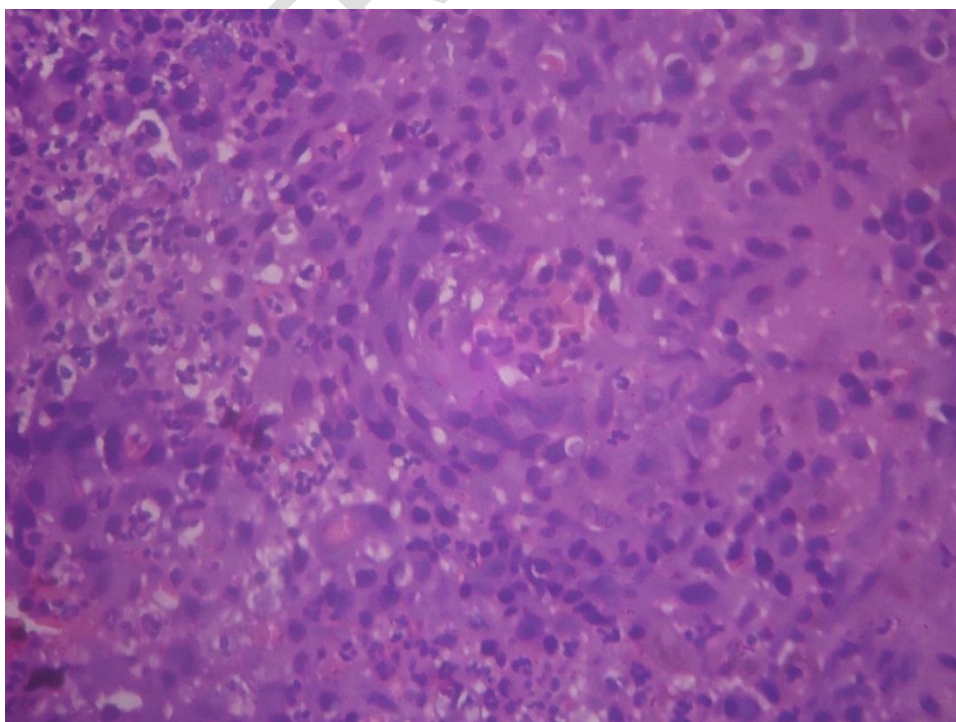
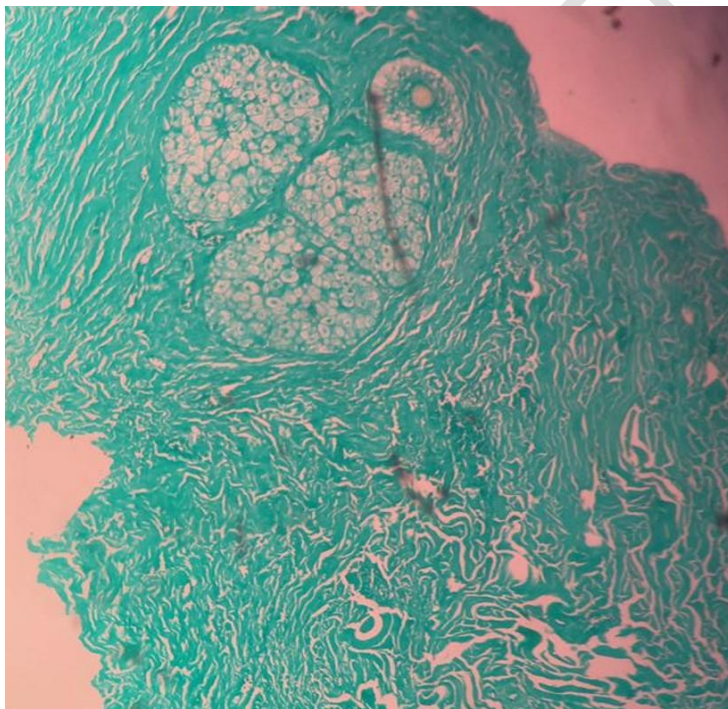


Fig 3 – histopathological examination showing Histiocytes and multinucleated giant cells which comprise the granuloma.

Gram stain, Gomori methenamine silver stain(fig 4) and Periodic acid stiff stain were negative.

Fig 4 – Gomori methenamine silver stain- negative for fungal elements



Based on the clinical features, site of the lesions and the classical histopathological finding of the Splendored Hoeppli phenomenon we diagnosed this case as Actinomycetoma.

Mycetoma over the extra pedal sites like neck, trunk and abdomen are known to be caused by Nocardia<sup>6</sup> and hence, we concluded it to be actinomycotic mycetoma caused by the Nocardia species.

Patient was treated with the Welsh regimen consisting of 3 cycles of Injection Amikacin 250 mg Q12h for 2 weeks with an interval of 2 weeks between each cycle and oral Trimethoprim Sulphamethoxazole for about a year.

He showed excellent improvement with resolution of lesions (fig 5a and 5b) and is currently doing well without any recurrence.

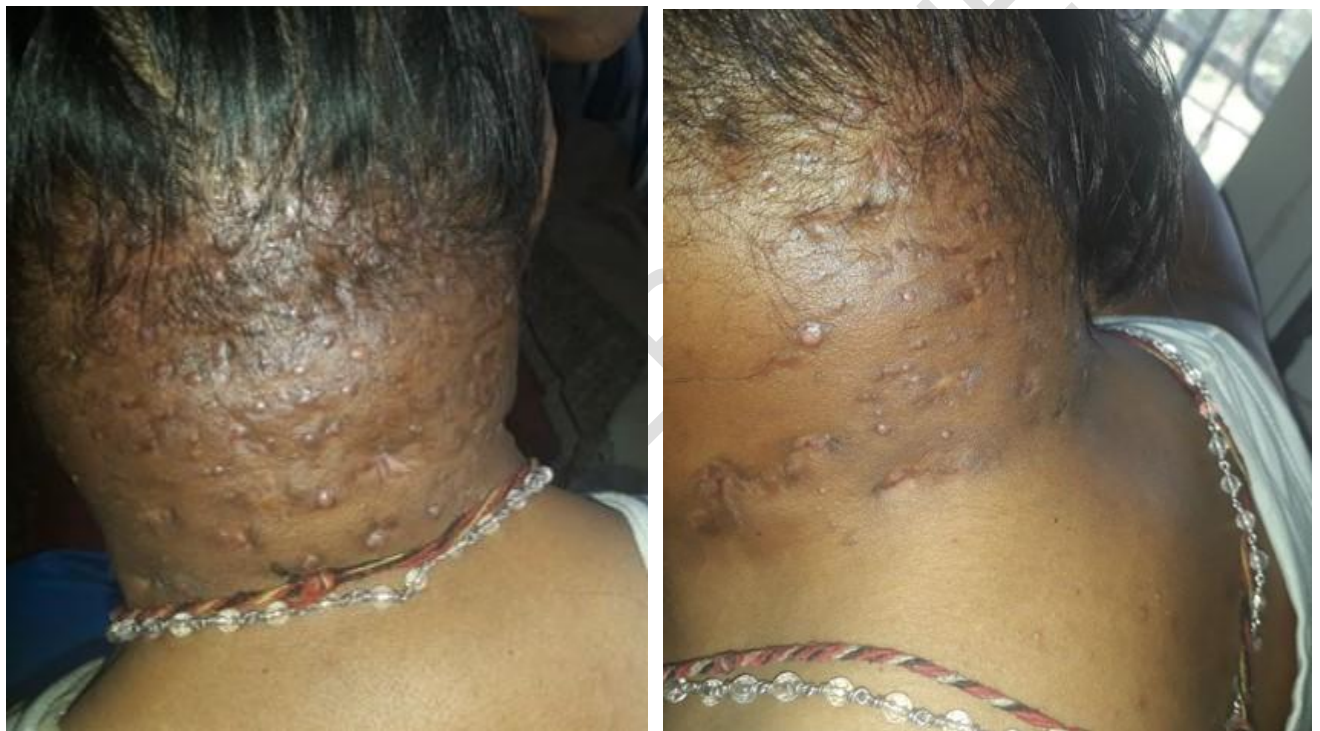

Fig 5a and 5b showing resolution of lesions

### 3.DISCUSSION

The advent of modern medicine has paved way for a reduction in the burden of infectious diseases. However, In countries like India Tropical diseases are still a cause of significant morbidity.

Mycetoma is one among these neglected tropical diseases. It is more common in the mycetoma belt region lying between 15°S and 30°N of the equator. Sudan is

considered as the hotspot for mycetoma and India also has a prevalence higher than average.<sup>6</sup>

As the name maduro foot suggests, extremities are the commonest sites involved and incidence of mycetoma of the neck region is rare as evidenced by the very few reports in medical literature.

Lynch in 1964, reported on 1860 mycetoma patients and of these only 18 patients (0.96%) had head and neck mycetoma. Mahgoub in 1977 reported an incidence of 3% of head and neck mycetoma. In 1986, Gumaa and her associates reported 15 out of 400 patients with mycetoma (3.75%) involving the head and neck region.<sup>6,8,7</sup>

Poor hygiene, low socioeconomic conditions, insufficient nutrition comprise the risk factors for the disease.

The painless nature of the disease delays the diagnosis worsening the quality of life of the patients.<sup>5</sup>

History of Trauma is an important predisposing factor, but was absent in this case. A study conducted at the Mycetoma research centre reported a prior history of trauma only in about 28 percent of the cases.<sup>9</sup>

Actinomycetoma is caused by filamentous bacteria, they can be anaerobic agents like *Actinomyces israelii* or by aerobic agents like *Nocardia brasiliensis*, *N. asteroides*, *Actinomadura madurae*, *A. pelletieri*. *Nocardia brasiliensis* is found to be the commonest causative agent and is also implicated in extra pedal mycetoma.<sup>4,6</sup>

After the inoculation of the organism, papules and nodules can form at the site and infection results. Deeper spread of the infection can involve the subcutaneous tissue which is manifested by swelling and eventual formation of purulent draining sinuses.

The exudate is composed of the characteristic grains, representing clusters of bacterial and fungal structures called "grains" or druses.<sup>1,5</sup>

Mycological and bacterial examination are crucial for the diagnosis, as treatment varies based on the type of mycetoma.

Specimen for examination of grains can be collected by scraping the walls of the sinuses, sampling a tissue biopsy, overnight application of saline dressings over the swelling and aspiration of grains from an unopened sinus tract.<sup>10</sup>

The grains extracted are subject to direct clinical examination, microscopy and culture to make a definitive diagnosis.

Gram staining shows gram positive filamentous bacteria.

On histopathological examination suppurative granulomas are noted surrounding the characteristic grains- composed of neutrophilic infiltrate, surrounded by palisading histiocytes and a mixed inflammatory infiltrate comprising lymphocytes, plasma cells, eosinophils, and macrophages.<sup>10</sup>

In actinomycetoma- aggregates of septate and branched, radially arranged broad, pink filaments are seen, these filaments are involved in forming antigen-antibody complexes giving rise to an eosinophilic fringe which comprises the **splendored Hoeppli** phenomenon and is a classical sign.<sup>4</sup>

Deep fungal infections are notorious for their low culture yields. Culture and staining methods did not yield any diagnostic clues in our patient.

However, the grains with **splendored Hoeppli** phenomenon were noted.

Treatment of mycetoma is difficult but Actinomycetoma is the lesser evil. Treatment with multiple agents is preferred to prevent resistance.

Drugs like Cotrimoxazole, Dapsone, Streptomycin, Trimethoprim (TMP), Rifampicin, and Amoxicillin-Clavulanic acid combination have been found to be effective.

Injection Amikacin in combination with TMP-SMX called as the Welsh regimen, shows excellent cure rate and has been used successfully in many of our previous patients.<sup>11</sup>

The regimen comprises cyclical dosing of amikacin 15 mg/kg/day, in two divided doses in cycles of 21 days for 1–3 cycles with intervals of 15 days between cycles combined with Cotrimoxazole.<sup>10</sup>

This was the regimen used in our patient and it resulted in complete resolution.

#### **4. CONCLUSION**

This rare case of Actinomycetoma over neck giving a lumpy, bumpy, oozy scary scary appearance emphasizes the need for high index of suspicion of mycetoma, one of the neglected tropical diseases when patients present with lumps and discharging sinuses irrespective of site and especially in a tropical country.

However, it is important to keep in mind other infections which can manifest with similar features, therefore, thorough investigation is key.

This case also stands as evidence for the notoriously low yield of growth of mycetoma causing organisms on culture.

This patient had been disabled by polio, another debilitating tropical disease and hence this draws attention to the fact that tropical diseases though rare are still prevalent and are still a cause of reduced quality of life in people living in these countries.

#### **CONSENT**

"All authors declare that 'written informed consent was obtained from the patient for publication of this case report and accompanying images.'"

#### **REFERENCES**

- 1) Gupta S, Jain K, Parmar C, Shah P, Raval RC. Mycetoma: Nonvenereal perineal lesions. *Indian J Sex Transm Dis AIDS*. 2010 Jan;31(1):39-41
- 2) R J Hay, Mycetoma – a history of the first contributions to the description of the disease and its pathogenesis. *Trans R Soc Trop Med Hyg*. 2021 April;115: 283–86

- 3) VandeSande WW. Global Burden of Human Mycetoma: A Systematic Review and Meta-analysis. *PLoS Negl Trop Dis*. 2013;7:e2550
- 4) Reis CMS, Reis-Filho EG de M. Mycetomas: An epidemiological, etiological, clinical, laboratory and therapeutic review. Vol. 93, *Anais Brasileiros de Dermatologia. Sociedade Brasileira de Dermatologia*; 2018. p. 8–18.
- 5) Fahal AH. Mycetoma: A thorn in the flesh. *Trans R Soc Trop Med Hyg*. 2004;98:3–11.
- 6) Lynch JB (1964) Mycetoma in the Sudan. *Ann R Coll Surg Engl* 35: 319–340.
- 7) Gumaa SA, Mahgoub ES, el Sid MA (1986) Mycetoma of the head and neck. *Am J Trop Med Hyg* 35: 594–600. Lichon V, Khachemoune A. Mycetoma: a review. *Am J Clin Dermatol*. 2006;7:315–321.
- 8) Mahgoub ES (1977) Mycoses of the Sudan. *Trans R Soc Trop Med Hyg* 71: 184–188.
- 9) Fahal A, Mahgoub ES, EL Hassan AM, Jacoub AO, Hassan D. Head and neck mycetoma: the mycetoma research centre experience. *PLoS neglected tropical diseases*. 2015 Mar 13;9(3):e0003587.
- 10) Relhan V, Mahajan K, Agarwal P, Garg VK. Mycetoma: An Update. *Indian J Dermatol*. 2017;62(4):332-340
- 11) Bhat RM, Monteiro RC, Bala N, Dandakeri S, Martis J, Kamath GH, Kambil SM, Asha Vadakayil R. Subcutaneous mycoses in coastal Karnataka in south India. *Int J Dermatol*. 2016 Jan;55(1):70-8.

UNDER PEER REVIEW