

Case report

A CASE REPORT ON BECKWITH WIEDEMANN SYNDROME

Abstract:

Introduction:

Beckwith Wiedemann syndrome (BWS) is a congenital disorder that involves a somatic overgrowth during the patient's first years of life and associated with visceromegaly, macroglossia, abdominal wall defects, pre and postnatal overgrowth, and neonatal hypoglycemia.

Case report:

This is a case report of a 14-year-old male patient who presented with macroglossia and Wilm's Tumor. Diagnosis was made after karyotyping, which showed an abnormality in chromosome 11p15 and dental treatment was done

Conclusion:

Pediatric dentists should be aware of Beckwith Wiedemann Syndrome and its oral manifestations as they can encounter this condition in their clinical practice

Key Words: Beckwith Wiedemann syndrome, Macroglossia, Wilm's tumour

Introduction:

“Beckwith Wiedemann syndrome (BWS) is a congenital overgrowth disorder affecting ~1 in 10,340 live birth”[1]. “It is associated with wide range of clinical features which include visceromegaly, macroglossia, abdominal wall defects, pre, postnatal overgrowth, neonatal hypoglycemia and an increased risk for developing embryonal tumors during early childhood. Exophthalmos, macroglossia, and gigantism, are considered the characteristic diagnostic triad of findings, due to which it is also known as EMG syndrome”[2-6]. “It is caused due to an alteration in the 11p15.5 imprinted gene cluster, with a specific role being played by the reduced expression or inactivation of the maternally expressed growth suppressor cyclin-dependent kinase inhibitor 1C and the increased expression of the paternally expressed growth promoter insulin like growth factor type 2”[7,8]. “Most of the cases are sporadic (85%) while a small portion display familial inheritance (15%)”[1].

“Other marked features include earlobe creases and pits, facial nevus flammeus, and prominent eyes with infraorbital creases, craniofacial abnormalities of maxillary hypoplasia and a prominence of the occiput”[2-

6]. “Furthermore, the presence of hypotonia, including in the orofacial muscles, followed by early tooth eruption and cleft palate is frequently seen” [9]. “For unknown reasons, these patients have an increased incidence of Wilm's Tumor, adrenal carcinoma, or hepatoblastoma” [2-6].

Here in this article we present a case report of a 14 year old with BWS highlighting the clinical features and diagnosis of the condition along with treatment strategies followed.

Case Report:

A 14-year-old male patient reported to the Department of Pedodontics, Yenepoya Dental College, Mangalore with the chief complaint of decayed teeth, which were asymptomatic. The medical history revealed that he was a full term baby with a birth weight of 4.400 kg. Parents reported that he was a “very large baby with a very small head”. A hard swelling was seen on the right side of the abdomen and **micturition was initially obstructed**. The swelling had increased with age, which was operated **at 9 months** of age and diagnosed as Wilm’s Tumor. Karyotyping of blood for chromosomal abnormalities revealed an abnormality in the short arm of chromosome 11p15, which was thus diagnosed as Beckwith Wiedemann syndrome.

Patient was hypotensive (100/60 mm of Hg) prior to the surgery and was under medication. The patient had undergone 36 doses of chemotherapy. On general examination it was seen that the patient was **hemihypertropic on the right side of the face** [Figure 1]. Speech was blurred and an incisional scar

was present on the lower right side of the abdomen. Built and gait was normal.

At 8 years, patient had an injury to the eyes and encountered total blindness in the right eye.

Extra oral examination revealed asymmetry of face, linear indentation of the ear [Figure 2], right eyes was smaller than the left and lower lips were everted.

Intraoral examination revealed the presence of all the permanent teeth except lower left premolars (34; 35). Ellis class VIII fracture of the maxillary central incisors (11; 21), macroglossia [Figure 3] and a bony swelling in the region of lower left premolars (34; 35) were also noted.

Investigations included blood test to rule out hypoglycemia and an orthopantomograph (O.P.G.) which revealed erupting, lower left premolars.

Dental treatment included endodontic procedures for 11,21 after which crown replacement was done [Figure 4].

Discussion:

“Beckwith Wiedemann Syndrome (BWS), originally termed EMG syndrome was first described by Beckwith and Wiedemann in 1963 and 1964 respectively. Beckwith first described this in three postmortem cases involving, extreme cytomegaly of adrenal fetal cortex, omphalocele and Leydig cell hyperplasia. Later on, Wiedemann described this condition with similar symptoms as well as umbilical hernia and macroglossia”[10,11].

BWS is one of the most common congenital overgrowth disorder with multiple clinical manifestations. Since there is an underestimation of exact prevalence and severity of this disease due to variability in the mode of inheritance and clinical manifestation ,an international consensus statement in the study by Brioude et al[2] recommended “using a scoring system to aid in the diagnosis of these patients. The scoring system is based on the cardinal and suggestive features. Cardinal features are those that when present are strongly suggestive of BWS; thus, two points are assigned for each feature. These include macroglossia, omphalocele, lateralized overgrowth, hyperinsulinism, bilateral Wilms tumors, and specific pathological findings such as placental mesenchymal dysplasia or adrenal cytomegaly” [2]. “In comparison, suggestive features are those characterized as being independent of the general pediatric population, such as birth weight greater than two standard deviations above the mean, ear creases or

pits, polyhydramnios or placentomegaly, facial nevus simplex, transient hypoglycemia, nephromegaly or hepatomegaly, embryonal tumors, and umbilical hernia or diastasis recti. Each of these features was assigned one point. Based on this scoring scheme, a patient with a score of ≥ 4 satisfied the clinical diagnosis of classical BWS"[2].

In this case, the karyotyping of blood for chromosomal abnormalities revealed abnormality in the short arm of chromosome 11p15 thus diagnosing the condition as Beckwith Wiedemann syndrome.

Affected children are often large at birth. Many have an abdominal wall defect, such as an umbilical hernia or omphalocele. They have a characteristic facial appearance with a gaping mouth and large tongue.

"The most common manifestation of Beckwith-Wiedemann Syndrome is true macroglossia secondary to enlargement of tongue musculature, reported in nearly 90% of the cases"[2,12]. "The degree of macroglossia varies with each patient. The enlargement is generalized and may cause a variety of difficulties such as speech anomalies, feeding and swallowing problems, airway obstruction, malocclusion, drooling and recurrent lingual trauma . The macroglossia is most prominent in infants but tongue size may remain above normal in childhood and adolescence. As the hyoid descends with age, the macroglossia may improve. Histologic examination shows hypertrophy and hyperplasia of muscle cells"[13-15]. "Partial glossectomy is

indicated when enlarged tongue is a risk to airway, interferes with feeding or affects development of the child” [16].

“Overall, intelligence is usually normal, although BWS has previously been reported in association with mild to moderate mental deficiency due to hypoglycemic episodes or to subtle cytogenetic alterations”. [17]

Patients often present with signs like hypoglycemia, enlarged kidneys, liver, and spleen, large fontanelle (enlarged soft spot), metopic ridge (a ridge in the forehead caused by premature closure of the cranial suture just forward of anterior fontanelle), early bone maturation and asymmetric overgrowth or hemi hypertrophy

Complications include seizures, respiratory difficulties from obstruction due to large tongue, feeding problems, neoplasms and tumors

“A significant complication of BWS is the increased risk of childhood tumor development. It is a cancer predisposition syndrome with an overall tumour risk of about 8%, including Wilm’s tumor are seen in 7.5% of patients” [1].

Monitoring should continue up to 12 years of age, or even up to adolescence

In the present case, the patient had undergone 36 doses of chemotherapy. One of the most frequent complications of antineoplastic chemotherapy is the formation of oral lesions due to high sensitivity of oral tissues to the toxic effects of chemotherapeutic agents. The most prevalent oral problems in

children and adolescents undergoing chemotherapy include mucositis, xerostomia, rampant caries, opportunistic oral infections and changes in the formation of dental germs in cases of treatment during the phases of the odontogenesis stages[18].

Current guidelines recommend that children need to have an oral examination before initiating cancer therapy [19]. As a dentist it is important to educate both parent and patient about the importance of thorough precancer therapy dental evaluation, maintenance of good oral hygiene and the benefits of preventive oral care like fluoride application to avoid oral problems during and after chemotherapy.

Conclusion:

BWS is considered one of the most common congenital overgrowth disorder with diverse oral and clinical manifestations. Hence, pediatric dentists should be aware of this condition as they can encounter such cases in their clinical practice.

Ethical Approval:

As per international standard or university standard written ethical approval has been collected and preserved by the author(s).

Consent

As per international standard, parental written consent has been collected and preserved by the author(s).

FIGURES AND LEGENDS

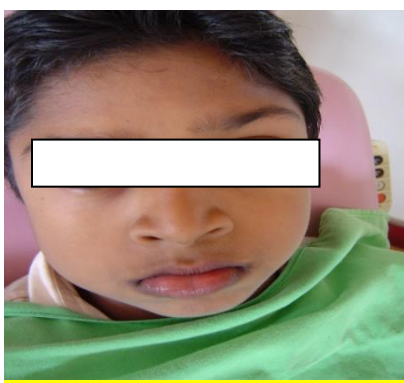

Figure 1

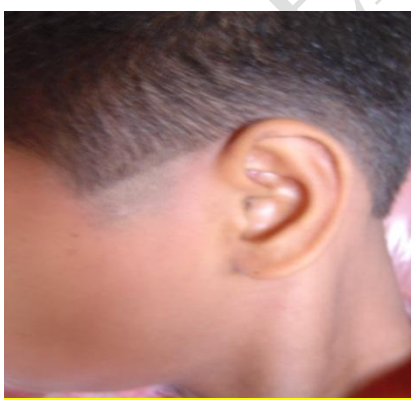

Figure 2

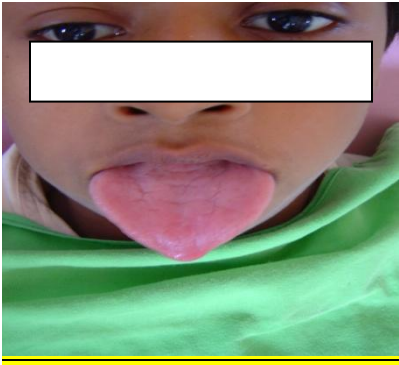


Figure 3

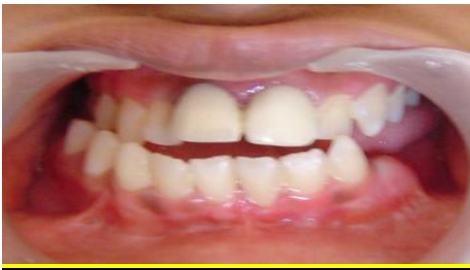

Figure 4

Figure 1: Hemihypertrophy of the right side of face

Figure 2: Linear indentation of the ear

Figure 3: Macroglossia

Figure 4: Crown replacement

References

1. Wang KH, Kupa J, Duffy KA, Kalish JM. Diagnosis and management of Beckwith-Wiedemann syndrome. *Frontiers in pediatrics*. 2020:562.
2. Brioude F, Kalish JM, Mussa A, Foster AC, Bliet J, Ferrero GB, Boonen SE, Cole T, Baker R, Bertolotti M, Cocchi G. Clinical and molecular diagnosis, screening and management of Beckwith–Wiedemann syndrome: an international consensus statement. *Nature Reviews Endocrinology*. 2018 Apr;14(4):229-49.
3. Elliott M, Bayly R, Cole T, Temple IK, Maher ER. Clinical features and natural history of Beckwith-Wiedemann syndrome: presentation of 74 new cases. *Clinical genetics*. 1994 Aug;46(2):168-74.
4. Engström W, Lindham S, Schofield P. Wiedemann-beckwith syndrome. *European journal of pediatrics*. 1988 Jun;147(5):450-7.

5. McManamny DS, Barnett JS. Macroglossia as a presentation of the Beckwith-Wiedemann syndrome. *Plastic and reconstructive surgery*. 1985 Feb 1;75(2):170-6.
6. Weng EY, Mortier GR, Graham Jr JM. Beckwith-Wiedemann syndrome: An update and review for the primary pediatrician. *Clinical pediatrics*. 1995 Jun;34(6):317-26.
7. Lim D, Bowdin SC, Tee L, et al. Clinical and molecular genetic features of Beckwith-Wiedemann syndrome associated with assisted reproductive technologies. *Hum Reprod* 2009;24(3):741-747.
8. Cooper WN, Luharia A, Evans GA, et al. Molecular subtypes and phenotypic expression of Beckwith-Wiedemann syndrome. *Eur J Hum Genet* 2005;13(9):1025-1032.
9. Lapunzina Badía P, del Campo Casanelles M, Delicado Navarro A, et al. Clinical guide to the management of patients with Beckwith- Wiedemann syndrome. *An Pediatr (Barc)* 2006;64(3):252-259
10. Beckwith JB. Extreme cytomegaly of the adrenal fetal cortex, omphalocele, hyperplasia of kidneys and pancreas, and Leydig-cell hyperplasia: another syndrome? Abstract presented at: 11th Annual Meeting of the Western Society for Pediatric Research; November 11- 12, 1963; Los Angeles, Calif.

11. Wiedemann HR. Familial malformation complex with umbilical hernia and macroglossia: a “new syndrome”? (in French). *J Genet Hum* 1964;13:223-232
12. Beckwith JB. Macroglossia, Omphalocele, adrenal cytomegaly, gigantism and hyperplastic visceromegaly. *Birth Defects*, 1969; 5: 188-196
13. M Therese Garvey, Dympna Daly, Triona McNamara. Beckwith Weidmann Syndrome: dental management. *Int Journal of Paediatric Dent*, 1997; 7:95-99
14. Cielo CM, Duffy KA, Taylor JA, Marcus CL, Kalish JM. Obstructive sleep apnea in children with Beckwith-Wiedemann syndrome. *J Clin Sleep Med*. 2019;15(3):375–381. Published 2019 Mar 15. doi:10.5664/jcsm.7656
15. Cohen JL, Cielo CM, Kupa J, et al. The utility of early tongue reduction surgery for macroglossia in Beckwith-Wiedemann syndrome. *Plast Reconstr Surg*. 2020;145(4):803e–813e. doi:10.1097/PRS.0000000000006673
16. Aldo Giancotti, Gaia Romanini, Raffaella Docimo, Claudio Arcuri. Clinical treatment of oral manifestations of Beckwith-Wiedemann syndrome in a child. *J Clin Paediatr Dent*, 2003; 4:377-380.
17. Gazzin A, Carli D, Sirchia F, Molinatto C, Cardaropoli S, Palumbo G, Zampino G, Ferrero GB, Mussa A. Phenotype evolution and health issues of

adults with Beckwith-Wiedemann syndrome. American Journal of Medical Genetics Part A. 2019 Sep;179(9):1691-702.

18. Santos TFR, Coradini CDB, et al. Knowledge and practice of oral health in child patients with cancer. Arquivos em Odontologia 2010;46(1):5–10.

19. Guideline on dental management of pediatric patients receiving chemotherapy, hematopoietic cell transplantation, and/or radiation therapy. Pediatr Dent. 2016 Oct;38(6):334-342

UNDER PEER REVIEW