

Immunophenotyping of cytologic Specimens by Flow Cytometry in Patients with or without Prior Hematologic Malignancy

Abstract

Introduction: Cytopathologists are frequently confronted with lymphocyte-rich effusions, and definite decision of reactive lymphocytosis or indolent lymphoma may be extremely difficult based on microscopy alone, where small proportions of malignant cells can be detected by flow cytometry. The study aimed to confirm the diagnosis of leukemia or lymphoma in body fluids and **fine needle aspirate (FNA)** specimens using multiparametric flow cytometry (MFC) immunophenotyping, which is a powerful tool for detecting hematologic malignancies.

Methods: Body fluids and FNA specimens simultaneously obtained for MFC, cytologic analysis and Real time PCR from 30 patients were submitted to flow cytometry laboratory from January 2017 to September 2019. The samples were 16 body fluids (11 pleural fluids; 5 ascetic fluids) and 14 FNA samples (13 lymph nodes; 1 lung mass). A panel of fluorochrome monoclonal antibodies against lymphoma and leukemia markers were used. The cases were diagnosed as leukemia or lymphoma according to the revised WHO classification of tumors of hematopoietic and lymphoid tissues(2016) guideline.

Results: Among 30 cases, 27(90%) showed immunophenotype consistent with malignancy. *Mycobacterium tuberculosis* DNA was positive in 3(10%) cases. Pleural fluid (n=11) samples were positive for 4 diffuse large B-cell lymphoma (DLBCL), 4 angioimmunoblastic T-cell lymphoma (AITL), 1 T-lymphoblastic lymphoma (T-LbLy), 1 thymoma, 1 tuberculosis. Ascetic fluid (n=5) samples showed positivity for 4 AITL and 1 DLBCL. FNA (n=14) were positive for 2 T-LbLy, 2 AITL, 3 DLBCL, 1 Classical Hodgkin lymphoma, 1 nodular lymphocyte predominant Hodgkin lymphoma, 1 peripheral T-cell lymphoma (NOS), 1 splenic B-cell marginal zone lymphoma, 1 neuroendocrine malignancy, 2 tuberculosis. Both immunophenotype and cytomorphology positive for malignancy were in 19/30(63.33%) cases. Cytomorphology was negative/ suspicious in 11/30(36.67%) cases, of which immunophenotype positive cases were 8/30(26.67%). **Conclusion:** Multiparametric flow cytometry is invaluable

tool to diagnose hematologic malignancies in SCEs/FNA as malignant cells can be missed out by cytomorphology.

Keywords: Flow cytometry, Body fluids & FNA, Cytology, lymphoma, Leukemia

Introduction: The treatment decision of malignant lymphoma depends on precise diagnosis of serous cavity effusion (SCE) which is part of staging procedure.^{1,2} Specific categorization of subtypes of non-Hodgkin lymphoma (NHL) becomes difficult if there are any degenerative changes in some SCE specimens.³

Cytopathologists are frequently confronted with lymphocyte-rich effusions, and the definite decision of whether the lymphocytosis is of a purely reactive nature, or a presentation of an indolent lymphoma may be an extremely difficult based on microscopy alone.⁴ Moreover, small proportions of malignant cells that may be missed out by routine morphology can be detected by flow cytometry.⁵

Flow cytometry is an indispensable tool for detecting hematologic malignancies in a variety of patient specimens including body fluids and lymph node aspirates. It has been accepted that flow cytometry acts as an adjunct to cytomorphologic diagnosis for NHL in SCEs.⁶

Previous study recommends multiparameter flow cytometry (MFC) immunophenotyping as a useful tool for rapid and reliable diagnosis of pediatric non-Hodgkin lymphoma and neuroblastoma in SCE samples.³

The study aimed to confirm the diagnosis of leukemia or lymphoma in serous cavity effusions and FNA specimens using MFC immunophenotyping, which can be missed out by cytomorphology.

Methods: This retrospective study was done by obtaining data from flow cytometry and PCR laboratory of Microbiology and Immunology department of Bangabandhu Sheikh Mujib Medical University (BSMMU), where Body fluids and FNA specimens obtained from 30 patients were submitted for MFC immunophenotyping and Real time PCR from January 2017 to September 2019. There were 16 males and 14 females. The mean age of the cohort was 12 (range 1 year to 18 year). The clinical indications for MFC analysis was presence of serous cavity effusion with suspicion of malignant lymphoma by cytospin. Cytopathologic diagnosis was done by HematoOncologists. The cytospin slides were stained by Papanicolaou method. The cytopathologic diagnosis was incorporated with MFC analysis, reviewed and categorized them into benign and malignant categories. MTB Real-time PCR positivity/negativity was noted. The samples studied were 16 body fluids (11 pleural fluids and 5 ascetic fluids) and 14 fine needle aspirate (FNA) samples (13 enlarged lymph nodes and 1 lung mass). Four color MFC immunophenotyping was performed and the following fluorescent monoclonal antibodies were used: CD45, CD19, CD5, CD20, CD22, CD23, CD79b, FMC7, Kappa and Lambda light chains, CD200, CD123, CD10, CD11c, CD2, CD1a, CD3, CD5, CD7, CD4, CD8, TdT, CD52, CD25, CD30, CD40, CD56, CD95, BCL2, CD34. The antibodies were conjugated with fluorescein isothiocyanate (FITC), phycoerythrin (PE), PerCP cy5.5, and R Phycoerythrin-Texas Red-X (ECD). Using lysing solution, red blood cells were lysed after staining. After lysing, vortexing and incubating, permeabilizing solution was added and incubated in dark at room temperature. The mature lymphocyte gating strategy included using dot plots of CD45 expression versus side scattering (SSC) and CD19 versus SSC and also a second gating strategy using forward scattering. A total of 30,000 events were acquired in target gate. Any antigen marker was considered positive if 20% or more of the cells reacted with a particular antibody. MFC analysis was done on a Beckman coulter cytomics FC500 flow cytometer using software CXP to analyze data. The cases were diagnosed as leukemia or lymphoma according to the revised WHO classification of tumors of hematopoietic and lymphoid tissues(2016) guideline. Real time PCR [Anyplex MTB/MDR/XDR multiplex Real-time PCR kit; CFX96 (Bio-Rad)] was done for detecting *Mycobacterium tuberculosis* (MTB) DNA to exclude tuberculosis. This retrospective study was approved by the Institutional Review Board of Bangladesh Bioethics Society. Data was extracted from the database and anonymized. A password-protected folder was created to store the data. Proper permission was taken from the institute for this study.

Data analysis-Collected data was analyzed with Graph Pad Prism Version 8.3.0. p value < 0.05 is considered as significant.

Results: Among 30 cases 27(90%) showed immunophenotype positivity for malignancy, of which 25(83.33%) were hematologic malignancies and 2(6.67%) other malignancies. MTB DNA was positive in 3(10%) cases (Figure 1A). Pleural fluid (n=11) samples were positive for diffuse large B-cell lymphoma (DLBCL) (4 cases), angioimmunoblastic T-cell lymphoma (AITL) (4 cases), T-lymphoblastic lymphoma (T-LbLy) (1 case), thymoma(1case), tuberculosis (1 case) [Figure 1B]. Ascitic fluid (n=5) samples showed positivity for AITL (4 cases) and DLBCL (1 case) [Figure 1C]. FNA of lymph nodes (n=13) were positive for T-LbLy (2 cases), AITL (2 cases), DLBCL (3 cases), Classical Hodgkin lymphoma (CHL) (1case), nodular lymphocyte predominant Hodgkin lymphoma (NLPHL) (1 case), peripheral T-cell lymphoma, not otherwise specified [PTCL(NOS)] (1 case), splenic B-cell marginal zone lymphoma (SMZL) (1 case), tuberculosis (2 cases). One FNA of lung mass were neuroendocrine malignancy (NEM) (Figure 1D). Both immunophenotype and cytomorphology positive for malignancy were in 19/30(63.33%) cases (Table-1). Using this combined approach, out of 19 cases immunophenotypic diagnosis identified 6 DLBCL cases (2 pleural fluids, 1 ascitic fluid, 3 FNA samples); 8 AITL cases (3 pleural fluids, 3 ascitic fluids, 2 FNA samples); 2 T-LbLy (1 pleural fluid, 1 FNA sample); one PTCL(NOS), one CHL and one NLPHL in FNA samples (Table-1). Cytomorphology was negative/ suspicious in 11/30(36.67%) cases, of which both cytomorphology and immunophenotype negative were 3 cases but MTB DNA was detected in these cases 3/30 (10%). Of 3 MTB DNA positive cases, one case was detected in pleural fluid and 2 cases in FNA samples (Table-2).

Cytomorphology negative but immunophenotype positive cases were 8/30 (26.67%). In these cytomorphologically negative cases flow cytometry detected malignant cells of lymphoid origin which changed the diagnosis from negative to positive for malignancy. Of 8 cases, MFC analysis classified 2 DLBCL cases in pleural fluid; 2 AITL (1 in pleural fluid, 1 ascitic fluid); one SMZL, one T-LbLy and one NEM in FNA sample of lung mass, one thymoma in pleural fluid (Table-3).

Group 1 represents those patients who were Cytomorphology and Immunophenotype Positive for Malignancy but MTB RT-PCR Negative for Tuberculosis (n= 19). In group 2 those patients who were Cytomorphology Negative and Immunophenotype Positive for Malignancy but MTB RT-PCR Negative for Tuberculosis (n=8) and in group 3 Cytomorphology and Immunophenotype Negative for Malignancy but MTB RT-PCR Positive for Tuberculosis (n=3). Group1 was compared with group2 and group3. Also group2 was compared with group3. [Group1, group2 and group3 were compared with each other.] Which are statistically significant (pvalue =< 0.05) (Figure 2).

The immunophenotypic features of body fluids and FNA in 27 malignancy positive cases are depicted in Table 4 and examples are illustrated in Figures 3-10. Among 27 malignancy positive cases most of the cases (18/27, 66.66%) were AITL (10/27, 37.03%) and DLBCL (8/27, 29.63%). Fulfilling the diagnostic criteria, out of eight DLBCL cases identified, four cases were detected in pleural fluid, one in ascitic fluid and three in FNA. These cases showed positive expression of CD45, CD19, CD20, CD79a, CD79b, FMC7, CD22, Light chain restriction (kappa or lambda) but negative expression of CD5 and CD23. Expression of BCL2 and CD10 were variable (Table 4; Figure 3).

Among ten Angioimmunoblastic T-cell lymphoma (AITL) cases identified, four cases were detected in pleural fluid, four in ascitic fluid and two in FNA. These cases showed positive expression of CD45, CD19, CD79a, CD3, CD4, CD5, CD7, CD8, but negative expression of CD30 and CD56. Expression of BCL2 and CD10 were variable (Table 4; Figure 4).

Three T-lymphoblastic lymphoma (T-LbLy) cases (3/27, 11.11%) were identified, of which one case in pleural fluid and two in FNA of lymph node. The immunophenotypic features of these cases showed positive expression of CD45, CD1a, cytCD3, CD2, CD5, CD7, TdT but negative expression of CD52, CD56, CD30. Expression of CD4 and CD8 were variable (Table 4; Figure 6).

One splenic B-cell marginal zone lymphoma (SMZL) (1/27, 3.70%) diagnosed in FNA sample showed positive expression of CD45, CD19, CD20, CD22, CD11c, CD79b, FMC7, Light chain restriction (kappa or lambda) but negative expression of CD23, CD5, CD25, CD123 (Table 4).

Peripheral T-cell lymphoma, not otherwise specified [PTCL (NOS)] (1/27, 3.70%) identified in one FNA sample showed bright expression of CD45, CD3, CD4 and moderate expression of

CD5, CD7. Characteristic immunophenotypic features of [PTCL (NOS)] are negative expression of Perforin, Granzyme, CD30, CD56, CD8, CD19, CD79a (Table 4; Figure 7).

Classical Hodgkin lymphoma (CHL)(1/27, 3.70%) was diagnosed in one FNA sample. The gated cell population were CD45 negative which were also negative for CD19 and CD3, CD79a, CD20, CD10, CD2, CD56, BCL6. These cells showed bright expression of CD30 and moderate expression of CD40, CD15 which is diagnostic criteria for Hodgkin lymphoma (Table 4; Figure 9).

One nodular lymphocyte predominant Hodgkin lymphoma (NLPHL) {1/27, 3.70%} identified in FNA sample fulfilling the diagnostic criteria which detected bright expression of CD45 and moderate expression of CD19, CD20, CD79a, BCL6 but negative expression of CD3, CD30, CD15, CD40, CD10, CD2, CD56 (Table 4; Figure 10).

One Thymoma(1/27, 3.70%) was identified in pleural fluid depicted characteristic immunophenotypic features showing bright expression of CD45, CD3, CD5, CD7, CD4, CD8 and moderate expression of CD10, CD95. These cells showed negative expression of CD19, CD56 and CD30. These populations also showed double positive T cell (CD4+CD8+) [Table 4; Figure 8].

Neuroendocrine malignancy (NEM) was detected in one (1/27, 3.70%) FNA sample of lung mass showed CD45-/ CD56++ phenotype and negative expression of other markers like CD3, CD4, CD5, CD7, CD8, CD10, CD95, CD19, CD30, BCL2 which allowed to suggest neural cell tumor (neuroendocrine malignancy) [Table 4; Figure 5].

Discussion: Cytomorphology alone often can accurately diagnose malignant lymphoma in cytologic specimens such as FNA.⁷ It may be difficult to detect small proportion of malignant lymphoid cells by light microscope if admixed with reactive lymphoid cells especially in effusions. Application of MFC immunophenotyping is not well investigated in SCE diagnosis despite it has been accepted in FNA specimens for analysis of cytomorphology as an adjunct.⁷⁻¹³ Immature or undifferentiated blast cells of B lymphocytes or T lymphocytes can be classified based on the expression of their cluster of differentiated antigens by MFC immunophenotyping.¹⁴ Mature B cell neoplasms is determined by monoclonality (light chain restriction, i.e. kappa or lambda) which can differentiate it from normal and reactive population

by FCM.¹⁵ Expression of CD5, CD7, CD2 or aberrant antigens can identify T cell and Natural Killer (NK) cell neoplasms.¹⁶

In this study, we have evaluated the utility of MFC immunophenotyping in the diagnosis and classification of malignancies in serous cavity effusions and FNA specimens.

Our study group consisted of 16 body fluids (11 pleural fluids and 5 ascitic fluids) and 14 fine needle aspirate (FNA) samples (13 enlarged lymph nodes and 1 lung mass). Overall diagnosis was hematologic malignancy (83.33%), other malignancy (6.77%) and tuberculosis (10%). Among mature B-cell malignancies two types of B-cell non-Hodgkin lymphoma were identified in this study, these were diffuse large B-cell lymphoma (DLBCL) and splenic B-cell marginal zone lymphoma (SMZL). Out of eight DLBCL cases identified, four cases were detected in pleural fluid, one in **ascitic** fluid and three in FNA of lymph node. DLBCL are a group of mature B-cell malignancies accounts for 30-35%, present as a rapidly growing mass in any lymph node group or non-lymphoid organ. The cytomorphology of DLBCL is highly variable, sub-division and prognostic assessment is based on the immunophenotype and chromosomal abnormalities in conjunction with International Prognostic Index (IPI).¹⁷ The subtype of DLBCL may arise as primary effusion lymphoma (PEL), typically presents as a pleural, **ascitic** or pericardial effusion without an accompanying tumor mass.¹⁸ Primary effusion lymphoma is typically highly aggressive and is commonly refractory to therapy.¹⁹ DLBCL showed CD5 and CD23 negativity with strong expression of CD19, CD20, CD79a, CD79b, FMC7, CD22. Monoclonality was determined by light chain restriction. CD5 negativity differentiates DLBCL from CLL/SLL and Mantle Cell Lymphoma (MCL) which express CD5.

Only one SMZL was identified in FNA of lymph node in which there is usually marked splenomegaly, **tiny lymphadenopathy**. It showed characteristic morphology of polar villous lymphocytes in peripheral blood. SMZL showed monoclonality, expressed CD11c but didn't express CD123 which differentiates it from Hairy cell leukemia which express both CD11c and CD123.

Among mature T-cell malignancies, in this study two types of T-cell non-Hodgkin lymphoma were diagnosed which were Angioimmunoblastic T-cell lymphoma (AITL) and Peripheral T-cell lymphoma, not otherwise specified [PTCL (NOS)]. Most of the AITL were identified in serous cavity effusions. Out of ten cases, four cases were detected in pleural fluid, four in ascitic fluid

and two in FNA. The characteristics of this lymphoma is effacement of nodal architecture by a polymorphous infiltrate of atypical lymphocytes and vascular proliferation, and the reactive cellular proliferation can make it difficult to determine if the lesion is of B-cell or T-cell lineage.¹⁷ Immunophenotype of AITL showed expression of pan T-cell markers on neoplastic cells, reactive B-cell markers (CD19, CD20, CD79a without light chain restriction). There was predominance of CD4+ T-cells over CD8+ T-cells.

Peripheral T-cell lymphoma, not otherwise specified [PTCL (NOS)] is mature T-cell neoplasm that do not fit into other recognizable subtypes of T-cell lymphoma. About half of the peripheral T-cell lymphomas in this group have multiple morphological subtypes.¹⁷ In this study, PTCL (NOS) was identified in only one FNA of lymph node. The characteristic immunophenotypic features of PTCL(NOS) are negative expression of CD30, perforin, granzyme and CD56, which differentiates it from other mature T-cell lymphomas as these markers are usually expressed by these neoplasms.

T-LbLy and T-ALL are neoplasms of precursor (thymic) T-lymphoid cells. **The white blood** cell count in T-ALL may be very high with circulating blasts while it is normal in T-LbLy. T-ALL is considered to be the leukemic form of T-Lbly where blast cells involve peripheral blood and bone marrow while lymph nodes architecture is usually replaced by lymphoblasts in T-LbLy. Serous cavity effusions may contain neoplastic cells which can be demonstrated by immunophenotyping.¹⁷ Three T-lymphoblastic lymphoma (T-LbLy) cases were diagnosed in this study of which one in pleural fluid and two in FNA of lymph node. Expression of Cytoplasmic CD3, CD1a, TdT and negative expression of CD52 differentiates it from T-cell prolymphocytic leukemia (T-PLL) which is a mature T-cell neoplasm usually CD1a and TdT negative but strongly express CD52.

One classical Hodgkin lymphoma (CHL) and one nodular lymphocyte predominant Hodgkin lymphoma (NLPHL) were identified in FNA of lymph node. Classical Hodgkin lymphoma (CHL) is a B-cell neoplasm usually arise in lymph nodes where the neoplastic cell population designated as Hodgkin and Reed-Sternberg (HRS) cells often be recognized morphologically by large cell size are either multinucleated or have a bilobed nucleus with prominent eosinophilic inclusion like nucleoli resembling an “owl’s eye” appearance. The HRS cells despite originates from mature B- cell, fail to express B-cell markers because of severe **impairment** of B-cell

transcription factor network. The diagnosis of CHL currently relies on a combination of morphological and immunohistochemical findings. Multiparameter flow cytometry (MFC) appears to be ideally suited for the detection of lymphomas where the malignant cells are rare and most of the background cells are of benign origin such as Classical Hodgkin lymphoma (CHL), nodular lymphocyte predominant Hodgkin lymphoma (NLPHL) and T-cell rich large B-cell lymphoma.²⁰ This study diagnosed only one case of Classical Hodgkin lymphoma (CHL) by MFC analysis that detected a small malignant CD45 negative population of cells that was also negative for CD19, CD20, CD79a, CD3, CD56 but did express CD30, CD40 and CD15, fulfilling the diagnostic criteria for CHL by MFC. In contrast NLPHL which is a monoclonal mature B-cell neoplasm characterized by presence of popcorn or L&H cells, didn't express CD30, CD40, CD15 but expressed CD19, CD20, CD79a, CD45, BCL6 by MFC analysis which differentiates it from CHL in this study.

Two non-hematologic malignancies identified in this study were thymoma and tumor of neural cell origin (neuroendocrine malignancy). We conducted MFC analysis on city guided FNA sample from lung mass and detected CD56+/CD45- population, this population didn't express markers of B-cells (CD19, CD20, CD79a) and markers of T-cells (CD3, CD2, CD5, CD7, CD4, CD8) which allowed us to suggest small cell lung carcinoma. A study reported similar findings who diagnosed neuroendocrine malignancy in serous effusions using panel of monoclonal antibodies comprising CD45, CD56 and markers of B-cell and T-cell.³ Other studies evaluated the usefulness of MFC in diagnosing neuroendocrine malignancies by detection of CD56+/CD45- phenotype in peripheral blood and bone marrow.^{21,22} The utility of MFC is very limited for the diagnosis of these malignancies due to lack of specific markers. One thymoma was identified in pleural fluid in this study, expressing double positive T-cells (CD4+CD8+) with expression of other T-cell markers but didn't express CD19, CD56. Morphologically, the immature thymocytes in a thymoma may resemble the immature cells in T-LbLy. Immunophenotype pattern of T-LbLy by MFC can efficiently differentiate it from thymoma.

Tuberculosis was diagnosed in three cases, one in pleural fluid and two in FNA of lymph node by detecting *Mycobacterium tuberculosis* DNA using RT-PCR. Immunophenotype of pleural fluid and FNA sample in these cases detected mature/ reactive T-cells or monocytes. MFC analysis of these cases could not detect malignancy but *Mycobacterium tuberculosis* DNA was detected by RT-PCR. This finding suggest us to apply techniques for detecting tuberculosis in

SCEs and FNA sample where there is lymphocytosis which arises suspicion of either tuberculosis or malignancy; It will also help physicians to plan for proper treatment.

In this study out of 30 cases, 19/30(63.33%) cases were both immunophenotype and cytomorphology positive for malignancy. Both Cytomorphology Negative and MTB RT-PCR Negative for Tuberculosis but immunophenotype Positive for Malignancy were 8/30(26.67%) cases. The findings of this study revealed that MFC immunophenotyping detected eight more malignancy cases (29.63%) which could be missed out by cytomorphology.

The findings of this study has shown that the distribution of T-cell and B-cell malignancies in ascites and pleural effusions is different. T-cell malignancies detected more in ascitic fluid, while B-cell malignancies in pleural effusions. A study by Shenet al. reported the distribution of T-cell and B-cell malignancies in SCEs where they identified T-cell malignancies more in pleural fluid and B-cell malignancies in ascites which is not consistent with this study.³ When lymphoma is clinically suspected, it can help the physicians to initially plan for emergency treatment according to ascites or pleural effusions.

Conclusion: Multiparameter flow cytometry using comprehensive panel of monoclonal antibodies is an invaluable tool to diagnose hematologic and non-hematologic malignancies in body fluids or FNA as it can demonstrate small malignant populations that may be missed out by routine cytomorphology. To our knowledge, this is the first study in Bangladesh to describe the utility of MFC analysis in diagnosing Hodgkin and non-Hodgkin lymphomas as well as neuroendocrine malignancy in serous cavity effusions.

References:

1. Dixit R, Agarwal KC, Gokhroo A, Patil CB, Meena M, Shah NS et al. Diagnosis and management options in malignant pleural effusions. Lung India. 2017; 34(2): 160–16
2. Czader M, Ali SZ. Flow cytometry as an adjunct to cytomorphologic analysis of serous effusions. DiagnCytopathol. 2003; 29 (2):74-8.

3. Shen H, Tang Y, Xu X, Wang L, Wang Q, Xu W et al. Rapid detection of neoplastic cells in serous cavity effusions in children with flow cytometryimmunophenotyping. *Leukemia & Lymphoma*. 2012; 53 (8):1509-1514.
4. Lesniewska BB. Flow Cytometry and Effusions in Lymphoproliferative Processes and Other Hematologic Neoplasias. *ActaCytologica*. 2016;60: 354-364.
5. Kumar S, Kimlinger T, Morice W. Immunophenotyping in multiple myeloma and related plasma cell disorders. *Best Pract Res ClinHaematol*. 2010;23(3): 433–451
6. Cesana C, Klersy C, Scarpati B, Brando B, Volpato E, Bertani G et al. Flow cytometryvscytomorphology for the detection of hematologic malignancy in body cavity fluids. *Leukemia Research*. 2010;34 (8):1027-1034.
7. Robbins DB, Katz RL, Swan F Jr, Atkinson EN, Ordonez NG, Huh YO. Immunophenotyping of lymphoma by fine-needle aspiration: a comparative study of cytospin preparation and flow cytometry. *Am J ClinPathol*. 1994;101: 569-576.
8. Dunphy CH, Ramos R. Combining fine-needle aspiration and flow cytometricimmunophenotyping in evaluation of nodal and extranodal sites for lymphoma: a retrospective review. *DiagnCytopathol*. 1997;16:200-206.
9. Alam K, Jain A, Maheshwari V, Siddiqui FA, Haider N, Khan AH. Fine-needle aspiration cytology diagnosis of non-Hodgkins lymphoma in a resource-challenged environment. *DiagnCytopathol*. 2011;39(6):461-7.
10. Young NA, Al-Saleem TI, Ehya H, Smith MR. Utilization of fine needle aspiration cytology and flow cytometry in the diagnosis and subclassification of primary and recurrent lymphoma. *Cancer (Cancer Cytopathol)*. 1998; 84: 252-261.
11. Zander DS, Ituraraspe JA, Everett ET, Massey JK, Braylan RC. Flow cytometry in vitro assessment of its potential application for diagnosis and classification of lymphoid neoplasms in cytologic preparations from fine-needle aspirates. *Am J ClinPathol*. 1994; 101: 577-586.
12. Saddik M, El Dabbagh L, Mourad WA. Ex vivo fine-needle aspiration cytology and flow cytometricimmunophenotyping in the diagnosis of lymphoproliferative disorders: a proposed algorithm for maximum resource utilization. *DiagnCytopathol*. 1997; 6:126-131.
13. Young NA, Al-Saleem T. Hematopathologists and cytopathologists: enemies or allies? *DiagnCytopathol*. 1999; 21:305-306.
14. Jaye DL, Bray RA, Gebel HM, Harris WAC, Waller EK. Translational Applications of Flow Cytometry in Clinical Practice. *J Immunol*. 2012;188 (10): 4715-4719.

15. Chizuka A, Kanda Y, Nannya Y, Oshima K, Kaneko M, Yamamoto R et al. The diagnostic value of kappa/lambda ratios determined by flow cytometric analysis of biopsy specimens in B-cell lymphoma. *Clin Lab Haematol.* 2002; 24:33-36.
16. Gorczyca W, Weisberger J, Liu Z, Tsang P, Hossein M, Wu CD et al. An approach to diagnosis of T-cell lymphoproliferative disorders by flow cytometry. *Cytometry.* 2002; 50: 177-90.
17. Parker A, Bain B, Devereux S, Gatter K, Jack A, Matutes E et al. *Best Practice in Lymphoma Diagnosis and Reporting* London, UK: British Committee for Standards in Haematology, Royal College of Pathologists; 2010.
18. Das DK. Serous effusions in malignant lymphomas: a review. *Diagn Cytopathol.* 2006; 34; 335-347.
19. Zanelli M, Sanguedolce F, Zizzo M, Palicelli A, Bassi MC, Santandrea G et al. Primary effusion lymphoma occurring in the setting of transplanted patients: a systematic review of a rare, life-threatening post-transplantation occurrence. *BMC Cancer.* 2021;21(1):468.
20. Roshal M, Wood BL, Fromm JR. Flow Cytometric Detection of the Classical Hodgkin Lymphoma: Clinical and Research Applications. *Advances in Hematology.* 2010; 2011:1-9.
21. Nagai J, Ishida Y, Koga N, Tanaka Y, Ohnuma K, Toyoda Y et al. A new sensitive and specific combination of CD81/CD56/CD45 monoclonal antibodies for detecting circulating neuroblastoma cells in peripheral blood using flow cytometry. *J Pediatr Hematol Oncol.* 2000; 22:20-26.
22. Cai JY, Tang YJ, Jiang LM, Pan C, Chen J, Tang JY et al. Prognostic influence of minimal residual disease detected by flow cytometry and peripheral blood stem cell transplantation by CD34+ selection in childhood advanced neuroblastoma. *Pediatr Blood Cancer.* 2007; 49: 952-957.

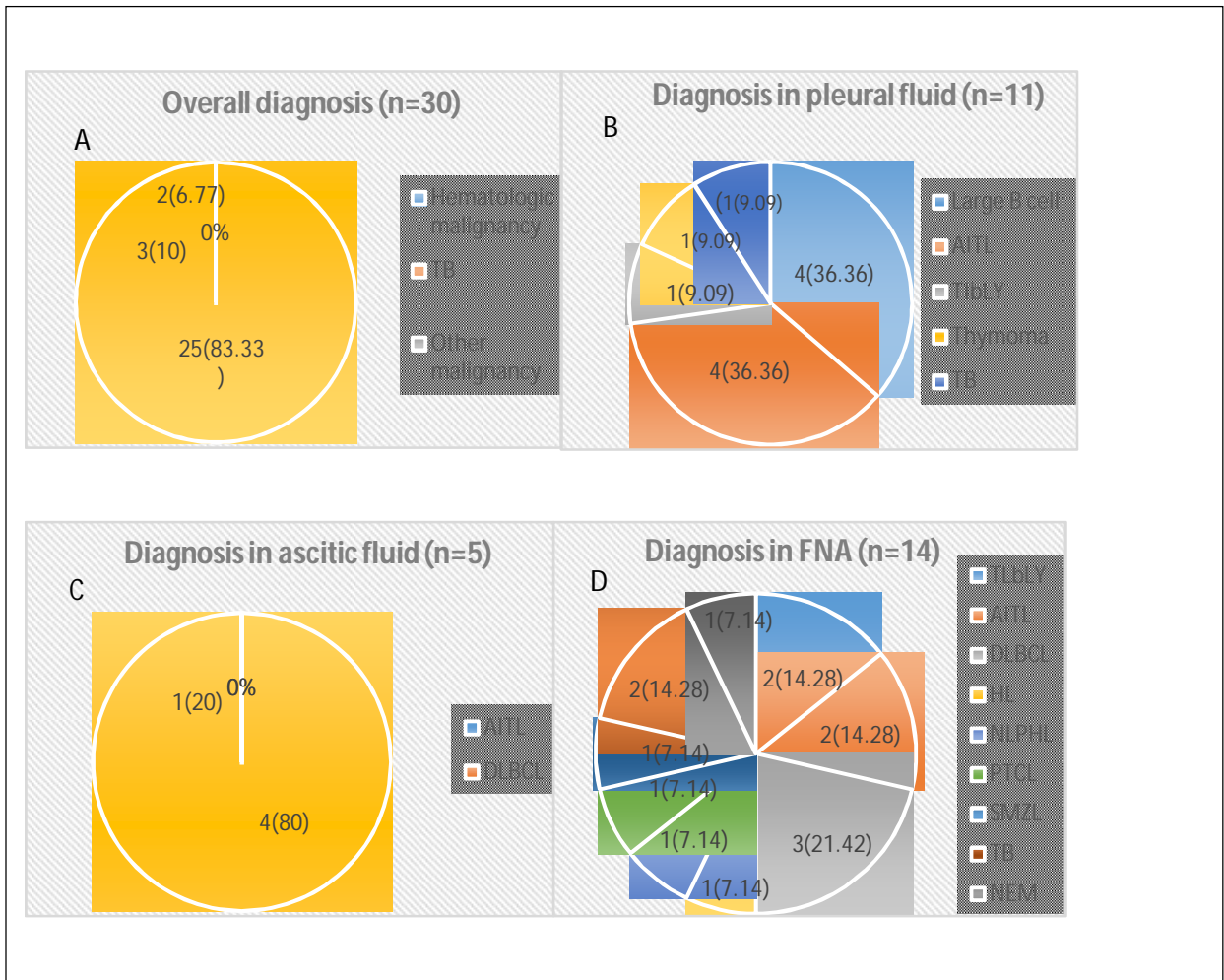


Figure 1:Diagnosis of different types of diseases in different body fluids & FNA (n=30). 1A. overall diagnosis where n= 30. 1B. pleural fluid analysis where n=11. 1C.ascitic fluid analysis where n=5. 1D. FNA analysis where n=14. Figure in parenthesis indicate percentage

Table 1: Both Cytomorphology and Immunophenotype Positive for Malignancy: MTB RT-PCR Negative for Tuberculosis (n=19)

Case no.	Specimen origin	Cytomorphology	FCI diagnosis	MTB RT-PCR
1	Pleural fluid	Positive	DLBCL	Negative
2	Pleura Fluid	Positive	DLBCL	Negative
3	Pleural fluid	Positive	AITL	Negative
4	Pleural fluid	Positive	AITL	Negative
5	Pleural fluid	Positive	AITL	Negative
6	Pleural fluid	Positive	T-LbLy	Negative
7	Ascitic fluid	Positive	AITL	Negative
8	Ascitic fluid	Positive	AITL	Negative
9	Ascitic fluid	Positive	AITL	Negative
10	Ascitic fluid	Positive	DLBCL	Negative
11	FNA	Positive	T-LbLy	Negative
12	FNA	Positive	AITL	Negative
13	FNA	Positive	AITL	Negative
14	FNA	Positive	PTCL(NOS)	Negative
15	FNA	Positive	HL	Negative
16	FNA	Positive	NLPHL	Negative
17	FNA	Positive	DLBCL	Negative
18	FNA	Positive	DLBCL	Negative
19	FNA	Positive	DLBCL	Negative

FCI: flow cytometric immunophenotyping, DLBCL: diffuse large B-cell lymphoma, AITL: angioimmunoblastic T-cell lymphoma, T-LbLy: T- lymphoblastic lymphoma, PTCL(NOS): peripheral T-cell lymphoma(not otherwise specified), HL: Hodgkin lymphoma, NLPHL: nodular lymphocyte predominant Hodgkin lymphoma, MTB RT-PCR: *Mycobacterium tuberculosis* Real time-Polymerase chain reaction.

Table 2: Both Cytomorphology and Immunophenotype Negative for Malignancy; MTB RT-PCR Positive for Tuberculosis (n=3)

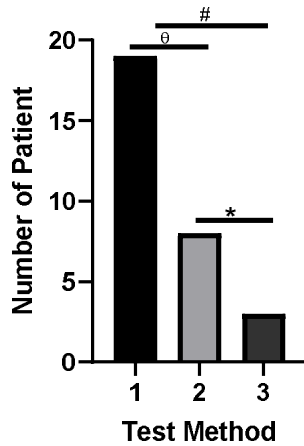
Case no.	Specimen origin	Cytomorphology	Immunophenotype	MTB RT-PCR
1	Pleural fluid	Negative	Mature T-cells/reactive	Positive
2	FNA	Negative	Mature monocytes/reactive	Positive
3	FNA	Negative	Mature T-cells/reactive	Positive

FNA: fine needle aspirate, MTB RT-PCR: *Mycobacterium tuberculosis* Real time -Polymerase chain reaction.

Table 3: Cytomorphology Negative for Malignancy: Immunophenotype Positive for Malignancy: MTB RT-PCR Negative for Tuberculosis (n=8)

Case no.	Specimen origin	Cytomorphology	Immunophenotype	MTB RT-PCR
1	Pleural fluid	Negative	DLBCL	Negative
2	Pleural fluid	Negative	DLBCL	Negative
3	Pleural fluid	Negative	AITL	Negative
4	Pleural fluid	Negative	Thymoma	Negative
5	Ascitic fluid	Negative	AITL	Negative
6	FNA	Negative	SMZL	Negative
7	FNA	Negative	T-LbLy	Negative
8	FNA	Negative	Neuroendocrine malignancy	Negative

FNA: fine needle aspirate, DLBCL: diffuse large B-cell lymphoma, AITL: angioimmunoblastic T-cell lymphoma, SMZL: Splenic B-cell marginal zone lymphoma, T-LbLy: T- lymphoblastic lymphoma, MTB RT-PCR: *Mycobacterium tuberculosis* Real time- Polymerase chain reaction.



1. Cytomorphology and Immunophenotype Positive for Malignancy: MTB RT-PCR Negative for Tuberculosis
2. Cytomorphology Negative and Immunophenotype Positive for Malignancy: MTB RT-PCR Negative for Tuberculosis
3. Cytomorphology and Immunophenotype Negative for Malignancy: MTB RT-PCR Positive for Tuberculosis

Note: p value * <0.05, ** <0.005, *** <0.0005, **** <0.0001 are compared to Cytomorphology Negative : Immunophenotype Positive for Malignancy: MTB RT-PCR Negative for Tuberculosis and Cytomorphology and Immunophenotype Negative for Malignancy: MTB RT-PCR Positive for Tuberculosis; p value # <0.05, ## <0.005, ### <0.0005, #### <0.0001 are compared to Cytomorphology : Immunophenotype Positive for Malignancy: MTB RT-PCR Negative for Tuberculosis and Cytomorphology and Immunophenotype Negative for Malignancy: MTB RT-PCR Positive for Tuberculosis; p value ^θ <0.05, ^{θθ} <0.005, ^{θθθ} <0.0005, ^{θθθθ} <0.0001 compared between Cytomorphology: Immunophenotype Positive for Malignancy: MTB RT-PCR Negative for Tuberculosis and Cytomorphology Negative and Immunophenotype Positive for Malignancy: MTB RT-PCR Negative for Tuberculosis (ANOVA followed by Bonferroni multiple comparison test).

Figure 2: Comparison of Cytomorphology and Immunophenotype for malignancy and MTB RT-PCR for Tuberculosis

Table 4: Immunophenotypic features of body fluids and FNA in malignancy positive cases

FCI Diagnosis	Immunophenotypes											
	CD45	CD19	CD5	CD23	CD22	CD20	CD79a	CD79b	CD10	FMC7	K/L clonal	Bcl-2
DLBCL	+++	+++	-	-	++	+++	++	+++	+/-	++		+/-
SMZL	+++	+++	-	-	++	++	++	++	-	++	K/L clonal	CD25 -
AITL	+++	+++	+++	+	+	+	-/+	-	-	+	CD79a +	Bcl-2 +
T-LbLy	+++	CD3 Cy++/ Mem-	CD2 ++	CD1a +	CD4 +/-	CD8 -/+	CD5 +	CD7 +	TdT +	CD52 -	CD56 -	CD30 -
PTCL(NOS)	+++	CD3 +++	CD4 +++	CD8 -	CD5 +	CD7 +	CD30 -	CD56 -	Perforin -	Granzyme -	CD79a -	CD19 -
CHL	-	CD19 -	CD3 -	CD30 +++	CD15 +	CD40 ++	CD79a -	CD20 -	CD10 -	CD2 -	CD56 -	Bcl-6 -
NLPHL	+++	CD19 ++	CD3 -	CD30 -	CD15 -	CD40 -	CD79a +	CD20 +	CD10 -	CD2 -	CD56 -	Bcl-6 +
Thymoma	+++	CD3 +++	CD4 ++	CD8 ++	CD5 +++	CD7 +++	CD4+ CD8+ ++	CD10 ++	CD95 +	CD19 -	CD56 -	CD30 -
NEM	-	CD3 -	CD4 -	CD8 -	CD5 -	CD7 -	CD56 ++	CD10 -	CD95 -	CD19 -	CD30 -	Bcl-2 -

FCI: flow cytometric immunophenotyping, DLBCL: diffuse large B-cell lymphoma, AITL: angioimmunoblastic T-cell lymphoma, T-LbLy: T- lymphoblastic lymphoma, PTCL(NOS): peripheral T-cell lymphoma (not otherwise specified), CHL: Classical Hodgkin Lymphoma, NLPHL: nodular lymphocyte predominant Hodgkin Lymphoma, FNA: fine needle aspirate. NEM: Neuroendocrine malignancy

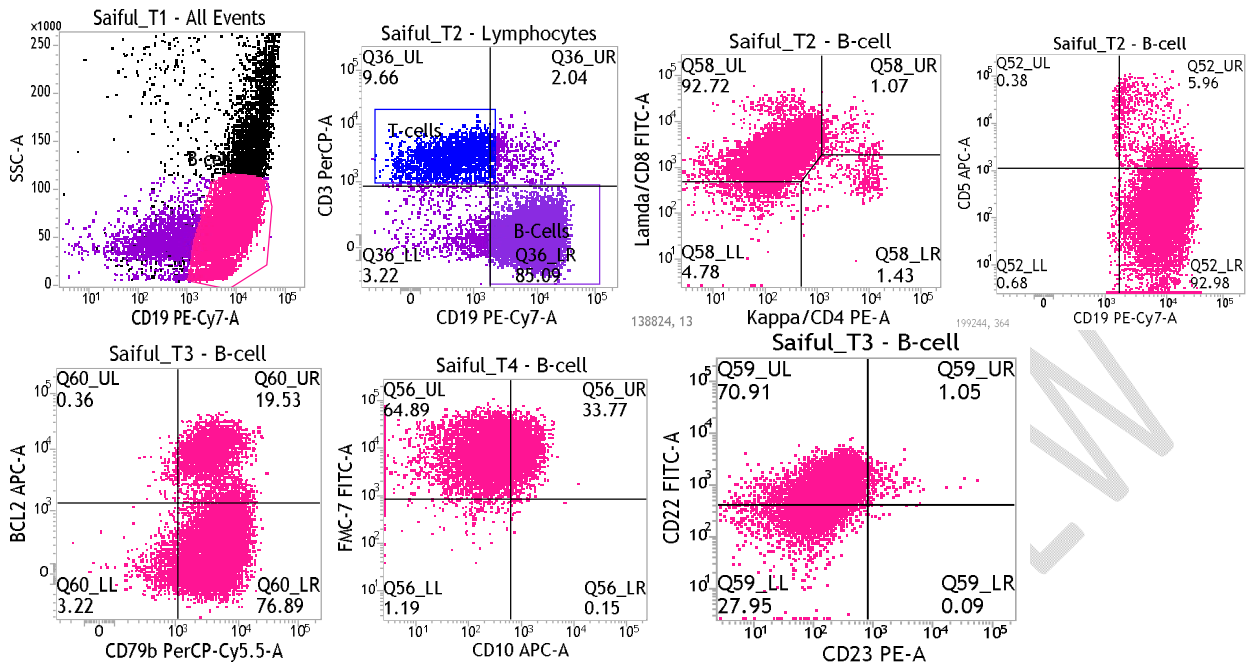


Figure-3: Flow cytometric immunophenotypic findings in a patient with Diffuse large B-cell lymphoma (DLBCL)

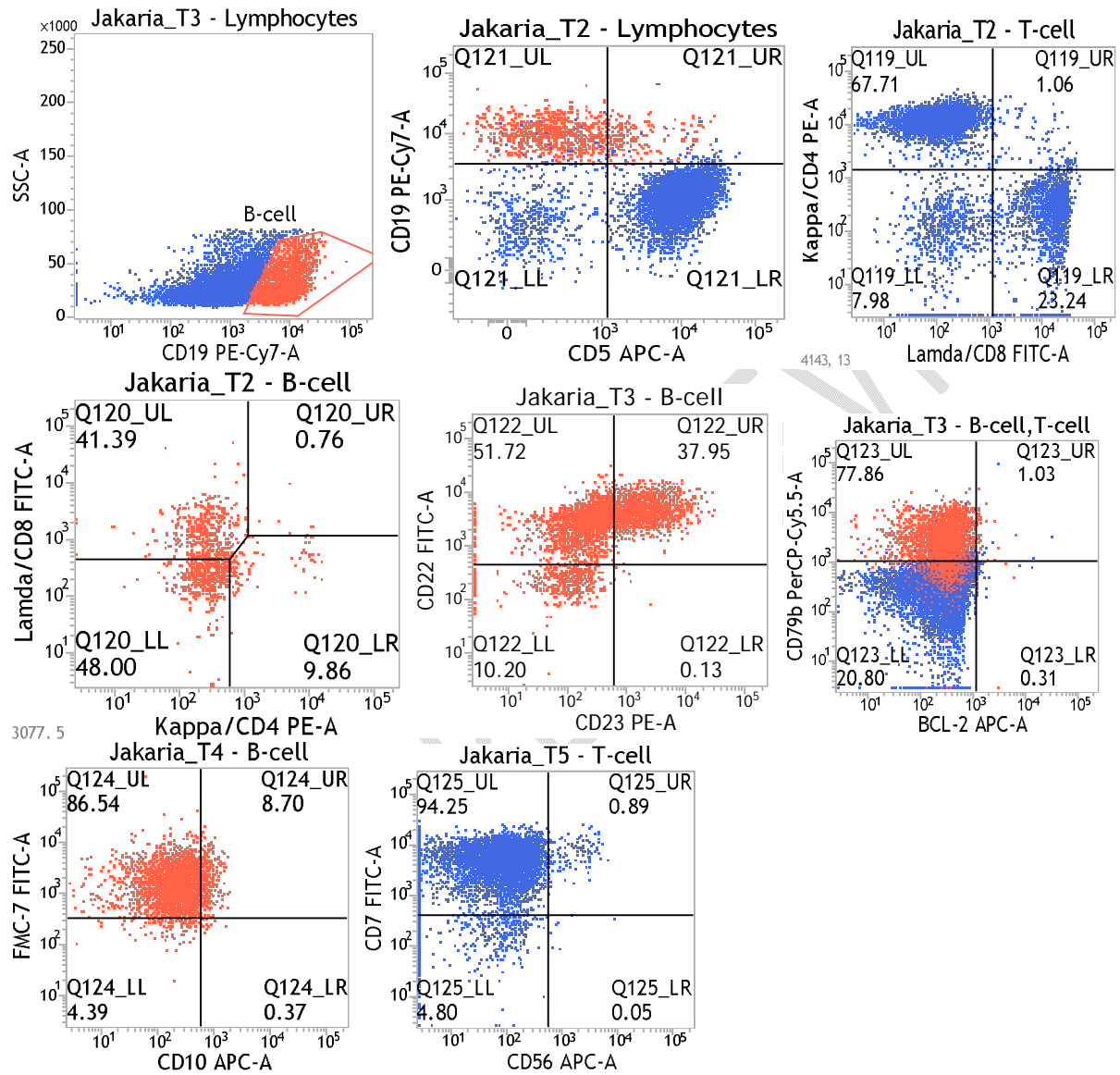
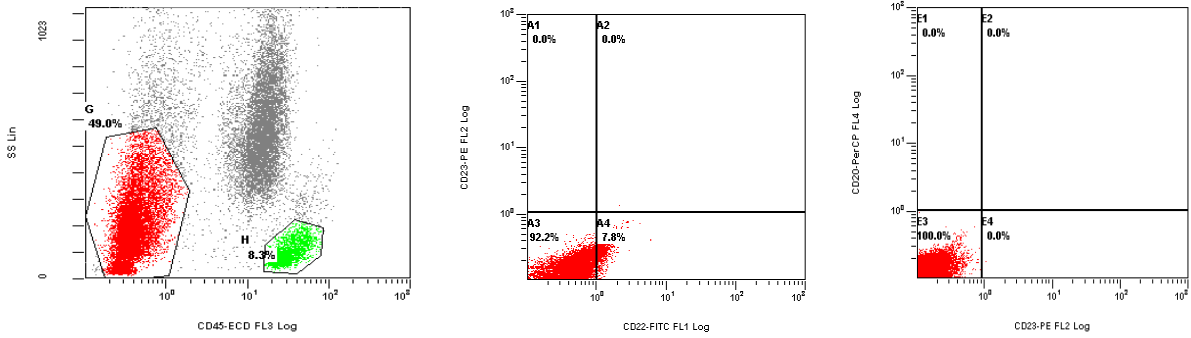
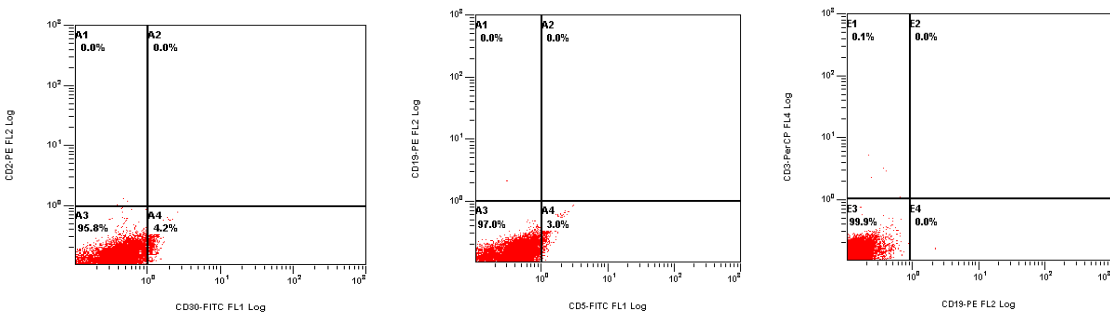


Figure-4: Flow cytometricimmunophenotypic findings in a patient with Angioimmunoblastic T- cell lymphoma (AITL)

gated] Leuk-Eut-1 Syma_199_22-23-20 00000734 2017-08-28 1725 701.LMD : FL3 Log/SS Lin ; 3] Leuk-Eut-1 Syma_199_22-23-20 00000734 2017-08-28 1725 701.LMD : FL1 Log/FL2 Log ; 3] Leuk-Eut-1 Syma_199_22-23-20 00000734 2017-08-28 1725 701.LMD : FL2 Log/FL4 Log -



]G] Leuk-Eut-1 Syma_199_30-2 00000736 2017-08-28 1740 703.LMD : FL1 Log/FL2 Log - A ; [G] Leuk-Eut-1 Syma_199_5-19-3 00000732 2017-08-28 1711 699.LMD : FL1 Log/FL2 Log - ;]G] Leuk-Eut-1 Syma_199_5-19-3 00000732 2017-08-28 1711 699.LMD : FL2 Log/FL4 Log -



]G] Leuk-Eut-1 Syma_199_7-35-25 00000733 2017-08-28 1719 700.LMD : FL1 Log/FL2 Log . ;]G] Leuk-Eut-1 Syma_199_7-35-25 00000733 2017-08-28 1719 700.LMD : FL2 Log/FL4 Log . ;]G] Leuk-Eut-1 Syma_199_BCI-56 00000735 2017-08-28 1732 702.LMD : FL1 Log/FL4 Log .

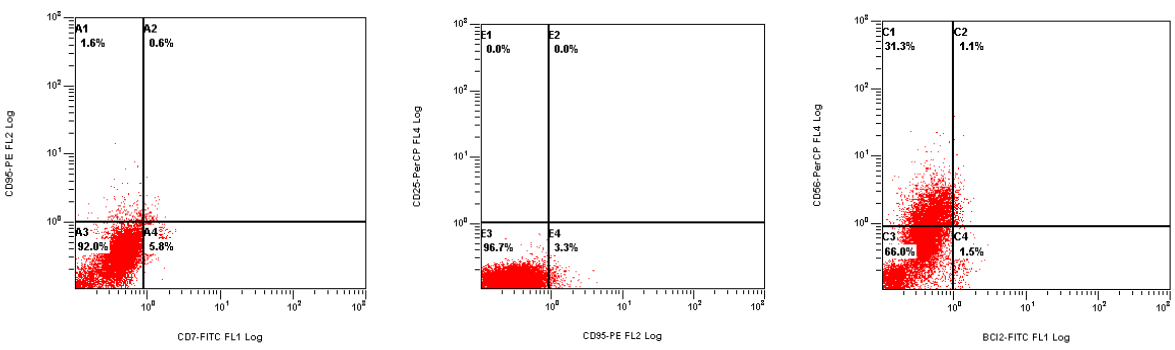
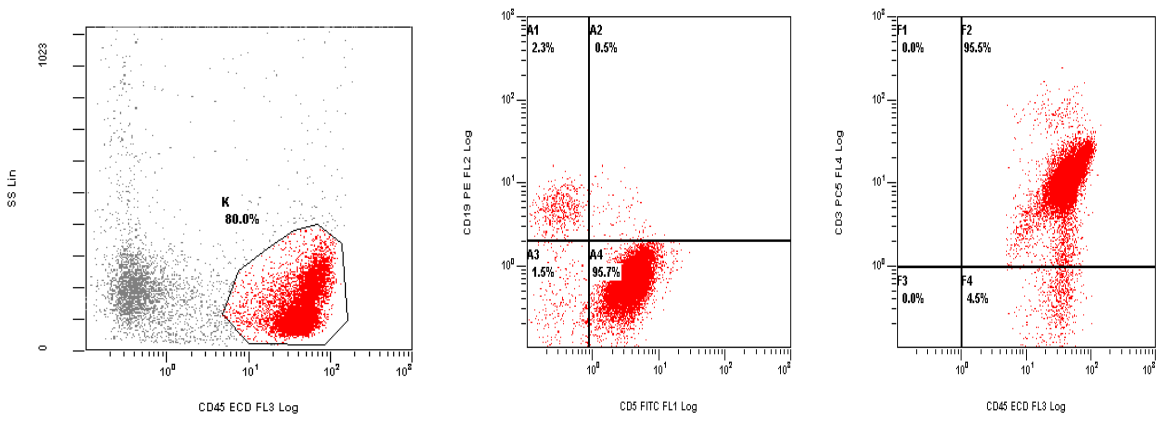
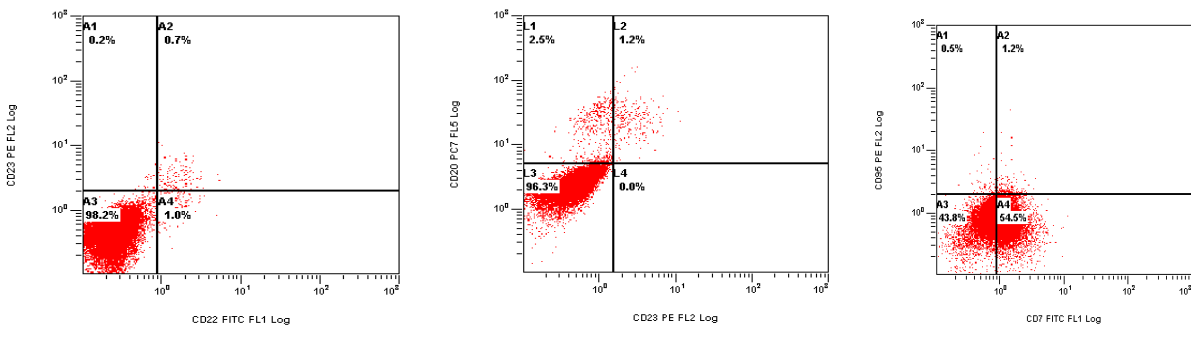


Figure-5: Flow cytometricimmunophenotypic findings in a patient with Neuroendocrinemalignancy

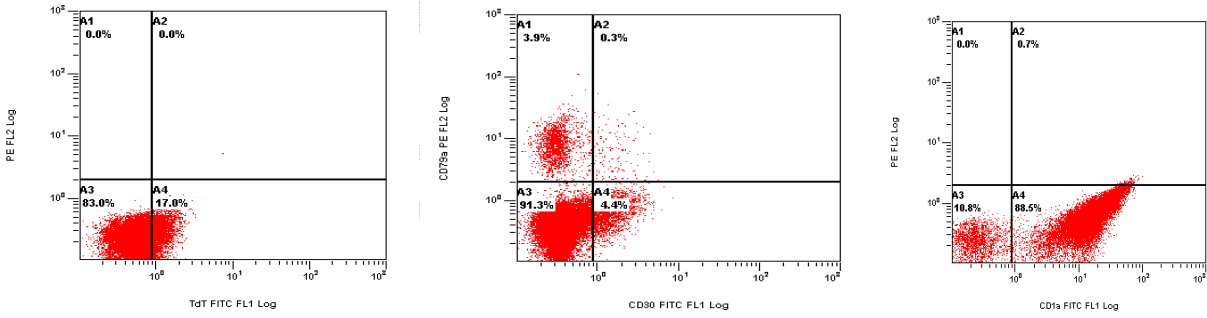
[Ungated] Leuk-Eur-2 Shohag_027 00004617 2019-03-19 1224 474.LMD : FL3 Log/SS Lin - AD 1 [K] Leuk-Eur-2 Shohag_027 00004617 2019-03-19 1224 474.LMD : FL1 Log/FL2 Log - AD 1 [K] Leuk-Eur-2 Shohag_027 00004617 2019-03-19 1224 474.LMD : FL3 Log/FL4 Log - AD



1 [K] Leuk-Eur-2 Shohag_027 00004618 2019-03-19 1225 475.LMD : FL1 Log/FL2 Log - AD 1 [K] Leuk-Eur-2 Shohag_027 00004618 2019-03-19 1225 475.LMD : FL2 Log/FL5 Log - AD 1 [K] Leuk-Eur-2 Shohag_027 00004619 2019-03-19 1226 476.LMD : FL1 Log/FL2 Log - AD



1 [K] Leuk-Eur-2 Shohag_027 00004635 2019-03-19 1348 482.LMD : FL1 Log/FL2 Log - AD 1 [K] Leuk-Eur-2 Shohag_027 00004624 2019-03-19 1236 481.LMD : FL1 Log/FL2 Log - AD 1 [K] Leuk-Eur-2 Shohag_027 00004634 2019-03-19 1342 491.LMD : FL1 Log/FL2 Log - AD



(F1) [K] Leuk-Eur-2 Asia_015 00003786 2018-11-06 1739 649.LMD : FL1 Log/FL2 Log - ADC (F1) [K] Leuk-Eur-2 Asia_015 00003781 2018-11-06 1720 638.LMD : FL1 Log/FL2 Log - ADC

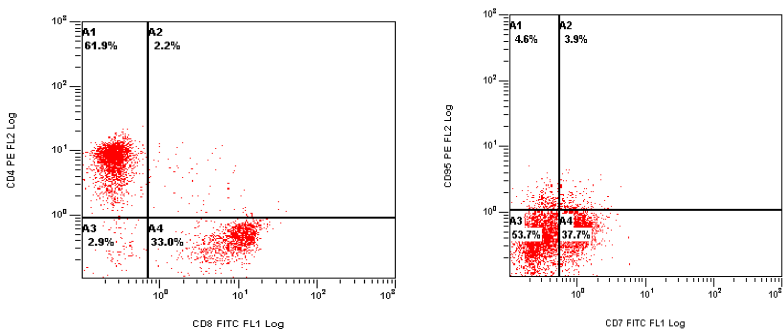


Figure-6: Flow cytometric immunophenotypic findings in a patient with T lymphoblastic lymphoma (T-LbLy)

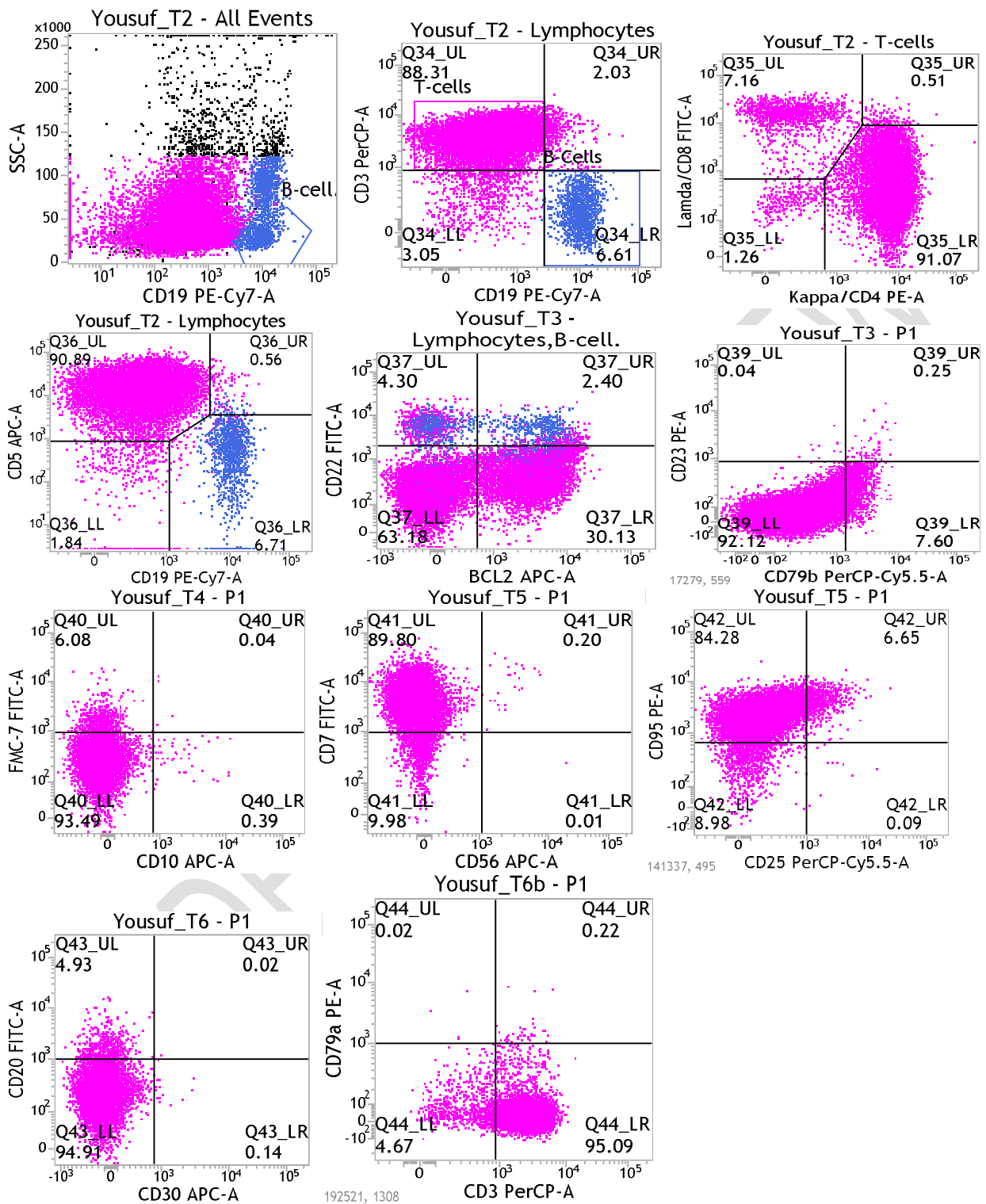


Figure-7: Flow cytometric immunophenotypic findings in a patient with Peripheral T Cell Lymphoma, Not otherwise specified

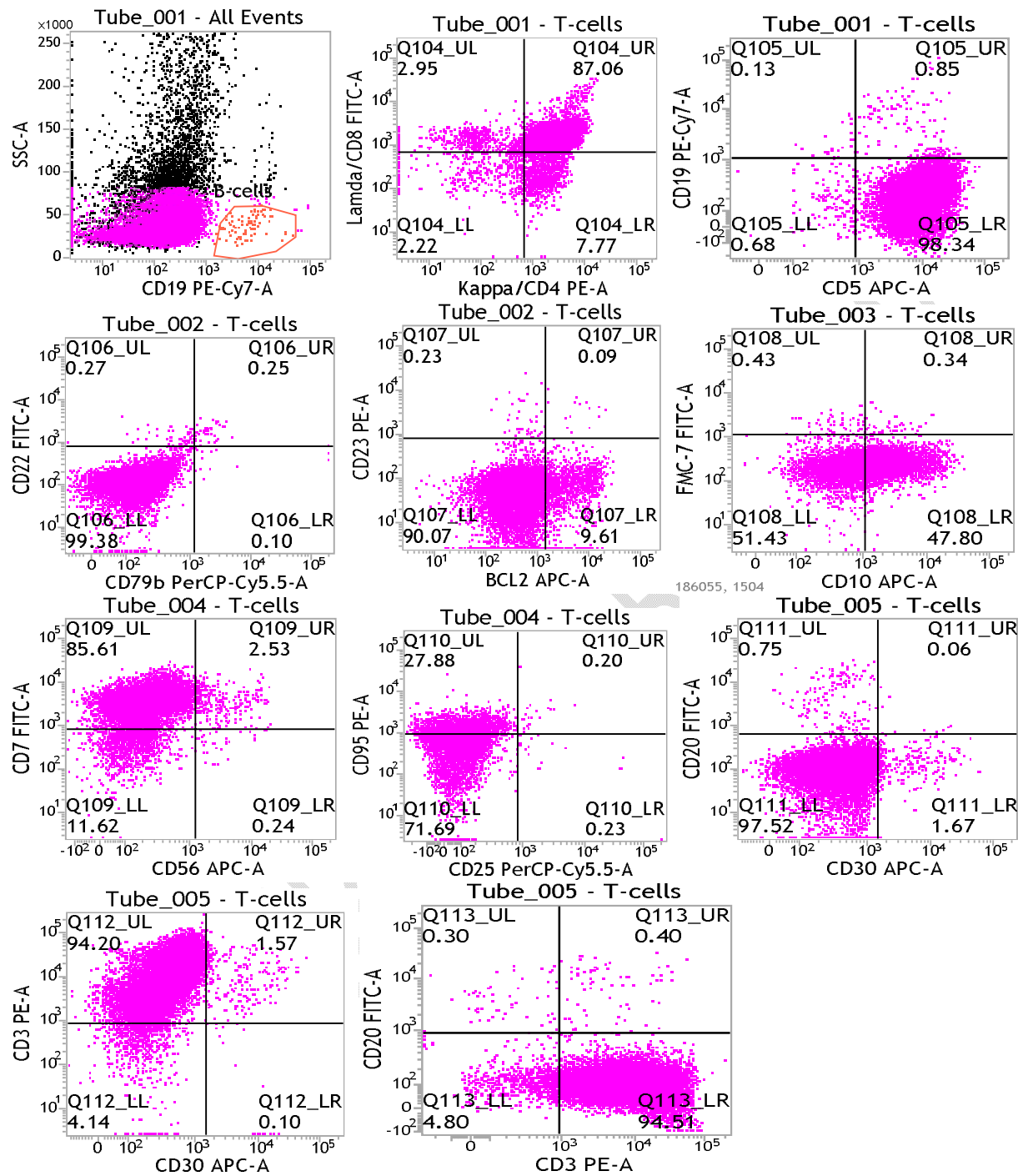


Figure-8: Flow cytometric immunophenotypic findings in a patient with Thymoma

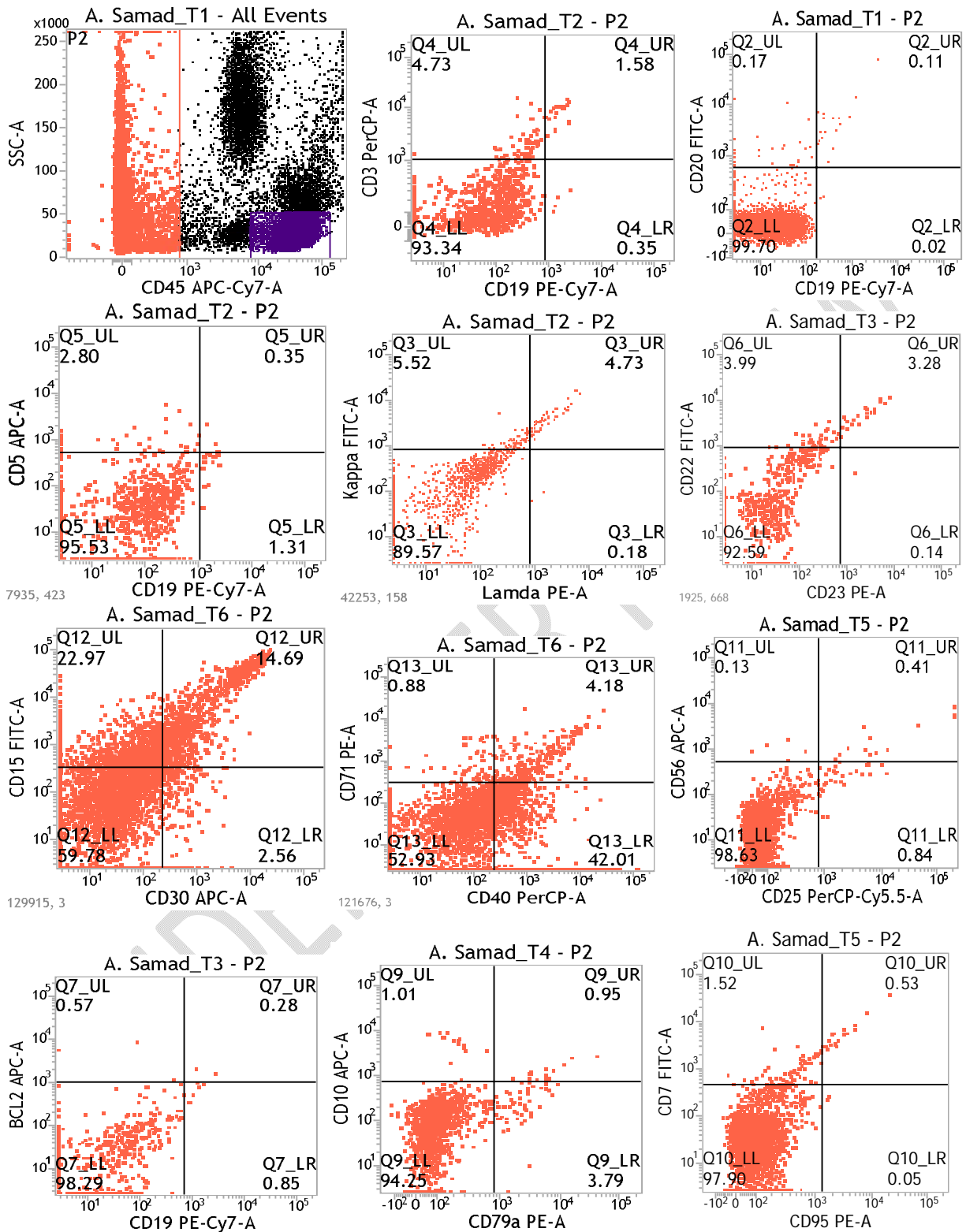
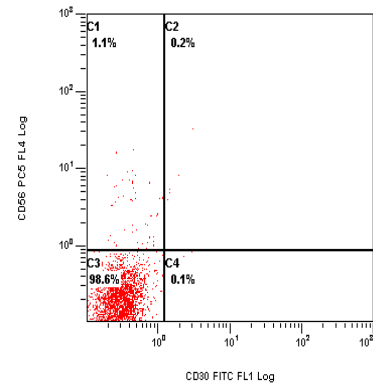
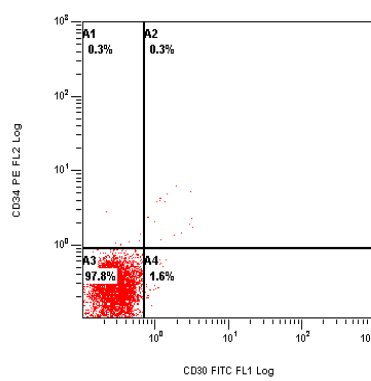
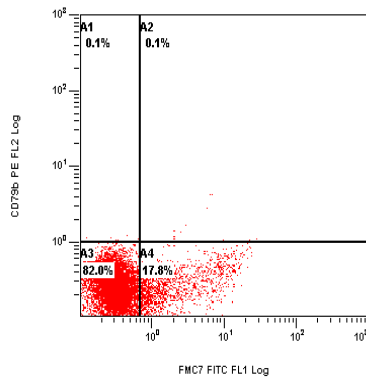


Figure-9: Flow cytometric immunophenotypic findings in a patient with Classical Hodgkin lymphoma

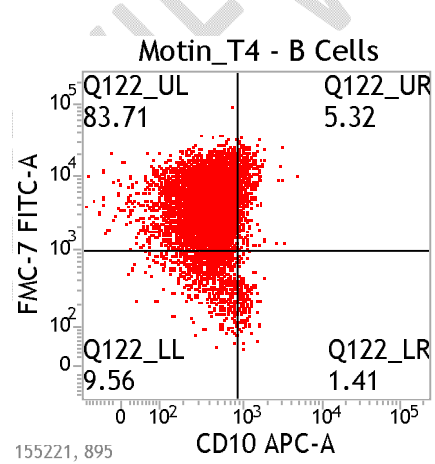
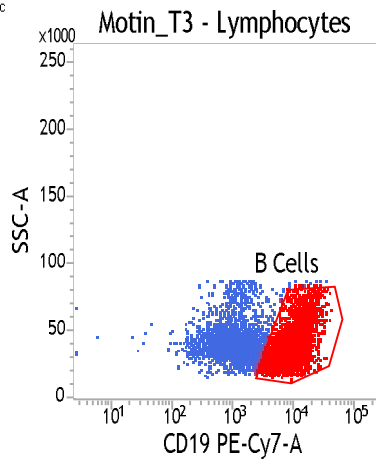
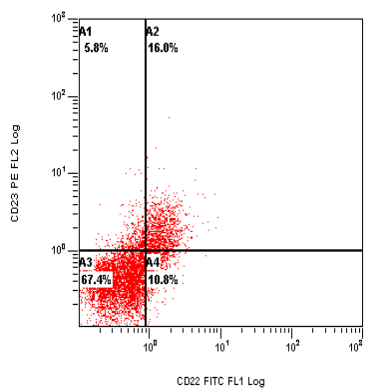
(F1)[K] Leuk-Eur1-2 Asia_015 00003782 2018-11-06 1725 639.LMD : FL1 Log/FL2 Log - ADC

(F1)[K] Leuk-Eur1-2 Asia_015 00003785 2018-11-06 1737 642.LMD : FL1 Log/FL2 Log - ADC

(F1)[K] Leuk-Eur1-2 Asia_015 00003785 2018-11-06 1737 642.LMD : FL1 Log/FL4 Log - ADC



(F1)[K] Leuk-Eur1-2 Asia_015 00003780 2018-11-06 1717 637.LMD : FL1 Log/FL2 Log - ADC



(F1)[K] Leuk-Eur1-2 Asia_015 00003780 2018-11-06 1717 637.LMD : FL1 Log/FL5 Log - ADC

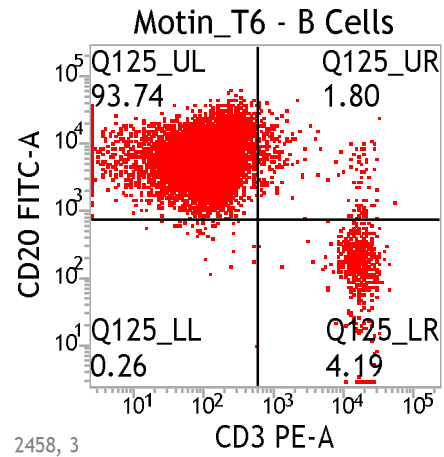
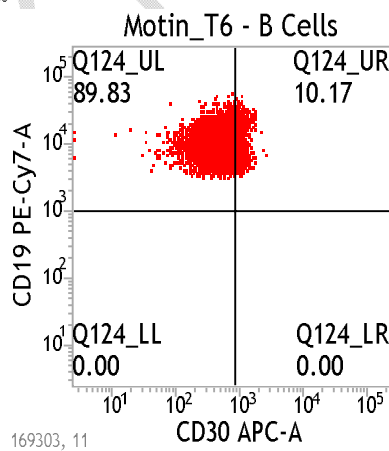
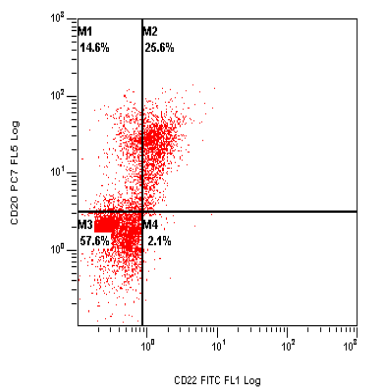


Figure-10: Flow cytometricimmunophenotypic findings in a patient with Nodular Lymphocyte Predominant Hodgkin Lymphoma.