Case study

CD8+ Mycosis Fungoides in Peripheral Blood; a Rare Finding

ABSTRACT

Cutaneous T cell lymphomas are mature lymphomas of T lymphocyte presenting with skin lesions and/or systemic manifestations. Majority of these cases show CD4+ phenotype and are classified as Mycosis Fungoides (MF)/Sezary syndrome (SS) spectrum.

Here we present a case of 74-year-old male patient, having no known comorbid, presented in Dr.Ziauddin Hospital, Karachi OPD with complains of skin lesions, itching for 2 years, generalized weakness for 4 months and no lymphadenopathy or visceromegaly. CT scan neck, chest and abdomen showed bilateral enlarged superficial inguinal lymph nodes, largest on right side having short axis diameter of 8.6 mm whereas largest one on left side having short axis diameter of 8.9 mm. Multiple enlarged enhancing bilateral axillary lymph nodes noted, most of them showed intact fatty hilum, largest one in right axilla having short axis diameter of 8 mm whereas largest one in left axilla is having short axis diameter of 6 mm.

Peripheral T cell lymphomas are a relatively uncommon hematologic malignancy that need multidisciplinary treatment. A hematologist who specializes in lymphomas, a hematopathologist, an oncologist, a primary care physician, an oncology nurse, an oncological pharmacist, an infectious disease expert, and a social worker should be part of this team.

These findings are very rare and highlight the importance of integrated approach to clinical course, morphological findings and other ancillary tests to be used in correlation with each other. These findings highlights the diversity present in T cell malignancies in terms of Immunophenotype.

Key Words: Immunophenotype, lymphadenopathy, lymphomas, Mycosis Fungoides

1. INTRODUCTION:

Cutaneous T cell lymphomas are mature lymphomas of T lymphocyte presenting with skin lesions and/or systemic manifestations [1, 4, 8, 10]. Majority of these cases show CD4+ phenotype and are classified as Mycosis Fungoides (MF)/Sezary syndrome (SS) spectrum[2,5,6,7].Mycosis Fungoides is the most common primary cutaneous lymphoma, but still, its early diagnosis remains a challenge as it requires a combination of clinical, laboratorial and pathologic studies. Its early clinical presentation resemble benign inflammatory skin conditions with overlapping histological features, providing another hindrance in making an accurate and timely diagnosis[3,8,9,10].Peripheral blood involvement is further a rarity and occurs in advanced stage of the disease[1,4,8]. Skin lesions in MF patients usually are patches and plaques, with development of ulcers and tumors in advanced stage[1], while SS has been historically defined as triad of erythroderma, lymphadenopathy and peripheral blood involvement[1,8].CD8+, CD4- cutaneous T cell lymphomas, particularly MF with such immunophenotype has rarely been described in literature[1,2,5,6,7.8].Here, we present a case of an adult male patient, who presented with chronic skin lesions all over the body including face, abdomen, limbs etc. and having peripheral blood involvement.

2. CASE PRESENTATION:

A 74-year-old male patient, having no known comorbid, presented in Dr.Ziauddin Hospital Karachi, out-patient-department (OPD) with complains of skin lesions, itching for 2 years, generalized weakness for 4 months and no lymphadenopathy or visceromegaly. Patient's weight was 62 kg, vitals were: blood pressure (BP) 130/70 mm of Hg, pulse 90 beats per minute, respiratory rate 20 breaths per minute and temperature 98.8 °F. The skin lesions were present on limbs, abdomen and face, having dark brown discoloration (hyperpigmented), with scaling and fissuring. Whitish patches were also seen on legs with edema on the hands as well. The lesions have worsened in the last 4 months. Patient was given oral steroids on and off during this time period, which remained ineffective.

Table 1: CBC along with differential leukocyte count of the patient

CBC Parameters	**Values**
Hemoglobin (gm/dL)	11.1
WBC count (x10⁹/L)	59.6
Platelets count (x10⁹/L)	231
Neutrophils (%)	7
Lymphocytes (%)	55
Eosinophils (%)	35
Monocytes (%)	3

Hemoglobin 11.1 g/dL, platelets 231 x 10^9/L and WBC count of 59.6 x 10^9/L. Differential leucocyte count revealed neutrophils 7% (absolute count 4.172 x 10^9/L), lymphocytes 55%

(absolute count 32.78 x 10^9/L), eosinophils 35% (absolute count 20.86 x 10^9/L) and monocytes 3% (absolute count 1.79 x 10^9/L), having absolute lymphocytosis and severe eosinophilia. Peripheral smear showed atypical small to medium sized lymphocytes, exhibiting nuclear folding and indentations, giving cerebriform appearance in 14% of lymphocytes. Eosinophils exhibited normal mature morphology.

CT scan neck, chest and abdomen showed bilateral enlarged superficial inguinal /lymph nodes, largest on right side having short axis diameter of 8.6 mm whereas largest one on left side having short axis diameter of 8.9 mm. Multiple enlarged enhancing bilateral axillary lymph nodes noted, most of them showed intact fatty hilum, largest one in right axilla having short axis diameter of 8 mm whereas largest one in left axilla is having short axis diameter of 6 mm. A small solitary soft tissue density nodule in the left lung lower lobe also noted measuring 9x8 mm in axial dimension.

Skin biopsy was inconclusive and reported non-specific findings consistent with reactive changes. Further, re-biopsy from a representative skin lesion site was advised. Retrospectively, it was assumed that this biopsy was most likely from a non-representative site, with having no underlying neoplastic cells and/or lesion.

Bone marrow biopsy was done to look for underlying causes of persistent severe eosinophilia and lymphocytosis. It concluded hypercellular marrow showing trilineage hematopoiesis with marked eosinophilia. There was no evidence of excess blasts, dysplasia, fibrosis, necrosis, granuloma, metastatic disease or any abnormal cell population. After some time another bone marrow biopsy was performed which also concluded similar findings.

FISH analysis for BCR-ABL1, RUNX1-RUNX1T1 gene fusions and inv (16) were negative.

Immunophenotyping of peripheral blood was then performed on Becton, Dickinson and Company's (BD) fluorescence-assisted cell sorter (FACS) model Canto II flow cytometer. It exhibited 42.8% T lymphocytes having positive expression of CD3, CD8, TCR alpha/beta, CD25, CD2 and negative for CD45, CD4, CD5, CD30, CD56, CD16 and CD19. CD7 showed heterogeneous/variable expression (positive in 62% of this population). So, an aberrant T cell population was evident by negativity of CD5, CD4, CD45 and heterogeneous CD7. Absence of significant lymphadenopathy did not favor the diagnosis of Sezary syndrome. Due to the patient's nature of skin lesions, characteristic morphology and immunophenotype, the diagnosis of CD8+ cytotoxic variant of Mycosis Fungoides was favored.

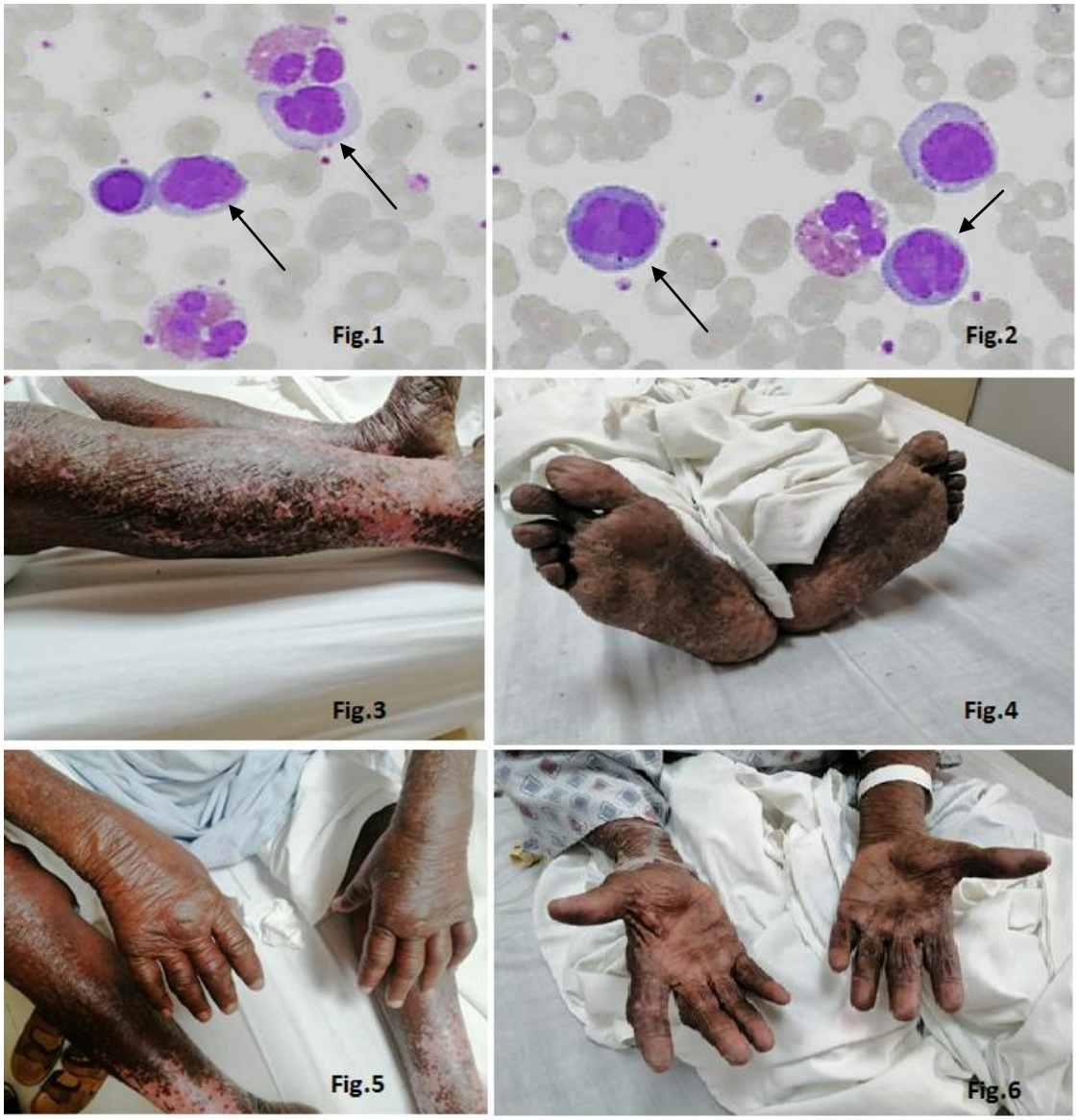

Fig 1 a & b. Leishman stained peripheral smear, 40x objective, showing lymphocytes with cerebriform nuclei (arrowed). **Fig 2 a, b, c & d**. Skin lesions present on all four limbs.

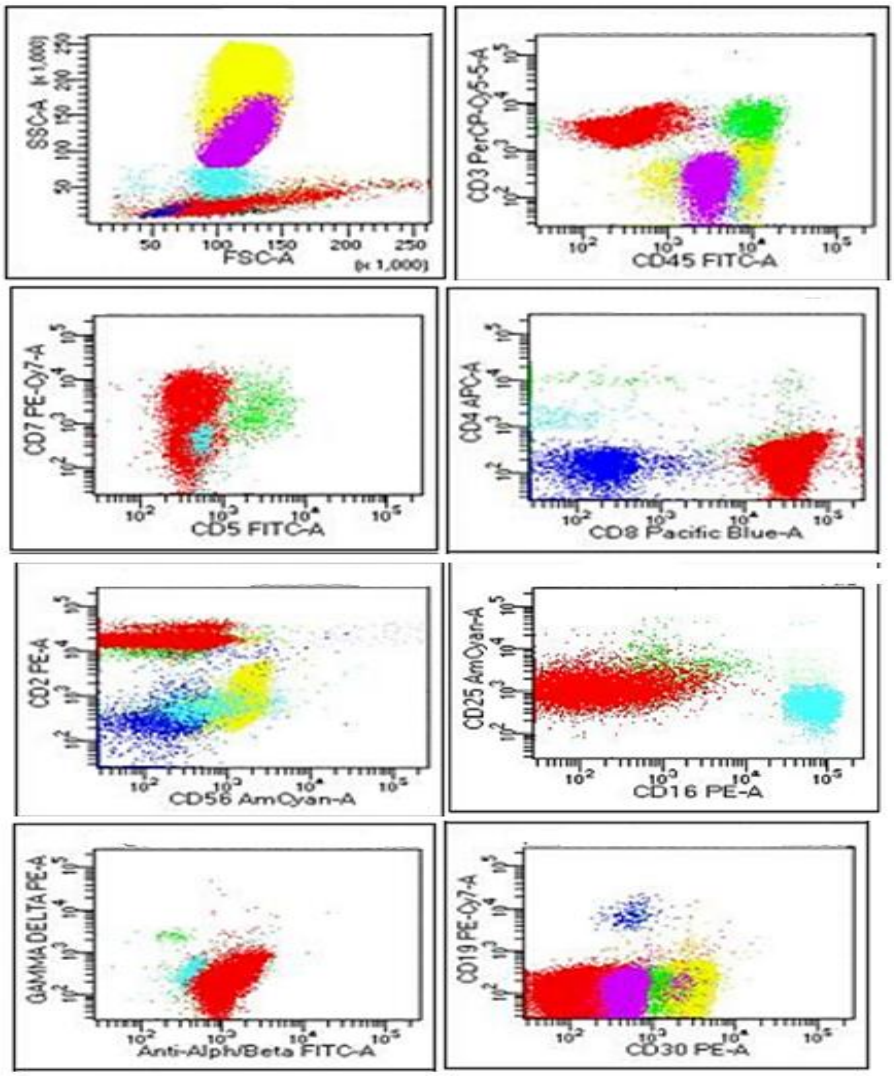

Fig.3 :Flow cytometric dot plot analysis. An aberrant CD3+ T cell population identified showing positivity for CD8, CD25, CD2, TCR alpha/beta, negative for CD45, CD4, CD5, TCR gamma/delta and variable for

(Color code). Red = malignant T cells. Blue = benign B cells. Green = benign T cells. Cyan = monocytes. Yellow = granulocytes. Violet = eosinophils.

1. DISCUSSION

Cutaneous T cell lymphoma is a group of mature T cell malignancies in the skin with variable involvement of the lymph nodes, blood and rarely viscera[1,2,6,7,8].The majority entities in this group are CD4+ and CD8^{-}. CD8+ cutaneous T cell lymphomas are a rarity [1, 5, 8, 9].Literature was searched to categorize our case, considering the clinical course, morphology of malignant cells and immunophenotype. According to the recent WHO Classification 2017, few diseases or their subtypes can be categorized into adult CD4-/CD8+ T cell lymphomas having cutaneous and/or peripheral blood involvement (without lymphadenopathy), which include; a small subset (15%) of T cell prolymphocytic leukemia (T-PLL) cases, few cases of adult T cell leukemia/lymphoma (ATLL), subcutaneous panniculitis-like T-cell lymphoma (SPTCL), cytotoxic variant of Mycosis Fungoides (MF) and primary cutaneous aggressive epidermotropic CD8+ cytotoxic T-cell lymphoma (a rare subtype of primary cutaneous peripheral T cell lymphoma)[1,5,8,9].

The morphology of our case was not consistent with that found in T-PLL. Further, skin manifestations are rarely seen in T-PLL and it also follows an aggressive clinical course. Both these findings were in contradiction to our case. ATLL usually presents with widespread lymph node involvement with skin being less commonly involved. The morphology of ATLL cells have a characteristic “flower-like” nuclei, which were not found in our case[1.] SPTCL presents with multiple subcutaneous infiltrates with no epidermic and peripheral blood involvement[1,3,8].Primary cutaneous aggressive epidermotropic CD8+ cytotoxic T-cell lymphoma has an aggressive clinical course and presents with generalized skin lesions with no involvement of peripheral blood[1].

MF is the most common type of cutaneous T cell lymphoma [2, 6, 7]. It is generally limited to the skin and extracutaneous dissemination may occur in advanced stages to the lymph nodes, liver, spleen, lungs and peripheral blood. It follows an indolent clinical course with slow progression over several years. The morphology of malignant cells in MF is lymphocytes with indented nuclei (cerebriform nuclei) [1, 5, 8, 9]. The typical phenotype is CD4+, CD8-. Cases with a cytotoxic phenotype (CD4-, CD8+) are also reported[1,8].

Our patient had an indolent disease course. The neoplastic cells exhibit characteristic cerebriform nuclei. The Immunophenotypic analysis revealed multiple aberrancies (apart from CD4/8 status) which include negativity for CD45, CD5 and variable expression of CD7. CD25 was also positive. Such findings are unusual in MF cases, but due to patient’s clinical picture, characteristic morphology and immunophenotypic expression, the diagnosis of MF was favored.

Sara Yumeen and colleagues published a case report of CD8+ mycosis fungoides palmaris et plantaris with peripheral blood involvement. The patient was adult male presenting with palmar skin lesions and no lymphadenopathy. Over the years the lesions got worsened. CBC showed lymphocytosis. Skin biopsy and flowcytometric analysis on blood were performed which both showed CD8+, CD5-, CD7-, CD56-, CD2+, CD30- abnormal population, and the case was eventually diagnosed as such[5].

4. CONCLUSION:

Peripheral T cell lymphomas are a relatively uncommon hematologic malignancy that need multidisciplinary treatment. A hematologist who specializes in lymphomas, a hematopathologist, an oncologist, a primary care physician, an oncology nurse, an oncological pharmacist, an infectious disease expert, and a social worker should be part of this team.

These findings are very rare and highlight the importance of integrated approach to clinical course, morphological findings and other ancillary tests to be used in correlation with each other. It also highlights the diversity present in T cell malignancies in terms of Immunophenotype.

ETHICAL APPROVAL:

As per international standard written ethical approval has been collected and preserved by the author(s).

CONSENT:

As per international standard or university standard, patients' written consent has been collected and preserved by the author(s).

REFERENCES:

1. Swerdlow SH, Campo E, Harris NL, Jaffe ES, Pileri SA, Stein H, et al. WHO classification of tumors of hematopoeitic and lymphoid tissues. 2017;2. Revised 4th edition. Lyon: IARC. 2017.
2. Rangoonwala, H. I., and M. Cascella. "Peripheral T-Cell Lymphoma." (2020).
3. Jawed, S. I., Myskowski, P. L., Horwitz, S., Moskowitz, A.,Querfeld, C, et al. Primary cutaneous T-cell lymphoma (mycosis fungoides and Sézary syndrome): part I. Diagnosis: clinical and histopathologic features and new molecular and biologic markers. Journal of the American Academy of Dermatology.2014;70(2), 205.e1–222.
4. Burg G. Systemic involvement in mycosis fungoides. Clinics in dermatology. 2015;33(5), 563–571.
5. Yumeen S, Mirza FN, Lewis JM, Carlson KR, King B, Cowper S, et al. CD8+ mycosis fungoides palmaris et plantaris with peripheral blood involvement. Journal of the American Academy of Dermatology. 2020;6(5):434–437.
6. Kelemen K, White CR, Gatter K, Braziel RM, Fan G. Immunophenotypic correlation between skin biopsy and peripheral blood findings in mycosis fungoides. American journal of clinical pathology. 2010; 134(5):739-748.Avaliable:doi.10.1309/AJCP7LRRLK8SLUGE. PMID: 20959657.
7. Jonak C, Tittes J, Brunner PM, Guenova E. Mycosis fungoides and Sézary syndrome. Journal der Deutschen Dermatologischen Gesellschaft.2021; 9(9):1307-1334. Available: doi.10.1111/ddg.14610. PMID: 34541796; PMCID: PMC9293091.
8. Guitart J, Martinez-Escala ME, Subtil A, Duvic M, Pulitzer MP, Olsen EA, et al. Primary cutaneous aggressive epidermotropic cytotoxic T-cell lymphomas: reappraisal of a

provisional entity in the 2016 WHO classification of cutaneous lymphomas. Modern Pathology.2017; 30(5):761-772. Available doi.10.1038/modpathol.2016.240. Epub 2017 Jan 27. PMID: 28128277; PMCID: PMC5413429.

9. McNiff JM, Schechner JS, Crotty PL, Glusac EJ. Mycosis fungoides palmaris et plantaris or acral pagetoid reticulosis? The American journal of dermatopathology. 1998; 20(3):271-275. Available: doi.10.1097/00000372-199806000-00009. PMID: 9650701.

10. Kazakov DV, Burg G, Kempf W. Clinicopathological spectrum of mycosis fungoides. Journal of the European Academy of Dermatology and Venereology. 2004;18(4):397-415.Available:doi.org/10.1111/j.1468-3083.2004.00937.x