

# TREATMENT OF METASTATIC RENAL CELL CARCINOMA: A COMPREHENSIVE REVIEW AND INDIAN PERSPECTIVE

## ABSTRACT

Renal cell carcinoma (RCC) is the eighth most common type of cancer, with more than one-third of patients having metastases when first diagnosed. There is a paradigm shift in metastatic RCC (mRCC) management with the advent of newer therapy options. The development of new innovative diagnostic and therapeutic tools has improved the prognosis of patients with advanced-stage disease. Inclusion of agents targeting the vascular endothelial growth factor (VEGF) pathway (predominantly VEGFR-directed tyrosine kinase inhibitors (TKIs)), immune-checkpoint inhibitors (ICIs) and parallel efforts to uncover new targets unveil the underlying biological differences between heterogeneous disease subtypes. Thus, new systemic therapies have become increasingly complex and optimising patient selection and treatment sequence for better patient outcomes has become crucial. This review provides a comprehensive overview of advances in the treatment landscape, emphasising the importance of individualised treatment approaches for specific subgroups of patients and also discusses the Indian perspective on the management of metastatic renal cell carcinoma with real-world case studies.

**Keywords:** *Metastatic RCC, Targeted Therapy, Immunotherapy, Systemic Therapy*

## INTRODUCTION

<sup>a</sup>GLOBOCAN 2020 reported kidney cancer as the 14th and 15th leading cause of new cases and deaths because of cancer, respectively. The projected incidence of renal cell carcinoma (RCC) among males was about 2/100,000 population, while for females was about 1/100,000 population in the year 2020 [1]. The incidence rate of RCC has risen recently, with more than 50% of RCC cases currently detected incidentally. About 20%–30% of patients will have metastatic disease at presentation. Furthermore, 20–30% of patients with previously non-metastatic diseases are anticipated to exhibit a recurrence within five years [2].

Molecular and genomic advances have increased the understanding of the underlying pathophysiology of kidney cancer. The updated classification by the <sup>b</sup>WHO described 16 subtypes of kidney cancer divided according to genomic, molecular, and syndromic characteristics [3]. In addition,

---

<sup>a</sup> Global Cancer Observatory

<sup>b</sup> World Health Organisation

immune-checkpoint inhibitors (ICI), novel targeted agents, and combination strategies are now available therapeutic options. Thus, treatment selection based on risk stratification and optimal sequencing is critical for better clinical outcomes and improving patients' quality of life [4,5]. Moreover, a better understanding of molecular characteristics, genomics, and biology of the tumour and its microenvironment drives the development of innovative diagnostic and therapeutic tools [6].

Metastatic RCC (mRCC) is often considered a chemotherapy and radiotherapy resistant tumour. Traditionally, treatment of mRCC was based on cytokine therapy, which had low response rates with a high level of treatment-related toxicity. Subsequently, the treatment strategy for mRCC has significantly shifted towards targeted therapy directed against angiogenesis, mTOR pathways, and immune checkpoint pathways (Figure 1) [7]. Biological heterogeneity of the disease is responsible for varying response rates to current treatment options [7].

The current review highlights the importance of risk stratification, active surveillance of metastatic RCC patients, and principles of RCC management decision-making. In addition, the treatment paradigm is reported based on individual factors, coupled with the management of naïve and special patient populations.

<sup>°</sup>ESMO clinical practice guidelines for diagnosis and treatment of RCC were updated for 2021 [8]. However, it was decided by both ESMO and the Singapore Society of Oncology (SSO) to convene a special, virtual guideline meeting in May 2021 to adopt ESMO 2019 recommendations, considering ethnic differences associated with the treatment of RCC in Asian patients. Experts made consensus opinions from India (<sup>d</sup>ISMPO), China (<sup>e</sup>CSCO), Japan (<sup>f</sup>JSMO), Korea (<sup>g</sup>KSMO), Singapore (SSO), Malaysia (<sup>h</sup>MOS), and Taiwan (<sup>i</sup>TOS) [9].

---

<sup>c</sup> European Society for Medical Oncology

<sup>d</sup> Indian Society of Medical and Pediatric Oncology

<sup>e</sup> Chinese Society of Clinical Oncology

<sup>f</sup> Japanese Society of Medical Oncology

<sup>g</sup> Korean Society of Medical Oncology

<sup>h</sup> Malaysian Oncological Society

<sup>i</sup> Taiwan Oncological Society

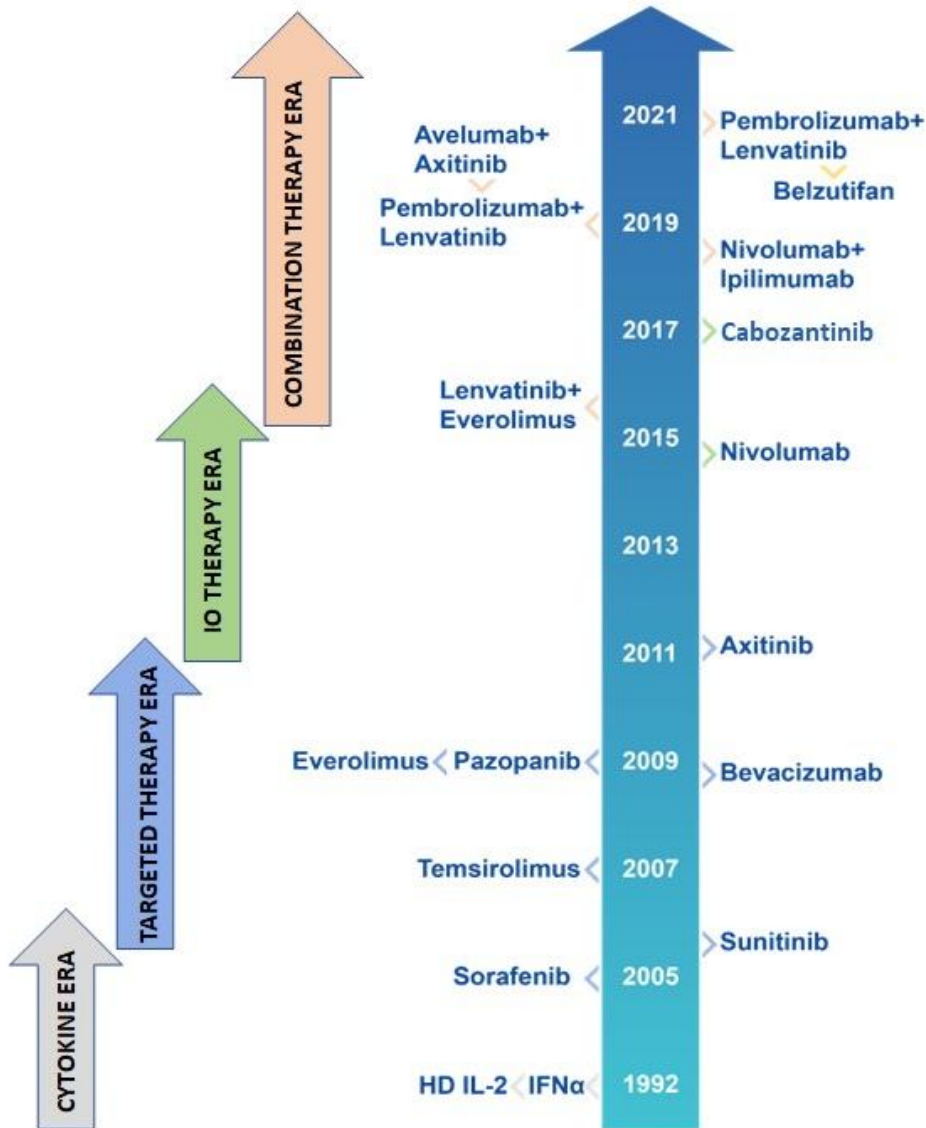


Figure 1: Treatment landscape for metastatic clear cell renal carcinoma.

### RISK STRATIFICATION OF METASTATIC RCC PATIENTS

Several risk models have been developed to guide treatment selection in mRCC patients. The most common risk models used for mRCC patients were developed by researchers from the International Metastatic Renal Cell Carcinoma Database Consortium (IMDC) and the Memorial Sloan Kettering Cancer Centre (MSKCC). These risk models incorporate various clinical and laboratory parameters for disease risk stratification [10,11].

The IMDC model overlaps with the MSKCC model in the targeted therapy era, except for the criterion that includes thrombocytosis and neutrophilia instead of elevated <sup>l</sup>LDH. IMDC is validated for different therapy settings, especially in patients with non-clear histologies [12]. In addition, the MSKCC tool was developed to assist clinicians to better-predicting prognosis based on risk stratification, which incorporates Karnofsky's performance status (<80%), time from the initial diagnosis to systemic therapy, low haemoglobin, hypercalcaemia, and LDH for treatment and diagnosis [13].

IMDC and MSKCC models include 6 and 5 risk factors, respectively, out of which four risk factors are common (Table 1) [14,15]. Treatment outcomes generally vary according to risk stratification, and poorer outcomes are observed in patients with three or more prognostic factors [16]. According to the IMDC and MSKCC prognostic models, more than 50% of patients are stratified into an intermediate-risk group [17]. However, various studies suggest that the intermediate-risk group is heterogeneous, which plays a vital role in treatment selection, patient counselling, and stratification [18,19]. The IMDC model was initially developed and validated as a prognostic model for patients treated with targeted therapy, and the MSKCC model was often used in conventional immunotherapy [20].

**Table 1. Comparison between IMDC and MSKCC prognostic models for risk stratification of mRCC patients [14]**

Risk factors	Values	IMDC	MKCC
KPS	<80	Present	Present
Diagnosis to treatment	<12 months	Present	Present
Hb concentration	<LLN For men: <13.2 g/dL For women: <11.6	Present	Present

---

<sup>l</sup>Lactate Dehydrogenase

	g/dL		
Corrected calcium concentration	>10 mg/dL	Present	Present
Neutrophil count	$7 \times 10^9$	Present	Absent
Platelet count	>400k	Present	Absent
LDH	1.5x normal	Absent	Present
<b>IMDC: International Metastatic Renal Cell Carcinoma Database Consortium; MSKCC: Memorial Sloan Kettering Cancer Centre; Hb: Hemoglobin; KPS: Karnofsky performance status; LLN: Lower limit of normal; RF: Tx: ULN: Upper limit of normal.</b>			

In the current immune checkpoint inhibitor era, the prognostic value of MSKCC and IMDC classifications has emerged as a potential predictive role. It has been used to conceptualise and design recent clinical trials (CABOSUN, Checkmate-214, and CARMENA) with an evolving predictive use of these scores [21].

### ACTIVE SURVEILLANCE

Progression of mRCC can either be rapid or have an indolent course [22]. Active surveillance (AS) is a term used to describe a watchful-waiting period in a subset of the mRCC population before starting systemic therapy. An increase in treatment-induced toxicities leads to impaired quality of life (QOL); hence, AS is a commonly used strategy in mRCC patients with low tumour burden or slow-growing diseases. Evaluation and assessment of comorbid conditions in patients are necessary to stratify the risk of treatment before choosing a management strategy. The multicentre trial study characterised the time to initiate systemic therapy under active surveillance and monitored 52 asymptomatic mRCC patients with a 38-month median follow-up [20]. Patients were assessed radiographically at baseline every three months in the first year, every four months in the second year, and every six months. It concluded that a subgroup of mRCC patients could safely undergo active surveillance before starting systemic therapy [23].

AS is a safe and appropriate alternative approach to immediate systemic treatment in clinical practice [23]. An extensive study done by Harrison et al. in 2021 provided beneficial evidence to define the population and outcomes in which AS can be considered [23]. The study included 504 patients with mRCC, initially managed by AS or systemic therapy. The disease was present in 69% of patients who received AS, whereas the remaining 31% had no evidence of disease. In the MaRCC study, AS was the initial management strategy in >25% (n = 143) of enrolled patients, with a median follow-up of 33 months from enrolment. However, follow-up was too short to assess long-term outcomes; the median overall survival (OS) has still not been reached in the AS cohort compared with 30 months median OS in the systemic therapy cohort [23]. Therefore, a considerable number of mRCC patients can be safely spared from treatment-induced toxicities and impaired QOL associated with systemic therapies for a

substantial duration. However, more research is required to identify relevant clinical and laboratory factors, including biomarkers, for more accurate and standardised characterisation of AS patients.

## **TREATMENT PARADIGM BASED ON INDIVIDUAL FACTORS**

Metastatic RCC is a complex disease with different prognostic factors, stages, and therapeutic options. The following discussion will assist in developing an individual treatment paradigm for mRCC patients based on specific clinical factors [24].

## **PATIENT SELECTION FOR CYTOREDUCTIVE NEPHRECTOMY**

Cytoreductive nephrectomy (CN) had become the standard of care for the management of mRCC for nearly two decades, [25] which is based on the prospective trials of interferon- immunotherapy era, an outdated and inferior treatment modality [26,27]. Before 2006, therapy for mRCC included a single-agent or a combination of cytokine-based regimens (e.g., IFN- $\alpha$  and IL-2) with or without CN. Level 1 evidence supported the use of CN to eradicate the primary tumour in combination with IFN- $\alpha$  [28,29] as it conferred a significant survival advantage over medical therapy alone.<sup>30</sup> Perioperative mortality was 1.4%, and more than 90% of patients undergoing CN received subsequent systemic therapy (ST) [30].

The choice of CN in patients is based on the performance status, which is the most critical factor. The <sup>k</sup>SWOG and <sup>l</sup>EORTC studies reported favourable performance status as an independent predictor of survival [31,32]. The study by Mathieu et al. demonstrated that only patients with an <sup>m</sup>ECOG score of 0 to 1 or a good/intermediate MSKCC prognostic score benefited from CN. On the contrary, patients with an ECOG score of 2 to 3 or poor MSKCC score did not take advantage of CN. Therefore, it is unclear whether this population benefits from CN or not [33]. In SWOG and EORTC trials, 20-25% of patients with poor performance showed limited survival [34].

The <sup>n</sup>EAU 2021 guidelines recommend CN for patients with good ECOG PS (0–1), large primary tumours, and low metastatic volume. In addition, these guidelines do not recommend CN use in patients with poor performance status (PS) or intermediate to poor risk diseases, small primary tumours, significant metastatic burden, or sarcomatoid tumours [35]. Another functional paradigm involves identifying preoperative risk factors as a predictor of better outcomes. A retrospective study identified seven preoperative factors that correlate with median overall survival (OS): elevated lactate dehydrogenase (LDH), decreased albumin, symptomatic metastases, liver metastases, retroperitoneal metastases, supradiaphragmatic metastases, and stage T3 or above [36]. Patients with  $\geq 4$  of these factors do not benefit from CN when compared to patients having  $\leq 3$  factors. According to the ESMO 2021, which has been adopted Pan-Asia, CN is recommended for patients with good PS, low metastatic burden, and symptomatic primary tumours either as up-front surgery or delayed nephrectomy [8,9].

---

<sup>k</sup> Southwest Oncology Group

<sup>l</sup> European Organisation for Research and Treatment of Cancer

<sup>m</sup> Eastern Cooperative Oncology Group

<sup>n</sup> European Association of Urology

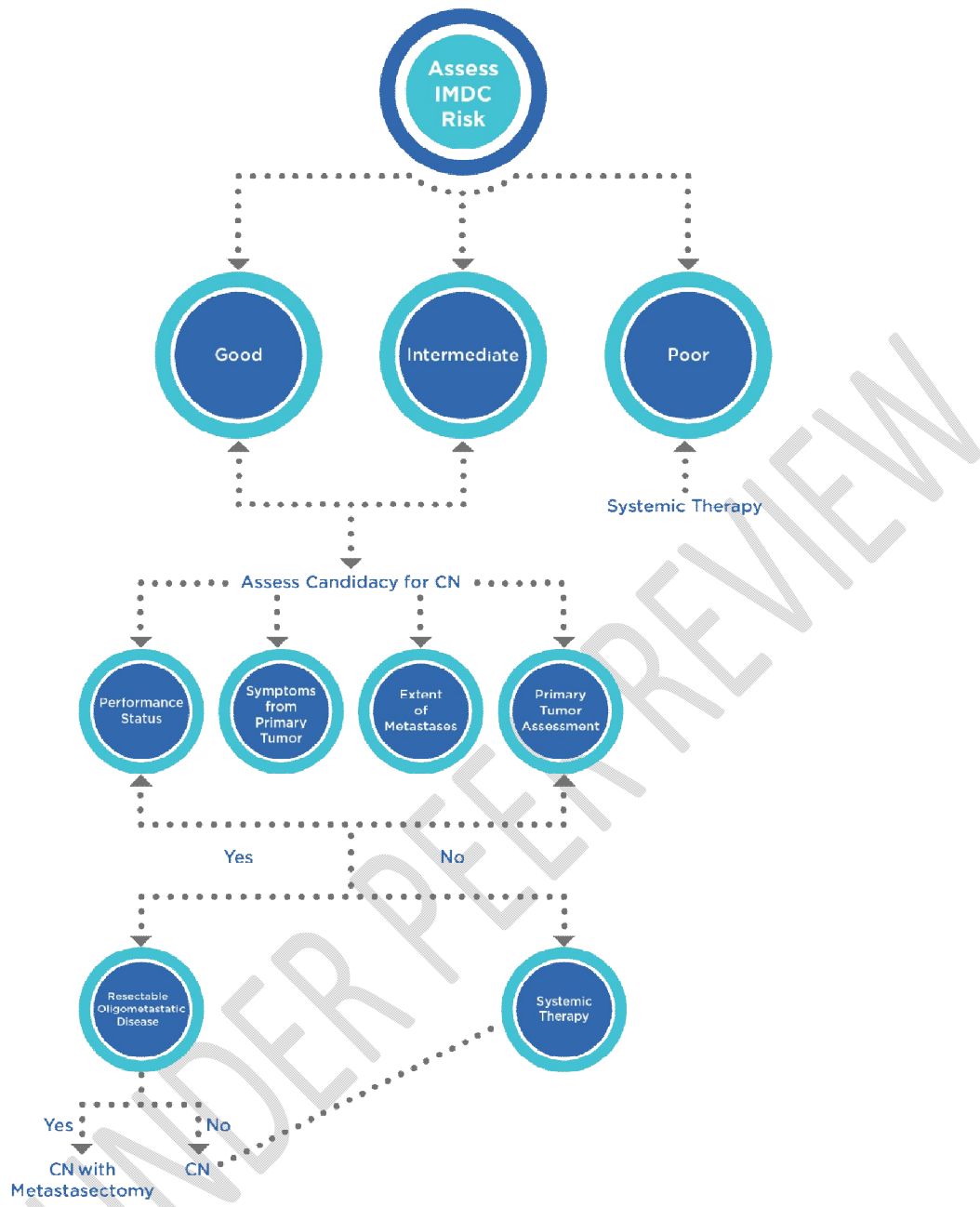
Bex and colleagues examined 16 patients with mRCC treated initially with two courses of IL-2 and interferon- $\alpha$  [37]. Five of these patients progressed and did not require surgery, whereas the remaining patients underwent CN, followed by additional immunotherapy with a mean OS of 11.5 months. The results were compared to the CN arm survival in the SWOG and EORTC trials. This demonstrated that cytokine therapy might determine the subset of patients who are unlikely to benefit from surgery, thereby protecting them from morbidity. The SURTIME trial, in which deferred CN was part of the study design, indicated that 83% of patients treated initially with sunitinib, followed by CN, had fewer surgical complications than patients who underwent CN first [24].

### **PATIENT SELECTION FOR METASTASECTOMY**

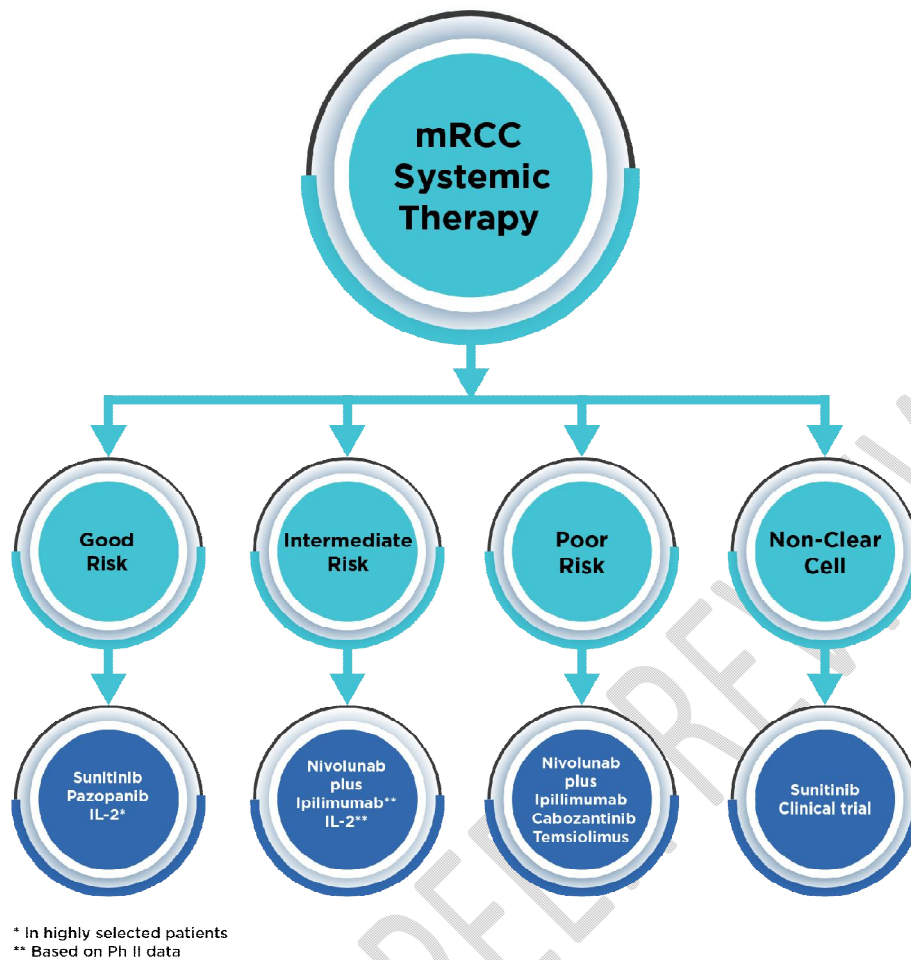
A disease-free interval of more than 12 months from treating the primary tumour to metastasis is essential in predicting favourable outcomes after metastasectomy. Other components that influence results are sites of metastasis, number of metastases, and ability to complete resection. The importance of complete resection is shown in a retrospective study in which all patients had multiple sites of metastasis, and only 14% of patients could undergo complete surgical resection [38]. A more prolonged cancer-specific survival was observed in patients with complete resection, particularly in cases of lung-only metastases. However, patients with multiple metastases involving organs other than the lung also benefited from complete resection [24]. A study reported the clinical benefit of metastasectomy in 44 patients across all three MSKCC risk categories in synchronous and metachronous metastatic settings. It revealed that metastasectomy were each independently associated with more favourable survival [39]. A study by Kavolius and colleagues reported that lung metastases, solitary metastases, and age less than 60 were independently predictive of improved survival with metastasectomy [40]. Another study found good-risk stratification by MSKCC criteria and patients undergoing metastasectomy were independently associated with improved survival [39].

### **PATIENT SELECTION FOR SYSTEMIC THERAPY**

Clinical risk characterisation and histologic subtype are essential for optimising systemic mRCC therapy as an individualised treatment approach [24]. Figures 2 & 3 provide an approach for selecting treatment in mRCC patients with a primary tumour, systemic treatment naïve, and a failed first-line therapy.



**Figure 2: Treatment approach for a newly diagnosed patient with mRCC.**



**Figure 3: Systemic treatment option for mRCC**

### PATIENT SELECTION FOR IMMUNOTHERAPY-BASED COMBINATION THERAPY

For the management of mRCC, combination therapies with immune checkpoint inhibitors and/or anti-angiogenic agents have been demonstrated to have good synergy as a treatment option [41]. In the IMDC risk stratification for intermediate and poor-risk patients, checkpoint inhibitor combinations such as ipilimumab with nivolumab and pembrolizumab with axitinib have improved response and overall survival (OS) in the first-line setting [42]. Furthermore, for IMDC favourable-risk patients, axitinib with pembrolizumab or single-agent VEGF inhibitors such as pazopanib and sunitinib are preferred as a first-line treatment [43]. Moreover, based on improved response rate (RR) and progression-free survival (PFS), combination therapy of axitinib and avelumab acts as an alternative option in a first-line setting [44]. According to the ESMO 2021 guidelines, a combination of axitinib and pembrolizumab is used as first-line therapy for patients with advanced diseases, irrespective of IMDC prognostic subgroups PD-L1 biomarker [8]. Figure 2 elucidates the first-line treatment approach for mRCC.

PD-1/PD-L1 targeted immune checkpoint inhibitors (ICI) have supplanted IFN- $\alpha$  and high-dose IL2 and have become the preferred immunotherapeutic agent for the treatment of mRCC [45]. Table 1 summarises selected randomised trials that established standard of care options in mRCC [46]. The CheckMate-214 trial has shown superiority for nivolumab/ipilimumab over sunitinib in patients with IMDC intermediate/ poor risk mRCC [47]. Updated results of this trial indicated a persistent OS benefit favouring nivolumab/ipilimumab in intermediate-/poor risk groups.

In the Javelin-101 Renal trial, 886 patients were enrolled, 442 randomised to the avelumab plus axitinib arm and 444 to the sunitinib arm. After a minimum follow-up of 13 months, PFS was significantly longer in the avelumab plus axitinib arm than in the sunitinib arm median of 13.8 versus 7.0 months and concluded the superiority of avelumab /axitinib (VEGFR-TKI) over sunitinib for mRCC patients regardless of PD-L1 status [48].

In the KEYNOTE-426 study, the combined effect of pembrolizumab plus axitinib showed improved OS, PFS and ORR in the first interim analysis compared with sunitinib.<sup>42</sup> Nevertheless, across all IMDC risk categories, a combination of an ICI with VEGFR-TKI such as axitinib/pembrolizumab is considered the most preferred treatment option [42].

In addition, in phase 3 randomised trial, 651 patients with previously untreated clear-cell, advanced renal-cell carcinoma (aRCC) received either nivolumab plus cabozantinib (323 patients) or sunitinib (328 patients). Cabozantinib plus nivolumab also showed significantly improved PFS, OS and better quality of life in treatment-naïve RCC patients compared to sunitinib [49].

Furthermore, in patients with IMDC-Int or IMDC-Poor risk disease, nivolumab/ipilimumab is considered a reasonable option. In addition, while offering nivolumab/ipilimumab upfront, some clinicians choose to preserve the introduction of VEGF-TKI therapy for second-line settings in IMDC-Intermediate and IMDC-Poor disease status. However, the impact of the sequencing of VEGFR-TKI in anti-PD-1/PD-L1 era has not been adequately investigated. Therefore, dual immunotherapy (ipilimumab/nivolumab, IO/IO) and immunotherapy/tyrosine kinase inhibitor (IO/TKI) combinations (pembrolizumab/axitinib) are recommended as first-line therapy for intermediate/poor risk mRCC patients [24]. According to the CLEAR trial, lenvatinib plus pembrolizumab was associated with significantly longer progression-free survival and overall survival than sunitinib in intermediate/poor risk mRCC patients. Hence, this combination can also be recommended as first-line therapy for intermediate/poor risk mRCC patients [50]. In addition, a multicentre phase II trial studied atezolizumab and bevacizumab and demonstrated safety and OR in patients with variant histology RCC or RCC with  $\geq 20\%$  sarcomatoid differentiation—this regimen warrants additional exploration in patients with rarer histological variants of RCC, particularly those with PD-L1-positive tumours [51].

In India, the standard management practice for mRCC patients is sunitinib or pazopanib in the first-line setting and everolimus as the disease progresses. In real-world scenarios, especially in low-middle income countries (LMIC), only a small number of patients can receive a combination of IOs in the first row. The use of IO in resource-constrained configurations is primarily restricted to later treatment lines. A study reported that only 1.61% of patients with advanced, i.e., relapsed or

metastatic solid tumours had an approved indication for IO use [52]. In the pre-IO era, the results of second-line treatment were disappointing, and a study by Zanwar S et al., 2016 showed 3.5 months of event-free survival and 6.2 months of OS for second-line targeted therapy for patients with mRCC [53].

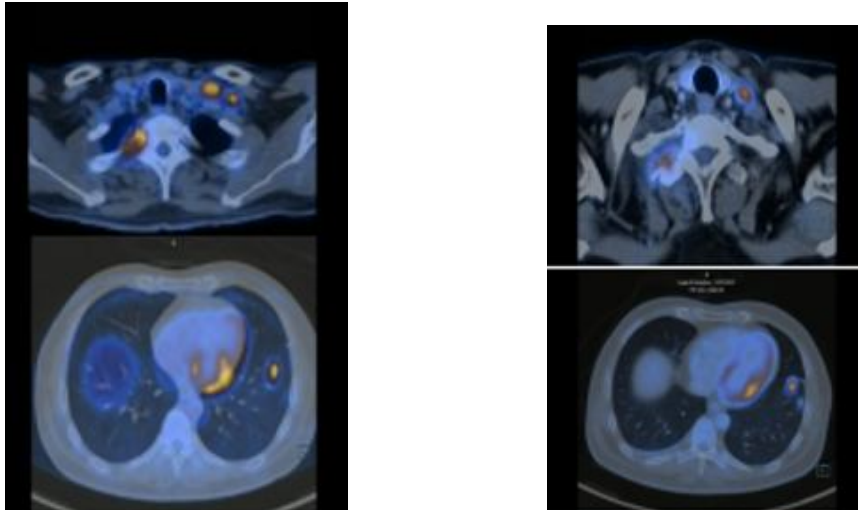
CheckMate 025 trial led to the nivolumab approval in the second-line setting for mRCC post-TKI [54]. Patients receiving IO in the first line and TKI are selected for second-line therapy or beyond becomes intriguing given the absence of data in this setting. Patients receiving pembrolizumab plus axitinib might develop resistance to VEGFR-targeted therapies [55]. Cabozantinib has activity against RET, AXL, MET, and TIE-2 besides VEGFR-1-3, making it a plausible option post IO + TKI; [56]; however, cabozantinib has limited availability in the LMICs. Another combination therapy can be considered in such a scenario, such as everolimus plus lenvatinib. Lenvatinib is known for its activity against RET, KIT, PDGFR and VEGFR-1-3 [57]. It is well known that activating the mTOR pathway is a mechanism for RCC development. Therefore, lenvatinib and everolimus combination seems to be a good choice. In the phase-II trial, 153 patients were randomly assigned to receive either lenvatinib plus everolimus or lenvatinib or everolimus. In case of median PFS, lenvatinib plus everolimus was more significant than that for single-agent everolimus and single-agent lenvatinib [58].

The study provides small but real-world data on IO as second-line therapy for mRCC patients treated with VEGFR TKIs in the first line. Out of all eligible patients, 38% (19/50) received IO. Though this number is low compared to that reported from the western countries; however, it is still much higher than that reported by the previous real-world studies of IO from India. In this study, data were obtained from a single centre, and the percentage of patients receiving IO is highly dependent on the patient's economic status. In this study, the median PFS and OS of the mRCC patients receiving nivolumab in the second line were eight months and 13 months, respectively, while the ORR was 26.3%. It should be noted that the median OS in this study was nearly half of that in the CheckMate 025 study (25.8 months [95% CI, 22.2–29.8]) [59].

### **CASE STUDY 1: A 48-year-old male was diagnosed with renal cell carcinoma with a high visceral disease burden.**

A forty-eight-year-old man was diagnosed with renal cell carcinoma in 2013 with no history of smoking and other comorbidities. He underwent a right radical nephrectomy in April 2013. The tissue dissected was sent for the histochemical examination, revealing clear cell carcinoma, grade II. Since then, the patient was provided with appropriate treatment and was on regular follow up and doing well. After a few years, the patient returned to the hospital in December 2020 with slurred speech and focal convulsion complaints. Again, the patient was directed towards evaluation with PET CT and MRI Scan. Patient had multiple brain lesions/metastasis visualised on MRI. In addition, PET-CT revealed multiple lungs, lymph nodal, adrenal and brain metastasis. However, there was no local recurrent lesion in the right renal fossa. The patient was prescribed immunotherapy from Jan 2021 with pembrolizumab 100mg and Tab. Axitinib 5mg BD every three weeks. The patient has well tolerated the treatment and was doing well.

During the first follow up in April 2021, a partial response to the treatment (4 cycles to date) was demonstrated via PET CT scan reports, as shown in figure 1. Hence, the patient was advised to continue the treatment, and the responses were evaluated at regular intervals in July 2021, Dec 2021 and April 2022. The patient follow-up results show a partial response to the treatment, as shown in figure 2.



Case1: Figure 1: PET-CT revealed multiple lungs, lymph nodal, adrenal and brain metastasis; Figure 2: PET-CT revealed partial response to the treatment.

**Table 2: Pivotal trials in the treatment advancement [24, 49, 50]**

Pivotal Trial	Year	No.	Response Rate (%)	Median PFS (Mo)	Median OS (Mo)
Sunitinib vs IFN- $\alpha$	2007	750	47 vs 12	11 vs 5	26.4 vs. 21.8
Pazopanib vs sunitinib	2013	1,110	31 vs. 25	8.4 vs 9.5	28.4 vs 29.3
Cabozantinib vs Sunitinib (poor/intermediate risk)	2017	157	46 vs 18	8.2 vs 5.6	30 vs. 21.8
Temsirolimus vs IFN- $\alpha$	2007	626	8.6 vs 4.8	5.5 vs 3.1	10.9 vs. 7.3
Nivolumab/ipilimumab vs sunitinib	2018	1,070	41.6 vs 26.5	11.5 vs 8.4	NR vs 26
Avelumab/axitinib vs Sunitinib	2019	886	55 vs 25.5	13.8 vs 8.4	NR
Pembrolizumab/axitinib vs Sunitinib	2019	840	59 vs 36	15 vs 11	NR
Nivolumab / Cabozantinib vs sunitinib	2021	651	55.7 vs 22.0	10.9 vs 4.2	NR vs 19.7
Pembrolizumab/ Lenvatinib	2021	1069	71 vs 36.1	23.9 vs 9.2	NR

vs Sunitinib					
--------------	--	--	--	--	--

**Table 3: Adverse events reported by pivotal trials [49,50,92]**

	Nivolumab <sup>13</sup>	Pembrolizuma b <sup>14</sup>	Nivolumab + ipiilimumab <sup>17</sup>	Pembrolizuma b + axitinib <sup>28</sup>	Avelumab axitinib <sup>26</sup>	Atezolizumab + bevacizumab <sup>20</sup>	Nivolumab + cabozantinib	Lenvatinib plus Pembrolizuma b <sup>15</sup>
Trial	CheckMat e-025	KEYNOTE -427	CheckMat e-214	KEYNOTE -426	JAVELIN RENAL 101	IMmotion- 151	CheckMat e-9ER	CLEAR
Fatigue	2.50%	--	4%	2.80%	3.50%	4.30%	3.4%	4.3%
Rash	<1%	1.80%	1%	0.20%	0.50%	Not reported	1.9%	--
Palmar-plantar erythrodysesthe sia	--	--	--	5.10%	5.80%	--	7.5%	4%
Hypertension	--	--	<1%	22.10%	25.60%	13.90%	34.7%	27.6%
Proteinuria	--	--	--	2.80%	--	<3%	2.8%	7.7%
Diarrhoea	1.20%	3.60%	4%	9.10%	6.70%	22%	6.9%	9.7%
Transaminitis	--	1.80%	--	--	--	Not reported	--	Not reported
AST elevation	--	Not reported	--	13.30%	6%	Not reported	3.4%	Not reported
ALT elevation	--	Not reported	--	7%	3.90%	Not reported	5.3%	Not reported
Colitis	--	2.70%	--	--	--	--	--	Not reported
Anaemia	1.80%	--	<1%	0.70%	1.60%	--	1.9%	Not reported
Thyroid dysfunction	--	--	<1%	0.2	0.2	Not reported	0.3%	1.4%
Pneumonitis	1.50%	0.90%	--	0.20%	--	--	--	--

## BEYOND FIRST-LINE TREATMENT OF METASTATIC RENAL CELL CARCINOMA

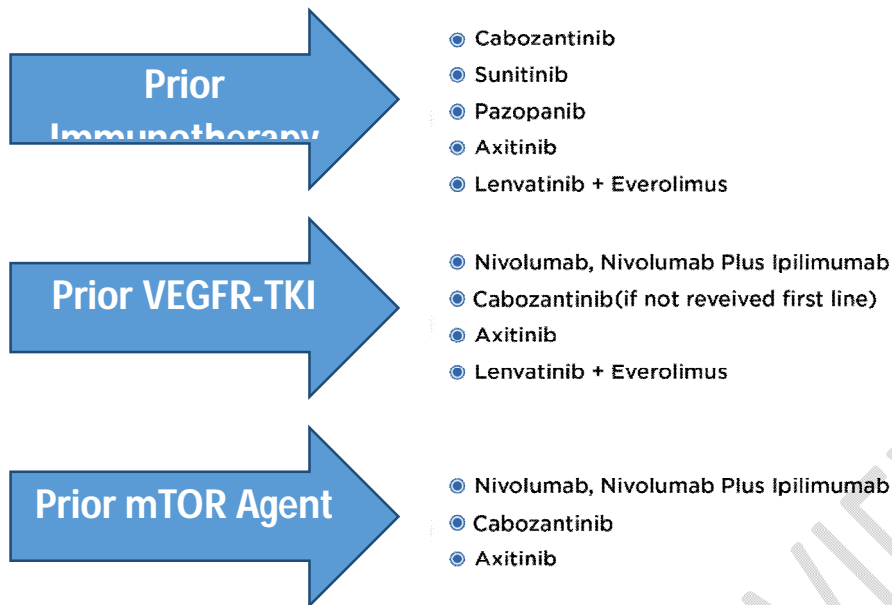
The disease management after first-line therapy, particularly after receipt of ICI, requires consideration of many diseases- and patient-related factors for better overall survival of mRCC patients [60].

## PATIENT SELECTION FOR SECOND-LINE THERAPY AND BEYOND

If disease progression is confirmed, switching to an alternative class of agents is recommended. If ICI is used in the first line, a TKI is preferred; the only available data in this setting is from a phase-II trial for axitinib, [61] though subgroup analysis of the phase III METEOR trial showed activity for cabozantinib in the post-ICI setting [62]. If single-agent TKI is used in first-line therapy, data from CheckMate-025 support the use of nivolumab as a second line [63]. However, the combination of ipilimumab/nivolumab is also used in practice [64]. In mRCC patients, if the disease progresses beyond first-line therapy, clinical risk stratification becomes less critical in decision making, and prior systemic therapy becomes the most crucial factor (figure 4). Although nivolumab with ipilimumab has been adopted recently, there is little evidence regarding therapy sequence after exposure to ICI therapy. However, a small retrospective study indicates that VEGF TKIs can have efficacy after exposure to anti-PD-1 therapy [65]. Thus, VEGF TKI is considered the preferred treatment in patients who have progressed on a combination of nivolumab and ipilimumab.

Individualised axitinib dosing in patients with mRCC previously treated with checkpoint inhibitors did not meet the prespecified threshold for PFS. However, a multicentre, phase 2 trial of axitinib data showed a feasible individualised titration scheme with robust clinical activity and warranted consideration of axitinib in this setting [62]. In the phase-III AXIS study, axitinib showed a prolonged PFS compared to sorafenib in aRCC patients previously treated with sunitinib or cytokines. However, responses to previous treatments did not affect the outcome of axitinib or sorafenib as second-line treatment. In addition, PFS was significantly longer in axitinib-treated patients who had been previously treated with cytokines and in sorafenib-treated patients who had less tumour volume after sunitinib [66]. In addition, cabozantinib as a second-line therapy showed improved PFS and OS compared to everolimus in VEGF-TKI pre-treated patients [58,67]. The combination of lenvatinib/everolimus improves PFS compared to everolimus as a second-line treatment in mRCC patients [68]. Although there is limited experience with the optimal second-line treatment after temsirolimus in the first-line setting, patients are currently treated with second-line VEGF TKIs such as cabozantinib or axitinib with nivolumab. Again, combining nivolumab and ipilimumab may be considered. Everolimus has been relegated to the third-line (and beyond) setting due to trials demonstrating superior efficacy of cabozantinib and nivolumab. However, it remains an option for patients who have not previously received an mTOR inhibitor [49].

According to the ESMO guidelines, TKIs, such as nivolumab or cabozantinib, are recommended for second-line treatment. The combination of lenvatinib/everolimus is FDA- and EMA-approved after TKI failure and is used for progression after first-line TKI monotherapy or a TKI combined with an ICI. In addition, either cabozantinib or nivolumab is considered in patients treated with two lines of TKI therapy and those who show disease progression [8,9].



**Chart 1: Approach for second-line treatment for patients with mRCC**

**Case 2: A 58-year-old female diagnosed with right renal cell carcinoma having progressed on first-line therapy.**

A 58-year-old female was diagnosed with right renal cell cancer in August 2020. She underwent a right radical nephrectomy in August 2020. Subsequently, a CT scan was performed for the whole abdomen with contrast revealed multiple peritoneal metastatic deposits, retroperitoneal lymphadenopathy, soft tissue metastatic deposits in the right lateral abdominal wall and bilateral gluteal muscles- pulmonary and left adrenal metastases.

PET CT done after four months showed an ill-defined intensely hypermetabolic pulmonary nodule involving the left upper lobe-hypermetabolic pulmonary, lymphatic, adrenal and diffuse soft tissue metastases and skin nodule in the left occipital region.

She was started on Tab Pazopanib in December 2020, which was given till May 2021, when she had disease progression with the development of pleural effusion requiring pleural drainage and pleurodesis.

From May 2021 to July 2021, she was started on Tab Lenvatinib, and Tab Everolimus which were given till July 2021 and the disease continued to progress. Meanwhile, patient was counselled for immunotherapy, and she finally agreed to immunotherapy-based treatment in July 2021. Subsequently started on Inj Nivolumab and Cabozantinib 40mg combination from July 2021 onwards. Good response and still ongoing response with regression of pleural fluid and metastatic lesions as documented on PET scan in April 2022.

**SYSTEMIC TREATMENT CONSIDERATIONS BASED ON HISTOLOGY**

Non-clear cell RCC (nccRCC) accounts for approximate 20% of renal cell carcinoma [69] and is primarily excluded or underrepresented in clinical trials evaluating systemic therapy, leading to

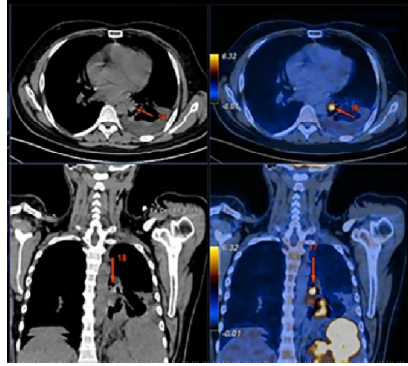
challenges in developing a management strategy. Two small-randomised phase 2 trials compared sunitinib to everolimus in patients with nccRCC and ccRCC patients [67,70]. Both suggested an OS and PFS benefit to sunitinib compared to everolimus in these patients. Thus, sunitinib should be strongly considered the initial therapy in patients with nccRCC, while mTOR inhibitors can be utilised in TKI-refractory settings. Trials establishing the efficacy of nivolumab and nivolumab plus ipilimumab in mRCC excluded nccRCC patients [71]. However, a small retrospective study in patients with nccRCC, who received nivolumab, showed responses to therapy on par with clear cell disease [72]. Thus, more studies are required to establish the use of nivolumab with or without ipilimumab in nccRCC patients. The PAMMET trial in metastatic papillary RCC patients demonstrated that cabozantinib is the preferred TKI, likely because of its MET-inhibitory properties [73]. Similarly, another study reported the benefits of savolitinib in papillary RCC patients, although completion of such trials has been challenging.<sup>74</sup> According to the ESMO guidelines, cabozantinib is the preferred first-line agent in patients with advanced papillary RCC [8]. Succinate dehydrogenase-associated RCC can be histologically composed of clear cell, chromophobe, or papillary RCC. Genomic profile of chromophobe RCC, which often has mutations that upregulate mTOR pathways, the use of the mTOR inhibitor everolimus is considered.

Further, small clinical trials have shown the efficacy of anti-VEGF therapy and everolimus combinations—either lenvatinib/everolimus or bevacizumab/everolimus—for patients with advanced chromophobe RCC [75]. The panel recommends enrolment in a clinical trial as a preferred option for these patients. It has been established that specific systemic therapy options recommended for patients with ccRCC may also have some efficacy in those with nccRCC, even in the absence of clinical trial data (NCCN, 2021) [76]. The systemic therapy options for metastatic nccRCC include targeted therapies, such as TKIs, ICIs, and, for specific rare subtypes, mainly collecting duct and medullary carcinomas, cytotoxic chemotherapy [9].

### **CASE STUDY 3: A 40-year-old male diagnosed with an eosinophilic variant of clear cell carcinoma**

A 40 years old man with a history of dry cough, weight loss, weakness and anorexia for one and half months presented initially in November 2019. Upon general examination, his vital signs were in normal range. He had been previously diagnosed with clear cell RCC based on his DICOM data from his previous investigations.

He was advised for a PET CT scan. There were no remarkable abnormalities found in the PET-CT of the head and neck region. However, PET CT of the abdomen and pelvis revealed heterogeneous density mass lesion in retroperitoneal space in the left lumbar region, as shown in figure 1. In addition, the thoracic CT revealed enlarged retroperitoneal and mediastinal lymph nodes along with a soft tissue lesion in the left lower lobe of the lung, prompting the possibility of RCC-lung metastasis.

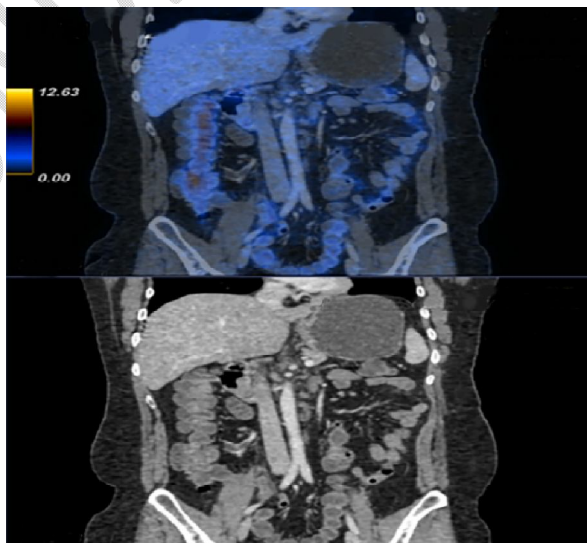


Case 3: Figure 1: PET CT of the abdomen and pelvis revealed heterogeneous density mass lesion in retroperitoneal space in the left lumbar region.

The patient was directed to undergo a biopsy for further diagnosis. Percutaneous image-guided biopsy of renal masses showed features of poorly differentiated carcinoma. After that, immunohistochemical analysis revealed poorly differentiated carcinoma and deposit of renal cell carcinoma; Gradell (Likely eosinophilic variant of Clear cell carcinoma). Therefore, the patient was immediately directed towards neoadjuvant chemotherapy (NACT) and followed that he was prescribed four cycles of axitinib and pembrolizumab.

The patient was called for a review in March 2020 post four treatment cycles. PET-CT was repeated, and the reports revealed a complete metabolic resolution (figure 2) with a significant reduction in the size of exophytic lesions arising from the upper pole of the left kidney and retroperitoneal lymph node and no new lesion was found. Therefore, the patient was instructed to continue eight more chemotherapy sessions with axitinib and pembrolizumab.

In June 2020, the patient was called for a second review, where he underwent a radical nephrectomy. Prominent chemotherapy-related changes were seen. Most of the tumours had been resolved, and there was no viable tumour expression. In addition to these reports, the left radical nephrectomy with left paraaortic lymph node dissection revealed scanty viable clear cell renal cell carcinoma, Fuhrman nuclear grade III. The patient was further advised to continue with the same chemotherapy as an adjuvant till Jan 2022, and during follow up, after two years, the patient continues to do well.



Case 3: Figure 2: PET-CT revealed a complete metabolic resolution with a significant reduction in the size of exophytic lesions arising from the upper pole of the left kidney.

## **MANAGEMENT APPROACH TO SPECIAL PATIENT POPULATION**

### **POOR PERFORMANCE STATUS**

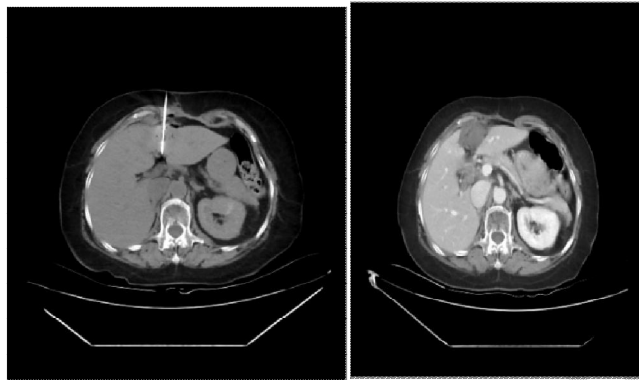
In past years, locally advanced or metastatic cases of RCC with significant laboratory abnormalities, site-related symptomology, and low-performance status resulted in a contraindication for systemic therapy. As the systemic therapy landscape progresses, immunotherapy is added to the first-line treatment for patients of all IMDC risk groups. The findings from CheckMate-214 and CheckMate-040 [47,77] reinforced this recommendation. In these trials, ICI was compared with sunitinib in formerly untreated advanced clear cell RCC patients. In both studies, a significant percentage of patients were stratified as IMDC-Int or IMDC-Poor risk patients. Combination immunotherapy was preferred in both trials, owing to a higher overall response rate, improved quality of life, and more prolonged overall survival seen in patients of all risk groups and levels of tumour PD-L1 expression. Patients with poor-risk diseases getting a combination of nivolumab and ipilimumab showed better responses than those with favourable-risk diseases [57]. Despite more frequent dose modification, elderly patients (>age 70) treated with sunitinib had a satisfactory safety status and similar clinical outcomes compared to younger patients [28]. It is believed that the clinical benefit, manageable toxicities of immunotherapy, and improvements in quality of life seen in practice support its use in patients with low-performance status. Ernst et al. analysed outcomes of patients older than 70 years treated in the first-line setting with ipilimumab, nivolumab, or pembrolizumab, monotherapy or combination. They found that the median OS of patients aged 70–99 years was not significantly different from those aged 50–69 years: 10 vs 11.8 months, respectively [78]. Another study by Hale et al. suggested that the combination of nivolumab and ipilimumab was the most efficacious treatment in terms of both progression-free survival and OS for patients >65 years in the first-line setting compared to VEGF inhibitors as monotherapy [79].

### **CASE STUDY 4: A 68-year-old female diagnosed with metastatic renal cell carcinoma (elderly patient with comorbidities)**

A 68-year-old female with comorbidities such as hypertension, coronary artery disease and transient ischemic attack presented initially in October 2017. She had undergone a radical nephrectomy in 2015 at an outside centre. She was evaluated and was found to have renal bed recurrence. She underwent a right hemicolectomy and tumour bed excision in June 2017 and was started on pazopanib. She was on regular follow up.

In January 2020, she presented with fatigue and melena. She was evaluated and found to have a jejunal lesion. She underwent segmental resection of jejunum. The histopathology was suggestive of metastasis from renal cell carcinoma. She developed liver metastasis in June 2020, for which microwave ablation was done, as shown in Figures 1 and 2. She was then started on everolimus, to which she had poor tolerance. Hence, her regimen was changed to lenvatinib plus pembrolizumab

from October 2020. Currently, she has completed 27 cycles of pembrolizumab. Her response evaluation showed a complete response, and she tolerated treatment well without any grade 3-4 adverse events.



Case 4: Figure 1: Microwave ablation of liver metastasis; Figure 2: Shows patient post-ablation evaluation reports.

### **END-ORGAN DYSFUNCTION**

RCC treatment frequently involves a multimodality approach comprising surgical management and systemic therapy that affects liver and kidney function. The organ dysfunction extent is measured while selecting systemic options; however, most therapies can be administered with close monitoring. Although TKIs cause hepatotoxicity, impaired liver function is not a contraindication for TKI treatment. Studies assessing the administration of sorafenib in hepatocellular carcinoma (HCC) showed that even though outcomes were unlike in patients with Child-Pugh A vs Child-Pugh B liver function, safety and tolerability were similar. A further subgroup analysis in phase III SHARP trial reported that sorafenib showed a safety profile and efficacy in advanced HCC patients despite alterations in baseline liver enzymes [80]. Moreover, patients with Child-Pugh B or C were omitted. Therefore, it is challenging to extrapolate any safety assessment for patients with more progressive diseases. Recent recommendations suggested a decrease in starting dose based on baseline liver function followed by titration based on the tolerability of individuals.

ICI administration has been safe in patients with underlying liver dysfunction. The CheckMate 040 study observed that nivolumab caused objective response rates in phase I/II trials with a controllable safety profile in advanced HCC patients with or without hepatitis B or C [76]. Hence, chronic hepatitis is not considered a contraindication for immunotherapy based on these findings. In KEYNOTE-426, patients in the pembrolizumab/axitinib group were observed to have a higher incidence of grade 3 or 4 liver enzymes elevation and were managed successfully with treatment breaks and corticosteroids.<sup>42</sup> Therefore, immunotherapy can be used safely and effectively in patients with baseline organ dysfunction with appropriate clinical monitoring [81]. A study on pharmacokinetics (PK) of a single sunitinib dose of 50mg in severe renal impairment (RI) subjects with end-stage renal disease (ESRD) was performed [82]. The PK of sunitinib appeared similar to those with normal renal function. However, plasma exposure to sunitinib and its metabolites appeared lower in ESRD subjects

than in subjects with normal or severe RI. In addition, another study by Josephs et al. reported that patients treated with sunitinib with severe RI or ESRD on haemodialysis have PFS compared to patients with normal renal function. Moreover, sunitinib appeared to be reasonably well tolerable without excess toxicities [83].

Thus, newer molecularly targeted agents (MTAs) such as sunitinib, bevacizumab, temsirolimus, and everolimus are well tolerated at standard doses and maintain efficiency in patients with mild to moderate RI. Patients with RI have a more significant increase in blood pressure with sunitinib and bevacizumab and a higher incidence of thyroid dysfunction with sunitinib. However, close monitoring for these specific toxicities is recommended [84].

### **POST-METASTASECTOMY**

Though metastasectomy in advanced RCC has been in clinical practice for several decades, no randomised controlled trials have assessed the clinical benefits of such procedures. The evidence of favourable outcomes mainly came from retrospective case series and case reports in RCC and other solid tumours. A study reported outcomes in patients who underwent metastasectomy at any time. In addition, a complete metastasectomy was independently associated with decreased mortality and better median overall survival compared with incomplete surgery [85]. There are no stringent guidelines for patient selection who will benefit most from metastasectomy surgery. The National Comprehensive Cancer Network (NCCN) guidelines (USA) suggest metastasectomy could be considered in patients with clear cell or non-clear cell histology who initially present with primary RCC and oligometastatic sites or develop oligometastases after a lengthy disease-free interval from nephrectomy [86]. The European Society for Medical Oncology recommends localised surgery upon recommendation by a multidisciplinary team to select patients having good performance status, solitary, or oligometastases; metachronous disease with the disease-free interval (>2 years); absence of disease progression on systemic therapy; or low/intermediate grade with complete resection [87]. Currently, there is no role for systemic adjuvant therapy after reported metastasectomy. A phase III trial conducted by the Eastern Cooperative Oncology Group-American College of Radiology Imaging Network group assessed the role of adjuvant pazopanib vs placebo in patients without disease after metastasectomy [87]. Patients received treatment for 52 weeks with several disease sites of resection and a disease-free interval. There was a trend towards worse overall survival with pazopanib. In addition, negative results were also observed with sorafenib [88]. However, several ongoing trials assess adjuvant sunitinib or checkpoint inhibitors, but currently, there is inadequate data to support their use.

With emerging studies on molecular pathways as predictive markers and the introduction of systemic immunotherapy and targeted therapy, the role of localised surgical intervention and consolidation are unclear. Therefore, the clinical experience of physicians on multidisciplinary teams should guide the recommendations for metastasectomy in advanced RCC patients [8].

### **BRAIN METASTASIS**

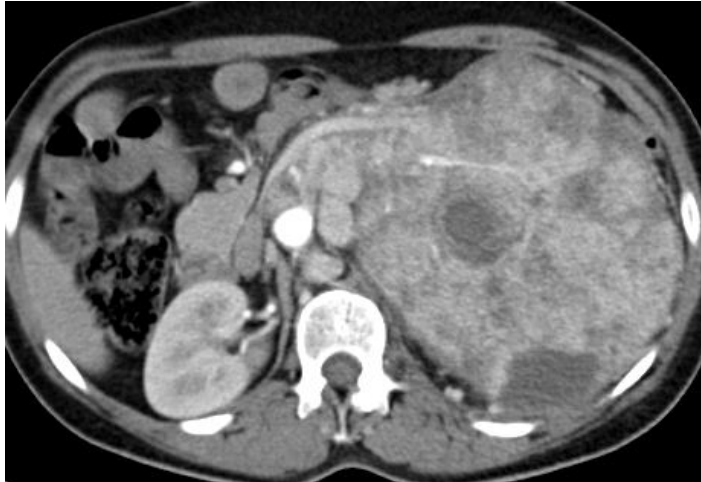Brain metastases happen in approximately 15% of RCC patients, and 6 to 8% of patients present symptomatic lesions. Initially thought to confer a poor prognosis, more active systemic therapies and an increase in the use of stereotactic radiation have produced survival outcomes similar to patients without brain metastases [89]. Corticosteroids are indicated in symptomatic patients, especially those with cerebral oedema and/or brain radiotherapy (whole brain radiotherapy or SRS depending on the number & location of the metastases) or surgery for the brain metastases (preferably single lesion). In addition, antiepileptics should be started in patients with seizures. Based on hypotheses related to neo-angiogenesis essential for metastatic spread to the brain, VEGFR TKIs have reported very modest responses. A phase II study presented no objective responses in sunitinib patients, although central nervous system disease remained stable at 31% [90]. Results with immune checkpoint inhibitors seem more favourable. NIVOREN, a phase II study of second-line nivolumab in untreated, asymptomatic brain metastases patients with RCC, showed an overall response rate of 23% [91]. Both stereotactic radiations to amenable lesions and systemic therapy with immune checkpoint inhibitors showed promising results for RCC patients with brain metastases [24].

#### **CASE STUDY 5: A 29-year-old male diagnosed with clear cell RCC with brain metastasis**

A 29-year-old male presented to a local hospital with complaints of severe headache f/b altered sensorium in Feb 2020. He had a history of headaches and vomiting for the past six months. He was a non-smoker and had no comorbidities. The patient was advised to take an MRI of the brain, which revealed a right frontal lobe space-occupying lesion with perilesional oedema. In addition, the histopathological examination revealed clear cell RCC in the patient. The computed tomography reports of the chest and abdomen also showed heterogeneously enhancing mass lesions measuring 16.7 x 18.8 x 21 cm with left renal hilar and retroperitoneal enlarged mediastinal and supraclavicular lymph nodes. He was then directed to undergo craniotomy, and the brain tumour was excised.

The patient was transferred to TMC, Kolkata, for further evaluation in May 2020. The IMDC risk stratification of the patient indicated intermediate risk. Therefore, therapy was initiated in the patient in June 2020, which included the administration of Inj. Pembrolizumab 200 mg every three weeks and oral administration of axitinib 5 mg b.i.d. He tolerated the therapy well without any significant toxicity, except for grade II hypertension, which was further managed with antihypertensives.

The patient was called for a review post five cycles of pembrolizumab/axitinib chemotherapy and was suggested to take a CT scan and brain MRI. The CT scan report showed partial response, whereas the brain MRI did not reveal any residual or recurrent brain metastasis, as shown in Figures 1 .



Case 5: Figure 1: PET CT revealed of chest and abdomen showed heterogeneously enhancing mass lesions measuring 16.7 x 18.8 x 21 cm with left renal hilar and retroperitoneal enlarged mediastinal and supraclavicular lymph nodes.

Hence, the patient was suggested to continue the therapy. After 19 cycles, the CT scan showed a favourable response to treatment during follow-up. In addition, the MRI brain revealed controlled disease by Dec 2020. The patient is currently doing well till his last follow-up in the first week of April 2022, where he has received 23 cycles of therapy to date.

The treatment of mRCC has been revolutionised after the invention of anti-VEGF TKI and immunotherapy (IO). The combination of IO and anti-VEGF TKI has prolonged overall survival substantially. The current patient achieved long term disease control in CNS disease with a combination of pembrolizumab and axitinib with good quality of life.

## CONCLUSION

Using the IMDC prognostic model, risk stratification remains a beneficial tool for predicting disease outcomes and is an excellent model for initial diagnostic workup for assessing a new patient. Active surveillance may be preferred for certain asymptomatic mRCC patients with slow-growing and low-volume diseases in a favourable risk group. Cytoreductive nephrectomy is beneficial for selected patients evaluated by multidisciplinary tumour experts. Metastasectomy may also be considered in patients with oligometastatic disease. However, prospective trials are required to confirm the benefit.

The introduction of ICI, either as a doublet or in combination therapy with VEGF-TKI, has led to the overall survival of patients with advanced-stage RCC improving remarkably and is rapidly becoming the standard of care in first-line treatment of mRCC. However, most patients eventually require additional lines of treatment and treating oncologists must contemplate judiciously while substituting for another therapy, mainly in conditions of drug intolerance or observable disease progression. Systemic therapy options after ICI are generally TKI-based, and ongoing clinical trials help to optimise the treatment algorithm. Nonetheless, despite many recent drug approvals for mRCC, there remains a pressing need to recognise new therapeutic targets in this disease.

New combination therapies that synergise these two therapeutic modalities or other drug classes are developing, expanding the therapeutic armamentarium of first-line treatments. Advancements in molecular techniques and genomic sequencing have also enabled precise disease prognostication. In addition, diagnostic tools that integrate biomarker data help individualise treatment plans based on distinct biological features. With the advent of newer treatment options in mRCC, more local data from the Indian perspective will be crucial through greater participation in clinical trials and more real-world studies.

The phase III trials for mRCC that are currently enrolling patients include PDIGREE (NCT03793166), COSMIC313 (NCT03937219), and PIVOT-09 (NCT03729245). These trials are anticipated to answer essential questions about intensity and duration of treatment, treatment sequence and discontinuation, and novel immunotherapy combinations. Moreover, the upcoming phase 3 trial PROBE is also expected to address the role of cytoreductive nephrectomy in setting ipilimumab-nivolumab immunotherapies. Treatment selection remains a challenge; however, biomarker development is ongoing. In addition, trials such as BIONIKK are projected to help elucidate treatment strategies tailored to tumour characteristics. Success and outcomes from these contemporary trials would ultimately improve the ability of clinicians to personalise treatments and optimise results for each patient.

## REFERENCES

1. Sung H, Ferlay J, Siegel RL, Laversanne M, Soerjomataram I, Jemal A, Bray F. Global cancer statistics 2020: GLOBOCAN estimates of incidence and mortality worldwide for 36 cancers in 185 countries. *CA: a cancer journal for clinicians*. 2021 May;71(3):209-49.
2. Milanetto AC, Morelli L, Di Franco G, David A, Campra D, De Paolis P, Pasquali C. A plea for surgery in pancreatic metastases from renal cell carcinoma: Indications and outcome from a multicenter surgical experience. *Journal of Clinical Medicine*. 2020 Oct;9(10):3278.
3. Alaghebandan R, Perez Montiel D, Luis AS, Hes O. Molecular genetics of renal cell tumors: A practical diagnostic approach. *Cancers*. 2019 Dec 30;12(1):85.
4. Barata PC, Rini BI. Treatment of renal cell carcinoma: current status and future directions. *CA: a cancer journal for clinicians*. 2017 Nov;67(6):507-24.
5. Heng DY, Xie W, Regan MM, Warren MA, Golshayan AR, Sahi C, Eigel BJ, Ruether JD, Cheng T, North S, Venner P. Prognostic factors for overall survival in patients with metastatic renal cell carcinoma treated with vascular endothelial growth factor-targeted agents: results from a large, multicenter study. *Journal of clinical oncology*. 2009 Dec 1;27(34):5794-9.
6. Kotecha RR, Motzer RJ, Voss MH. Towards individualised therapy for metastatic renal cell carcinoma. *Nature reviews Clinical oncology*. 2019 Oct;16(10):621-33.
7. Libertino JA, Gee JR. *Renal Cancer*. Springer International Publishing; 2020.
8. Powles T. Recent eUpdate to the ESMO Clinical Practice Guidelines on renal cell carcinoma on cabozantinib and nivolumab for first-line clear cell renal cancer: Renal cell carcinoma: ESMO Clinical Practice Guidelines for diagnosis, treatment and follow-up1. *Annals of Oncology*. 2021 Mar 1;32(3):422-3.
9. Yoshino T, Argilés G, Oki E, Martinelli E, Taniguchi H, Arnold D, Mishima S, Li Y, Smruti BK, Ahn JB, Faud I. Pan-Asian adapted ESMO Clinical Practice Guidelines for the diagnosis treatment and follow-up of patients with localised colon cancer. *Annals of Oncology*. 2021 Dec 1;32(12):1496-510.

10. Motzer RJ, Mazumdar M, Bacik J, Berg W, Amsterdam A, Ferrara J. Survival and prognostic stratification of 670 patients with advanced renal cell carcinoma. *Journal of clinical oncology*. 1999 Aug;17(8):2530-.
11. Yip SM, Wells C, Moreira R, Wong A, Srinivas S, Beuselinck B, Porta C, Sim HW, Ernst DS, Rini BI, Yuasa T. Checkpoint inhibitors in patients with metastatic renal cell carcinoma: results from the international metastatic renal cell carcinoma database consortium. *Cancer*. 2018 Sep 15;124(18):3677-83.
12. Kroeger N, Xie W, Lee JL, Bjarnason GA, Knox JJ, MacKenzie MJ, Wood L, Srinivas S, Vaishamayan UN, Rha SY, Pal SK. Metastatic non-clear cell renal cell carcinoma treated with targeted therapy agents: characterisation of survival outcome and application of the International mRCC Database Consortium criteria. *Cancer*. 2013 Aug 15;119(16):2999-3006.
13. Noe A, de Bruijn RE, Blank C, Horenblas S, Haanen J, Bex A. Comparison of pre-treatment MSKCC and IMDC prognostic risk models in patients with synchronous metastatic renal cell carcinoma treated in the era of targeted therapy. *World journal of urology*. 2016 Aug;34(8):1067-72.
14. Doppalapudi SK, Leopold ZR, Thaper A, Kaldany A, Chua K, Patel HV, Srivastava A, Singer EA. Clearing up clear cell: Clarifying the Immuno-Oncology treatment landscape for metastatic clear cell RCC. *Cancers*. 2021 Jan;13(16):4140.
15. Fay AP, Xie WL, Lee JL, Harshman LC, Bjarnason GA, Knox JJ, Ernst S, Wood L, Vaishamayan UN, Yuasa T, Tan MH. Characteristics of long-term and short-term survivors of metastatic renal cell carcinoma treated with targeted therapies: results from the International mRCC Database Consortium. *Clinical genitourinary cancer*. 2015 Apr 1;13(2):150-5.
16. Iacovelli R, De Giorgi U, Galli L, Zucali P, Nolè F, Sabbatini R, Fraccon AP, Basso U, Mosca A, Atzori F, Santini D. Is it possible to improve prognostic classification in patients affected by metastatic renal cell carcinoma with an intermediate or poor prognosis?. *Clinical genitourinary cancer*. 2018 Oct 1;16(5):355-9.
17. Rini BI, Hutson TE, Figlin RA, Lechuga MJ, Valota O, Serfass L, Rosbrook B, Motzer RJ. Sunitinib in patients with metastatic renal cell carcinoma: clinical outcome according to international metastatic renal cell carcinoma database consortium risk group. *Clinical genitourinary cancer*. 2018 Aug 1;16(4):298-304.
18. Sella A, Michaelson MD, Matczak E, Simantov R, Lin X, Figlin RA. Heterogeneity of patients with intermediate-prognosis metastatic renal cell carcinoma treated with sunitinib. *Clinical Genitourinary Cancer*. 2017 Apr 1;15(2):291-9.
19. Kim JK, Kim SH, Song MK, Joo J, Seo SI, Kwak C, Jeong CW, Song C, Hwang EC, Seo IY, Lee H. Survival and clinical prognostic factors in metastatic non-clear cell renal cell carcinoma treated with targeted therapy: A multi-institutional, retrospective study using the Korean metastatic renal cell carcinoma registry. *Cancer medicine*. 2019 Jul;8(7):3401-10.
20. Rini BI, Dorff TB, Elson P, Rodriguez CS, Shepard D, Wood L, Humbert J, Pyle L, Wong YN, Finke JH, Rayman PA. Active surveillance in metastatic renal-cell carcinoma: a prospective, phase 2 trial. *The Lancet Oncology*. 2016 Sep 1;17(9):1317-24.
21. Guida A, Le Teuff G, Alves C, Colomba E, Di Nunno V, Derosa L, Flippot R, Escudier B, Albiges L. Identification of International Metastatic Renal Cell Carcinoma Database Consortium (IMDC) intermediate-risk subgroups in patients with metastatic clear-cell renal cell carcinoma. *Oncotarget*. 2020 Dec 8;11(49):4582.
22. Crispen PL, Viterbo R, Boorjian SA, Greenberg RE, Chen DY, Uzzo RG. Natural history, growth kinetics, and outcomes of untreated clinically localised renal tumors under active surveillance. *Cancer*. 2009 Jul 1;115(13):2844-52.
23. Harrison MR, Costello BA, Bhavsar NA, Vaishampayan U, Pal SK, Zakharia Y, Jim HS, Fishman MN, Molina AM, Kyriakopoulos CE, Tsao CK. Active surveillance of metastatic renal cell carcinoma: Results from a prospective observational study (MaRCC). *Cancer*. 2021 Jul 1;127(13):2204-12.

24. Tenold M, Ravi P, Kumar M, Bowman A, Hammers H, Choueiri TK, Lara Jr PN. Current approaches to the treatment of advanced or metastatic renal cell carcinoma. *American Society of Clinical Oncology Educational Book*. 2020 Apr 2;40:187-96.
25. Bamias A, Escudier B, Sternberg CN, Zagouri F, Dellis A, Djavan B, Tzannis K, Kontovinis L, Stravodimos K, Papatsoris A, Mitropoulos D. Current clinical practice guidelines for the treatment of renal cell carcinoma: a systematic review and critical evaluation. *The oncologist*. 2017 Jun;22(6):667-79.
26. Escudier B, Bellmunt J, Négrier S, Bajetta E, Melichar B, Bracarda S, Ravaud A, Golding S, Jethwa S, Sneller V. Phase III trial of bevacizumab plus interferon alfa-2a in patients with metastatic renal cell carcinoma (AVOREN): final analysis of overall survival. *J Clin Oncol*. 2010 May 1;28(13):2144-50.
27. Hudes G, Carducci M, Tomczak P, Dutcher J, Figlin R, Kapoor A, Staroslawska E, Sosman J, McDermott D, Bodrogi I, Kovacevic Z. Temsirolimus, interferon alfa, or both for advanced renal-cell carcinoma. *New England Journal of Medicine*. 2007 May 31;356(22):2271-81.
28. Flanigan RC, Salmon SE, Blumenstein BA, Bearman SI, Roy V, McGrath PC, Caton Jr JR, Munshi N, Crawford ED. Nephrectomy followed by interferon alfa-2b compared with interferon alfa-2b alone for metastatic renal-cell cancer. *New England Journal of Medicine*. 2001 Dec 6;345(23):1655-9.
29. Mickisch GH, Garin A, Van Poppel H, de Prijck L, Sylvester R. Radical nephrectomy plus interferon-alfa-based immunotherapy compared with interferon alfa alone in metastatic renal-cell carcinoma: a randomised trial. *The Lancet*. 2001 Sep 22;358(9286):966-70.
30. Flanigan RC, Mickisch G, Sylvester R, Tangen C, Van Poppel H, Crawford ED. Cytoreductive nephrectomy in patients with metastatic renal cancer: a combined analysis. *The Journal of urology*. 2004 Mar;171(3):1071-6.
31. Lara Jr PN, Tangen CM, Conlon SJ, Flanigan RC, Crawford ED. Predictors of survival of advanced renal cell carcinoma: long-term results from Southwest Oncology Group Trial S8949. *The Journal of urology*. 2009 Feb 1;181(2):512-7.
32. Logan T, McDermott DF, Dutcher JP, Makhson A, Mikulas J, Berkenblit A, Galand L, Krygowski M, Hudes GR. Exploratory analysis of the influence of nephrectomy status on temsirolimus efficacy in patients with advanced renal cell carcinoma and poor-risk features. *Journal of Clinical Oncology*. 2008 May 20;26(15\_suppl):5050-.
33. Mathieu R, Pignot G, Ingles A, Crepel M, Bigot P, Bernhard JC, Joly F, Guy L, Ravaud A, Azzouzi AR, Gravis G. Nephrectomy improves overall survival in patients with metastatic renal cell carcinoma in cases of favorable MSKCC or ECOG prognostic features. *In Urologic Oncology: seminars and original investigations 2015 Aug 1 (Vol. 33, No. 8, pp. 339-e9)*. Elsevier.
34. Halbert RJ, Figlin RA, Atkins MB, Bernal M, Hutson TE, Uzzo RG, Bukowski RM, Khan KD, Wood CG, Dubois RW. Treatment of patients with metastatic renal cell cancer: a RAND Appropriateness Panel. *Cancer*. 2006 Nov 15;107(10):2375-83.
35. Bex A, Ljungberg B, van Poppel H, Powles T, European Association of Urology. The role of cytoreductive nephrectomy: European Association of Urology Recommendations in 2016. *European urology*. 2016 Dec 1;70(6):901-5.
36. Culp SH, Tannir NM, Abel EJ, Margulis V, Tamboli P, Matin SF, Wood CG. Can we better select patients with metastatic renal cell carcinoma for cytoreductive nephrectomy?. *Cancer*. 2010 Jul 15;116(14):3378-88.
37. Bex A, Horenblas S, Meinhardt W, Verra N, De Gast GC. The role of initial immunotherapy as selection for nephrectomy in patients with metastatic renal cell carcinoma and the primary tumor in situ. *European urology*. 2002 Dec 1;42(6):570-6.
38. Alt AL, Boorjian SA, Lohse CM, Costello BA, Leibovich BC, Blute ML. Survival after complete surgical resection of multiple metastases from renal cell carcinoma. *Cancer*. 2011 Jul 1;117(13):2873-82.

39. Eggener SE, Yossepowitch O, Kundu S, Motzer RJ, Russo P. Risk score and metastasectomy independently impact prognosis of patients with recurrent renal cell carcinoma. *The Journal of urology*. 2008 Sep;180(3):873-8.
40. Kavolius JP, Mastorakos DP, Pavlovich C, Russo P, Burt ME, Brady MS. Resection of metastatic renal cell carcinoma. *Journal of Clinical Oncology*. 1998 Jun;16(6):2261-6.
41. Hara T, Miyake H, Hinata N, Fujisawa M. Inhibition of tumor growth and sensitisation to Sunitinib by RNA interference targeting programmed death-ligand 1 in mouse renal cell carcinoma RenCa model. *Anticancer Research*. 2019 Sep 1;39(9):4737-42.
42. Rini BI, Plimack ER, Stus V, Gafanov R, Hawkins R, Nosov D, Pouliot F, Alekseev B, Soulières D, Melichar B, Vynnychenko I. Pembrolizumab plus axitinib versus sunitinib for advanced renal-cell carcinoma. *New England Journal of Medicine*. 2019 Mar 21;380(12):1116-27.
43. Deng H, Huang Y, Hong Z, Yuan X, Cao Z, Wei Y, Zhang W. Pazopanib has equivalent anti-tumor effectiveness and lower Total costs than sunitinib for treating metastatic or advanced renal cell carcinoma: a meta-analysis. *BMC cancer*. 2019 Dec;19(1):1-2.
44. Motzer RJ, Penkov K, Haanen J, Rini B, Albiges L, Campbell MT, Venugopal B, Kollmannsberger C, Negrier S, Uemura M, Lee JL. Avelumab plus axitinib versus sunitinib for advanced renal-cell carcinoma. *New England Journal of Medicine*. 2019 Mar 21;380(12):1103-15.
45. Motzer RJ, Hutson TE, Tomczak P, Michaelson MD, Bukowski RM, Rixe O, Oudard S, Negrier S, Szczylik C, Kim ST, Chen I. Sunitinib versus interferon alfa in metastatic renal-cell carcinoma. *New England Journal of Medicine*. 2007 Jan 11;356(2):115-24.
46. Verman R, Lara PN. Cytokines in the Management of Advanced Renal Cell Cancer. In *Kidney Cancer 2015* (pp. 245-258). Springer, Cham.
47. Escudier B, Tannir NM, McDermott DF, Frontera OA, Melichar B, Plimack ER, Barthelemy P, George S, Neiman V, Porta C, Choueiri TK. CheckMate 214: efficacy and safety of nivolumab+ ipilimumab (N+ I) v sunitinib (S) for treatment-naïve advanced or metastatic renal cell carcinoma (mRCC), including IMDC risk and PD-L1 expression subgroups. *Annals of Oncology*. 2017 Sep 1;28:v621-2.
48. Choueiri TK, Motzer RJ, Rini BI, Haanen J, Campbell MT, Venugopal B, Kollmannsberger C, Gravis-Mescam G, Uemura M, Lee JL, Grimm MO. Updated efficacy results from the JAVELIN Renal 101 trial: first-line avelumab plus axitinib versus sunitinib in patients with advanced renal cell carcinoma. *Annals of Oncology*. 2020 Aug 1;31(8):1030-9..
49. Choueiri TK, Powles T, Burotto M, Escudier B, Bourlon MT, Zurawski B, Oyervides Juárez VM, Hsieh JJ, Basso U, Shah AY, Suárez C. Nivolumab plus cabozantinib versus sunitinib for advanced renal-cell carcinoma. *New England Journal of Medicine*. 2021 Mar 4;384(9):829-41.
50. Motzer R, Alekseev B, Rha SY, Porta C, Eto M, Powles T, Grünwald V, Hutson TE, Kopyltsov E, Méndez-Vidal MJ, Kozlov V. Lenvatinib plus pembrolizumab or everolimus for advanced renal cell carcinoma. *New England Journal of Medicine*. 2021 Apr 8;384(14):1289-300.
51. McGregor BA, McKay RR, Braun DA, Werner L, Gray K, Flaifel A, Signoretti S, Hirsch MS, Steinharter JA, Bakouny Z, Flippot R. Results of a multicenter phase II study of atezolizumab and bevacizumab for patients with metastatic renal cell carcinoma with variant histology and/or sarcomatoid features. *Journal of Clinical Oncology*. 2020 Jan 1;38(1):63.
52. Noronha V, Abraham G, Patil V, Joshi A, Menon N, Mahajan A, Janu A, Jain S, Talreja VT, Kapoor A, Kumar Singh G. A real-world data of Immune checkpoint inhibitors in solid tumors from India. *Cancer Medicine*. 2021 Mar;10(5):1525-34.
53. Zanzwar S, Joshi A, Noronha V, Patil VM, Sable N, Papat P, Menon S, Kothari R, Bhargava P, Kapoor A, Prabhaskar K. Patterns of care and outcomes for second-line targeted therapy in metastatic renal cell carcinomas: A registry-based analysis. *Indian Journal of Cancer*. 2016 Oct 1;53(4):579.
54. Escudier B, Sharma P, McDermott DF, George S, Hammers HJ, Srinivas S, Tykodi SS, Sosman JA, Procopio G, Plimack ER, Castellano D. CheckMate 025 randomised phase 3

- study: outcomes by key baseline factors and prior therapy for nivolumab versus everolimus in advanced renal cell carcinoma. *European urology*. 2017 Dec 1;72(6):962-71.
55. Bergers G, Hanahan D. Modes of resistance to anti-angiogenic therapy. *Nat Rev Cancer* 2008; 8: 592–603.
  56. Grüllich C. Cabozantinib: multi-kinase inhibitor of MET, AXL, RET, and VEGFR2. *Small Molecules in Oncology*. 2018:67-75.
  57. Zschäbitz S, Grüllich C. Lenvantinib: a tyrosine kinase inhibitor of VEGFR 1-3, FGFR 1-4, PDGFR $\alpha$ , KIT and RET. *Small Molecules in Oncology*. 2018:187-98.
  58. Motzer RJ, Hutson TE, Glen H, Michaelson MD, Molina A, Eisen T, Jassem J, Zolnierek J, Maroto JP, Mellado B, Melichar B. Lenvatinib, everolimus, and the combination in patients with metastatic renal cell carcinoma: a randomised, phase 2, open-label, multicentre trial. *The lancet oncology*. 2015 Nov 1;16(15):1473-82.
  59. Abbas W, Aggarwal A, Pankaj P, Jain R. Real-world data of second-line immunotherapy in metastatic clear cell renal cell carcinoma: A retrospective study. *Cancer Research, Statistics, and Treatment*. 2021 Jan 1;4(1):55.
  60. Escudier B, Motzer RJ, Sharma P, Wagstaff J, Plimack ER, Hammers HJ, Donskov F, Gurney H, Sosman JA, Zalewski PG, Harmenberg U. Treatment beyond progression in patients with advanced renal cell carcinoma treated with nivolumab in CheckMate 025. *European urology*. 2017 Sep 1;72(3):368-76.
  61. Ornstein MC, Pal SK, Wood LS, Tomer JM, Hobbs BP, Jia XS, Allman KD, Martin A, Olencki T, Davis NB, Gilligan TD. Individualised axitinib regimen for patients with metastatic renal cell carcinoma after treatment with checkpoint inhibitors: a multicentre, single-arm, phase 2 study. *The Lancet Oncology*. 2019 Oct 1;20(10):1386-94.
  62. Powles T, Motzer RJ, Escudier B, Pal S, Kollmannsberger C, Pikiel J, Gurney H, Rha SY, Park SH, Geertsen PF, Gross-Goupil M. Outcomes based on prior therapy in the phase 3 METEOR trial of cabozantinib versus everolimus in advanced renal cell carcinoma. *British journal of cancer*. 2018 Sep;119(6):663-9.
  63. Motzer RJ, Escudier B, McDermott DF, George S, Hammers HJ, Srinivas S, Tykodi SS, Sosman JA, Procopio G, Plimack ER, Castellano D. Nivolumab versus everolimus in advanced renal-cell carcinoma. *New England Journal of Medicine*. 2015 Nov 5;373(19):1803-13.
  64. Sheng IY, Ornstein MC. Ipilimumab and nivolumab as first-line treatment of patients with renal cell carcinoma: the evidence to date. *Cancer Management and Research*. 2020;12:4871.
  65. Nadal R, Amin A, Geynisman DM, Voss MH, Weinstock M, Doyle J, Zhang Z, Viudez A, Plimack ER, McDermott DF, Motzer R. Safety and clinical activity of vascular endothelial growth factor receptor (VEGFR)–tyrosine kinase inhibitors after programmed cell death 1 inhibitor treatment in patients with metastatic clear cell renal cell carcinoma. *Annals of Oncology*. 2016 Jul 1;27(7):1304-11.
  66. Escudier B, Michaelson MD, Motzer RJ, Hutson TE, Clark JI, Lim HY, Porfiri E, Zalewski P, Kannourakis G, Staehler M, Tarazi J. Axitinib versus sorafenib in advanced renal cell carcinoma: subanalyses by prior therapy from a randomised phase III trial. *British journal of cancer*. 2014 Jun;110(12):2821-8.
  67. Motzer RJ, Barrios CH, Kim TM, Falcon S, Cosgriff T, Harker WG, Srimuninnimit V, Pittman K, Sabbatini R, Rha SY, Flaig TW. Phase II randomised trial comparing sequential first-line everolimus and second-line sunitinib versus first-line sunitinib and second-line everolimus in patients with metastatic renal cell carcinoma. *Journal of Clinical Oncology*. 2014 Sep 1;32(25):2765.
  68. Motzer RJ, Tannir NM, McDermott DF, Frontera OA, Melichar B, Choueiri TK, Plimack ER, Barthélémy P, Porta C, George S, Powles T. Nivolumab plus ipilimumab versus sunitinib in advanced renal-cell carcinoma. *New England Journal of Medicine*. 2018 Mar 21.

69. Hutson TE, Michaelson MD, Kuzel TM, Agarwal N, Molina AM, Hsieh JJ, Vaishampayan UN, Xie R, Bapat U, Ye W, Jain RK. A single-arm, multicenter, phase 2 study of lenvatinib plus everolimus in patients with advanced non-clear cell renal cell carcinoma. *European urology*. 2021 Aug 1;80(2):162-70.
70. Tannir NM, Jonasch E, Albiges L, Altinmakas E, Ng CS, Matin SF, Wang X, Qiao W, Lim ZD, Tamboli P, Rao P. Everolimus versus sunitinib prospective evaluation in metastatic non-clear cell renal cell carcinoma (ESPN): a randomised multicenter phase 2 trial. *European urology*. 2016 May 1;69(5):866-74.
71. Parikh M, Harris J, Alpajaro SI, Lara PN, Evans CP. Defining an Individualised Treatment Strategy for Metastatic Renal Cancer. In *Renal Cancer 2020* (pp. 437-452). Springer, Cham.
72. Koshkin VS, Barata PC, Zhang T, George DJ, Atkins MB, Kelly WJ, Vogelzang NJ, Pal SK, Hsu J, Appleman LJ, Ornstein MC. Clinical activity of nivolumab in patients with non-clear cell renal cell carcinoma. *Journal for immunotherapy of cancer*. 2018 Dec;6(1):1-7.
73. Pal SK, Tangen C, Thompson Jr IM, Balzer-Haas N, George DJ, Heng DY, Shuch B, Stein M, Tretiakova M, Humphrey P, Adeniran A. A comparison of sunitinib with cabozantinib, crizotinib, and savolitinib for treatment of advanced papillary renal cell carcinoma: a randomised, open-label, phase 2 trial. *The Lancet*. 2021 Feb 20;397(10275):695-703.
74. Choueiri TK, Heng DY, Lee JL, Cancel M, Verheijen RB, Mellempgaard A, Ottesen LH, Frigault MM, L'Hernault A, Szijgyarto Z, Signoretti S. Efficacy of savolitinib vs sunitinib in patients with MET-driven papillary renal cell carcinoma: the SAVOIR phase 3 randomised clinical trial. *JAMA oncology*. 2020 Aug 1;6(8):1247-55.
75. Tran J, Ornstein MC. Clinical review on the management of metastatic renal cell carcinoma. *JCO Oncology Practice*. 2022 Mar;18(3):187-96.
76. Kidney Cancer NCCN Clinical Practice Guidelines in Oncology. Available online: [https://www.nccn.org/professionals/physician\\_gls/pdf/kidney.pdf](https://www.nccn.org/professionals/physician_gls/pdf/kidney.pdf) (accessed on 15 December 2019).
77. Felip E, Ardizzoni A, Ciuleanu T, Cobo M, Laktionov K, Szilasi M, Califano R, Carcereny E, Griffiths R, Paz-Ares L, Duchnowska R. CheckMate 171: A phase 2 trial of nivolumab in patients with previously treated advanced squamous non-small cell lung cancer, including ECOG PS 2 and elderly populations. *European Journal of Cancer*. 2020 Mar 1;127:160-72.
78. Ernst DS, McConkey H, Liu L, Butler MO, Petrella T, Baetz T, Koneru R, Song X, Cheng T, Smylie MG, Rajagopal S. Utilization of real-world data to assess the effectiveness of immune checkpoint inhibitors (ICIs) in elderly patients with metastatic melanoma. *Annals of Oncology*. 2019 Oct 1;30:v553.
79. Hale P, Hahn AW, Rathi N, Pal SK, Haaland B, Agarwal N. Treatment of metastatic renal cell carcinoma in older patients: a network meta-analysis. *Journal of Geriatric Oncology*. 2019 Jan 1;10(1):149-54.
80. McNamara MG, Slagter AE, Nuttall C, Frizziero M, Pihlak R, Lamarca A, Tariq N, Valle JW, Hubner RA, Knox JJ, Amir E. Sorafenib as first-line therapy in patients with advanced Child-Pugh B hepatocellular carcinoma—A meta-analysis. *European Journal of Cancer*. 2018 Dec 1;105:1-9.
81. Kanz BA, Pollack MH, Johnpulle R, Puzanov I, Horn L, Morgans A, Sosman JA, Rapisuwon S, Conry RM, Eroglu Z, Johnson DB. Safety and efficacy of anti-PD-1 in patients with baseline cardiac, renal, or hepatic dysfunction. *Journal for immunotherapy of cancer*. 2016 Dec;4(1):1-6.
82. Khosravan R, Toh M, Garrett M, La Fargue J, Ni G, Marbury TC, Swan SK, Lunde NM, Bello CL. Pharmacokinetics and safety of sunitinib malate in subjects with impaired renal function. *The Journal of Clinical Pharmacology*. 2010 Apr;50(4):472-81.
83. Josephs DH, Hutson TE, Pickering LM, Larkin JM, Choueiri TK, Patel TV, Mcdermott DF, Powles T, Harper PG, Chowdhury S. Efficacy and toxicity of sunitinib in patients with metastatic renal cell carcinoma (mRCC) with severe renal impairment or on haemodialysis. *Journal of Clinical Oncology*. 2009 May 20;27(15\_suppl):5109-.

84. Gupta S, Parsa V, Heilbrun LK, Smith DW, Dickow B, Heath E, Vaishampayan U. Safety and efficacy of targeted agents in metastatic kidney cancer patients with renal dysfunction. *Anti-cancer drugs*. 2011 Sep;22(8):794.
85. Achkar T, Maranchie JK, Appleman LJ. Metastasectomy in advanced renal cell carcinoma: a systematic review. *Kidney Cancer*. 2019 Jan 1;3(1):31-40.
86. Motzer RJ, Jonasch E, Boyle S, Carlo MI, Manley B, Agarwal N, Alva A, Beckermann K, Choueiri TK, Costello BA, Derweesh IH. NCCN guidelines insights: kidney cancer, version 1.2021: featured updates to the NCCN guidelines. *Journal of the National Comprehensive Cancer Network*. 2020 Sep 1;18(9):1160-70.
87. Chapin BF, Delacroix Jr SE, Culp SH, Gonzalez GM, Tannir NM, Jonasch E, Tamboli P, Wood CG. Safety of presurgical targeted therapy in the setting of metastatic renal cell carcinoma. *European urology*. 2011 Nov 1;60(5):964-71.
88. Appleman LJ, Puligandla M, Pal SK, Harris W, Agarwal N, Costello BA, Ryan CW, Pins M, Kolesar J, Vaena DA, Parikh RA. Randomised, double-blind phase III study of pazopanib versus placebo in patients with metastatic renal cell carcinoma who have no evidence of disease following metastasectomy: A trial of the ECOG-ACRIN cancer research group (E2810).
89. Wardak Z, Christie A, Bowman A, Stojadinovic S, Nedzi L, Barnett S, Patel T, Mickey B, Whitworth T, Hannan R, Brugarolas J. Stereotactic radiosurgery for multiple brain metastases from renal-cell carcinoma. *Clinical genitourinary cancer*. 2019 Apr 1;17(2):e273-80.
90. Chevreau C, Ravaud A, Escudier B, Amela E, Delva R, Rolland F, Tosi D, Oudard S, Blanc E, Ferlay C, Négrier S. A phase II trial of sunitinib in patients with renal cell cancer and untreated brain metastases. *Clinical Genitourinary Cancer*. 2014 Feb 1;12(1):50-4.
91. Flippot R, Dalban C, Laguerre B, Borchiellini D, Gravis G, Négrier S, Chevreau C, Joly F, Geoffrois L, Ladoire S, Mahammedi H. Safety and efficacy of nivolumab in brain metastases from renal cell carcinoma: results of the GETUG-AFU 26 NIVOREN multicenter phase II study. *Journal of Clinical Oncology*. 2019 Aug 10;37(23):2008-16.
92. Parikh M, Bajwa P. Immune checkpoint inhibitors in the treatment of renal cell carcinoma. *In Seminars in nephrology* 2020; 40(1):76-85. WB Saunders.