

## **Case study**

# **Giant pancreatic pseudocyst complicating twin pregnancy with spontaneous resolution: case report**

### **Abstract**

Pancreatic pseudocyst during pregnancy is a rare pathology whose management lacks of hindsight , with only 10 cases reported in the literature since 1980. Spontaneous resolution in 11 to 16% of cases has been described in the literature.

We report a case of giant pseudocyst of the pancreas during pregnancy spontaneously resolving.

A 19-year-old pregnant female presented with giant pancreatic pseudocysts which was managed conservatively, evolving towards a spontaneous resolution after delivery.

### **Key Words:**

Pancreatic pseudocyst – pregnancy – resolution

### **1. INTRODUCTION**

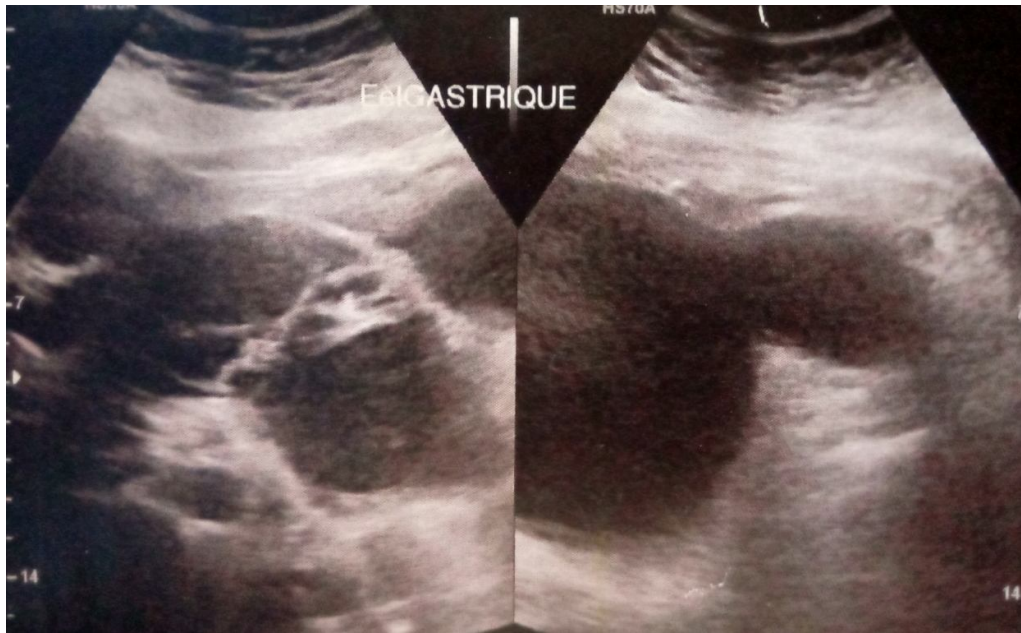
Pancreatic pseudocysts are liquid collections without a distinct epithelial wall, developed at the edge of or in contact with the pancreas, containing pure pancreatic fluid or mixed with necrotic debris; following an inflammatory process such as Pancreatitis (mainly from an unknown etiology) or Trauma (1).

Pancreatic pseudocysts are common complication of pancreatitis. However, few cases of giant pancreatic pseudocysts, which measure 10 cm or more in widest diameter, have been described. During pregnancy, the management of this rare condition is not standardized (2).

### **2. CASE REPORT:**

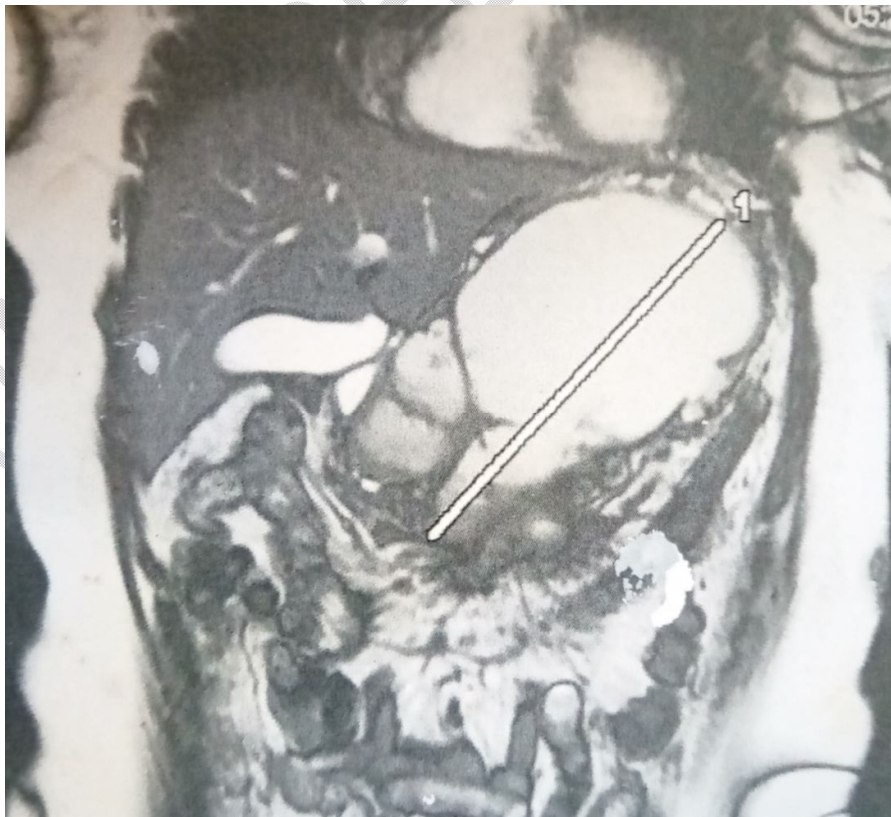A 19-year-old female in the 24<sup>th</sup> week of her first twin pregnancy with a past medical history of undocumented abdominal trauma within the last 7 months, presented a one week of intermittent epigastric abdominal gravity-type pain with radiation to her back and nausea. The clinical examination found a conscious patient, hemodynamically and respiratory stable, without clinical cholestasis. The abdominal examination shows a hard, slightly tender epigastric mass, fixed in relation to the deep plane measuring 20 cm in diameter. The rest of the somatic examination, including cardiovascular and pleuropulmonary examination, was normal.

An ultrasound scan was performed showing large cystic formations occupying all portions of the pancreas, communicating with each other, containing thickened partitions and walls. They measure 120\*90mm and 50\*48mm. It also showed a monochorionic diamniotic intrauterine pregnancy.

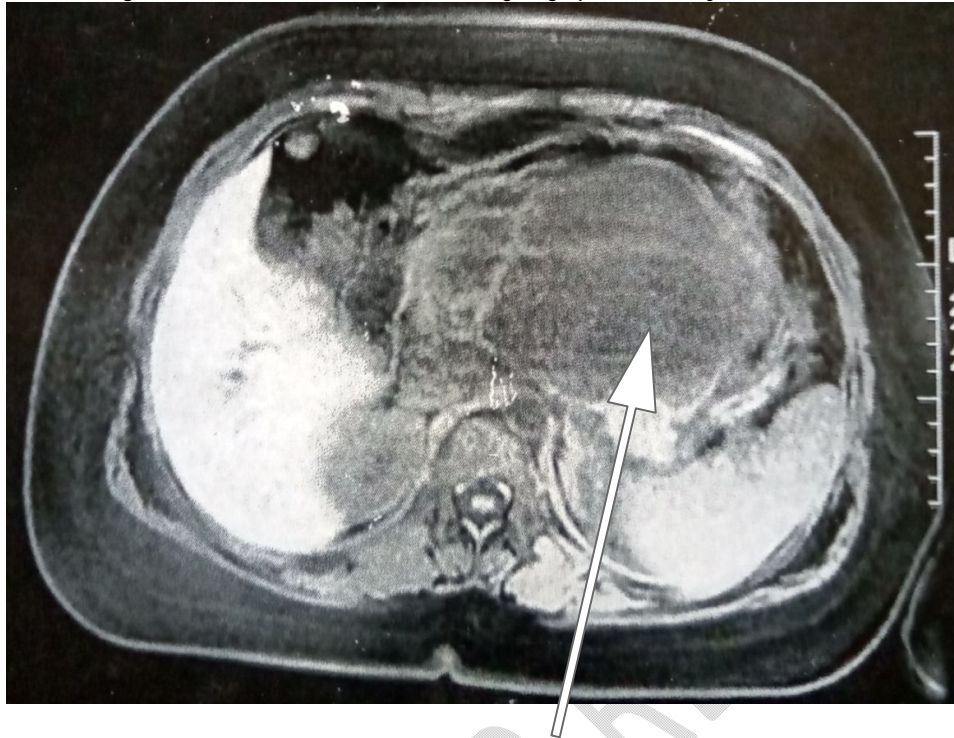


**Figure 1:** large cystic formations occupying all portions of the pancreas

MRI revealed a large cystic formation measuring 19 cm in diameter at the expense of the whole pancreas which only the distal part of the tail remains, with homogeneous content. **nothing else was reported on this scanner. the tracing of the electrocardiogram was normal.** Tumor markers noted an elevated CA19.9 at 79, 4 IU/ml and a normal ACE at 0,9ng/ml. The lipasemia was normal.



**Figure 2:** T2 coronal slice MRI showing large pancreatic cystic formation



**Figure 3:** diffusion axial slice MRI showing large pancreatic cystic formation

A cytological and biochemical study of the fluid from the ultrasound-guided puncture of the pancreatic cyst was performed, showing an inflammatory fluid without tumor cells, with amylase level at 4921IU/L and lipase level at 349IU/L.

After the disappearance of the symptoms following digestive rest and parenteral feeding as well as symptomatic treatment, the patient benefited from a regular follow-up until the delivery.

6 months later, an abdominal CT scan was performed, showing a normal-looking pancreas.

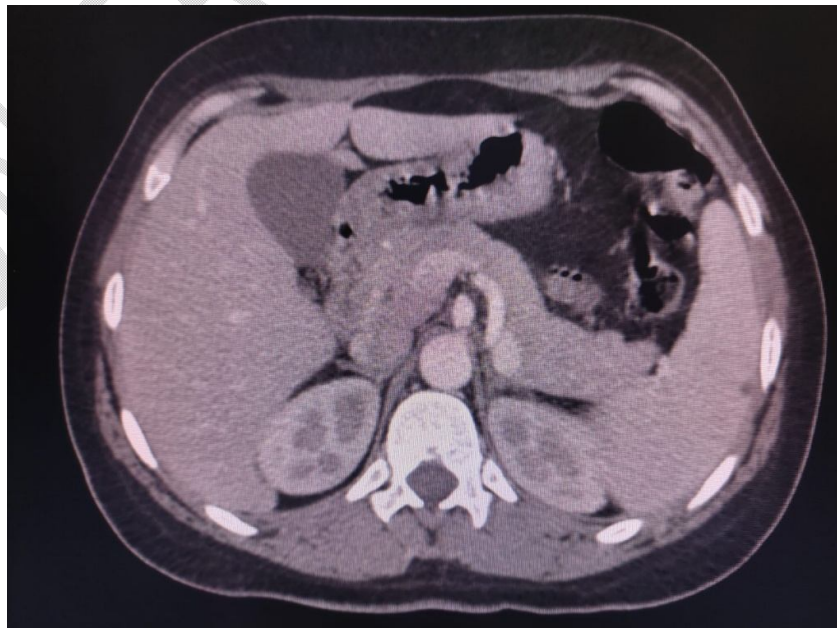


Figure 4: axial slice MRI showing a normal pancreas

### 3. DISCUSSION:

"Pancreatic secretions accumulate in the peri-pancreatic tissues when the main duct of the pancreas or one of the ductal branches is ruptured. Most of these accumulations resolve spontaneously. However, in some cases, the accumulation of fluid persists, and the inflammatory process forms a fibrous wall around the fluid that does not have normal epithelialization, so it is called a pseudocyst" (2-3). "The synonyms of huge or large are used in the scientific reports of giant pseudocysts" (4). "The incidence of pancreatic pseudocysts is low at 0.5–1/100 000 adults per year, with spontaneous resolution in 11% to 16% of cases is reported in the literature (5). Approximately 30%-40% are complicated by infection, rupture, hemorrhage or obstruction of the stomach, small bowel, colon, or bile duct" (6).

"The natural history of pancreatic pseudocysts in pregnancy appears similar to nonpregnant patients. Pancreatic pseudocysts present a clinical polymorphism. Some may be completely asymptomatic while others may present with features of biliary tract obstruction. The most common clinical manifestations are abdominal swelling, pain, nausea and vomiting. Others include early satiety and weight loss" (7).

"Diagnostic modalities are mainly imaging. In our case; ultrasound and MRI were the examinations of choice over CT because of their non-irradiating nature. Confirmation is by finding cystic wall devoid of epithelial lining on pathologic specimen" (7-8).

Previous reports have noted that pancreatic pseudocysts larger than 6 cm in diameter and persisting for more than 6 weeks are unlikely to resolve spontaneously (9). But in our case, a spontaneous resolution was the evolution, despite the giant volume and duration of persistence.

"The management of pancreatic pseudocysts during pregnancy is poorly clarified. However, surgical treatment can be of two approaches closed (percutaneous drainage or laparoscopic approach); and open with internal or external drainage. Most surgeons adhere to the 'Rule of 6' for the management of pancreatic pseudocysts (that is cysts >6 cm or duration >6 weeks). This was based on the expectations that 6 weeks is sufficient time for the pseudocyst to resolve spontaneously and the pseudocyst wall to mature to be tough enough to hold sutures" (10).

"An Endoscopic retrograde cholangiopancreatography is advisable as pancreatic duct disruption is associated with a decreased rate of pseudocyst resolution following drainage. The reference treatment modality consists of transmural drainage guided by endoscopic ultrasound" (11).

### 4. CONCLUSION:

Giant pseudocysts of pancreas may not be as rare as they were thought to be, but in pregnancy they can create a great problem of therapeutic management. The conservative attitude can be a choice, but when the impact is obvious, the appeal to therapeutic modalities must be standardized by creating decisional algorithms for the different clinical presentations.

### Ethical Approval:

As per international standard or university standard written ethical approval has been collected and preserved by the author(s).

### Consent

As per international standard or university standard, patient(s) written consent has been collected and preserved by the author(s).

### REFERENCES

1. Gumaste VV, Pitchumoni CS: Pancreatic pseudocysts; in Brandt LJ (ed): Clinical Practice of Gastroenterology. Philadelphia, Current Medicine Inc, 1999, pp 1219–1224.
2. G.V. De Socio, M. Vispi, M.J. Fischer, et al., A giant pancreatic pseudocyst in a patient with HIV infection, J. Int. Assoc. Physicians AIDS Care (Chic) 11 (2012) 227–229.
3. I. Elkhatib, T. Savides, S.M.A. Fehmi, Pancreatic fluid collections: physiology, natural history, and indications for drainage, Tech. Gastrointest. Endosc. 14(2012) 186–194.
4. A. Oria, C. Ocampo, H. Zandalazini, et al., Internal drainage of giant acute pseudocysts—the role of video-assisted pancreatic necrosectomy, Arch. Surg. 135 (2000) 136–410.
5. G.C. Wang, S. Misra, A giant pancreatic pseudocyst treated by cystogastrostomy, BMJ Case Rep. 24 (2015) 130–142.
6. Habashi S, Draganov PV. Pancreatic pseudocyst. World J Gastroenterol. 2009;15(1):38-47.
7. Lankisch, P. G., Weber-Dany, B., Maisonneuve, P., & Lowenfels, A. B. (2012). Pancreatic pseudocysts: prognostic factors for their development and their spontaneous resolution in the setting of acute pancreatitis. *Pancreatology*, 12(2), 85-90.
8. A. Tyberg, K. Karia, M. Gabr, A. Desai, R. Doshi, M. Gaidhane, et al., Management of pancreatic fluid collections: a comprehensive review of literature, World J. Gastroenterol. 22 (7) (2016) 2256–2270.
9. Igwe, P. O., Ray-Offor, E., Karibi, E. N., Okeke, U. F., Ugwa, O. C., & Jebbin, N. J. (2020). Giant pseudocyst of the pancreas: A report of three cases. *International Journal of Surgery Case Reports*, 77, 284-297.
10. J.W. Cannon, M.P. Callery, C.M. Vollmer Jr., Diagnosis and management of pancreatic pseudocysts, J. Am. Coll. Surg. 3 (2009) 385–390.
11. Lu, X., Uchida, E., Yokomuro, S., Nakamura, Y., Aimoto, T., & Tajiri, T. (2008). Features and Choice of Treatment of Acute and Chronic Pancreatic Pseudocysts—with Special Reference to Invasive Intervention. *Pancreatology*, 8(1), 30-35.