

Idiopathic Mono-Ventricular Hydrocephalus in Adults patient: Case Study and Literature review

Abstract

Mono-ventricular hydrocephalus is a rare condition in adults. Most of the time, this condition is acquired and is secondary to an anatomical or functional obstruction of the foramen of Monro. Exceptionally, mono-ventricular hydrocephalus is the result of a congenital atresia of the foramen of Monro. We reported here the case of a 31-year-old received in consultation with chronic headaches, morning jet vomiting whose paraclinical assessment made it possible to diagnose monoverventricular hydrocephaly by atresia of the foramen of monro

The patient was cured of his symptoms after septomy endoscopic under stereotac condition. Etiological, clinico-radiolocal and and therapeutical aspects are discussed in the light of the literature.

Keywords: Monoventricular- hydrocephalus idiopathic-Septotomiy

Introduction

Unilateral hydrocephalus, mono-ventricular hydrocephalus or even unilateral ventriculomegaly was initially described by Von Morh in 1842(1, 2), then by Cushing (3) and Dott (4) and has been recognized as a clinical entity since the Salmon report (1). It is a dilation of a lateral ventricle resulting from the obstruction of the flow of cerebrospinal fluid (CSF) through the ipsilateral foramen of Monro (5).

The treatment can be either by ventriculoperitoneal bypass (DVP), or by neuroendoscopy. Neuroendoscopy can be either a simple fenestration of the septum pellicidum, in stereotaxic condition, or assisted by neuronavigation or finally a neuroendoscopic fenestration of the foramen of monro management is the gold standard for treating unilateral hydrocephalus (6).

Neuroendoscopic septotomy is nowadays the most widely used therapeutic technique because it is minimally invasive and does not expose the complications of internal bypass (infections, drain migration, neck pain, umbilical fistulas, disjunction, and calcification of the drain (7).

Ventriculostomy is a surgical technique practiced by several teams in the treatment of monoverventricular hydrocephalus, several series are described through the literature, (8,9,10). This technique has presented complications in any patient, significant intraventricular hemorrhage, wound breakdown, shunt infection and sterile meningitis (10)

The treatment of monoverventricular hydrocephalus by septotomy, although rare, is described by DHAVAC (7) in India, Gangemie et al (9) in the USA, Fondop et al (11) in France Jivana (12) in South Africa and by several other authors, this technique is practical in several countries, the neuro navigation used in our method, allows more precision of the choice of the very little vascularized area of the septum pellicidum to be perforated.

We report here the case of idiopathic mono-ventricular hydrocephalus in adults successfully treated by endoscopic septotomy in stereotaxic condition. The etiology, clinical, radiological presentation and treatment options of this disease entity are discussed in the literature review.

Clinical case

A 31-year-old right-handed patient had presented headaches for three months associated with progressive worsening neck pain, morning vomiting and visual blurring episodes.

For the past 2 weeks, asthenia had been associated with antegrade memory disorders. On clinical examination, there was no objective neurological sign other than a lively Osteotendinous reflex in the lower limbs. The fundus produced showed bilateral papillary edema predominantly on the right with visual acuity of 3/10th on the right and 4/10th on the left. The brain scan showed a ventriculomegaly of the right lateral ventricle producing a mass effect on the midline and associated with periventricular hyperhydration (fig.1).

Brain MRI with flow sequence confirmed the obstructive nature (Monro foramen) of unilateral hydrocephalus of the right lateral ventricle but did not find any anatomical cause for this obstruction (fig 2).

Emergency management consisted of an endoscopic septotomy in stereotaxic condition. After trepanning, placement of the mid-endoscope sheath (Storz®) in the right lateral ventricle resulted in the pressurized release of CSF which will flow through the sheath upon removal of the mandrel. After placement of the endoscope, perforation of the septum pellucidum was performed using the NeuroBalloon®. A sentinel external ventricular drain was left in place to monitor intracranial pressure and removed at the 24th hour when symptoms improved with normal CSF pressure.

The postoperative period was marked by the immediate regression of headaches and neck pain as well as the complete disappearance of nausea and vomiting. On D5 postoperatively, the fundus was normal and the control brain CT scan showed the persistence of ventricular dilation and the mass effect on the septum pellucidum with, however, a decrease in peri-ventricular hydration. The patient went home on D5 postoperative. Moreover, at 3 months postoperatively, the fundus remained normal and visual acuity was measured at 3 / 10th on the right and 8 / 10th on the left and from 4/10 to 10/10 on the right. Brain MRI still showed the existence of ventricular asymmetry with deviation of the septum pellucidum. At 1 year postoperatively, the situation remained unchanged clinically and radiologically (fig. 3).

Discussion

Unilateral progressive hydrocephalus has been classified by Oi et al. into 4 categories based on the appearance of the foramen of Monro: atresia, morphological obstruction, functional obstruction or no obstruction (2, 6, 13). The most frequently found

causes are tumor, malformation (Monro's foramen or adjacent structures), hemorrhagics, infectious, linked to a surgical scar or hypertrophy of the choroid plexuses. Congenital atresia of the foramen of Monro revealed in adulthood is rare and happens in exceptional cases (6, 7, 13,14).

The clinical conditions surrounding the discovery of mono ventricular hydrocephalus can be either: repetitive headaches, ideomotor slowing and visual disturbances. In rare cases unilateral or mono ventricular hydrocephalus has been responsible for hemiparesis (6, 8).

MRI is the gold standard in the diagnosis of unilateral hydrocephalus. It allows both to make the positive diagnosis but also most of the time the etiological diagnosis. In our patient no cause was identified and thus unilateral congenital atresia of the foramen of Monro was suggested (9,14).

Treatment for nomoventricular hydrocephalus can be done either by drainage of the CSF by ventriculo-peritoneal bypass or treatment via the neuroendoscopic route. The ventriculoperitoneal bypass is the oldest technique, and is indicated as a second-line treatment in patients with a deterioration of the clinical condition or a reobstruction of the CSF circulation path after endoscopic treatment (2, 6) Neuroendoscopic treatment is the standard treatment for mono-ventricular hydrocephalus as it is less invasive and allows a biopsy to be performed (6, 7).

Two types of endoscopic treatment have been described:

- **Fenestration of the septum pellicidum** by simple craniotomy in stereotaxic condition or assisted by neuronavigation (2, 6).
- **Fenestration of the foramen of Monro.** The indication for this technique is hydrocephalus by occlusion of the foramen of Monro by an avascular membrane. The development of postoperative symptoms is marked by a decrease in signs of intracranial hypertension. On the other hand, the restoration of visual signs depends on the delay in diagnosis (2,6,8,9). The absence of normalization of the size of the ventricles and in particular the persistence of a deviation of the midline as in our case is the rule (12). After the ventriculo septotomy, the size of the right lateral ventricle had not changed but the clinical signs had

disappeared and the fundus was normal, which is consistent with the work of Dhaval Shukla(7) who noted that in chronic symptomatic mono ventricular hydrocephalus, this therapeutic technique improves the clinical signs without changing the radiological signs. In work by Qiang et al, the CT-scan size of the dilated ventricle decreased significantly in 8/12 patients while it remained unchanged in 4/12 patients. on the other hand, the size of the dilated ventricle decreased in all the 5 patients described by M Gangemi et al (9).

The complications of ventriculo septotomy have been described in the work of Aldana et al in 4/32 patients such as the significant intraventricular hemorrhage, wound breakdown, shunt infection and sterile meningitis; In this same study, in this same study, 9/42 septotomy are revisions at least once , none of these complications have been described in our patients. No complications have been described after 6 months(13). Ventriculo septotomy is a minimally invasive technique where the patient has few days of hospitalization, does not present any long-term complication described, as in ventriculoperitoneal bypass it is a technique to be encouraged in developing countries

Conclusion:

Unilateral hydrocephalus due to atresia of the Monro foramen is a rare condition in adults. The treatment of choice is endoscopic fenestration of the septum pellucidum. The prognosis is often good if patients are diagnosed on time.

REFERENCES

1. Salomon JH. Isolateral unilateral hydrocephalus following ventriculoatrial shunt, J.Neurosurg. 1970; 32:219-26
2. OI S, Matsumoto S, Pathophysiology of non-neoplastic obstruction of the foramen of Monro and progressive unilateral hydrocephalus .Neurosurgery1985 Dec; 17(6):891-6
- 3.Cushing H. Surgery of the head. Its principles and Practice. In: Keen WW (ed.) Surgery; Philadelphia: WB Saunders: 1908; 3: 142–3
4. Dott NM. A case of left unilateral hydrocephalus in an infant, operation-cure. Brain. 1927; 56:548-61
5. Nigri1 F, Gobbi GN, Pinto PHDCF et al. Hydrocephalus caused by unilateral foramen of Monro obstruction: A review on terminology A Supplement to Surgical Neurology International .SNI: Paediatric Neurosurgery 2016; 7(12)12:307-313
6. Boruah DK , Ora MA ,Prakash A. et al Idiopathic unilateral foramen of monro stenosis: neuroimaging findings in three patients J. Evid. Based Med. Healthc., pISSN- 2349-2562, eISSN- 2349-2570/, 2016 Apr. 28 (3)34:1673-75
7. Dhaval Shukla. Neuroendoscopic treatment of idiopathic occlusion of unilateral foramen of Monro presenting as chronic headache. Journal of Neurosciences in Rural Practice 2016 Jan-Mar;7(1):128-30.
- 8- Qiang Cai, Ping Song, Qianxue Chen,et al. Neuroendoscopic fenestration of the septum pellucidum for monoventricular hydrocephalus ,Clin Neurol Neurosurg . 2013 Jul;115(7):976-80.
- 9-M Gangemi, F Maiuri, P A Donati et al . Endoscopic surgery for monoventricular hydrocephalus Surg Neurol , 1999 Sep;52(3):246-50
- 10-Philipp R Aldana, John R W Kestle, Douglas L Brockmeyer, Marion L Walker , Results of endoscopic septal fenestration in the treatment of isolated ventricular hydrocephalus, Pediatr Neurosurg 2003 Jun;38(6):286-94.
- 11 - J Fondop 1, M Lagmari, P Metellus, S Fuentes, E Ngah, V Djentcheu, F Grisoli, H Dufour , Unilateral hydrocephalus secondary to a brain temporal abscess treated by endoscopic septotomy: a case report, Neurochirurgie, 2010 Aug; 56(4):337-9.
- 12- Jivan K, Mochan A, Modi G, Intraventricular neurocytotoxicosis causing acute

unilateral hydrocephalus, scientific letter. African Journal of psychiatry (Johannesbg).2010 Sep;13(4):315-7

13- Krucoff, MO, Chinn M, Babington P et al. Interdisciplinary Neurosurgery: Advanced Techniques and Case Management 2015; 2:108–110

14- Rena L, Sood D. Rana N. et al. MR Imaging in Unilateral Hydrocephalus in Adults. Journal of Clinical Medical R , 2020;1(2): 1-6.

Idiopathic Mono-Ventricular Hydrocephalus in Adults: Clinical Case Study and Literature review.

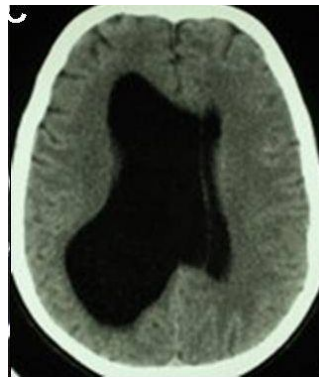


Fig 1: Brain CT before endoscopic surgery

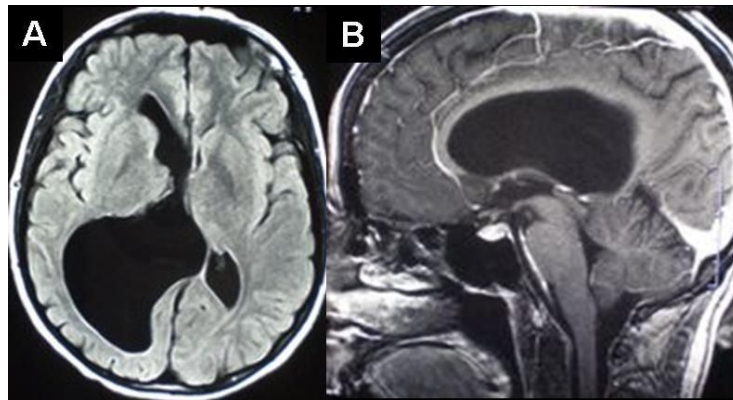


Fig 2: Brain MRI before endoscopic surgery (A axial slice, B sagittal slice)

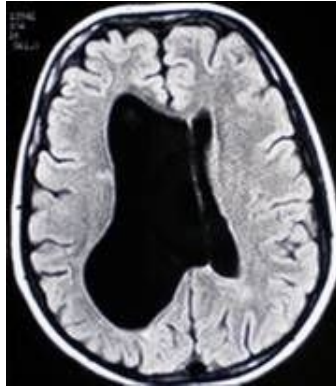


Fig 3: Brain MRI 1 year after the operation