

Original Research Article

Retinal and Choroidal Changes in Patients with Systemic Arterial Hypertension

ABSTRACT

Aims: to evaluate retinal and choroidal changes in patients with systemic arterial hypertension using optical coherence tomography (OCT).

Setting: The study was performed in the outpatient clinic of Tanta ophthalmology Hospital.

Design: prospective, cross sectional and controlled study.

Patients and methods: Retinal and choroidal changes using spectral domain optical coherence tomography that includes the following parameters: central macular thickness (CMT), Subfoveal choroidal thickness (SFCT), and Retinal nerve fiber layer thickness (RNFL).

Results: The study comprised 10 eyes of healthy individuals without hypertension, 15 eyes of systemic hypertensive patients on beta blockers for more than one year, and 15 eyes of systemic hypertensive patients on calcium channel blockers for more than one year. This study showed There were statistically significant differences between the three studied groups as regards the mean central macular thickness (CMT). In this study, we found a statistically significant decrease in the mean subfoveal choroidal thickness (SFCT) from $247.40 \pm 46.18 \mu\text{m}$ in group A (non hypertensive) to $195.63 \pm 28.96 \mu\text{m}$ in group B (hypertensive patients on beta blockers for more than one year) and decreased to $203.10 \pm 27.74 \mu\text{m}$ in group C (hypertensive patients on calcium channel blockers for more than one year). According to the retinal nerve fiber layer thickness (RNFL), our study showed (100%) were within normal thickness in group A (non-hypertensive), In group B (hypertensive patients on beta blockers for more than one year) Twelve eyes (40.0%) were within normal thickness, ten eyes (33.3%) had thinning inferior, and eight eyes (26.7%) had thinning superior. Eight eyes (26.7%) were within normal thickness, ten eyes (33.3%) had thinning inferior, four eyes (13.3%) had thinning superior, and eight eyes (26.7%) were borderline in group C (hypertensive patients on calcium channel blockers for more than one year).

Conclusion: Hypertension (HTN) has significant increase in the central macular thickness, lower SFCT and thinning in retinal nerve fiber layer thickness in all quadrants compared to normotensive individuals. Neither beta blockers nor calcium channels blockers have significant changes on these previous parameters changes.

Keywords: Hypertension, central macular thickness, subfoveal choroidal thickness, retinal nerve fiber layer thickness, spectral domain OCT with EDI.

1. INTRODUCTION

"Hypertension (HTN) is a medical condition in which the blood pressure in the arteries is persistently elevated. High blood pressure typically does not cause symptoms, long term high blood pressure however is a major risk factor for coronary artery disease, stroke, heart failure and vision loss" [1]. HTN affects several body systems such as cerebrovascular, renal, cardiovascular and retina [2].

Ocular damage as a result of HTN appears in 3 forms: chorioidopathy, retinopathy and optic neuropathy. "Hypertensive chorioidopathy occur later than retinal vascular changes of arteriolar narrowing and arteriovenous crossing changes" [3]. "The manifestations of chorioidopathy include serous retinal detachment, Elschnig spots, and siegrist streaks" [4, 5].

Spectral domain optical coherence tomography (OCT) is non invasive technique, that has become very important tool in diagnosis of hypertensive retinopathy and chorioidopathy [6]. Retinal and choroidal changes in patients with systemic arterial hypertension using optical coherence tomography with EDI that includes the following parameters: Central macular thickness in μm (CMT), Subfoveal choroidal thickness in μm (SFCT), and Retinal nerve fiber layer thickness (RNFL).

This study was carried out to evaluate retinal and choroidal changes in patients with systemic arterial hypertension using optical coherence tomography (OCT).

2. SUBJECTS AND METHODS

This prospective, cross-sectional, controlled study was carried out on 40 patients attending the Ophthalmology outpatient clinic at Tanta Ophthalmology Hospital. The duration of the study extended for 12 months (from October 2020 to September 2021). The study adhered to the tenets of the Declaration of Helsinki and all patients signed a written informed consent to participate in the study and for publication of data before enrollment in the study after approval from the ethical committee, Faculty of Medicine, Tanta University.

2.1. Participants in this study were divided into three groups:

Group A: - Normal individuals with no hypertension.

Group B: - Hypertensive Patients on beta blockers for more than one year duration.

Group C: - Hypertensive Patients on calcium channel blockers for more than one year duration.

2.2. Patient's inclusion in the study was accomplished according to the following criteria:

1. Hypertensive patients receiving beta blockers and calcium channel blockers for more than one year.
2. Eyes with clear ocular media

The following cases were excluded from the study:

- 1- Diabetic patients and other systemic diseases that affect retinal and choroidal circulation.
- 2- Hazy media that will interfere with reliable OCT images.
- 3- Eyes with previous ocular surgeries.
- 4- Any local diseases including glaucoma

All patients included in the study were subjected to the following:

1. History taking:

Detailed history taking including anti hypertensive drug used:

- Generic name, trade name, type, number, dose and duration.
- Past history of any ophthalmic surgery, drugs or prior eye disease.

2. Full ophthalmic examination:

- BCVA.
- Anterior segment examination using slit lamp biomicroscopy with no abnormal data.
- Posterior segment examination using slit lamp biomicroscopy using auxillary lenses (90 diopter lens) and hypertensive changes in the form of generalized and focal arteriolar narrowing, copper wiring, and AV nicking were found in some patients.
- IOP measurement with applanation tonometry to exclude glaucomatous patients.

3- Investigations

- HBA1C and Fundus fluorescein angiography (FFA) were done to exclude diabetic patients.
- Optical Coherence tomography (OCT).

We used Heidelberg Engineering OCT Spectralis in this study with enhanced depth image mode to gain choroidal image.

2.1. Statistical analysis:

Statistical analysis was performed using IBM SPSS software package version 20.0 (Armonk, NY: IBM Corp) Qualitative data were described using number and percent. Shapiro-Wilk test was used to verify the normality of distribution. Quantitative data were described using range (minimum and maximum), mean, standard deviation, median and interquartile range (IQR). Significance of the obtained results was judged at the 5% level.

The used tests were:

1 - Chi-square test

For categorical variables, to compare between different groups.

2 - Monte Carlo correction

Correction for chi-square when more than 20% of the cells have expected count less than 5.

3 - Mann Whitney test

For abnormally distributed quantitative variables, to compare between two studied groups.

4 - F-test (ANOVA)

For normally distributed quantitative variables, to compare between more than two groups, and Post Hoc test (Tukey) for pairwise comparisons.

5 – Kruskal Wallis test

For abnormally distributed quantitative variables, to compare between more than two studied groups and Post Hoc (Dunn's multiple comparisons test) for pairwise comparisons.

3. RESULTS AND DISCUSSION

In group A (Normal individuals), included 5 females and 5 males. While group B (Hypertensive patients on beta blockers) included 6 males and 9 females, and group C (Hypertensive Patients on calcium channel blockers) included 6 males and 9 females. The mean age was 49.20 ± 6.09 years ranging from (41.0 – 60.0years), 55.53 ± 10.01 years ranging from (42.0 – 71.0 years), and 56.87 ± 6.76 years ranging from (47.0 – 72.0 years) in groups A, B, and C respectively. (table 1)

The mean duration of hypertension was 5.60 ± 2.92 years ranging from (2.0 – 10.0 years), and 8.20 ± 3.47 years ranging from (4.0 – 15.0 years) in groups B and C respectively. No statistically significant difference between the two studied groups ($p= 0.051$). (Table 2)

Table (1): Demographic data

	Group A (n =10)		Group B (n =15)		Group C (n =15)		Test of Sig.	P
	No.	%	No.	%	No.	%		
Gender								
Male	5	50.0	6	40.0	6	40.0	$\chi^2=0.307$	0.858
Female	5	50.0	9	60.0	9	60.0		
Age (years)								
Min. – Max.	41.0 – 60.0		42.0 – 71.0		47.0 – 72.0		F= 2.964	0.064
Mean ± SD.	49.20 ± 6.09		55.53 ± 10.01		56.87 ± 6.76			
Median (IQR)	48.5 (45.0–54.0)		55.0 (47.5–64.5)		56.0 (53.0 – 61.0)			

Table (2): Duration of hypertension and treatment in the two studied groups;

	Group B (n =15)	Group C (n =15)	U	P
Duration of HTN				
Min. – Max.	2.0 – 10.0	4.0 – 15.0	65.50	0.051
Mean ± SD.	5.60 ± 2.92	8.20 ± 3.47		
Median (IQR)	5.0(3.0 – 7.50)	9.0(5.5 – 10.5)		
Duration of treatment				
Min. – Max.	1.50 – 5.0	2.0 – 6.0	66.0	0.056
Mean ± SD.	3.23 ± 1.27	4.20 ± 1.26		
Median (IQR)	3.0(2.0 – 4.50)	4.0(3.0 – 5.0)		

3.1. OCT results:

The mean central macular thickness was $238.95 \pm 11.91 \mu\text{m}$ ranging from (212.0 – 255.0 μm), $274.33 \pm 29.82 \mu\text{m}$ ranging from (184.0 – 331.0 μm), and $310.07 \pm 50.47 \mu\text{m}$ ranging from (223.0 – 399.0 μm) in groups A,B, and C respectively. There were statistically significant difference between the three studied groups ($p < 0.001^*$). (Table 3) (Figure 1)

The mean subfoveal choroidal thickness was $247.40 \pm 46.18 \mu\text{m}$ ranging from (157.0 – 299.0 μm), $195.63 \pm 28.96 \mu\text{m}$ ranging from (148.0 – 263.0 μm), and $203.10 \pm 27.74 \mu\text{m}$ ranging from (160.0 – 299.0 μm) in groups A,B, and C respectively. There were statistically significant decrease between group A and B ($p_1 < 0.001^*$) and between group A and C ($p_2 < 0.001^*$). There were no statistically significant difference between group B and C ($p_3 = 0.667$). (Table 4) (figure 2)

As regard retinal nerve fiber layer thickness, Twenty eyes (100%) were within normal in group A. Twelve eyes (40.0%) were within normal thickness, ten eyes (33.3%) had thinning inferior, and eight eyes (26.7%) had thinning superior in group B. Eight eyes (26.7%) were within normal thickness, ten eyes (33.3%) had thinning inferior, four eyes (13.3%) had thinning superior, and eight eyes (26.7%) were borderline. There were statistically significant difference between the three studied groups ($p < 0.001^*$). (Table 5) (figure 3)

Table (3): central macular thickness

Central macular thickness	Group A (n =20 eyes)	Group B (n =30 eyes)	Group C (n =30 eyes)	F	P
Min. – Max.	212.0 – 255.0	184.0 – 331.0	223.0 – 399.0		
Mean ± SD.	238.95 ± 11.91	274.33 ± 29.82	310.07 ± 50.47	23.205*	<0.001*
Median (IQR)	239.50 (234.50–247.0)	279.50 (265.0 – 289.0)	293.50 (278.0 – 357.0)		
Sig. bet. Grops	$p_1=0.003^*, p_2<0.001^*, p_3=0.001^*$				

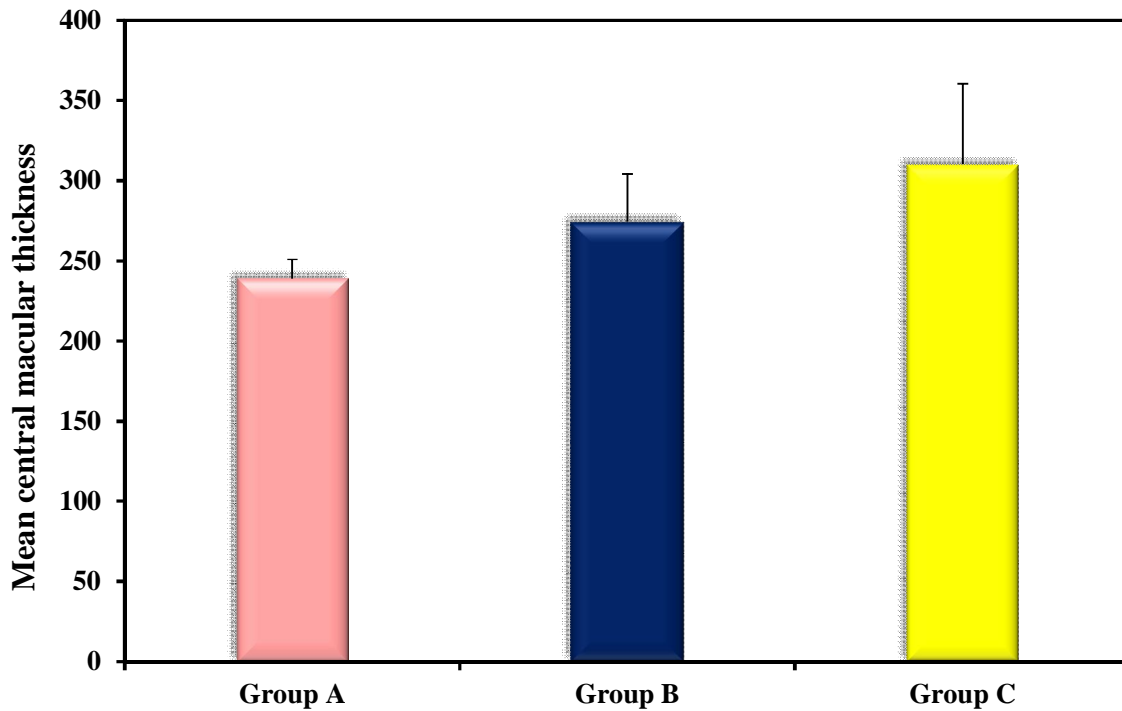


Figure (1): Central macular thickness

Table (4): Subfoveal choroidal thickness

Subfoveal Choroidal thickness	Group A (n =20)	Group B (n =30)	Group C (n =30)	F	P
Min. – Max.	157.0 – 299.0	148.0 – 263.0	160.0 – 299.0		
Mean ± SD.	247.40 ± 46.18	195.63 ± 28.96	203.10 ± 27.74	15.658*	<0.001*
Median (IQR)	254.50 (230.50–286.50)	193.50 (178.0 – 211.0)	200.0 (188.0 – 219.0)		
Sig. bet. Grops	$p_1<0.001^*, p_2<0.001^*, p_3=0.667$				

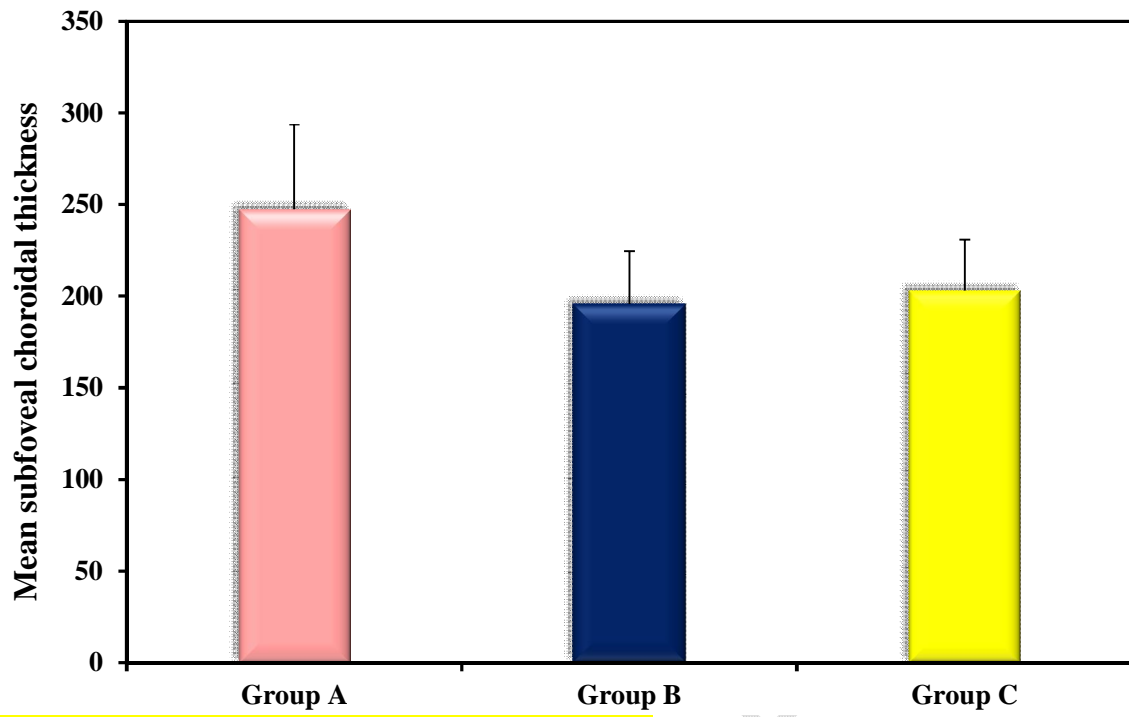


Figure (2): Subfoveal Choroidal thickness

UNDER PEER RE

Table (5): Retinal nerve fiber layer thickness

RNFL thickness	Group A (n =20 eyes)		Group B (n =30 eyes)		Group C (n =30 eyes)		χ^2	^{MC} p	
	No.	%	No.	%	No.	%			
Within normal	20	100.0	12	40.0	8	26.7			
Thinning inferior	0	0.0	10	33.3	10	33.3	37.876*	<0.001*	
Thinning superior	0	0.0	8	26.7	4	13.3			
Borderline	0	0.0	0	0.0	8	26.7			
Sig.bet.Grps	^{MC} p ₁ <0.001*, ^{MC} p ₂ <0.001*, ^{MC} p ₃ =0.013*								

IQR: Inter Quartile Range

SD: Standard deviation

F: F for ANOVA test, Pairwise comparison bet. each 2 groups was done using Post Hoc Test (Tukey)

p: p value for comparing between the studied groups

p1: p value for comparing between Group A and Group B

p2: p value for comparing between Group A and Group C

p3: p value for comparing between Group B and Group C

*: Statistically significant at $p \leq 0.05$

Group A: Normal individuals with no systemic hypertension

Group B: Systemic hypertension receiving beta blockers.

Group C: Systemic hypertension receiving calcium channel blockers

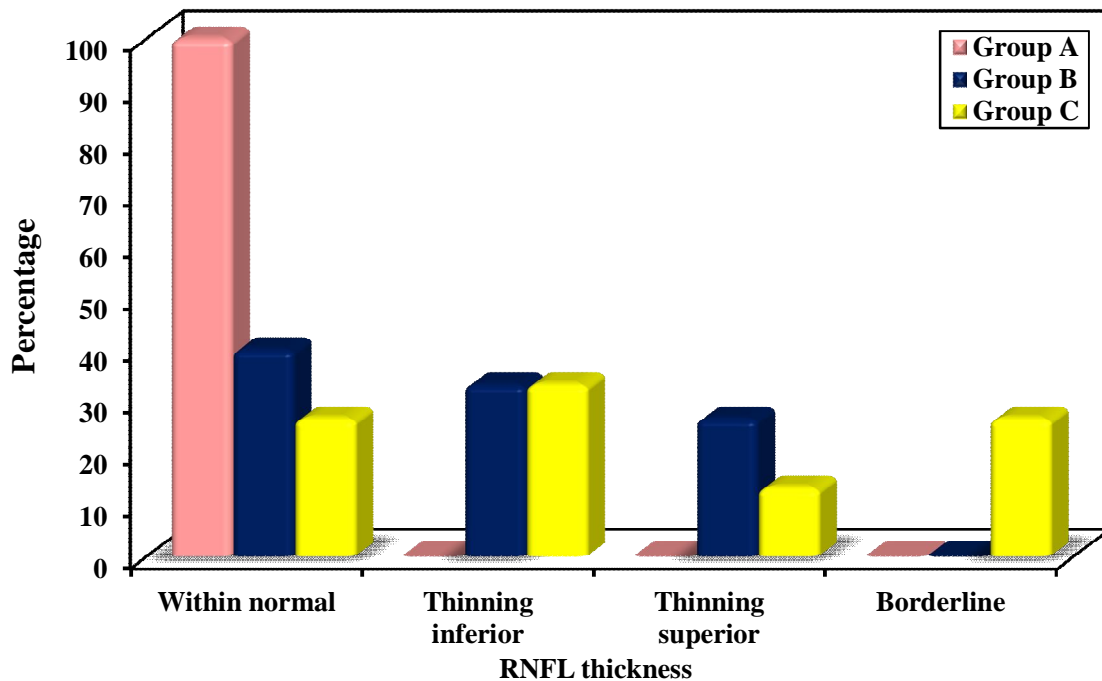


Figure (3): Retinal nerve fiber layer thickness

4. DISCUSSION:

This study aimed to evaluate the retinal and choroidal changes in hypertensive patients receiving treatment in the form of beta blockers or calcium channel blockers compared to normal control subjects using spectral domain optical coherence tomography with enhanced depth image to visualize choroidal thickness.

“Systemic arterial hypertension affects 25% of the world’s adult population and is estimated to increase to 29% by 2025” [7]. “Approximately 90% of hypertensive cases are classified as essential hypertension, where the precise cause is unknown and it has widespread effects on the eyes” [8].

“Various changes in the eyes of hypertensive patients have been reported including retinopathy, choroidopathy, optic neuropathy, vascular abnormalities such as arterial and venous occlusive disease, retinal arteriolar **macro aneurysm** formation, and embolic events” [9].

“Systemic hypertension remains a major health problem worldwide with silent and multisystem complications” [9].

“Optical Coherence Tomography (OCT) is one of the most important non-invasive, reproducible and reliable ancillary tests for diagnosis of retinal pathology. It has allowed detailed quantitative analysis of retinal microstructure with high spatial resolution that has the advantage of segmenting the retina up to nine sector measurements rather than average thickness alone” [10]. OCT can be used for evaluation of the peripapillary retinal nerve fiber layer (RNFL), subfoveal choroidal thickness (SFCT) using EDI (**Enhanced Depth Image**) to visualize choroid, macular thickness and may provide a significant tool to detect ocular effect of hypertension and effect of therapy [11].

- Our study found that there was significant increase in the central macular thickness in group B and group C than control group. There was statistically significant difference between group A (control group) and group B ($p=0.003^*$), between group A and group C ($p<0.001^*$) and between group B and group C ($p=0.001^*$).
- This was similar to the study of Han-Min Lee, et al [12] which **demonstrated** that, at the time of initial diagnosis of hypertension, the mean central macular thickness in the hypertensive group were significantly greater than those of the control group. However longitudinal study of Han-Min Lee, et al [12] found that the central macular thickness gradually and statistically significantly decreased with time mainly 1 year of follow up, stabilization of blood pressure and the disappearance of the retinal changes evident during the early period of elevated blood pressure.
- This disagree with the study of Lee et al. [12] which found that the central macular thickness was significantly thinner in hypertensive group than those of healthy eyes.
- Those results may be explained by the retinal swelling and optic disc **edema** induced by abnormally elevated blood pressure and failure of good control in most patients, and also the small sample size which hinder for further evaluation of cases..
- Regarding SFCT it was found that there is a decrease in the mean subfoveal choroidal thickness (measured by EDI OCT) in group B (hypertensive patients receiving beta blockers) and group C (hypertensive patients receiving calcium channel blockers) than group A (control group). There was statistically significant difference between control group and hypertensive groups ($p<0.001$). There was no statistically significant difference between group B and group C.
- This results agrees with the study of Masís et al. [13] which demonstrated that the subfoveal choroidal thickness was significantly thinner in hypertensive patients compared to controls. Also a study of Akay et al. [14] demonstrated that “subfoveal choroidal thickness was significantly lower in hypertensive patients with respect to control subjects”.
- This disagrees with the study done by Gök et al. [15] which showed that there was no significant correlation of the mean SFCT with hypertension.
- “Reduced SFCT may be explained by the choroid has one of the highest blood flow rates in the body [16]. Choroidal arteries have a unique course in the choriocapillaris. They run short with few branches and supply the choriocapillaris at right angles. Due to this architecture, high blood pressure is transmitted directly to the choriocapillaris” [17]. “The choriocapillaris is controlled primarily by the sympathetic nervous system, which in response to hypertension will cause vasoconstriction” [5, 16] However, “the vasoconstriction may be overcome by a further increase in blood pressure that leads to muscle layer and endothelial damage” [5, 17]. In addition, “increased systemic arterial pressure and ophthalmic/ ciliary artery vaso-occlusion may result in choroidal ischemia [5] that may also contribute to choroidal thinning”.
- Also in this study, neither beta blockers nor calcium channel blockers had statistically significant difference on subfoveal choroidal thickness.

- As regard retinal nerve fiber layer, our study demonstrated that 40% of group B were within normal limits of thickness and 60% had thinning (mainly inferior and superior thinning), and group C had 26.7% within normal limits of thickness and 73.3% had thinning (mainly inferior, superior and borderline). There were statistically significant difference between the two hypertensive groups ($p < 0.001$).
- This study agrees with Lee et al. study [18], that found that, “the hypertensive groups showed a significantly thinner RNFL than the control group. All four sectors in the HTN groups showed greater reduction rate in RNFL thickness than those in the control group. The superior and inferior sectors showed greater reduction rates than the nasal and temporal sectors in both groups”. Also another study of Lee et al [12]. reported that “chronic hypertensive patients, even with well-controlled Blood pressure had a significantly thinner RNFL than normal controls”. Also study of Akay et al. [14] found “significantly thinner RNFL thickness at average, superior and inferior quadrants in patients with systemic arterial hypertension”.
- These results regarding RNFL thinning explained by retinal **micro vascular** changes caused by hypertension which are constriction or hardening of the retinal arteries [19].

In summary, hypertension was associated with increase in the mean **central** macular thickness compared to healthy controls. In addition, there was a significant decrease in SFCT in hypertensive groups than controls, And also there were statistically significant difference in retinal nerve fiber layer thickness between hypertensive and controls.

5. CONCLUSION

- The recent introduction of SD-OCT with EDI has enabled clinicians to evaluate a variety of ocular changes, associated with hypertensive retinopathy with detailed quantitative analysis of retinal microstructure with high spatial resolution. Also we can detect improvement with treatment.
- Our study showed that anti hypertensive medication in the form of beta blockers or calcium channel blockers does not improve ocular changes associated with sustained hypertension because CMT slightly increased, SFCT slightly decrease and RNFL thickness decreased in comparison to normotensive patients.

ETHICAL APPROVAL AND CONSENT

The study adhered to the tenets of the Declaration of Helsinki and all patients signed a written informed consent to participate in the study and for publication of data before enrollment in the study after approval from the ethical committee, Faculty of Medicine, Tanta University.

REFERENCES

1. Chatterjee S, Chattopadhyay S, Hope-Ross M, Lip PL. Hypertension and the eye: changing perspectives. *J Hum Hypertens*. 2002; 16(10):667-75.
2. Pontremoli R, Sofia A, Tirota A, Ravera M, Nicoletta C, Viazzi F, et al. The deletion polymorphism of the angiotensin I-converting enzyme gene is associated with target organ damage in essential hypertension. *J Am Soc Nephrol*. 1996; 7(12):2550-8.
3. Poulter NR. Independent effects of smoking on risk of hypertension: small, if present. *J Hypertens*. 2002; 20(2):171-2.
4. Wolffsohn JS, Hurcomb PG. Hypertension and the eye. *Curr Hypertens Rep*. 2002; 4(6):471-6.
5. Tso MO, Jampol LM. Pathophysiology of hypertensive retinopathy. *Ophthalmology*. 1982; 89(10):1132-45.
6. Frank RN. The eye in hypertension. In: Izzo JL, Black HR (eds). *Hypertension Primer*. Dallas, TX: Lippincott Williams & Wilkins; 2003. 209-11.
7. Mittal BV, Singh AK. Hypertension in the developing world: challenges and opportunities. *Am J Kidney Dis*. 2010; 55(3):590-8.
8. Kearney PM, Whelton M, Reynolds K, Whelton PK, He J. Worldwide prevalence of hypertension: a systematic review. *J Hypertens*. 2004; 22(1):11-9.
9. Henderson AD, Bruce BB, Newman NJ, Biousse V. Hypertension-related eye abnormalities and the risk of stroke. *Rev Neurol Dis*. 2011; 8(1-2):1-9.
10. Bruce A, Pacey IE, Dharni P, Scally AJ, Barrett BT. Repeatability and reproducibility of macular thickness measurements using fourier domain optical coherence tomography. *Open Ophthalmol J*. 2009; 3:10-4.
11. Konstantinidis L, Guex-Crosier Y. Hypertension and the eye. *Curr Opin Ophthalmol*. 2016; 27(6):514-21.
12. Lee HM, Lee WH, Kim KN, Jo YJ, Kim JY. Changes in thickness of central macula and retinal nerve fibre layer in severe hypertensive retinopathy: a 1-year longitudinal study. *Acta Ophthalmol*. 2018; 96(3):e386-e92.
13. Masís M, Hernandez E, Wu L. Choroidal Thickness in Patients with Systemic Hypertension. *Invest Ophthalmol Vis Sci*. 2011; 52(14):5296.
14. Akay F, Gundogan FC, Yolcu U, Toyran S, Uzun S. Choroidal thickness in systemic arterial hypertension. *Eur J Ophthalmol*. 2016; 26(2):152-7.
15. Gök M, Karabas VL, Emre E, Aksar AT, Aslan MS, Ural D. Evaluation of choroidal thickness via enhanced depth-imaging optical coherence tomography in patients with systemic hypertension. *Indian J Ophthalmol*. 2015; 63(3):239-43.
16. Parver LM. Temperature modulating action of choroidal blood flow. *Eye (Lond)*. 1991; 5 (Pt 2):181-5.
17. Nickla DL, Wallman J. The multifunctional choroid. *Prog Retin Eye Res*. 2010; 29(2):144-68.
18. Lee SH, Lee WH, Lim HB, Jo YJ, Kim JY. Thicknesses of central macular, retinal nerve fiber, and ganglion cell inner plexiform layers in patients with hypertension. *Retina*. 2019; 39(9):1810-8.
19. Lee MW, Lee WH, Park GS, Lim HB, Kim JY. Longitudinal Changes in the Peripapillary Retinal Nerve Fiber Layer Thickness in Hypertension: 4-Year Prospective Observational Study. *Invest Ophthalmol Vis Sci*. 2019; 60(12):3914-9.