

***Ficus thonningii* leaf extract and its ameliorative effect on hepatic enzymes of acetaminophen-induced liver necrosis in wistar rats**

ABSTRACT

Acetaminophen is a highly used over-the-counter drug, and a good number of drug-related liver necrosis are associated with high doses of acetaminophen. In the last decade, drug-related liver necrosis has been the most reported form of liver disease. In view of this, our research sought to determine the possible ameliorative effect(s) of *Ficus thonningii* leaf extract on hepatic enzymes of acetaminophen-induced liver necrotic albino wistar rats. For the study, total of 36 wistar rats were divided into six groups (A-F) with six animals in each group. Group A served as the positive control group, and rats were fed *ad libitum* throughout the experiment. Group B was the leaf extract control group, 2,000 mg/kg body weight of leaf extract was administered all through the treatment period. Group C served as acetaminophen control group, 1,000 mg/kg body weight of acetaminophen was administered throughout the inducement period, and fed *ad libitum* afterwards. Groups D, E and F were the test groups, liver necrosis was induced with 1,000 mg/kg body weight and they were afterwards treated with 250 (low dose), 500 (medium dose) and 1,000 (high dose) mg/kg body weight of *Ficus thonningii* leaf extract respectively. At the end of each treatment week (which lasted for 3 weeks), two animals from each group were sacrificed and blood sample collected. Serum was used to determine hepatic enzymes (Aspartate Aminotransferase, Alanine Aminotransferase and Alkaline Phosphatase) using COBAS C311 auto-analyzer. Data obtained

were analyzed by one-way ANOVA. No significant decrease in serum alkaline phosphatase level in liver necrotic rats administered 250, 500, as well as those given 1,000 mg/kg body weight of *Ficus thonningii* leaf was observed at the end of the first, second and third week of treatment. Serum alkaline aminotransferase level also followed the same trend, where no significant difference was observed. No significant difference in serum aspartate aminotransferase level was recorded in the low dose and medium dose test groups (i.e. rats treated with 250 and 500 mg/kg body weight of *Ficus thonningii* leaf extract respectively), however, there was a significant decrease in the high dose test group (treated with 1,000 mg/kg body weight of leaf extract) with $P=0.037$, thus strengthening findings of other researchers, that *Ficus thonningii* leaf extract is hepatoprotective at high concentrations.

Keywords: *Ficus thonningii* leaf, Acetaminophen, hepatic enzymes, wistar rats, liver necrosis.

INTRODUCTION

Ficus thonningii is one of the ‘strangler figs’, so-called for its habit of ‘strangling’ other plants as their roots and stems struggle to find nourishment and light in their original habitat” (Dangarembizi, 2013). “The roots supply nutrients to the fig, allowing it to grow faster than the host tree. In Nigeria, *Ficus thonningii* is predominant among the Igedes in Benue State and Fulanis in Sokoto State” (Ahur *et al.*, 2010), it belongs to the family Moraceae and falls into the genus *Ficus*. It is native to Africa (predominantly Nigeria) and has diverse economic, medicinal and environmental uses across many farming and pastoral communities in Africa (Balehegn *et al.*, 2015). Some researchers have reported on the possible hepatoprotective activity of *Ficus thonningii* in cases of acetaminophen intoxicity (Enogieru *et al.* (2015) , “which was attributed to the presence of flavonoid and saponin compounds in *Ficus thonningii* leaf extract. *Ficus thonningii* is a well-known ornamental tree that is also used in improving agroforensic systems. Its

leaves are used as fodder and its bark is used for making bark cloth” (Bamikole and Ikhatua, 2010).

“The prohibitive cost of conventional medicines and their limited availability especially to rural communities in Africa and other developing regions have driven the continued dependence on traditional therapeutics. About 75-90% of the world population rely on plants(their extracts in particular) as a source of primary healthcare” (Benzie and Watchel-Galor, 2011).”With increased incidence of liver necrosis in the last decade as a result of drug misuse and abuse, there is a worldwide trend to go back to traditional medicinal plants in the treatment of liver necrosis as synthetic drugs used in the treatment of liver diseases have serious adverse side effects and are often times inadequate” (Syed *et al.*, 2012, Taj *et al.*, 2019).“Plant-based remedies have proven to be useful in the treatment and management of diseases and they are used extensively in ethno-medical and ethno-veterinary practice” (Umar *et al.*, 2017).

Acetaminophen is a highly used over-the-counter drug, and a good number of drug-related liver necrosis are associated with high doses of acetaminophen (Bernal *et al.*, 2010) and most therapies used for the management of liver necrosis are hepatotoxic and often times inadequate(Enogieru *et al.*, 2015). Several previous studies have shown that some foods and plants have protective effects on the liver against induced biochemical toxicity(Lala, *et al.*, 2022).

According to Shivakumar (2014), “acetaminophen-induced albino wistar rats exhibited significant elevation of serum marker enzymes alanine aminotransaminase, aspartate aminotransaminase, alkaline phosphatase and increased concentration of bilirubin (Total and Direct) indicating hepatic damage when compared with normal control group. It was also observed that the elevation of serum enzymes as a result of acetaminophen intoxication was dose-dependent”. In the same vein, Iyanda and Adeniyi (2011) “in a publication reported significant increases in the serum levels of hepatic enzymes especially at toxic levels of exposure to acetaminophen”.Other researchers, Yuan

and Kaplowitz (2013), Wang *et al.* (2013), reported that “numerous enzymes are produced in the liver and are normally distributed within the cells of the liver, elevation of serum enzyme is taken as a sensitive biomarker of liver toxicity. The determination of various liver enzymes in serum are used to evaluate the functional status of the liver and to detect liver injury”.

Subsequent to this initial report, many cases of acetaminophen overdose were reported over the years. Abolfazl *et al.*, (2014) described “the principal clinical symptoms as development of nausea and vomiting within 2-3 hours of ingestion, followed by abdominal pain in the right upper quadrant. Liver dysfunction occurred within 24 hours and reached maximum approximately 3-4 days after ingestion”. Dadkhah *et al.*, (2007) summarized “the clinical and biochemical changes to be a dramatic increase in serum alanine aminotransferase (ALT) and aspartate aminotransferase (AST) levels, mild hyperbilirubinemia, and increased prothrombin time as well”.

“Liver damage due to hepatotoxic agents is of dire consequence, prompting an ever increasing need for an agent which can protect it from such damage” (Enogieru *et al.*, 2015). Over the years, acetaminophen (paracetamol) has been identified as the major culprit involved in drug-induced liver necrosis (damage) (Shivakumar Hugar, 2014). With the alarming incidence of rise liver diseases (Okonkwo, et al, 2022) as a result of drug abuse and misuse, and the unavailability of rational therapy (non-toxic) in modern medicine (Ashok *et al.*, 2010), there is a pressing need for non-toxic therapies such as *Ficus thonningii*, hence the need for this study. This study sought to determine possible ameliorative effect(s) of *Ficus thonningii* leaf extract on hepatic enzymes in acetaminophen-induced liver necrotic albino wistar rats.

MATERIALS AND METHODS

Study area and animal care

The study was carried out in the Animal House, Faculty of Pharmaceutical Sciences, University of Jos, Plateau State, Nigeria.

Albino wistar rats were obtained from National Veterinary Research Institute (NVRI), Vom and were maintained in the Animal House, Faculty of Pharmaceutical Sciences, University of Jos. The rats were housed and allowed to acclimatize for one week under standard laboratory conditions in a controlled room with 12 hours light-12 hours dark cycle at room temperature of 21-25°C and 52-58% humidity. The animals were fed with Grower mash Feed® (manufactured by Grand Feed Mills Ltd Jos, Plateau State) and pyrogen-free distilled water was given *ad libitum* throughout the study.

The animals were allocated into control and experimental groups; a total of thirty six wister rats were used for the study and they were grouped into six(6) groups (A, B, C, D, E and F), consisting of six (6) rats each in groups B, D, E and F and three (3) in groups A and C based on weight and size.

The weight of each animal was determined with the aid of a weighing scale and the mean weight of each group was taken weekly throughout the period of study. The changes in the rate and quantity of food and water consumption was also taken by measuring the food and water given to each group before and after treatment on daily basis.

The experiment consisted of two (2) basic periods, the inducement period and the treatment period. The former lasted for a week, during which liver necrosis was induced in animals in certain groups using acetaminophen based on individual body weight (1000 mg/kg body weight). The animals were given acetaminophen daily all through the inducement period. On the other hand, the latter lasted for a period of three (3) weeks, during which animals in certain groups were treated with *Ficus thonningii* leaf extract (with dosage varying with different groups).

Two (2) animals each in groups B, D, E and F and one (1) each from groups A and C were sacrificed at the end of each treatment week, and samples analysed.

The grouping is as follows:

A: Rats in group A served as positive control and were fed with Grower mash and pyrogen free distilled water only (*ad libitum*).

GROUPS	A	B	C	D	E	F
TREATMENT GIVEN	Distilled water	Leaf extract (2000 mg/kg)	APAP only (1000 mg/kg)	APAP + 250 mg/kg B.W. of extract	APAP + 500 mg/kg B.W. of extract	APAP + 1000 mg/kg B.W. of extract
NO. OF RATS	3	6	3	6	6	6

B: Rats in group B were not induced with liver necrosis, but were given *Ficus thonningii* leaf extract throughout the treatment period. This served as the first negative control group.

C: Rats in group C were induced with liver necrosis using acetaminophen, but were not treated with *Ficus thonningii* leaf extract. They were fed *ad libitum* throughout the treatment period. This served as the second negative control group.

D: Rats in group D were induced with liver necrosis using acetaminophen and then treated with 250 mg/kg body weight of the leaf extract. This served as the ‘Low Dose Group’.

E: Rats in group E were induced with liver necrosis using acetaminophen and then treated with 500 mg/kg body weight of the leaf extract. This served as the ‘Medium Dose Group’.

F: Rats in group F were induced with liver necrosis using acetaminophen and then treated with 1000 mg/kg body weight of the leaf extract. This served as the ‘High Dose Group’.

1st week	3	6	3	6	6	6
2nd week	2	4	2	4	4	6
3rd week	1	2	1	2	2	2
4th week	-	-	-	-	-	-

Table 3.1: Experimental design

Key

APAP: Acetaminophen

B.W.: Body Weight

Extract: *Ficus thonningii* leaf extract

PLANT MATERIAL

The leaves of *Ficus thonningii* were obtained from University of Jos in Plateau State, Nigeria and were identified in the herbarium and authenticated by the Department of Plant Science and Technology, Faculty of Natural Sciences, University of Jos, Plateau State, Nigeria. A Voucher Number (UJH000314) was issued by the Authenticating Officer.

Table 3.2: Macroscopic features of harvested *Ficus thonningii* leaf

Parameters	Fresh Leaf	Powdered Leaf
Condition	Moist and sticky	Dry
Shape	Elliptic	-
Colour	Green	Grey
Odour	Characteristic	Characteristic
Fracture	Fibrous	-
Texture	Rough	Fine/Smooth

PREPARATION OF EXTRACT

The leaves obtained were washed with distilled water, air-dried at room temperature and protected from direct sunlight for two (2) weeks. The air-dried leaves were then pulverized using a laboratory mill and the powdered samples stored in air and water-proof containers until required

for extraction. 300g of the powdered leaf was then soaked in methanol for 72 hours. The solution was filtered using Whatmann filter paper, and the filtrate concentrated with a rotary evaporator at 60°C giving a semi-solid residue. An aliquot portion of the extract was stored in a laboratory refrigerator and measured portions subsequently reconstituted in pyrogen-free distilled water at appropriate concentration on each day of the experiment.

DETERMINATION OF ORAL LETHAL DOSE (LD₅₀) OF FICUS THONNINGII (LORKES, 1983).

A total number of 16 albino wistar rats were used for determining the oral lethal dose of *Ficus thonningii* leaf extract.

The first phase of the experiment consisted of 12 rats, 9 rats were used for the test group while 3 rats were treated as control and were given pyrogen-free distilled water only.

The test group containing 9 rats was further sub-divided into 3 groups and marked accordingly, for the administration of 10mg/kg body weight, 100mg/kg body weight and 1000mg/kg body weight of *Ficus thonningii* leaf extract respectively.

The average weights of the 3 wistar rats in each test group were measured and the appropriate amount of the leaf extract to be administered was calculated (in milliliters (ml)).

The appropriate concentration of the aqueous *Ficus thonningii* leaf extract was administered to each group of wistar rats.

The rats were fed more than an hour before administration and were not fed again until after 24 hours. They were then observed for death after 24 hours.

No death was reported after 24 hours, hence the second phase of the experiment was conducted.

In the second phase, four (4) rats that were not used in the first phase of the experiment were used. Three of the rats were given a concentration of 1600, 2900 and 5000mg/kg body weight of

Ficus thonningii leaf extract respectively and the last rat (i.e the fourth rat) served as the control (given pyrogen-free distilled water only).

Oral LD₅₀ Determination of *Ficus thonningii* leaf extract

Phase	Group	Number of Rats used	Dose (mg/kg)
Phase 1	1	3	10
2	3	100	
3	3	1000	
Phase 2	4	1	1600
5	1	2900	
6	1	5000	

SACRIFICE OF ANIMALS

Two (2) animals each from groups B, D, E and F were sacrificed while one (1) animal each from groups A and C was sacrificed at the end of each week. All animals were painlessly sacrificed under chloroform anaesthesia and a midline incision made through the anterior abdominal wall and blood samples were then obtained.

BIOCHEMICAL ESTIMATIONS

Samples collected were analyzed with Cobas C311 chemistry auto-analyzer at Aids Prevention Initiative in Nigeria (APIN) in Jos University Teaching Hospital (JUTH), Jos.

The blood samples obtained were transferred to chemically clean plain sample bottles (without anticoagulant or blood preservative). The samples were allowed to clot and spun for five (5) minutes at 5,000 rpm to obtain serum. Serum obtained was used for the estimation of Alanine aminotransferase (ALT), Aspartate aminotransferase (AST) and Alkaline Phosphatase (ALP).

STATISTICAL ANALYSIS

Data collected were analyzed using Statistical Package for Social Sciences (SPSS), windows version 20.0 software and Microsoft excel 2013. Data generated were also presented as Mean \pm Standard Deviation and $p < 0.05$ was considered to be statistically significant.

RESULTS

The result of acute toxicity testing (LD_{50}) of *Ficus thonningii* methanolic leaf extract in wistar rats is shown in table 1. In the first phase of the test, none of the three animals that were administered 10 mg/kg body weight of the leaf extract died, likewise those administered 100 mg/kg body weight and 1,000 mg/kg body weight of the leaf extract. In the second phase of the test, animals were administered 1,600, 2,900 and 5,000 mg/kg body weight of *Ficus thonningii* leaf extract respectively, and they all survived after 24 hours of administration.

TABLE 1: RESULT OF ACUTE TOXICITY TESTING (LD_{50}) OF *Ficus thonningii* METHANOLIC LEAF EXTRACT IN WISTAR RATS

DOSE (mg/kg)	MORTALITY	
	FIRST PHASE	SECOND PHASE

10	0/3	
100	0/3	
1000	0/3	
1600		0/1
2900		0/1
5000		0/1

KEY:

1. 0/3 means none of the wistar rats died out of three wistar rats in a group.
2. 0/1 means none of the wistar rats died in each group of one wistar rat after 24 hours of the experiment.

Our study shows that animals in Group A (Positive control group) were fed *ad libitum*, had a smooth fur appearance, dark and formed faecal droppings with normal urine output, and they were very active. Those in Group B (Leaf extract control group) were administered 2,000 mg/kg body weight of the leaf extract, their fur appearance were slightly rough, soft and formed faecal droppings which had an offensive odour, increased urine output was observed, and they were active. While those in Group C (APAP control group) were administered 1,000 mg/kg body weight of acetaminophen, they had rough fur appearance, the faecal droppings and urine output were same with those in Group B, but faecal droppings appeared mucoid, and the animals were less active. Wistar rats in Group D (Low dose test group) were induced with 1,000 mg/kg body weight of acetaminophen and later treated with 250 mg/kg body weight of *Ficus thonningii* leaf extract, their fur appeared rough, with soft and formed faecal dropping that had an offensive odour, urine output was increased and the animals were less active. Physical observations of animals in Group E (Medium dose test group) were same with that of Group D, although both groups were induced with 1,000 mg/kg body weight of acetaminophen alike, Group E animals were treated with 500

mg/kg body weight of the leaf extract. Animals in Group F (High dose test group) were induced with with 1,000 mg/kg body weight of acetaminophen and treated with 1,000 mg/kg body weight of the leaf extract, the physical observations were same with those obtained from Groups D and E, except for the fact that the offensive odour of the faecal droppings eventually faded out and the offensive odour disappeared with time as shown in table 2.

TABLE2: GENERAL OBSERVATION OF WISTAR RATS INDUCED WITH NECROSIS AND TREATED WITH *Ficus thonningii* LEAF EXTRACT

GROUP	TREATMENT GIVEN	FUR APPEARANCE	FAECAL DROPPINGS	URINE OUTPUT	ALERTNESS/ACTIVITY
A	Distilled water	Smooth	Dark, formed	Normal	Very active
B	Leaf extract	Slightly rough	Soft, formed, offensive odour	Increased	Active
C	APAP only 1000 mg/kg	Rough	Soft, formed, offensive odour and mucoid	Increased	Less active
D	APAP + 250 mg/kg of extract	Rough	Soft, formed, offensive odour	Increased	Less active
E	APAP + 500 mg/kg of extract	Rough	Soft, formed, offensive odour	Increased	Less active

F	APAP + 1000 mg/kg of extract	Rough	Soft, formed, offensive odour and later normal	Increased	Less active
----------	------------------------------------	-------	---	-----------	-------------

In the first week of the experiment, two animals each died in Groups A and C, resulting to 33.3% as the percentage mortality in each group. no death was recorded in Groups B, D, E and F, the percentage mortality of these groups was 0%. No death was recorded in all groups in the second week of the experiment, with the exception of Group C with a record of one death, giving rise to a percentage mortality of 16.6%. in the third week of the experiment, only one death was recorded in Group A, giving rise to a percentage mortality of 16.6%. as indicated in table 3.

TABLE 3: PERCENTAGE MORTALITY IN WISTAR RATS INDUCED WITH NECROSIS AND TREATED WITH *Ficus thonningii* LEAF EXTRACT

WEEKS	EXPERIMENTAL GROUPS					
	A(N=6)	B(N=6)	C(N=6)	D(N=6)	E(N=6)	F(N=6)
1	33.3	0	33.3	0	0	0
2	0	0	16.6	0	0	0
3	16.6	0	0	0	0	0

Two deaths each (33.3%) were recorded in Groups A and C (1st week of experiment), one death (16.6%) in Group C (2nd week of experiment) and one death (16.6%) in Group A (3rd week of experiment) while the work lasted. Values presented are in percent (%).

KEY:

A: Distilled water (Normal Control)

B: Leaf extract, 2000 mg/kg

C: APAP only, 1000 mg/kg

D: APAP + 250 mg/kg of extract

E: APAP + 500 mg/kg of extract

F: APAP + 1000 mg/kg of extract

N: 6 (Number of wistar rats in each group)

The mean body weight (in grams) of wistar rats in all groups throughout the experiment is shown in Figure 1. In Group A, the initial mean body weight was 100.6g, 106.1g in the first week, 104.3g in the second week and 103.9g in the third week of the experiment. In Group B, the initial mean body weight was 117.3g, 115.4g in the first week, 112.7g in the second week and 110.8g in the third week of the experiment. In Group C, the initial mean body weight was 133.1g, 131.1g in the first week, 130.2g in the second week and 127.2g in the third week of the experiment. In Group D, the initial mean body weight was 142.3g, 139.0g in the first week, 138.0g in the second week and 134.9g in the third week of the experiment. In Group E, the initial mean body weight was 110.4g, 108.5g in the first week, 109.0g in the second week and 108.2g in the third week of the experiment. In Group F, the initial mean body weight was 148.8g, 147.2g in the first week, 139.7g in the second week and 134.4g in the third week of the experiment.

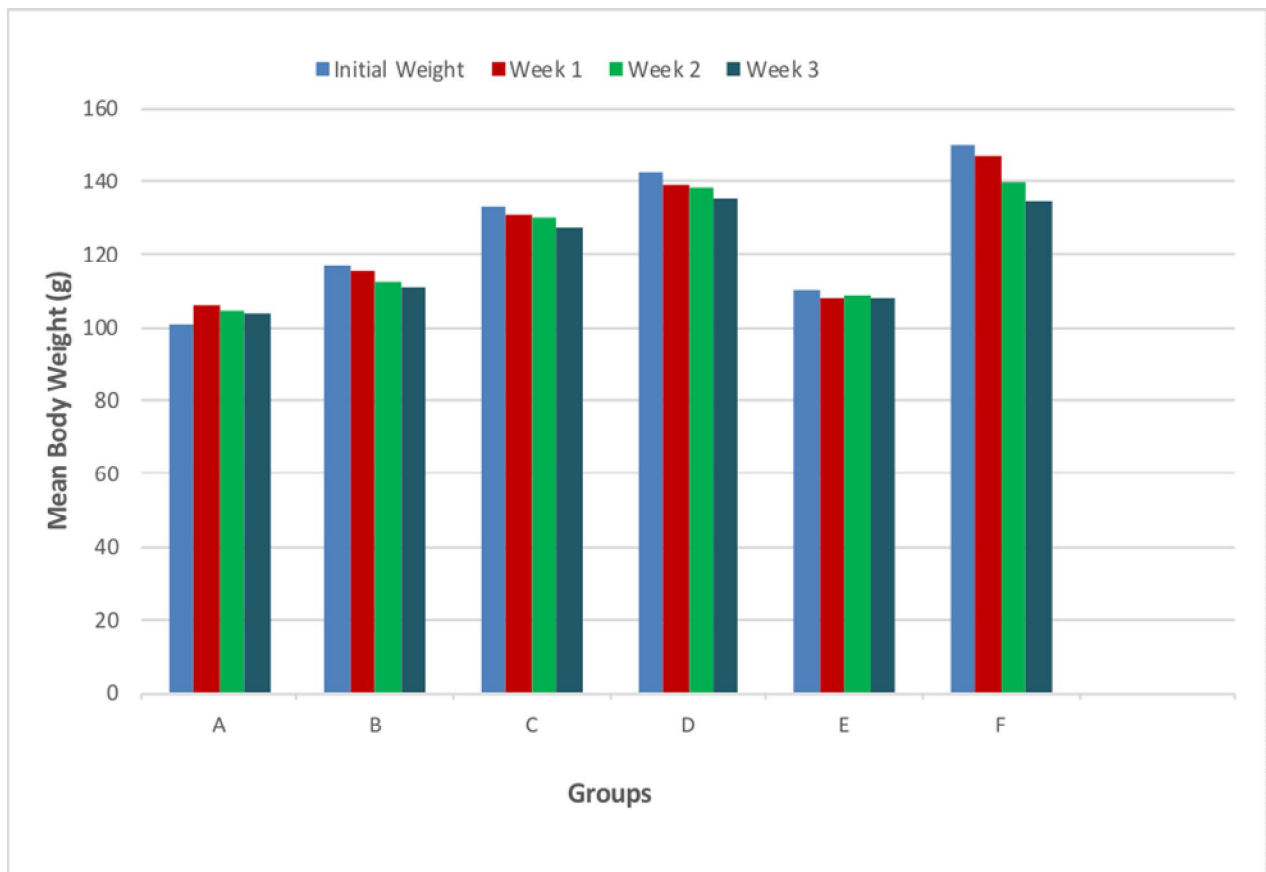


Figure1: Bar Chart showing Mean Body Weight (g) of wistar rats

KEY:

A: Distilled water (Normal Control)

B: Leaf extract, 2000 mg/kg

C: APAP only, 1000 mg/kg

D: APAP + 250 mg/kg of extract

E: APAP + 500 mg/kg of extract

F: APAP + 1000 mg/kg of extract

Table 4 shows possible effect of *Ficus thonningii* leaf extract on aspartate aminotransferase of induced liver necrotic rats in Group A, aspartate aminotransferase level of 199.90 IU/L was obtained in the first week. 277.90 IU/L in the second week and 146.10IU/L in the third week of the experiment. In Group B, 193.30 ± 13.71 IU/L was obtained in the first week. 221.60 ± 8.76 IU/L

in the second week and 246.70 ± 33.79 IU/L in the third week. In Group C, 283.80 IU/L was obtained in the first week, 258.30 IU/L in the second week and 279.90 IU/L in the third week. In Group D, 292.65 ± 111.93 IU/L was obtained in the first week, 301.00 ± 5.09 IU/L in the second week and 189.85 ± 4.87 IU/L in the third week. In Group E, 202.15 ± 11.95 IU/L was obtained in the first week, 240.50 ± 12.44 IU/L in the second week and 314.05 ± 78.41 IU/L in the third week. In Group F, 179.50 ± 8.76 IU/L was obtained in the first week, 248.05 ± 16.75 IU/L in the second week and 194.80 ± 17.11 IU/L in the third week.

TABLE 4: EFFECT OF *Ficus thonningii* LEAF EXTRACT ON ASPARTATEAMINOTRANSFERASE OF INDUCED LIVER NECROTIC RATS

	Group A	Group B	Group C	Group D	Group E	Group F
Week 1	199.90*	193.30 ± 13.71^1	$283.80^{*,1}$	292.65 ± 111.93^2	202.15 ± 11.95^2	179.50 ± 8.76^2
Week 2	277.90*	221.60 ± 8.76^1	$258.30^{*,1}$	301.00 ± 5.09^2	240.50 ± 12.44^2	248.05 ± 16.75^2
Week 3	146.10*	246.70 ± 33.79^1	$279.90^{*,1}$	189.85 ± 4.87^2	314.05 ± 78.41^2	194.80 ± 17.11^2

Data is expressed as Mean \pm SD (n=2), * = Standard Deviation is equal to 0, ¹= Data is compared with Group A, ²= Data is compared with Group C, Values presented are in IU/L.

KEY:

A: Distilled water (Normal Control)

B: Leaf extract, 2000 mg/kg

C: APAP only, 1000 mg/kg

D: APAP + 250 mg/kg of extract

E: APAP + 500 mg/kg of extract

F: APAP + 1000 mg/kg of extract

While looking at the effect of *Ficus thonningii* leaf extract on alanine aminotransferase of induced liver necrotic rats, Group A, shows that alanine aminotransferase level of 60.10 IU/L was obtained in the first week, 84.00 IU/L in the second week and 53.50 IU/L in the third week of the experiment. In Group B, 50.05 ± 7.28 IU/L was obtained in the first week, 46.90 ± 6.08 IU/L in the second week and 61.05 ± 2.33 IU/L in the third week. In Group C, 62.70 IU/L was obtained in the first week, 69.30 IU/L in the second week and 70.40 IU/L in the third week. In Group D, 74.55 ± 44.47 IU/L was obtained in the first week, 71.30 ± 15.27 IU/L in the second week and 48.30 ± 0.42 IU/L in the third week. In Group E, 49.10 ± 9.75 IU/L was obtained in the first week, 66.90 ± 19.23 IU/L in the second week and 95.80 ± 57.41 IU/L in the third week. In Group F, 46.40 ± 6.36 IU/L was obtained in the first week, 59.20 ± 3.25 IU/L in the second week and 43.45 ± 3.18 IU/L in the third week as shown in table 5.

TABLE 5: EFFECT OF *Ficus thonningii* LEAF EXTRACT ON ALANINE AMINOTRANSFERASE OF INDUCED LIVER NECROTIC RATS

	Group A	Group B	Group C	Group D	Group E	Group F
Week 1	60.10 [*]	50.05 ± 7.28^1	$62.70^{*,1}$	74.55 ± 44.47^2	49.10 ± 9.75^2	46.40 ± 6.36^2
Week 2	84.00 [*]	46.90 ± 6.08^1	$69.30^{*,1}$	71.30 ± 15.27^2	66.90 ± 19.23^2	59.20 ± 3.25^2
Week 3	53.50 [*]	61.05 ± 2.33^1	$74.40^{*,1}$	48.30 ± 0.42^2	95.80 ± 57.41^2	43.45 ± 3.18^2

Data is expressed as Mean \pm SD (n=2), ^{*} = Standard Deviation is equal to 0, ¹ = Data is compared with Group A, ² = Data is compared with Group C, Values presented are in IU/L.

KEY:

A: Distilled water (Normal Control)

B: Leaf extract, 2000 mg/kg

- C:** APAP only, 1000 mg/kg
D: APAP + 250 mg/kg of extract
E: APAP + 500 mg/kg of extract
F: APAP + 1000 mg/kg of extract

Table 6 shows the effect of *Ficus thonningii* leaf extract on alkaline phosphatase of induced liver necrotic rats, in Group A, alkaline phosphatase level of 143.0 IU/L was obtained in the first week, 192.00 IU/L in the second week and 144.00 IU/L in the third week of the experiment. In Group B, 218.00 ± 38.18 IU/L was obtained in the first week, 91.50 ± 16.26 IU/L in the second week and 177.50 ± 34.64 IU/L in the third week. In Group C, 320.00 IU/L was obtained in the first week, 166.00 IU/L in the second week and 273.00 IU/L in the third week. In Group D, 259.50 ± 48.79 IU/L was obtained in the first week, 282.50 ± 256.16 IU/L in the second week and 167.50 ± 0.70 IU/L in the third week. In Group E, 218.00 ± 8.48 IU/L was obtained in the first week, 155.50 ± 40.30 IU/L in the second week and 267.50 ± 98.28 IU/L in the third week. In Group F, 159.00 ± 57.98 IU/L was obtained in the first week, 194.00 ± 7.07 IU/L in the second week and 268.50 ± 19.21 IU/L in the third week.

TABLE 6: EFFECT OF *Ficus thonningii* LEAF EXTRACT ON ALKALINE PHOSPHATASE OF INDUCED LIVER NECROTIC RATS

	Group A	Group B	Group C	Group D	Group E	Group F
Week 1	143.00*	218.00 ± 38.18 ¹	320.00* ¹	259.50 ± 48.79 ²	218.00 ± 8.48 ²	159.00 ± 57.98 ²
Week 2	192.00*	91.50 ± 16.26 ¹	166.00* ¹	282.50 ± 256.16 ²	155.50 ± 40.30 ²	194.00 ± 7.07 ²
Week 3	144.00*	177.50 ± 34.64 ¹	273.00* ¹	167.50 ± 0.70 ²	267.50 ± 98.28 ²	268.50 ± 19.21 ²

Data is expressed as Mean \pm SD (n=2), * = Standard Deviation is equal to 0, ¹= Data is compared with Group A, ²= Data is compared with Group C, Values presented are in IU/L.

KEY:

- A:** Distilled water (Normal Control)
- B:** Leaf extract, 2000 mg/kg
- C:** APAP only, 1000 mg/kg
- D:** APAP + 250 mg/kg of extract
- E:** APAP + 500 mg/kg of extract
- F:** APAP + 1000 mg/kg of extract

DISCUSSION

Our work suggests that the lethal dose i.e dose that will result in 50% death of a population of *Ficus thonningii* leaf extract is greater than 5000mg/kg. This is an indication of high level of safety of the leaf extract which is in line with the work of Ahur et al. (2010), who stated that any substance with LD₅₀ estimated to be greater than 2000-5000 mg/kg body weight given orally could be considered of low toxicity and safe. The lethal dose (LD₅₀), being greater than 5000 mg/kg body weight, is thought to be safe as suggested by Lorke (1983) and this is in agreement with Enogieru et al. (2015) and Bader et al. (2017) who both reported in separate works that the acute oral lethal dose of *Ficus thonningii* leaf extract in rats was greater than 5000 mg/kg. The absence of toxicity signs or death among rats in all the dose groups throughout the forty-eight hours of the experimental period suggests that lethal dose of *Ficus thonningii* leaf extract is greater than 5000 mg/kg body weight.

The rats control group (A) did not record any abnormal behavior during the experiment as compared with the treatment groups which showed significant changes such as rough fur appearance, stool was soft, formed mucoid with offensive odour, increased urination, reduced activity and alertness. This is in contrast to the work of Dangarembizi *et al.* (2014) who observed that treatment of rats with *Ficus thonningii* leaf extract resulted in no significant treatment-related changes including behavioural observations. All animals in groups C, D, E and F (induced liver

necrosis) survived acute phase of inducement and consequently produced rough furs and became less active following a period of liver necrosis this is inline with the findings of Badiora *et al.* (2016).

Two deaths each were recorded in groups A and C in the first week of the experiment, one death in group C in the second week and one death in group A in the third week. These deaths maybe as a result of choking due to the improper administration of fluids, confirming the claims of Abolfazl *et al.* (2014) who discovered that improper administration of fluids may lead to choking and subsequently death.

Progressive increase in body weight was observed with the control group which was in contrast to some in the treatment group which showed slight decrease in body weight. On the other hand, rats in groups B, C, D and F showed marked decrease in body weight compared to those in groups A and E, with group F (group treated with high dose of the leaf extract) being the most pronounced. This is in agreement with the findings of Gopinathan and Rameela (2015) and Karandikar *et al.* (2016) who reported that rats treated with *Ficus thonningii* leaf extract showed a significant reduction in body weight. However, this contrasts the findings of Yakout *et al.* (2015) who reported that there was no significant change in body weight of rats during acute as well as sub-chronic treatment with *Ficus thonningii* leaf extract.

A look at the possible effect of *Ficus thonningii* leaf extract on Aspartate Aminotransferase of acetaminophen-induced liver necrotic albino wistar rats indicates serum level were lower than values obtained from the positive control group (Group A). This confirms the findings by Dangarembizi *et al.* (2014) which stated that Aspartate Aminotransferase level was significantly decreased in liver necrotic albino wistar rats treated with *Ficus thonningii* leaf extract. This is also in support of the findings of Ahur *et al.* (2010) that suggested that the flavonoid component of

Ficus thonningii leaf extract is capable of lowering serum hepatic enzymes. Aspartate Aminotransferase levels of rats in group C (acetaminophen control group) were significantly elevated when compared with control group. This is in line with the findings of Bari and Fontana (2014) who reported that acetaminophen overdose elevates serum Aspartate Aminotransferase levels. Shivakumar (2014) also reported that acetaminophen overdose increases Aspartate Aminotransferase levels in albino wistar rats. From the test groups, Aspartate Aminotransferase levels in groups D and E when compared with group C showed no significant decrease. This is in line with the findings of Dangarembizi *et al.* (2014), which stated that Aspartate Aminotransferase level showed no significant decrease in liver necrotic albino rats treated with *Ficus thonningii* leaf extract.

The mean values of Alanine Aminotransferase obtained from specimens from group B were lower than values obtained from the positive control group (Group A), thus validating the findings of Badiora *et al.* (2016), which stated that *Ficus thonningii* leaf extract was capable of suppressing elevated alanine Aminotransferase of acetaminophen-induced liver necrotic albino wistar rats. Alanine Aminotransferase levels of rats in group C (acetaminophen control group) were significantly elevated when compared with those in group A. This is in line with the findings of Bari and Fontana (2014) who reported that acetaminophen overdose elevates serum Alanine Aminotransferase levels. Shivakumar (2014) also reported that acetaminophen overdose increases Alanine Aminotransferase levels in albino wistar rats. Alanine Aminotransferase levels from all test groups (groups D, E and F) compared with group C showed no significant decrease. This is in line with the findings of Dangarembizi *et al.* (2014), which stated that Alanine Aminotransferase level was not significantly decreased in liver necrotic albino rats treated with *Ficus thonningii* leaf extract.

The Alkaline Phosphatase of acetaminophen-induced liver necrotic albino wistar rats from group B were higher than values obtained from the control group, which is in contrast to the work of Badiora *et al.* (2016), who stated that there was no significant difference between the control group and that treated with *Ficus thonningii* leaf extract. Alkaline Phosphatase levels of rats in the acetaminophen control group were significantly elevated when compared with control group. This is in line with the findings of Bari and Fontana (2014) who reported that acetaminophen overdose elevates serum Alkaline Phosphatase levels. Shivakumar (2014) also reported that acetaminophen overdose increases Alkaline Phosphatase levels in albino wistar rats. Alkaline Phosphatase levels from all test groups (groups D, E and F) showed no significant decrease. This is in line with the findings of Dangarembizi *et al.* (2014), which stated that Alkaline Phosphatase level showed no significant decrease in liver necrotic albino rats over prolonged treatment with *Ficus thonningii* leaf extract.

CONCLUSION AND RECOMMENDATION

The study was designed to find out the ameliorative effect of *Ficus thonningii* leaf extract on hepatic enzymes of acetaminophen-induced liver necrotic wistar rats. The findings of the study showed that leaf extract of *Ficus thonningii* ameliorates the serum level of Aspartate Aminotransferase in acetaminophen-induced liver necrotic wistar rats especially at high concentrations (1,000 mg/kg body weight of leaf extract) this is in agreement with the work of Swem *et al.* ,2020. However, the leaf extract showed no ameliorative effect on Alanine Aminotransferase and Alkaline Phosphatase both at low and high concentrations. Thus, this justifies the use of *Ficus thonningii* leaf extract in the treatment of liver diseases which show signs of abnormal levels of Aspartate Aminotransferase. In addition, further work maybe necessary to help ascertain the antioxidative properties of this plant extract.

In line with our findings, proper awareness on the potential effects of acetaminophen toxicity should be embarked upon in order to curb the menace of drug abuse and misuse. Also, further research work which is gender-based should be conducted in order to determine if the effect of *Ficus thonningii* leaf extract is gender-based.

ETHICAL CLEARANCE

Ethical clearance for the study was obtained from the Ethical Committee, Animal House, Department of Pharmacology, Faculty of Pharmaceutical Sciences, University of Jos. Having met the conditions of the Institutional Animal Care and Use (IACU) in collaboration with the Office of Laboratory Animal Welfare (OLAW), a Reference Number (F17-00379) was obtained for the study. Hence, the study was conducted in accordance with the current National Academy of Science guidelines for animal welfare.

REFERENCES

- Ahur V. M., Madubunyi I., Adenkola A. Y. and Udem S. C. (2010). The Effect of Acetyl Acetate Extract of *Ficus thonningii* (Blume) Leaves on Erythrocyte Osmotic Fragility and Haematological Parameters in Acetaminophen-treated Rats. *Com. Clin. Pathol.*, 10:1107-1111.
- Ashok Kumar Mobiya, Ashutosh Kumar Patidar, G Selvam and Jeyakandan M. (2010). Hepatoprotective Effect of Cleome Viscosa L. Seeds in Paracetamol Induced Hepatotoxic Rats. *International Journal of Pharmaceutical & Biological Archive*; 1(4): 399-403.
- Bader G. N., Mir P. A., Naqash A., Ali T., Wadoo R. and Ali S. (2017). "Phytochemical Screening and Elevation of Hepatoprotective Potential of *Swertia petiolata* Against

- Thioacetamide-induced Hepatotoxicity in Rats". *International Journal of Current Research*. 9. (06), 52737-52747.
- Badiora A. S., Agbi A. J., Ogunleye S. G., Areola J. O., Babalola O. O. (2016). Toxicological Evaluation of *Ficus thonningii* Blume(Moraceae) Stem Bark Extract on the Liver, Kidney and Testes of Adult Wistar Rats. *American Journal of Biochemistry*. 2016; 6(3): 59-71.
- Bamikole M. A. and Ikhatua U. J. (2010). Nutritional Evaluation of *Ficus thonningii* – *Panicum maximum* Mixtures in West African Dwarf Goats. *Journal of Nutrition and Food Science*.40:280-288.
- Bari K., Fontana R. J. (2014). Acetaminophen Overdose: What Practitioners Need to Know. *Clinical Liver Dis*. 2014;4:17-21.
- Benzie I. F. and Watchel-Galor S. (2011). *Herbal Medicine: Biomolecular and Clinical Aspects*. 2nd edition Nigeria: CRC Press, pp.2.
- Bernal W., Auzinger G., Dhawan A., Wendon J. (2010). Acute Liver Failure. *Lancet* 2010; 376; 190-201.
- Dadkhah A, Allameh A, Fatemi F, Rasmi Y, Ashrafihelan J. (2007). Considering the Pathologic Lesions of Liver and Changes of Plasma Alanine Transaminase and Aspartate Transaminase in Acetaminophen-induced Toxicity in Rats. *Pharm Sci*. 2007; 2: 47-54.
- Dangarembizi R., Erlwanger K., Chivandi E. (2014). Effects of *Ficus thonningii* Extracts on the Gastrointestinal Tract and Clinical Biochemistry of Sucking Rats. *African Journal of Traditional, Complementary and Alternative Medicines*. 2014; 11(2): 285-291.
- Dangarembizi Rachael, Kennedy Erlwanger, Davison Moyo and Eliton Chivandi (2013). A Review of Phytochemistry, Pharmacology and Ethnomedicinal Uses of *Ficus*

- thonningii* (Blume Moraceae). *African Journal of Traditional, Complementary and Alternative Medicines*. 10(2): 203-212.
- Enogieru A. B., Charles Y. O., Omoruyi S. I., Momodu O. I., Ezeuko V. C. (2015). Stem Bark Extract of *Ficus exasperate* Protects the Liver Against Paracetamol-induced Toxicity in Wistar Rats. *J. Appl. Sci. Environ Manage*. March 2015; Vol.19 (1): 155-159.
- Fisher K., Vuppalanchi R., Saxena R. (2015). Drug-induced Liver Injury. *Arch Pathol Lab Med*. 2015; 139:876-887.
- Gopinathan S. and Rameela N. (2015). Ameliorative Effects of *Clerodendrum phlomidis* Linn Against Oxidative Stress Induced Metabolic Syndrome in Obese Rats. *World J Pharm Res*. 4(3): 1633-1673.
- Iyanda A. A. and Adeniyi F. A. A., (2011). Biochemical and Histologic Presentations of Female Wistar Rats Administered with Different Doses of Paracetamol/methione. *Niger J. Physiol.Sci*. 26 (2011) 151-160.
- Karandikar YS, Belsare P, Panditrao A. (2016). Effect of Drugs Modulating Serotonergic System on the Analgesic Action of Paracetamol in Mice. *Indian J Pharmacol*. 48(3): 281-285.
- Lala V, Goyal A, Minter DA.(2022) Liver Function Tests. [Updated 2022 Mar 19]. In: StatPearls [Internet]. Treasure Island (FL): StatPearls Publishing; 2022
- Lee WM, Hynan LS, Rossaro L. (2009). “Intravenous N-acetylcysteine Improves Transplant free Survival in Early Stage Non-acetaminophen Acute Liver Failure”. *Gastroenterology*. 137 (3): 856-864.
- Lorke D. (1983). A New Approach to Practical Acute Toxicity Testing. *Arch Toxicol*. 1983;54 (4): 275-87.

Luo J., Xu I., Li J. and Zhao S. (2015). “Nonalcoholic Fatty Liver Disease as a Potential Risk Factor of Cardiovascular Disease”. *European Journal of Gastroenterology and Hepatology*. Vol. 27, no. 3, pp. 193-199, 2015.

Okolonkwo, B. N., Ekwempu, A. I., Brisibe, N., Konne, J. B., & Nyenke, C. U. (2022). Hepatocellular Recovery of Chronic Paraquat Induced Liver Toxicity in Vitamin E and C Treated Male Wistar Rats. *International Journal of Biochemistry Research & Review*, 31(7), 1-8. <https://doi.org/10.9734/ijbcr/2022/v31i730334>

Ozougwu J. C. and Eyo J. E. (2014). Hepatoprotective Effects of *Allium cepa* Extracts on Paracetamol Induced Liver Damage in Rats. *African Journal of Biotechnology*. 13(26): 2679-2688.

Shivakumar Hugar (2014). Hepatoprotective Activity of *Luffa cylindrical* Leaf Extract on Paracetamol Induced Liver Toxicity in Rats. *Sikkim Manipal University Medical Journal*. Volume I, No. 1, January, 2014. pp. 113-119.

Swem, Festus & Aba, Patrick & Udem, Samuel. (2020). Ameliorative Effect and In-Vivo Antioxidant Properties of Methanol Extract of *Burkea africana* Stem Bark On Acetaminophen-Induced Hepatotoxicity in Rats. 4. 36-42. 10.26538/tjnpr/v4i2.3.

Taj, D., Tariq, A., Sultana, V.(2019). Protective role of *Stokeyia indica* in liver dysfunction and associated complications in acetaminophen intoxicated rats. *Clin Phytosci* 5, 28. <https://doi.org/10.1186/s40816-019-0122-2>

Umar H. Danmalam, Salihu N., Garba I., Saidu M. Bello (2017). Pharmacognostic Evaluation of the Stem-bark of *Ficus thonningii* Blume (Moraceae). *Nigerian Journal of Pharmaceutical and Biomedical Research*. Vol.2, No. 2, August 2017.

Wang DW, Yin YM, Yao YM (2013). Advances in the Management of Acute Liver Failure. *World J Gastroenterol*. 2013;19:7069-7077.

- Yakout A. El-Senosity, Souad A. Ahmad, Ayman S. Farid, Wessam E. M. (2015).
Hepatoprotective Effect of *Asparagus racemosus* in Paracetamol Induced Hepatotoxicity
in Rats. *Benha Veterinary Medical Journal*. Vol. 28, No. 1: 133-137.
- Yuan L. and Kaplowitz N. (2013). Mechanisms of Drug-induced Liver Injury. *Clin Liver Dis*.
17:507-518.