A Rare Cause of Dysphagia: Esophageal papillomatosis complicated by squamous cell carcinoma

ABSTRACT

Esophageal papillomatosis is a fairly rare illness that is thought to have a benign clinical course. Recent findings highlight the possibility of a malignancy emerging in connection with esophageal squamous papillomatosis. A case of esophageal papillomatosis is documented, which was worsened by the development of esophageal invasive squamous cell carcinoma following numerous nondiagnostic endoscopic biopsies. In addition, the patient developed squamous cell carcinoma in the oral cavity. Extensive esophageal papillomatosis and recurrent dysphagia symptoms should prompt an examination into an underlying malignancy.

Keywords: HPV, Squamous papilloma of the esophagus, squamous cell carcinoma of the esophagus, gastroscopy

1. INTRODUCTION

Esophageal papilloma is a rare benign tumor of the oesophagus (1). It was first described by Adler et al. in 1959 (2). Its pathophysiology remains unknown (1). Two main etiologies have been proposed and appear to be synergistic (3): local irritation by gastroesophageal reflux (4,5) and Human Papillomavirus (HPV) infection (6, 7, 8).
The discovery is often fortuitous during a gastroscopy performed for other symptoms (4). Its natural history remains poorly understood, particularly its risk of malignancy. A few cases of oesophageal squamous cell carcinoma in the context of oesophageal papillomatosis have been reported (9-14), which is why no consensus on endoscopic management has been validated to date.

2. CASE PRESENTATION

A 68-year-old woman, with no history of smoking, reverse smiking or consuming smokeless tobacco , was referred to the Gastroenterology department for progressive dysphagia. The patient reported a 2-year history of heartburn, which she described as intermittent epigastric abdominal pain radiating to her chest. Her symptoms worsened with spicy food as well as coffee. The patient had been taking over-the-counter omeprazole 1 to 2 times daily for her symptoms with moderate relief.
Three months before the patient's initial evaluation, she began to experience progressive dysphagia to solids and liquids, with a remarkable weight loss. However, she reported normal bowel movements without diarrhea, constipation, hematochezia or melena.

Upperendoscopy using a 10 mm diameter endoscope revealed a non-stenotic multifocal esophageal polyps extending from 10 to 18 cm from her incisors, with no particularity in the rest of the esophageal and gastric mucosa (Figure 1). several biopsies were taken.

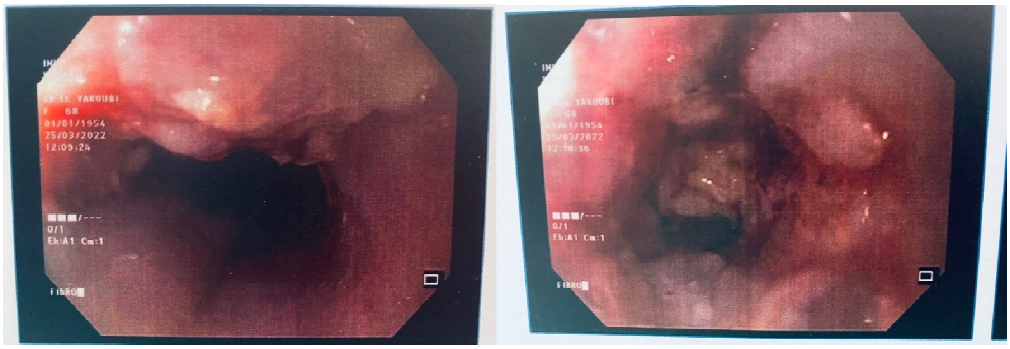

Figure 1: endoscopic image of a multifocal polypoid non-stenotic masssuggestive of esophageal papillomatosis

The biopsy specimens revealed a polypoidal esophageal mucosa that is characterized by a thickened acanthous and papillomatous squamous epithelium with preserved global architecture, and surmounted by a thick parakeratosis surface, dyskeratosis and leukokeratosis cells.
this concluded to a morphological aspect in favor of an esophageal papillomatosis accompanied by signs of Hpv viral infestation. With the presence of mycelium elements on the PAS coloration
HPV testing was not performed due to financial constraints.
The patient took 14 days of fluconazole for her esophageal candidiasis without any improvement of her dysphagia.
Because of the increasing clinical suspicion of an underlying malignancy (worsening dysphagia, the remarkable weight loss), and the risk of occult esophageal cancer, a second endoscopy was performed for further biopsies 1 month later, that showed at 10 cm from the incisors a vegetative mass completely stenotic repressing the larynx (figure 2).

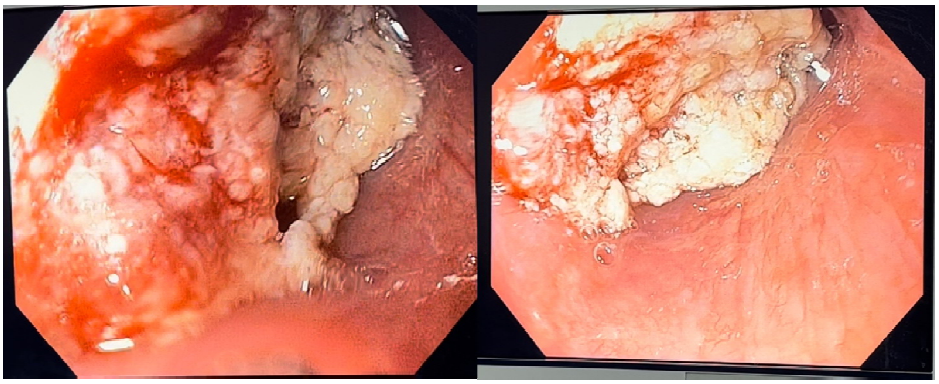

/

Figure 2: endoscopic image of vegetative mass which was histologically identified to be squamous papilloma

The biopsy specimens showed this time a well-differentiated keratinizing and infiltrating

An abdominal and chest computed tomography (CT) scan reveal an tumor-like process of the hypopharynx pushing the larynx forward, without any sign of invasion. Multiple laterocervical adenopathies, the most voluminous of which are located on the left. Without mediastinal lymphadenopathy, or other findings suggestive of malignancy or metastasis.
the case was discussed in a multidisciplinary meeting and the decision was for a surgical gastrostomy with first radiochemotherpy.

3. DISCUSSION

Esophageal squamous papilloma (ESP), is a rare lesion of the esophagus. Its prevalence varies between 0.01% and 0.45% according to literature series (1, 7, 15) of which three quarters were performed in Europe (1). And it is occurring in 0.01% of individuals at autopsy(24).
The highest prevalence has been observed in north- eastern of Italy (1).
This prevalence seems to increase with age (7). Some series found a male predominance for esophageal papilloma (7).

The Pathogenesis of ESP is unknown to date (3): two main etiological factors have been evoked. The first one is mucosal irritation which leads to an hyper-regeneration of the esophageal mucosa in response to chronic mechanical or chemical irritation (3, 7, 8) such as gastroesophageal reflux (4, 5) endobrachyoesophagus (3), peptic esophagitis (3), mechanical esophageal trauma (1) (sclerosis of oesophageal varices, metallic oesophageal prostheses...). This theory is supported by a more frequent localization of ESP in the distal esophagus (7).
The second etiological factor is a viral mechanism related to HPV infection (6). Its exact pathophysiological importance is not yet defined (1, 8).
The prevalence of HPV detection in ESP ranges from 0% to 87.5% in different published series (7,8). In some studies, histological abnormalities characteristic of HPV, were found while HPV detection remained negative (7,5). However, it is not recommended to routinely test for HPV in upper aerodigestive tract in squamous cell carcinoma (SCC), since their detection does not have therapeutic implications (17).

Figure 3 : Esophageal papillomatosis: multiple, sessile lesions extending over several centimeter

Figure 4 : Esophageal papilloma: single, flat, sessile, small lesion

For our patient, she had a positive history of heartburn for about 2 years, and specific histological abnormalities of HPV infection, which confirms the two theories above.
but the distinctive feature in this case is that the lesions are rather proximal, which calls into question the involvement of esophageal reflux in the pathophysiology of here ESP.

Esophageal papilloma is usually asymptomatic (1) and discovered incidentally during gastroscopy (11, 12). Its endoscopic appearance is characteristic but not pathognomonic (1). It can be confused with glycogenic acanthosis or verrucous carcinoma, a particular type of SCC (1).
It is described as a sessile, mostly polypoid, or pedunculated formation that is well delimited from the adjacent tissue (1, 7). It is usually small (5 mm) (3, 8) but giant forms (up to 5 cm) have been reported in the literature (1, 21). It is usually whitish or pinkish in color (7) and has a soft consistency with a smooth or slightly rough surface (1) (Figures 3-4). It is most often unique and found in the distal esophagus (3). Multiple forms, true esophageal papillomatosis, have been described in the literature (22, 23) (Figure 2). In this case, dysphagia (10, 22) may be found at diagnosis, due to esophageal stenosis caused by papillomatosis. ESP is most often removed endoscopically using diathermic snare or excisional biopsy (2).
Indeed, our patient was asymptomatic until she developed dysphagia with a real stenosing papillomatosis at the gastroscopy which confirms the quiet development of the ESP in our study too. And endoscopic characteristics of ESP were almost similar to those published in the literature, but the ESP location was unusual.
ESP is developed from the squamous epithelium of the esophageal mucosa (16). It is a benign tumor, the general architecture of the squamous epithelium is preserved as well as the integrity of the basement membrane (7, 16). There are no clear cytonuclear atypia but mitoses are more frequent than normal, and always located at the basement membrane (16). There is no invasion of the underlying connective tissue (16).
The histological lesions found are (16) (Figures 5-6):
PAPILLOMATOSIS: the epithelial ridges become longer and the basal layer of the epithelium becomes sinuous. With fine papillae centred by a small conjunctivo-vascular axis.
HYPERACANTHOSIS: the thickening of the squamous epithelium at the level of the mucous bodies of Malpighi
the HYPERKERATOSIS: the thickening of the superficial keratin layer, with two types orthokeratosis or parakeratosis.

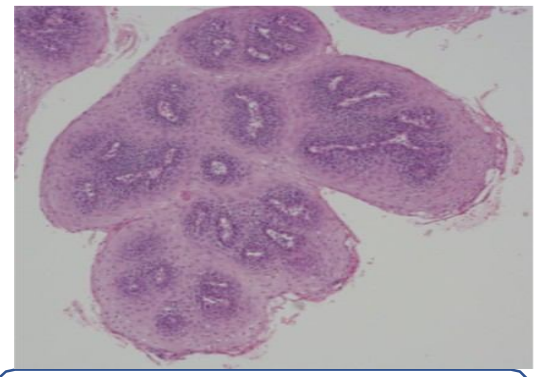

Figure 5: Histological section characteristic of an esophageal papilloma (objective x 20, Hematoxylin-eosin- stain)

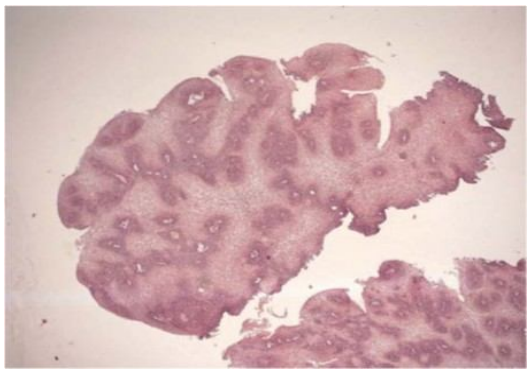

Figure 6 : Polypoid lesion with papillomatous architecture (HES × 20)

Although HPV testing was not done in our study due to financial constraints, our patient presented specific histological abnormalities suggesting an HPV infection with papillomatosis, acanthosis, and parakeratosis lesions.

ESP is a benign tumor, developed at the esophageal epithelium. Its malignant transformation has been described but remains highly debated. Only six cases of ESP complicated by

The first case was described in 1992 by Van Cutsem (9). This was a patient with esophageal papillomatosis and positive HPV test.
Waluga in 2000 also reported a case of squamous cell carcinoma on esophageal papillomatosis in a 28-year-old man discovered during a dysphagia workup. Gastroscopy revealed multiple papillomas in the upper and middle esophagus, the largest of which measured 1.5 cm. Histopathology confirmed the diagnosis of esophageal papilloma and the cervical CT scan showed tracheal infiltration. Surgical treatment was therefore performed, and the histopathology showed areas of SCC. HPV testing was not performed in this case (10).
In 2004, Reynoso described a case of ECC on papillomatosis in a 74-year-old female patient. Gastroscopy revealed multiple pearly elevated lesions, circumferential between 20 and 30 cm from the dental arches. Biopsies revealed esophageal papilloma. Because of the patient's dysphagia and the risk of occult esophageal cancer, an esophagectomy with cervical gastroesophageal anastomosis was performed. Pathology on the surgical resection specimen showed lesions of squamous cell carcinoma in situ. HPV testing by in situ hybridization was negative (11).
In 2009, Attila reported the occurrence of SCC in a 70-year-old man. A gastroscopy was performed for intermittent dysphagia, and revealed an extensive papillomatosis between 22 and 39 cm from the incisors. Biopsies performed on several occasions did not reveal lesions in favor of SCC. The patient was monitored and then operated (esophagectomy) following an esophageal food impaction. Anatomopathology found lesions of invasive differentiated SCC. The HPV test by PCR was negative (12).
Borgulya in 2011, also published the case of a 72-year-old female patient with progressive dysphagia with reflux symptoms. A gastroscopy was performed and found an esophageal mucosal alteration with a suspicious area. Biopsies were taken, and histopathology revealed papilloma lesions associated with squamous cell carcinoma in situ at the suspected esophageal area. The patient underwent esophagectomy with esogastric anastomosis. The remaining lesions on the proximal esophagus were treated with argon- plasma coagulation. Two years later, the patient presented a recurrence of squamous cell carcinoma on the remaining proximal esophagus, which was treated by endoscopic mucosecomy with success (13).The last case, described by Donnellan in 2012, corresponded to a 64-year-old woman with multiple esophageal polyps over 5 cm in the middle esophagus and a larger distal nodule of 2 cm. On pathology, the esophageal polyps were consistent with papillomatosis and the larger nodule with squamous cell carcinoma. HPV testing was not performed in this study (14).

No predictive risk factors for ESP degeneration have been found in the literature. This is partly explained by the very low number of cases of SCC on esophageal papilloma described in the literature. However, some authors suggest that the risk of malignant transformation is very low for solitary papilloma but increases in the case of esophageal papillomatosis (10) or giant papilloma (11). Donnellan et al. (14) proposed endoscopic flow up in the absence of specific treatment of ESP. However, no consensus is available to date regarding the treatment and monitoring of esophageal papilloma.

4. CONCLUSION

Extensive papillomatosis and unremitting symptoms should prompt investigations into an underlying malignancy. This finding is consistent with our case report, that also indicates that ESP and papillomatosis are not always benign lesions and emphasizes the difficulties that may occur in diagnosing a malignancy.
Extensive lesions with clinical symptoms, such as our case, may require surgical resection for concurrent diagnosis and treatment.
Endoscopists should be aware of potential malignant development in ESP, involving total removal and endoscopy surveillance. Large prospective cohorts are needed to determine the natural history of ESP.

ACKNOWLEDGEMENTS

WE THANK ALL OF AUTHORS WORK AND OUR PATIENT'S COOPERATION.

COMPETING INTERESTS

H.Mahtal and other co-authors have no conflict of interest

AUTHORS' CONTRIBUTIONS

MAHTAL HANANE: wrote the paper

BADRE WAFAA: Helped write the paper

NACER SARA : writing the paper

EL RHAOUSSI FATIMA ZAHRA: contributed with the management of the patient

TAHIRI MOHAMED: contributed with the management of the patient

HLIWA WAFAA: contributed with the management of the patient

BELLABAH AHMED: contributed with the management of the patient

HADDAD FOUAD: contributed with the management of the patient

EL MEHDI CHOUKRI: contributed with the management of the patient

KHALID EL HATTABI: contributed with the management of the patient

FATIMA ZAHRA BENSARDI: contributed with the management of the patient

ABDELILAH EL BAKOURI: contributed with the management of the patient

MOUNIR BOUALI: contributed with the management of the patient

ABDELAZIZ FADIL: contributed with the management of the patient

CONSENT

"All authors declare that 'written informed consent was obtained from the patient (or other approved parties) for publication of this case report and accompanying images. A copy of the written consent is available for review by the Editorial office/Chief Editor/Editorial Board members of this journal."

Ethical Approval:

As per international standard or university standard written ethical approval has been collected and preserved by the author(s).

REFERENCES

1. Adler RH, Carberry DM, Ross CA. Papilloma of the esophagus. Association with hiatus hernia. J Thorac Surg 1959; 37: 625-35.

2. Mosca S, Manes G, Monaco R et al. Squamous papilloma of the esophagus: long-term follow up. J Gastroenterol Hepatol 2001; 16: 857 – 861.

3. Sablich R, Benedetti G, Bignucolo S et al. Squamous cell papilloma of the esophagus: report of 35 endoscopic cases. Endoscopy 1988; 20: 5–7.

4. Talamini G, Capelli P, Zamboni G et al. Alcohol, smoking and papillomavirus infection as risk factors for esophageal squamous-cell papilloma and esophageal squamous-cell carcinoma in Italy. Int J Cancer 2000; 86(6): 874-8.

5. Takeshita K, Murata S, Mitsufuji S et al. Clinicopathological characteristics of esophageal squamous papillomas in Japanese patients with comparison of findings from Western countries. Acta Histochem Cytochem 2006; 39(1): 23-30.

6. Fernández-Rodríguez CM, Badia-Figuerola N, Ruiz del Arbol L et al. Squamous papilloma of the esophagus: report of six cases with long-term follow-up in four patients. Am J Gastroenterol 1986; 81(11): 1059-62.

7. Odze R, Antonioli D, Shocket D et al. Esophageal squamous papillomas. A clinicopathologic study of 38 lesions and analysis for human papillomavirus by the polymerase chain reaction. Am J Surg Pathol 1993; 17: 803 – 812.

8. Narayani RI, Young GS. Recurrent proximal esophageal stricture associated with dysplasia in squamous cell papillomatosis. Gastrointest Endosc 2002; 56(4): 591-4.

9. Park SH, Bang BW, Kim HG et al. A case of esophageal squamous papillomatosis. Korean J Intern Med 2012; 27(2): 243.

10. Inomata S, Aoyagi K, Eguchi K et al. Giant esophageal papilloma. Gastrointest Endosc 2004; 60(3): 430.

11. Collège Français des Pathologistes CoPath.

12. Bohn OL, Navarro L, Saldivar J et al. Identification of human papillomavirus in esophageal squamous papillomas. World J Gastroenterol 2008; 14(46): 7107-11.

13. Chang F, Janatuinen E, Pikkarainen P et al. Esophageal squamous cell papillomas: failure to detect human papillomavirus DNA by in situ hybridization and polymerase chain reaction. Scand J Gastroenterol 1991; 26: 535–43.

14. Van Cutsem E, Geboes K, Visser L. Squamous papillomatosis of the oesophagus with malignant degeneration and demonstration of the human papilloma virus. Eur J Gastroenterol Hepatol 1992; 3: 561 – 6.

15. Waluga M, Hartleb M, Sliwinski ZK et al. Esophageal squamous-cell papillomatosis complicated by carcinoma. Am J Gastroenterol 2000; 95: 1592 – 3.

16. Bouvard V, Baan R, Straif K et al. WHO International Agency for Research on Cancer Monograph Working Group. A review of human carcinogens--Part B: biological agents. Lancet Oncol 2009; 10(4): 321-2.

17. Poljak M, Orlowska J, Cerar A. Human papillomavirus infection in esophageal squamous cell papillomas: a study of 29 lesions. Anticancer Res 1995; 15(3): 965-9.

18. Chang F, Janatuinen E, Pikkarainen P, Syrjanen S, Syrjanen K. Esophageal squamous cell papillomas: failure to detect human papillomavirus DNA by in situ hybridization and polymerase chain reaction. Scand J Gastroenterol 1991; 26: 535–43

19. Orlowska J, Jarosz D, Gugulski A, Pachlewski J, Butruk E. Squamous cell papillomas of the esophagus: report of 20 cases and literature review. Am J Gastroenterol 1994; 89(3): 434-7.

20. Spinelli P. Papilloma esofagei: esperienza personale e revisione casistica. Gior Ital End Dig 1989; 12: 209-12. (In Italian with English abstract)

21. Inomata S, Aoyagi K, Eguchi K, Sakisaka S. Giant esophageal papilloma Gastrointest Endosc 2004; 60(3): 430.

22. Narayani RI, Young GS. Recurrent proximal esophageal stricture associated with dysplasia in squamous cell papillomatosis. Gastrointest Endosc 2002; 56(4): 591-4.

23. Park SH, Bang BW, Kim HG, Shin YW, Kim L. A case of esophageal squamous papillomatosis. Korean J Intern Med 2012; 27(2): 243.

24. Orlowska J, Jarosz D, Gugulski A, Pachlewski J, Butruk E. Squamous cell papillomas of the esophagus: Report of 20 cases and literature review. Am J Gastroenterol. 1994;89:434–7.