Review Article

ALPORT SYNDROME: AN OVERVIEW OF THE PATHOLOGY.

ABSTRACT

Alport syndrome(AS),also known as hereditary nephrosis, is an X-linked genetic disease that predominantly affects type IV collagen mainly in the kidneys and the eyes. It primarily affects males, particularly children, and can be transmitted via autosomal dominant and recessive inheritance modes. It typically presents with a triad of kidney involvement (nephritis), sensorineural hearing loss (SNHL), and visual impairment. Diseases related to mutation of the gene of the X chromosome include leiomyomatosis and AMME complex. AMME Complex is an acronym for alport syndrome, Midface hypoplasia, Mental retardation, and Elliptocytosis.

All type IV collagen genes must undergo mutation for the disease to occur.The most commonly implicated genes are COL4A3, COL4A4, and rarely COL4A5. It is one of the three prevalent inherited kidney diseases. In addition to others like polycystic kidney disease, cystinosis, Lowe syndrome, hereditary interstitial kidney disease, fabry disease,gittleman & barter's syndrome, and nephronophthisis.AS is considered a congenital disease.

The disease has no cure. Therapeutic strategies involve combating the symptoms and complications associated with the disease. The era of 21st-century technological evolution has clarified the diagnosis and evaluation of AS, but more studies are essential to help further understand the disease spectrum. This review article highlights the salient learning objectives to foster a better understanding of Alport syndrome for basic medical students and health professionals.

Keywords: Alport syndrome, COL4A3-5 genes, Type IV collagen,X-linked disorder, chronicrenal failure.

UNDER PEER REVIEW

INTRODUCTION

Alport syndrome (AS) is an inherited defect or disease that damages small blood vessels of the kidney, also known as a basement membrane (BM) disorder arising from the mutation of collagen type IV.This disease is characterized by sensorineural hearing loss and ocular impairment.[1]

During late childhood, patients with AS often develop sensorineural hearing loss caused by inner ear abnormalities. The affected people may also have deformed lenses in their eyes.[2]

It is also associated with thin basement membrane nephropathy (TBMN)s.[3] Patients with TBMN have disparities in the same genes that cause AS. They also have persistent hematuria, as in AS patients [3]. These patients are less likely to have extrarenal abnormalities. Proteinuria,

hypertension, kidney insufficiency, and kidney failure are less common in TBMN patientsthan AS patients. [3]People with hematuria and variants in the *COL4A3*, *COL4A4*, or *COL4A5* genes should be diagnosed with AS. In contrast, those with TGBM but no gene variant should be diagnosed with hematuria with TGBM. Differentiating alport syndrome and TBMN can be difficult, particularly in women and young patients.[3]

There are three genetic types of AS, namely:

i. X-linked AS (XLAS)- Most common, affects 80% of cases andusually occurs in males rather than females.

ii. Autosomal recessive AS (ARAS) this type occurs equally in males and females. This type affects 15% of the cases.[2]

iii. The third type is the least common, affects only 5% of the cases, and equally occurs in males and females, and this type is called autosomal dominant alport syndrome (ADAS).[1,2]

Epidemiology of Alport syndrome

Alport syndrome affects approximately 1 in every 5,000-10,000 people in the United States. Statistics show that about 0.2% of adults and about 3% of children in the United States (USA) with end-stage kidney disease have Alport syndrome [4].

AS does not affect any particular race or ethnicity more readily. In the USA, AS has been noticed to have a higher prevalence rate in Western states than in other areas [5].AS causes about 2% of pediatric end-stage renal disease cases[6].

XLAS type is the most prevalent (80-85%). The autosomal recessive mode of inheritance accounts for about 15% of the cases. The least common type is the autosomal dominant type, with only a few cases reported, which accounts for less than 5% of cases. The X-linked type of Alport syndrome is more common and has a greater severity in men than in women. [4]

ETIOPATHOGENESIS

A gene mutation in the connective tissue of collagen IV and mutations in the COL4A3, COL4A4, and COL4A5 genes cause AS.[2]

The cause of glomerulonephritis is good pasture syndrome (GPS). GPS is caused by autoantibodies against the BM of the glomeruli and alveoli. Abnormality in the BM from a different cause similarly affects AS.[2]

Being male is the highest risk factor for getting AS. Smoking, obesity, hypertension,glucose intolerance, or diabetes mellitus may also damage kidney filters causing AS.[7]

Type IV collagen is a crucial component of the inner ear structure, especially the organ of Corti, which transforms sound waves and impulses from nerves to the brain. Error in type IV collagen

UNDER PEER REVIEW

usually leads to abnormality in the inner ear function, which causes hearing loss.[8] Collagen type IV is also crucial for keeping the shape of the lens and the retina's actual color. Type IV collagen mutation may lead to malformed lenses and an abnormally colored retina. [8, 9]

Genetic implications

AS's modes of inheritance are diverse. These modes of inheritance constitute the types of Alport syndrome.

In about 80% of cases, it is X-linked. It involves the mutation of *the COL4A5*gene. This gene is on the X chromosome. Males are especially susceptible as they only have a single X-chromosome. One disrupted gene of *COL4A5* is enough to cause kidney failure and other symptoms in these patients. In females, a single copy mutation of the *COL4A5* gene mainly results in only hematuria, but some other females can have more severe symptoms. There is also a 50% chance of affected females transferring the disease to their male off-springs. However, fathers who have the disease cannot pass along the X-linked form of this disease to their sons [2, 3].

Type IV collagen alpha 3, 4, and 5 interaction play a functional role in the BM of the kidney, inner ear, and eye [10].The X-linked *COL4A5* gene provides the instructions for making the alpha5 (IV) chain of the type IV collagen. The alpha5 chain combines with the other two chains, alpha3, and alpha4, to form a structurally complete type IV collagen molecule. [10]

In about 15% of cases, the mode of inheritance is autosomal recessive. It involves a mutation in both copies of *the COL4A3* or *COL4A4* gene. For this to occur, an individual's parents must be carriers of one copy of the mutated genes. Most carriers are unaffected, but some could develop a less severe condition called TBMN, indicated by blood in the urine [2].

The autosomal *COL4A3* gene provides the instruction for making the alpha3 (IV) chain of type IV collagen [11].The autosomal *COL4A4* gene provides the instruction for making the alpha4 (IV) chain of type IV collagen [12].

In about 5% of cases, the mode of inheritance is autosomal dominant. In this form of alport syndrome, there is a mutation in either the *COL4A3* or the *COL4A4* gene in each cell [2].Some individuals with alport syndrome present with contiguous gene syndrome. It involves microdeletion of genetic material and loss of function of adjacent genes (genes in close proximity) on the long arm of the X chromosome, which affects the COL4A5 and COL4A6 genes. People with the contiguous gene syndrome often develop associated diseases, like leiomyomatosis and AMME complex, alongside AS. [3]

Molecular genetics and relation to other renal diseases

The genetics of AS was classified under two categories, the X-linked form and the autosomal (Dominant and recessive) form of inheritance. The X-linked form involves the COL4A5 gene mutation, and the autosomal recessive consists of the COL4A3 and COL4A4 gene mutations. However, some cases involved an autosomal dominant pattern and had father-to-son transmission.

UNDER PEER REVIEW

The two categories could not easily be used to classify the disease. In conjunction with that, certain kidney disorders were observed to have a molecular genetic relationship with AS. TBMN, also known as benign familial hematuria, was present in families affected by autosomal recessive AS. There was also an associated finding of heterozygous mutations in the COL4A3 and COL4A4 genes related to TBMN. These findings confirmed the relationship between the two [13].

The spectrum of AS genetics is vast, with one end, TBMN, just involving hematuria with no kidney impairment, and the other, characteristic AS with end-stage renal disease and ocular and hearing abnormalities. So even patients with TBMN have a familial chance of kidney failure [13].The diagnostic finding of kidney diseases and the spectrum of AS has been further problematized with the advent of hereditary focal segmental glomerulosclerosis (FSGS). Genetic analysis of patients with this disease revealed a relationship between AS and the spectrum. [13]

A cohort study conducted by Malone et al. of families diagnosed with hereditary FSGS revealed that a fraction of the families had compound heterozygosity for the COL4A3. There were no FSGS gene mutations implicated in these families. The COL4A3 alleles contained a mutation that can typically cause AS [13]. Alport syndrome pathogenesis involves a defect in the GBM, which would ultimately lead to foot process effacement, so secondary FSGS is commonly observed in late-stage biopsies [13]. Familial focal segmental glomerulosclerosis, characteristic proteinuria, hematuria, and glomerular pathology, can be linked to type IV collagen mutations involving the COL4 genes [13].

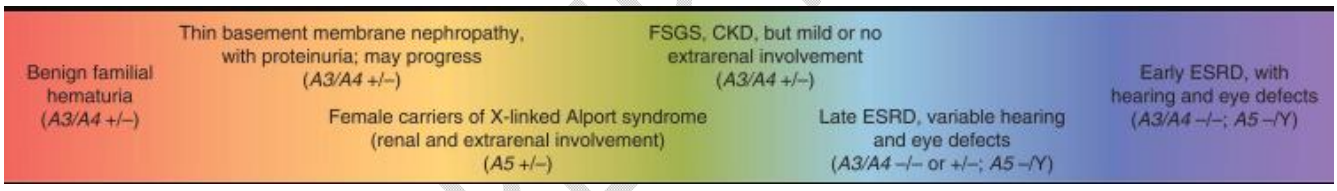

Table: 1 **The spectrum of alport syndrome, thin basement membrane nephropathy (benign familial hematuria) at one end to early-onset end-stage renal disease with hearing and eye defects at the other end.**

https://els-jbs-prod-cdn.jbs.elsevierhealth.com/cms/attachment/1f81bbf1-0abb-435b-9928-be02180d5d61/gr1.jpg

PATHOPHYSIOLOGY

In the kidneys, glomeruli form an integral component of the nephron that filters the blood.The glomeruli have basement membranes called glomerular basement membranes (GBM). GBM has

UNDER PEER REVIEW

fenestrated capillary endothelium, and the podocytes slit diaphragm, forms a selective filter.[14, 15]

In AS, the kidney functions normally through early childhood, but over time the missing or non-functional type 4 collagen causes the GBM to become thin and overly porous, which allows red blood cells to pass through the capillaries, causing microscopic or gross hematuria. Over time, the disease progresses and causes proteinuria. Finally, this excessive protein loss and other factors caused the GBM to undergo sclerosis. AS patient may develop renal insufficiency, due to progressive glomerular damage, leading to renovasular hypertension. Hematuria, renal insufficiency, and hypertension contribute to the categorization of Alport Syndrome as glomerulonephritis.[14,15]

CLINICAL MANIFESTATIONS

In all types of Alport syndrome, the kidneys are affected. The tiny blood vessels in the glomeruli are harmed and may be unable to filter the wastes and extra fluid in the body. Patients with Alport syndrome may have hearing issues and abnormalities in their vision. [3]

Signs and symptoms change according to a person's age, gender, and the inherited type of Alport syndrome. However, the usual symptoms are hematuria (the most common and earliest sign of AS), proteinuria, hypertension, lower limbs and facial edema. [16]

Also, in earlier stages, these symptoms may be noticed: Nausea and vomiting, muscle cramps, loss of appetite, dry or itchy skin, dyspnea, insomnia, and urinating either too much or too little. [3]The first sign of kidney disease is usually microscopic hematuria; however, massive hematuria can occur, particularly after upper respiratory tract infections. In early childhood, males with XLAS usually exhibit persistent microscopic hematuria. Although hematuria may be intermittent, 95% of females with XLAS syndrome have microscopic hematuria. In childhood, hematuria is seen in both males and females with ARAS. [3, 16]

Aortic aneurysms in the chest or abdominal are not uncommon, especially in male patients [16]. Aneurysms happen when the walls of blood vessels balloon outward, potentially rupturing and causing bleeding through the body. [7] The disease can be complicated by chronic renal failure, blindness, chronic renal failure, and permanent deafness.

UNDER PREVIEW

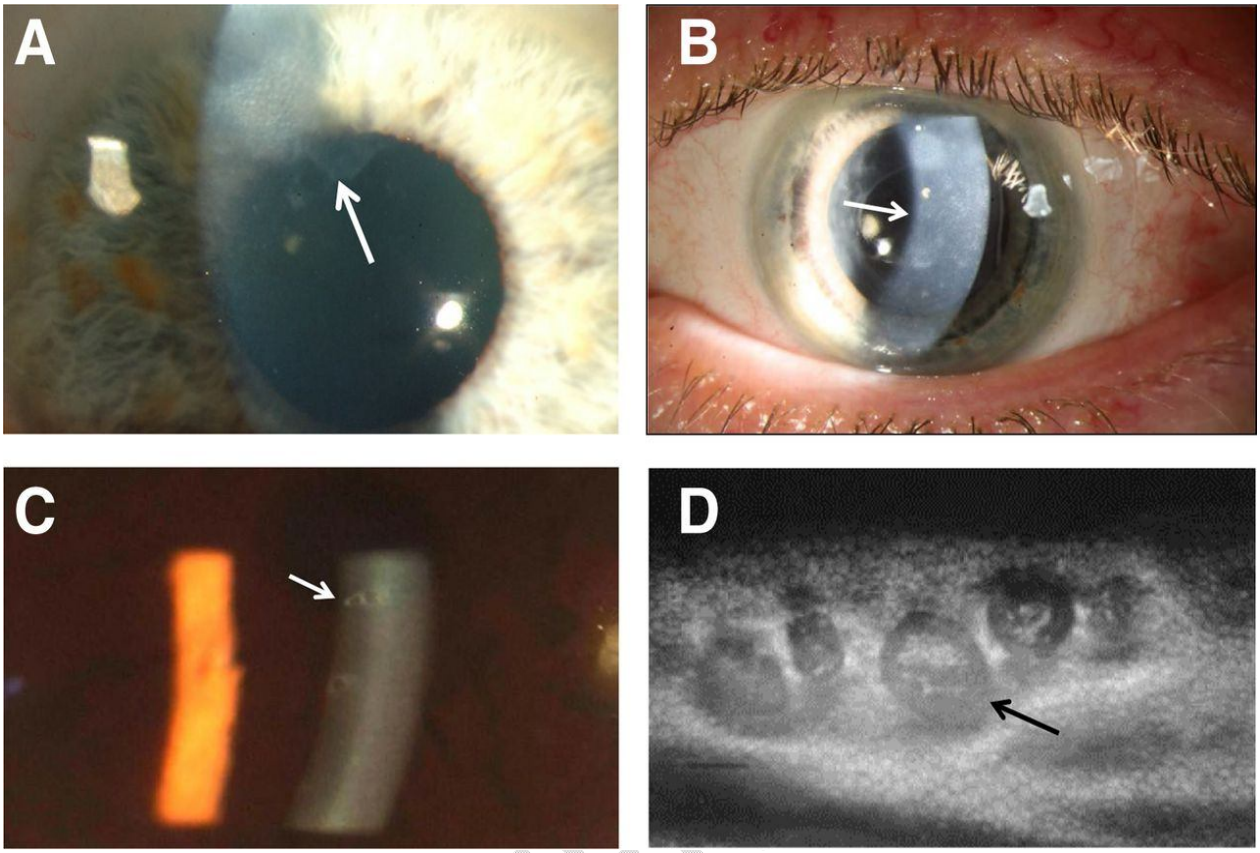

Fig1: Images showing a spectrum of corneal changes in Alport syndrome (Shown by arrows). Slit-lamp microscopy shows A.Scarring and erosion(cornea) B.Posterior corneal dystrophy C. Posterior corneal dystrophy with vesicles D. Doughnut-like lesions, vesicles, clustering around endothelial cells.

Source:https://cjasn.asnjournals.org/content/clinjasn/10/4/703/F2.large.jpg?width=800&height=600&carousel=1

UNDER PEER

Associated diseases

As mentioned previously, people with the contiguous gene syndrome can develop associated conditions: leiomyomatosis and AMME complex.

Leiomyomatosis is characterized by uncontrolled growth and proliferation of smooth muscle cells. It affects the esophagus and presents with difficulty swallowing (dysphagia) due to the narrowing of the esophagus. Vomiting and epigastric pain are also noted. In females, the uterus is affected. There is an enlarged and abnormal uterine wall. Vulva and clitoral hypertrophy are not uncommon [3, 17].

AMME complex is a rare.AMME complex consists of Alport syndrome, intellectual disability, midface hypoplasia, and elliptocytosis. Affected individuals presents with AS features, intellectual

disability, typically mental retardation, mid-face hypoplasia, and abnormally shaped red blood cells (elliptocytosis), which can result in anemia [3, 18].

Thin basement membrane nephropathy (TBMN) describes a condition with hematuria without other signs of kidney disease. People with this nephropathy would have thin glomerular basement membranes on kidney biopsy, and there will be no renal failure or a family history of renal failure. Thin basement membrane nephropathy typically occurs independently of AS, but can also be associated. There is usually an overlap between Alport syndrome and thin basement membrane nephropathy. For one, TBMN results from a diseased variant in one of the type IV collagen genes. Furthermore, people diagnosed with Alport syndrome often have thin glomerular basement membranes. However, hematuria with genetic variants in the COL4A3, COL4A4, or COL4A5 should be diagnosed as Alport syndrome [3].

DIAGNOSIS

Patients with persistent glomerular hematuria and hypertension are suspected of having Alport syndrome and a family history of Alport syndrome or renal failure, which increases the likelihood of being diagnosed with this disease. Other clinical features to note are hearing loss (Audiometry), lenticonus, or retinopathy (Ophthalmoscope).Their presence suggests a high likelihood of diagnosing Alport syndrome.

Baseline investigations like urinalysis to show hematuria and proteinuria are done. Other abnormalserum proteins, electrolytes, urea, and creatinine suggest renal failure.

Molecular genetic testing of the pathogenic variant(s) allows for the diagnosis of Alport syndrome. The pathogenic variants in *COL4A3* and *COL4A4* can be autosomal dominant or autosomal recessive, while pathogenic variants in *COL4A5* are X-linked [19] [20] [21].

Approaches to this Molecular genetic testing can include a combination of gene-targeted and comprehensive genomic testing depending on the phenotype [19].

Histopathology

Basement membranes support the cells and form barriers. The three basement membrane layers are lamina Lucida, lamina densa(which includes the type 4 collagen, and lamina reticularis. [15]

Electron microscopy (EM)of the glomerulus of Alport syndrome can be seen as a Basket-Weave pattern, and on LIGHT MICROSCOPY,the majority of cases revealed two unique pathologic changes:

1. A "zone of separation" between the basilar membrane and overlying cells of the organ of Corti.
2. The presence of cells filling the tunnel of Corti and extracellular spaces of Nuel. [12][21]

UNDER PEER REVIEW

The cytologic loss of hair cells, stria vascularis, and cochlear neuronal cells were insufficient to account for the observed SNHL in our cases. Electron microscopy was applied in four cases; all four revealed the following [15][22]:

1. The zone of separation observed at light microscopy occurred between the basement and basilar membranes.

2. The cells within the tunnel of Corti and the spaces of Nuel were morphologically similar to supporting cells.

3. The basement membrane of the stria capillaries and the spiral vessel (under the basilar membrane) were normal.[15][22]

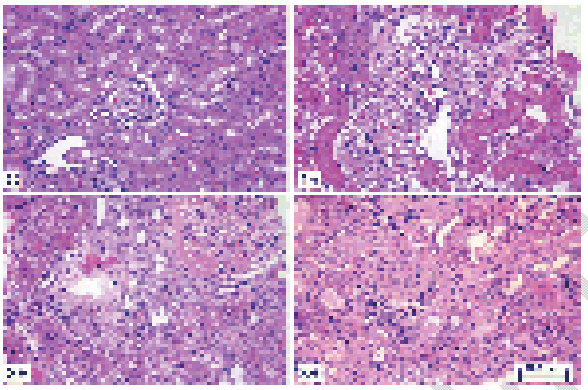

Fig2: Multiple H&E stain showing widened mesangium, mesangial cell proliferation, and sclerosed glomerulus, suggestive of Alport disease.

Source:http://www.dxline.info/diseases/alport-syndrome#

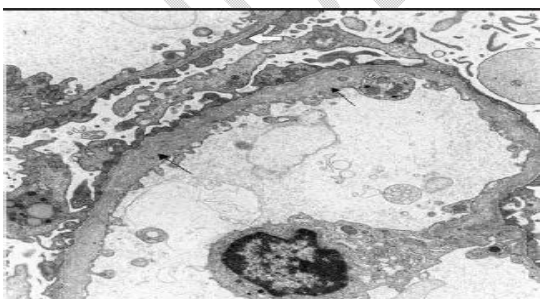

Fig.3: Electron microscopic appearance of the glomerular capillary wall in the Alport syndrome (Basket weave pattern).[22]

UNDER PEER REVIEW

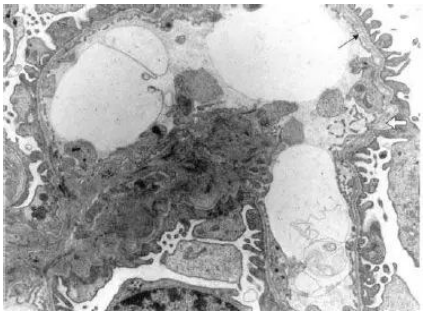

Fig.4:Extensive attention to the GBM. With one short segmentShowing replication of the lamina densa and densa particles within lacunae.[22]

DIFFERENTIAL DIAGNOSIS

Some common differential diagnoses of Alport's syndrome include persistent familial hematuria, renal failure, hearing loss, retinal fleck, and lamellated glomerular basement membrane [23]. These include;

- Polycystic Kidney Disease[24]
- Thin basement membrane nephropathy[24]
- Medullary Cystic Disease [25]
- Epstein Syndrome [26]
- Fechtner Syndrome [27]
- Leiomyomatosis [28]
- MYH9-related disorders (MYH9RD) are characterized by large platelets and thrombocytopenia. It is variably associated with the young-adult onset of progressive sensorineural hearing loss, presenile cataract, the elevation of liver enzymes, and renal disease manifesting initially as glomerular nephropathy [19].

MANAGEMENTOF ALPORT SYNDROME

Alport syndrome is managed by treating symptoms as presented in each patient. [3] In order to reduce proteinuria in children with X-linked Alport syndrome, Angiotensin-converting enzyme (ACE) inhibitors are used [23]. Angiotensin-receptor blockers and aldosterone inhibitors also have additional benefits for proteinuria [29]. Some evidence from a retrospective study, animal models, and other forms of renal failure has suggested that ACE inhibitors delay the onset of end-stage renal failure and improve life expectancy in men, even before the onset of proteinuria [30]. The effect of the renin-angiotensin blockade on proteinuria and renal failure progression must be formally evaluated[21] [31]. Other potential therapies include statins [21] [32], metalloproteinase inhibitors [33], vaso-peptidase inhibitors [34], chemokine receptor antagonists [35], and stem cell therapy [36, 37].Some patients who do not respond to or tolerate ACE inhibitors may be treated with angiotensin receptor blockers (ARBs) which bring about similar results [3].

UNDER PEER REVIEW

Treatment and management may slow the progression of kidney disease in Alport syndrome. There is yet no cure for this disorder, and no drugs or therapy has thus far been shown to completely stop kidney decline [3]. The progression rate to kidney failure in patients with this disease varies highly. In many patients affected by Alport syndrome, kidney function will eventually deteriorate to where dialysis or a kidney transplant is required [3].

The renal failure may be managed conservatively to slow progression before transplantation (stem cells and organ). Numerous drug and drugs trials are employed to reduce the progression of chronic renal failure in these patients ,the most documented list of medications are Sodium-glucose co-transporter 2 inhibitors(SGLT2i),Bardoxolone methyl,Anti-microRNA-21,Endothelin type A receptor inhibitors, angiotensin II type 1 receptor inhibitors, anti-lipidemic drugs (statin) and lipid modifiers, osteopontin blockers,hydroxychloroquine,metformin,Paricalcitrol and chaperones.[21][31][32][33][34]

In case of deafness,hearing aids may be needed. Cataract removal can be suggested for visual issues. Surgical intervention may be required to treat diffuse leiomyomatosis [19].

CONCLUSION

Alport syndrome, also known as hereditary nephrosis is predominantly an X-linked inheritance disorder of type 4 collagen synthesis, but variants may be theautosomal recessive and dominant mode of inheritance. [21]They are commonly seen in males with varying degrees of manifestations. Sensorineural hearing loss and progressive renal disease are the most common characteristics, along with Dot and fleck retinopathy. [4][5]

Early diagnosis of Alport syndrome is crucial since therapeutic blockade of the renin-angiotensin-aldosterone system can slow the progression to End stage renal disease (ESRD).Investigations of Alport syndrome include routine baseline investigations like electrolytes, urea, creatinine, urinalysis, and confirmation, usually with renal biopsy, hearing and genetic tests. Electron microscopy typically shows a Basket-wave appearance.

Therapeutical recommendations are that patients with Alport syndrome should be treated individually, according to the genetic mutation identified, sex, and the clinical stage of the disease. Most researchers have established that no cure can completely stop kidney decline. Therefore, the initial treatment can be ACE inhibitors or angiotensin receptor blockers. However, if the kidney problem worsens, opting fordialysis or a kidney transplant may be necessary.

UNDER PEER REVIEW

REFERENCES

1. Walead Latif, MD, Nephrologist and Clinical Associate Professor, Rutgers Medical School, Newark, NJ. Review provided by VeriMed Healthcare Network 22.2021

Alport syndrome (adam.com)
2. MedlinePlus [Internet]. Bethesda (MD): National Library of Medicine (US); [updated 2020 June 24]. Alport syndrome, Genetics, [updated December 1, 2013; cited 2022 August 16]-
Alport syndrome: MedlinePlus Genetics
3. National Organization for Rare Disorders. NORD Compendium of Rare Diseases and Disorders. Acknowledgment of Clifford Kashtan, MD, FASN, Division of Pediatric Nephrology, Department of Pediatrics, University of Minnesota Medical School; Executive Director, Alport Syndrome Treatments and Outcomes Registry. Alport syndrome. February 13, 2020-
Alport Syndrome - NORD (National Organization for Rare Disorders) (rarediseases.org)

4. BioNews Services, LLC. Alport syndrome News: Prevalence of Alport syndrome.2013-2022.

https://alportsyndromenews.com/prevalence-of-alport-syndrome/

5. C. Michael Gibson, MS, MD, Aarti Narayan, MBBS, Tarek Nafee, Shankar Kumar, Daniel Nethala, and Raviteja Reddy Guddeti. Alport syndrome- WikiDoc. December 2, 2016

https://www.wikidoc.org/index.php/Alport_syndrome_epidemiology_and_demographics#:

6. Expert reviewer(s): Dr. Laurence HEIDET, Pr Rachel LENNON- Orphanet: Alport syndrome. March 2020.https://www.orpha.net/consor/cgi-bin/OC_Exp.php?lng=EN&Expert=63

7. Slajpah M, Gorinsek B, Berginc G, Vizjak A, Ferluga D, Hvala A, Meglic A, Jaksa I, Furlan P, Gregoric A, Kaplan-Pavlovcic S, Ravnik-Glavac M, Glavac D. Sixteen novel mutations identified in COL4A3, COL4A4, and COL4A5 genes in Slovenian families with Alport syndrome and benign familial hematuria. Kidney Int. 2007 Jun; 71(12):1287-95. Epub 2007 March 28.
Alport Syndrome | National Kidney Foundation
8. kashtan CE. Alport syndrome: an inherited disorder of renal, ocular, and cochlear basement membranes. Medicine. 1999; 78:338-60.Alport syndrome. An inherited disorder of renal, ocular, and cochlear basement membranes - PubMed (nih.gov)

9. Distribution of type IV collagen in the cochlea in Alport syndrome - PubMed (nih.gov)Zehnder AF, Adams JC, Santi PA, Kristiansen AG, Wacharasindhu C, Mann S, Kalluri R, Gregory MC, Kashtan CE, Merchant SN.
10. MedlinePlus [Internet]. Bethesda (MD): National Library of Medicine (US); [updated 2020 June 24]. COL4A5 gene, [updated Dec 1, 2013; cited 2022 August 16]

https://medlineplus.gov/genetics/gene/col4a5/

11. MedlinePlus [Internet]. Bethesda (MD): National Library of Medicine (US); [updated 2020 June 24]. COL4A3 gene, [updated Dec 1, 2013; cited 2022 August 16]

UNDER PEER REVIEW

https://medlineplus.gov/genetics/gene/col4a3/

12. MedlinePlus [Internet]. Bethesda (MD): National Library of Medicine (US); [updated 2020 June 24]. COL4A4 gene, [updated Dec 1, 2013; cited 2022 August 16]

    https://medlineplus.gov/genetics/gene/col4a4/

13. . Jeffrey H. Miner Pathology vs. Molecular genetics: (re)defining the spectrum of Alport syndrome. December 1, 2014

    https://www.kidney-international.org/article/S0085-2538(15)30474-9/fulltext

14. Pescucci C, Longo I, Bruttini M, Mari F, Renieri A. Type-IV collagen related diseases. J Nephrol. 2003 Mar-Apr; 16(2):314-6. Review.
    pixorize usmle 1 mnemonic Alport Syndrome | USMLE Step 1 Mnemonic - YouTube

15. Ramesh Saxena, MD, PhD; Chief Editor: Vecihi Batuman, MD, FASN Jun 28, 2021
Alport syndrome - an Osmosis preview - YouTube

16. Thorner PS. Alport syndrome and thin basement membrane nephropathy. Nephron Clin Pract. 2007;106(2):c82-8. Epub 2007 June 6. Review. niddk-health-information
17. Brooke E. Howitt, Bradley J. Quade in Diagnostic Gynecologic and Obstetric Pathology (Third Edition), chapter 20- Uterine Mesenchymal Tumors. February 22, 2018.

    Marc S. Levine, in Textbook of Gastrointestinal Radiology, 2-Volume set (Fourth Edition). 4 March 2022

    https://www.sciencedirect.com/topics/medicine-and-dentistry/leiomyomatosis

18. OMIM AMME COMPLEX, ALPORT SYNDROME, MENTAL RETARDATION, MIDFACE HYPOPLASIA, AND ELLIPTOCYTOSIS; Creation: Victor A. McKusick, 6/1/1999. Contributors: Hilary J. Vernon-updated 04/28/2022
https://www.omim.org/entry/300194
19. Kashtan CE. Alport Syndrome. 2001 Aug 28 [Updated 2019 Feb 21]. In: Adam MP, Mirzaa GM, Pagon RA, et al., editors. GeneReviews® [Internet]. Seattle (WA): University of Washington, Seattle; 1993-2022. Available from:
https://www.ncbi.nlm.nih.gov/books/NBK1207/
20. Kashtan CE, Ding J, Garosi G, Heidet L, Massella L, Nakanishi K, Nozu K, Renieri A, Rheault M, Wang F, Gross O. Alport syndrome: a unified classification of genetic disorders of collagen IV α345: a position paper of the Alport Syndrome Classification Working Group. KidneyInt. 2018;93:104551. [PubMed] [Reference list]
21. Chavez E, Rodriguez J, Drexler Y, Fornoni A. Novel Therapies for Alport Syndrome. *Front Med (Lausanne)*. 2022;9:848389. Published 2022 Apr 25. doi:10.3389/fmed.2022.848389

22. Duvall-Young J, Short CD, Raines MF, Gokal R, Lawler W. Fundus changes in mesangiocapillary glomerulonephritis type II: clinical and fluorescein angiographic findings. *Br J Ophthalmol*. 1989;73(11):900-906. doi:10.1136/bjo.73.11.900

UNDER PEER REVIEW

23. Savige J, Gregory M, Gross O, Kashtan C, Ding J, Flinter F (2013). "Expert guidelines for the management of Alport syndrome and thin basement membrane nephropathy." J Am Soc Nephrol. 24 (3): 364–75. doi:10.1681/ASN.2012020148. PMID 23349312.https://www.wikidoc.org/index.php/Alport_syndrome_differential_diagnosis
24. Hudson BG, Reeders ST, Tryggvason K (1993). "Type IV collagen: structure, gene organization, and role in human diseases. Molecular basis of Goodpasture and Alport syndromes and diffuse leiomyomatosis". J Biol Chem. 268 (35): 26033–6. PMID 8253711. https://www.wikidoc.org/index.php/Alport_syndrome_differential_diagnosis
25. Amari F, Segawa K, Ando F (1994). "Lens coloboma and Alport-like glomerulonephritis." Eur J Ophthalmol. 4 (3): 181–3. PMID 7819734 https://www.wikidoc.org/index.php/Alport_syndrome_differential_diagnosis
26. Lonsdale RN, Roberts PF, Vaughan R, Thiru S (1992). "Familial oesophageal leiomyomatosis and nephropathy." Histopathology. 20 (2): 127–33. PMID 1559666 https://www.wikidoc.org/index.php/Alport_syndrome_differential_diagnosis
27. García-Torres R, Orozco L (1993). "Alport-leiomyomatosis syndrome: an update". Am J Kidney Dis. 22 (5): 641–8. PMID 8238008. https://www.wikidoc.org/index.php/Alport_syndrome_differential_diagnosis
28. McCarthy PA, Maino DM (2000). "Alport syndrome: a review." Clin Eye Vis Care. 12 (3–4): 139–150. PMID 11137428. https://www.wikidoc.org/index.php/Alport_syndrome_differential_diagnosis
29. Kaito H, Nozu K, Iijima K, Nakanishi K, Yoshiya K, Kanda K, Przybyslaw Krol R, Yoshikawa N, Matsuo M: The effect of aldosterone blockade in patients with Alport syndrome. *Pediatr Nephrol* 21: 1824–1829, 2006pmid:17039334 [PubMed] https://jasn.asnjournals.org/content/24/3/364
30. Gross O, Licht C, Anders HJ, Hoppe B, Beck B, Tonshoff B, Hocker B, Wygoda S, Ehrich JH, Pape L, Konrad M, Rascher W, Dotsch J, MullerWiefel DE, Hoyer P, Knebelmann B, Pirson Y, Grunfeld JP, Niaudet P, Cochat P, Heidet L, Lebbah S, Torra R, Friede T, Lange K, Muller GA, Weber M: Early angiotensin-converting enzyme inhibition in Alport syndrome delays renal failure and improves life expectancy. *Kidney Int* 81:494–501, 2012 pmid:22166847 [PubMed] https://jasn.asnjournals.org/content/24/3/364
31. Gross O, Friede T, Hilgers R, Görlitz A, Gavénis K, Ahmed R, Dürr U: Safety and efficacy of the ACE-inhibitor ramipril in Alport syndrome: The double-blind, randomized, placebo-controlled, multicenter phase III EARLY PROTECT Alport trial in pediatric patients [published online July 1, 2012]. *ISRN Pediatr* doi:10.5402/2012/436046pmid:22811928 [PubMed] https://jasn.asnjournals.org/content/24/3/364
32. Koepke ML, Weber M, Schulze-Lohoff E, Beirowski B, Segerer S, Gross O: Nephroprotective effect of the HMG-CoA-reductase inhibitor cerivastatin in a mouse model of progressive renal fibrosis in Alport syndrome. *Nephrol Dial Transplant* 22: 1062–1069, 2007pmid:17287218 [PubMed] https://jasn.asnjournals.org/content/24/3/364
33. Zeisberg M, Khurana M, Rao VH, Cosgrove D, Rougier JP, Werner MC, Shield CF, Werb Z, Kalluri R: Stage-specific action of matrix metalloproteinases influences

UNDER PEER REVIEW

progressive hereditary kidney disease. *PLoS Med* 3: e100, 2006pmid:16509766 https://jasn.asnjournals.org/content/24/3/364

34. Ninichuk V, Gross O, Reichel C, Khandoga A, Pawar RD, Ciubar R, Segerer S, Belemezova E, Radomska E, Luckow B, Perez de Lema G, Murphy PM, Gao JL, Henger A, Kretzler M, Horuk R, Weber M, Krombach F, Schlöndorff D, Anders HJ: Delayed chemokine receptor 1 blockade prolongs survival in collagen 4A3-deficient mice with Alport disease. *J Am Soc Nephrol* 16: 977–985, 2005pmid:15716328 [PubMed] https://jasn.asnjournals.org/content/24/3/364
35. Gross O, Koepke ML, Beirowski B, Schulze-Lohoff E, Segerer S, Weber M: Nephroprotection by antifibrotic and anti-inflammatory effects of the vasopeptidase inhibitor AVE7688. *Kidney Int* 68: 456–463, 2005pmid:16014022 [PubMed] https://www.ncbi.nlm.nih.gov/books/NBK1207/
36. Sugimoto H, Mundel TM, Sund M, Xie L, Cosgrove D, Kalluri R: Bone-marrow-derived stem cells repair basement membrane collagen defects and reverse genetic kidney disease. *Proc Natl Acad Sci U S A* 103: 7321–7326, 2006pmid:16648256 https://jasn.asnjournals.org/content/24/3/364
37. Prodromidi EI, Poulsom R, Jeffery R, Roufosse CA, Pollard PJ, Pusey CD, Cook HT: Bone marrow-derived cells contribute to podocyte regeneration and amelioration of renal disease in a mouse model of Alport syndrome. *Stem Cells* 24: 2448–2455, 2006pmid:16873763 [PubMed] https://jasn.asnjournals.org/content/24/3/364

UNDER PEER REVIEW